

Feasibility of Ultrasound-Guided Lumbar Transforaminal Epidural Steroid Injections for Management of Lumbar Radicular Back Pain

Amaresh Vydyanathan¹, Priya Agrawal², Khaled Donia³, Sayed E Wahezi¹, Sarang S Koushik⁴, Kateryna Slinchenkova¹, Karina Gritsenko¹, Naum Shaparin¹

¹Montefiore Medical Center, Albert Einstein College of Medicine, Bronx, NY, USA; ²Department of Anesthesiology, Perioperative and Pain Medicine, Alameda Health System, Oakland, CA, USA; ³Faculty of Medicine, Menoufia University, Menofia, Egypt; ⁴Valleywise Health Medical Center, Creighton University School of Medicine, Phoenix, AZ, USA

Correspondence: Amaresh Vydyanathan, Email avydyana@montefiore.org; Kateryna Slinchenkova, Email kslinche@student.nymc.edu

Background: Whereas traditional image guidance for placement of transforaminal epidural steroid injections (TFESI) has been fluoroscopy, it has disadvantages including inability to identify soft tissue, radiation exposure, and contrast administration need. Several studies found that ultrasonography is reliable in localizing lumbar nerve root. Few have investigated the feasibility of performing ultrasound guided TFESI in the lumbar spine. This study seeks to aid in filling this gap.

Methods: Patients meeting inclusion criteria (BMI < 25) and exclusion criteria (no spinal deformity or previous lumbar surgery) were enrolled. Ultrasound visualization of nerve root and proximate placement of needle tip guided needle placement. Vascular signals were monitored. The contrast injection was done under real-time ultrasound visualization. Final needle placement with transforaminal epidural spread was assessed for accuracy by contrast fluoroscopy. Complications were assessed.

Results: Thirty ultrasound guided lumbar TFESI were performed. Visualization at the L2, L3, and L4 levels was successful. At the L5 level, needle tip was placed in proximity to the nerve root, but the final needle tip position for transforaminal placement and injection was not visualized; fluoroscopic guidance was used instead. There was no evidence of intravascular injection. No complications were noted.

Conclusion: Ultrasonography shows feasibility as an imaging modality in localizing lumbar intervertebral foramina at higher lumbar levels in patients with normal BMI and no spinal deformities. However, ultrasonography was consistently unable to assist transforaminal needle placement at the L5 level due to poor final needle tip visualization and the requirement of fluoroscopy to advance needle tip transforaminally. While no complications were seen, further controlled trials with larger sample size are needed to investigate safety.

Keywords: ultrasound, transforaminal epidural, lumbar radiculopathy, radicular artery, real-time

Introduction

The traditional imaging method for performing transforaminal epidural injections is fluoroscopy. There are different approaches that may be used to perform the procedure under fluoroscopic guidance. While these approaches are generally safe, there is a risk of inadvertent intravascular injection as well as neural injury.^{1,2}

Therefore, while fluoroscopy is accurate in identification of the relevant neural foramina and performing the injection, it necessitates contrast administration to confirm transforaminal spread and the absence of intravascular injection. Thus, it cannot be used in patients with contrast allergy. Moreover, contrast fluoroscopy may not detect intravascular injection in all cases, and this holds true even with the use of digital subtraction angiography (DSA).^{3,4} Further, the use of DSA increases radiation exposure 2–4-fold compared to fluoroscopy alone.⁵

Ultrasonography has been shown to be sufficiently reliable and accurate in the demonstration of lumbar paravertebral anatomy and performing nerve root injections.⁶ Studies have also stated that ultrasonography can work reliably in localizing lumbar intervertebral foramina; however, they did not investigate the feasibility, including possible anatomical variations between individual lumbar vertebrae that affect the performance of ultrasound guided transforaminal

injections.⁷⁻⁹ Given the occasional need for performing transforaminal epidurals in radiation-sensitive patients like pregnant women or patients with contrast allergy – both of which we have encountered in our practice, studying the feasibility of using ultrasonography in performing the procedure is indicated.

The purpose of this study is to evaluate the feasibility of ultrasonography in the placement of lumbar transforaminal injections at different lumbar levels while evaluating for any complications.

Methods

We conducted a single center feasibility study assessing the performance of lumbar transforaminal epidural injections under ultrasound guidance. The prospective study protocol and consent forms were reviewed and approved by the Einstein Institutional Review Board of the Albert Einstein College of Medicine. The review was approved on 2/28/2017 under IRB#216-6053. The study was conducted in accordance with the Declaration of Helsinki.

Patient Characteristics

Inclusion criteria included patients with lumbar radiculopathy scheduled for transforaminal injections with body mass index less than 35 kg/m². Patients with known spinal deformity or prior spine surgery were excluded. All patients were enrolled for a period of 7 months from December 2016 to June 2017. Informed consent was obtained from all patients.

Study Endpoints

We assessed the placement of needle tip in the corresponding intervertebral foramen in proximity to the exiting nerve and the ability to perform a transforaminal injection with visualization real-time. Contrast Fluoroscopy was used to confirm final needle tip position and the transforaminal spread.

All the injections were done with patients in the prone position and observing standard sterile techniques. A LOGIQ S8 Ultrasound station (GE, MA, USA) with a broadband curved array transducer 1–5 MHz was used. Initially, the probe was placed in the lumbar paraspinal area to obtain a paramedian sagittal view and tilted obliquely to identify corresponding transverse processes as well as the sacral hiatus. Then, a cranial count was performed to mark the lumbar level of interest. Once the correct level was identified in the sagittal plane, the transducer was rotated to a transverse oblique view, and the corresponding spinous process was located. The transducer was then moved laterally until the lamina, which forms the posterior part of the intervertebral foramina, was clearly visualized (Figures 1 and 2).

To visualize the nerve root and radicular artery, the probe was tilted cranio-caudally until the facet joint was visualized, and rotated obliquely until nerve root was visualized in the long axis (Figure 3). The articular processes of the adjoining vertebrae form the posterior border of the intervertebral foramen. At this point, the probe orientation is an

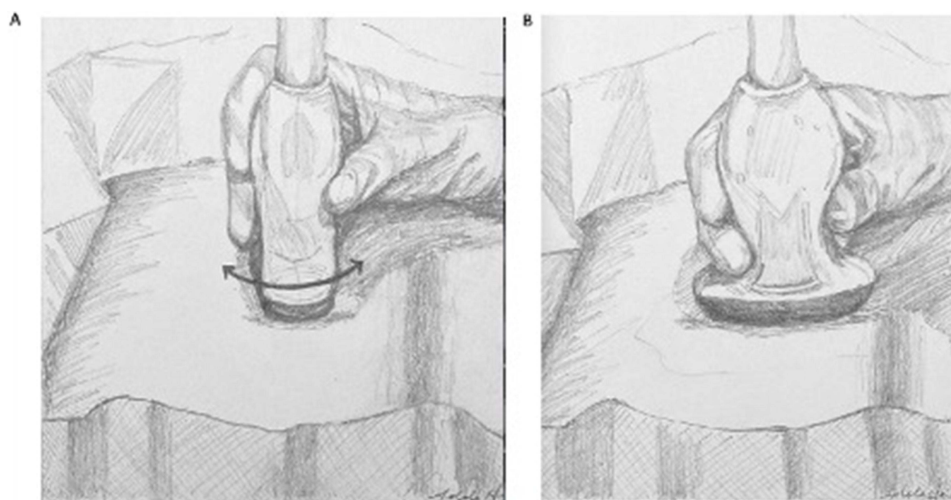


Figure 1 Probe Positioning. Demonstration of the way the probe was placed initially in a midline to parasagittal plane to identify the lumbar level (A) and then how it was placed in a oblique transverse plane to visualize foramen (B).

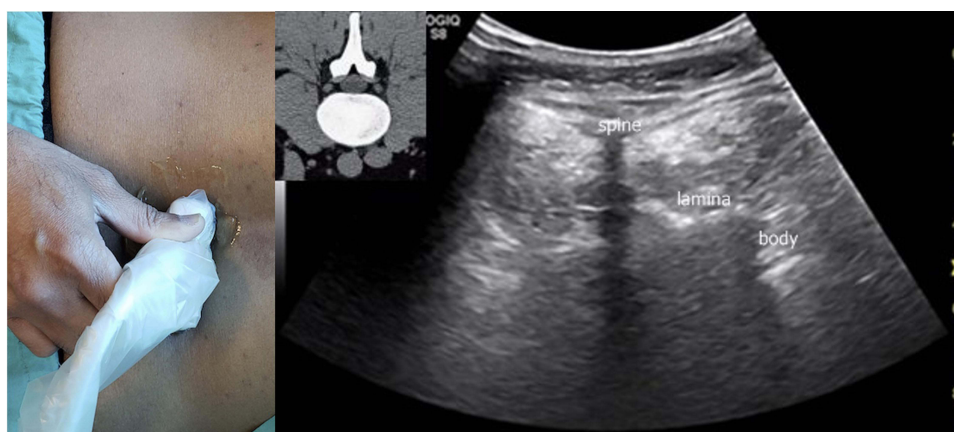


Figure 2 Oblique transverse plane view. The probe position was used to obtain sonographic lumbar spinal anatomic view as outlined. The CT anatomy is also shown for correlation.

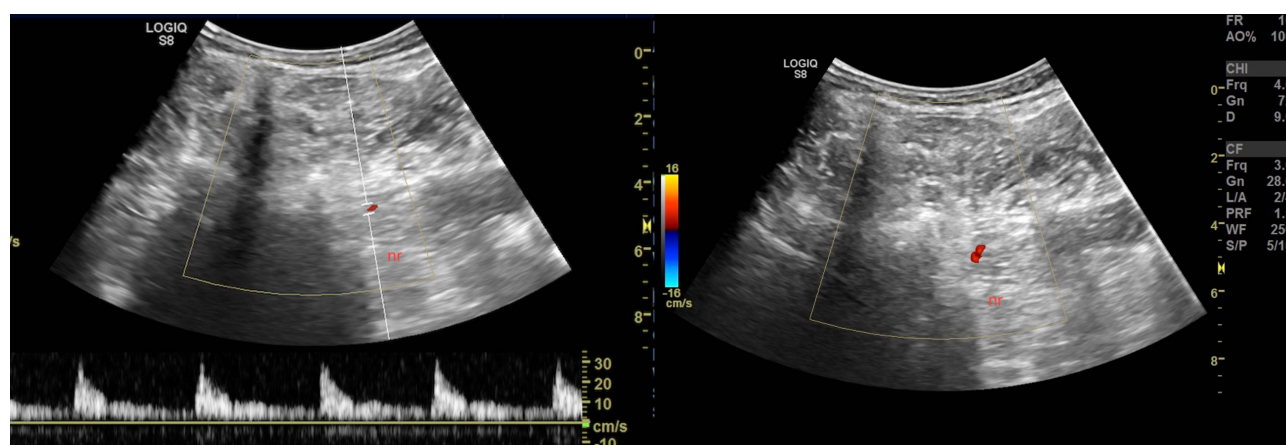


Figure 3 Color duplex and power Doppler demonstrating spinal segmental artery. This could help in directing the needle to avoid the vessel. "nr" indicates nerve root.

oblique transverse view with cranio-caudal tilt as necessary. Then, the probe was adjusted so that any vessels as well as nerve root were no longer in the path of the foramen.

An echogenic Stimuquik 21 gauge 3.5-inch needle (Teleflex, Wayne, PA, USA) was introduced in-plane, and the needle tip position was placed close to the vertebral body at the medial most point of visualization (before it disappeared from view). At this point 0.5 cc of Omnipaque 180 (GE Healthcare, USA) contrast was injected under real-time ultrasound while assessing spread as well as intravascular injection. After injection was completed, the contrast spread and needle tip position were verified by fluoroscopy using the Philips Veradius C-Arm machine (Philips, MA, USA). (Figures 4 and 5).

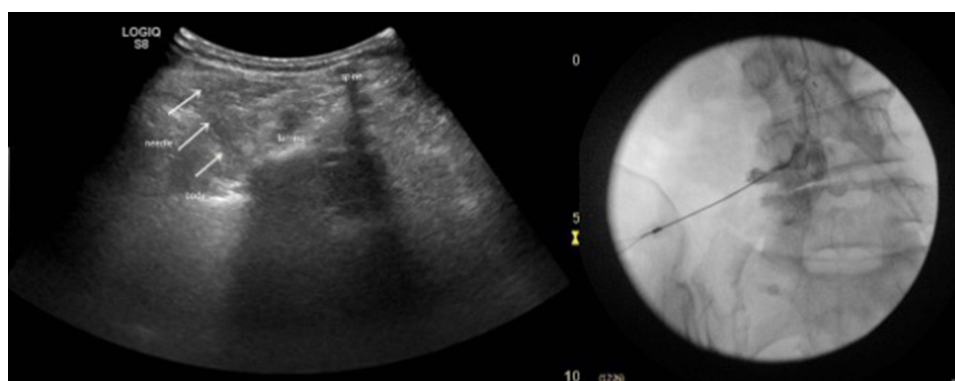


Figure 4 Ultrasound guided transforaminal injection at L4. Needle, needle tip, and dorsal surface of vertebral body are demonstrated. Fluoroscopic confirmation with contrast shows epidural spread indicating appropriate needle tip position.

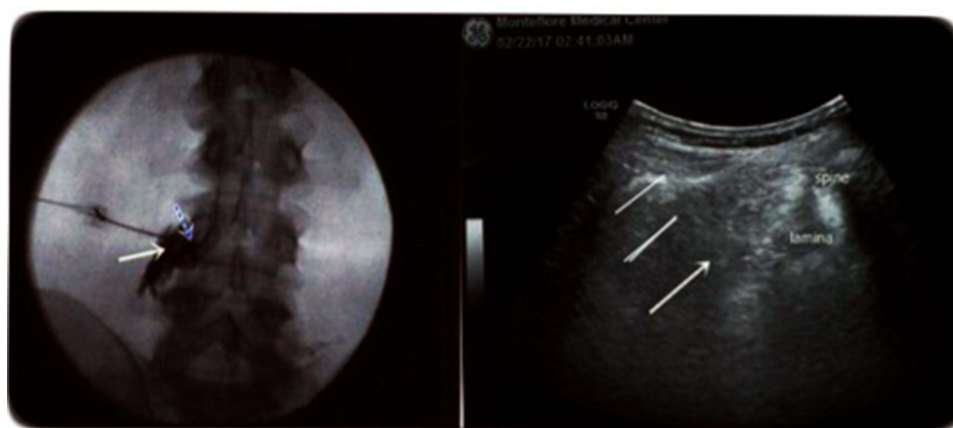


Figure 5 L3 transforaminal epidural injection. This demonstrates needle shadow (arrows) in ultrasound view (right) and corresponding contrast fluoroscopic confirmation of epidural spread (left).

Statistics

As this is a feasibility exploratory study, no prior sample size was calculated. We enrolled 30 patients to evaluate the feasibility of the technique.

Results

Thirty ultrasound guided transforaminal epidural steroid injections were performed: two injections were performed at L2, four injections were performed at L3, fourteen injections were performed at L4 and ten injections were performed at the L5 level.

We could visualize needle tip and real-time injection of contrast with ultrasound at L2, L3 and L4 levels. After contrast injection, AP fluoroscopic images confirmed transforaminal spread (Figure 6).

At the L5 level, the tip of the needle, after using similar technique of placement under ultrasound, was found to be outside the foramen consistently. The AP contrast fluoroscopic imaging demonstrated needle tip placement was lateral and with no epidural flow. To ensure needle placement for epidural flow, the needle tip needed to be advanced under fluoroscopic guidance. Therefore, at the L5 foramen real time transforaminal injection under ultrasound was generally not possible.

Discussion

This study demonstrates the feasibility of using ultrasound guidance in performing lumbar transforaminal injections. This is especially true in the L1-L4 lumbar levels, while the L5 level posed significant challenges.

We examined the anatomy of the lumbar intervertebral foramina to understand the reason for the challenges we encountered with needle placement at the L5 level. The foramina at the lumbar levels face laterally. The anterior border of the intervertebral foramen is formed by the upper vertebra and intervertebral disc, the posterosuperior border is comprised of the inferior articular process (IAP) of the vertebra above and the posteroinferior border is comprised of the superior articular process (SAP) of the vertebra below. The pedicles of the vertebrae above and below form the roof and the floor, respectively.¹⁰

We noted that the posterior border of the foramina is narrower than the anterior border at the upper lumbar levels. This means that the posterior border of foramina is more medially placed than the anterior border in the upper lumbar levels and that gives a window for ultrasound to visualize the needle tip inside the foramina (Figure 6).¹¹ Additionally, this difference between the orientation of the L5 foramen and the foramen at the upper lumbar levels is evident when comparing these levels in lumbar spine MRI images. Lumbar nerves exit their respective foramina at different angles from L1 through L5.¹¹

Ultrasound guided lumbar nerve root injections have been evaluated in previous studies. *Galiano* et al concluded that sonographic guidance is a useful adjunct to increase the safety and efficacy of periradicular injections (posterior transforaminal) in the lumbar spine in a feasibility cadaveric study using CT to confirm needle tip position.⁶ *Sato* et al studied L5 nerve root block under ultrasound guidance with nerve stimulator assistance; the final needle tip position was

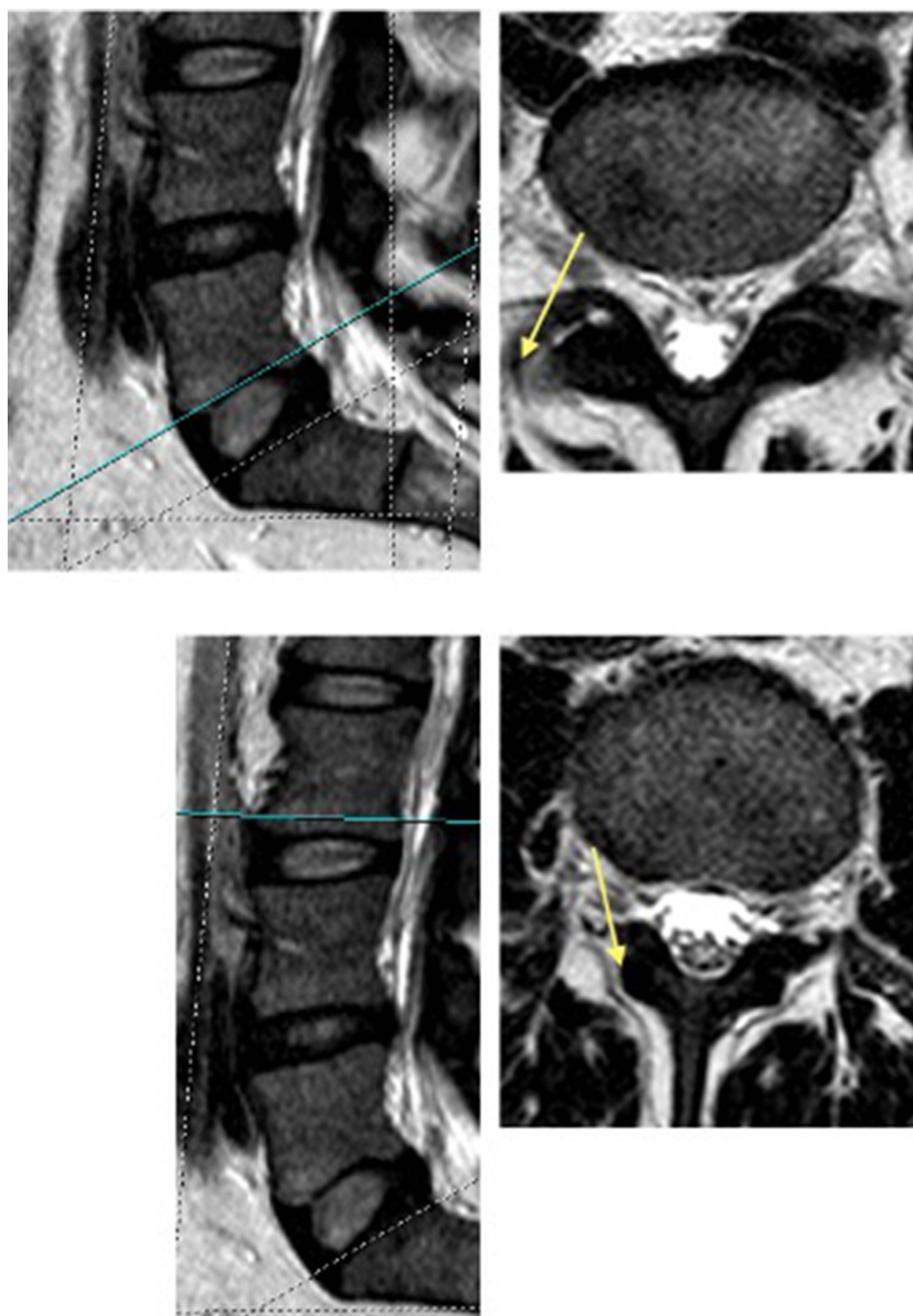


Figure 6 Comparison of anatomical lumbar anatomy on MRI. The sagittal cuts show the level of the corresponding axial cuts (L3 and L5) at the superior part of the foramen. Appreciate the variation in the anteroposterior angulation of the foramen between L3 and L5.

confirmed after contrast injection and fluoroscopic imaging.⁹ Loizides et al compared ultrasound guided to CT-guided paravertebral injections in terms of time for procedure, dose of radiation and pain relief; needle tip in the ultrasound group was confirmed by CT.⁸ One study that has looked at the feasibility of performing transforaminal lumbar epidurals with ultrasound guidance was a cadaveric study by Gofeld et al.⁷ Our study is one of the first to evaluate the feasibility of ultrasound in guiding lumbar transforaminal epidural injections in live subjects.

The two main approaches for performing transforaminal epidural injections are the safe triangle anteriorly or Kambin's triangle posteriorly (Figure 7). In a true anteroposterior (AP) view, the “safe triangle” boundaries consist of

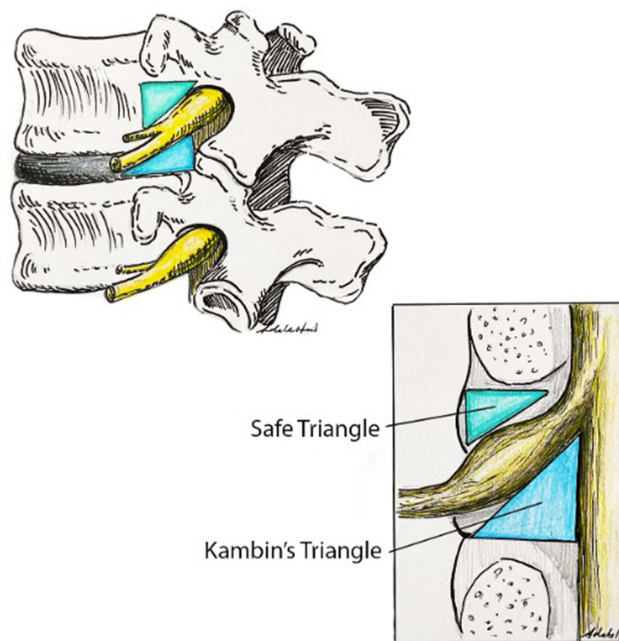


Figure 7 Anatomy of the Safe triangle and Kambin's triangle.

the following: the upper border is formed by the inferior margin of the pedicle, the lateral boundary is a sagittal line extending caudad from the lateral aspect of the pedicle to the segmental nerve, and the hypotenuse is formed by the lateral border of the exiting nerve root.⁸ Kambin's triangle is defined anatomically by the superior endplate of the inferior vertebral body inferiorly, the posterior border by the inferior endplate as well as the superior articular facet with the exiting nerve root forming the hypotenuse.² The approach we used in this study was the anterior approach targeting the safe triangle. Given the anatomy and orientation of the lumbar intervertebral foramen at the different lumbar levels as described earlier, we can clearly see that the placement of the needle anteriorly allows entry into the intervertebral foramen at the upper lumbar levels, while the lower lumbar levels pose greater challenges especially at the L5 level.

The lateral tangential lines denote the orientation of the lateral borders of the corresponding lumbar vertebrae. We can see that the lateral tangential lines diverge anteriorly at L3 and diverge posteriorly at L5 (Figure 8). Examining the

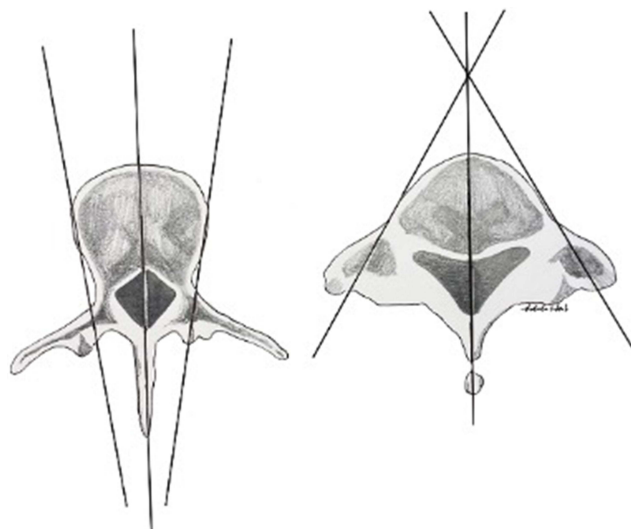


Figure 8 The lateral tangential lines. The lateral tangential lines are depicted here at L3 on left and L5 on the right. As seen, the angulation is very different with the lines diverging anteriorly at L3 and posteriorly at L5.

transverse inter-tangential angle (TITA, [Figure 8](#)) at the different lumbar levels illustrates the difference between L5 vertebrae compared the other lumbar vertebrae.¹² This also allows us to appreciate the orientation of the intervertebral foramina that favors foraminal needle placement at the upper lumbar levels under ultrasound guidance, while it is almost impossible to achieve transforaminal placement at the L5 level with visualization of needle tip. While we encountered consistent requirement of fluoroscopy to access the epidural space transforaminally at L5, *Yang H et al* have described a novel ultrasonographic approach to access the L5 transforaminal epidural space reliably.¹³

One of the advantages of ultrasound guidance is the ability to visualize vasculature. Radicular vessels are frequently in the vicinity of the lumbar nerve roots as they traverse the intervertebral foramen. ([Figure 9](#)).^{14,15} The caliber of the radicular arteries ranges from 0.2 mm to 2 mm and the artery of Adamkiewicz ranges from 0.5 to 0.8 mm.¹⁶ This means it is possible to detect radicular arteries using ultrasound, especially with the use of pulsed wave Doppler and color flow Doppler. In fact, the validity of ultrasound for the assessment of segmental spinal vasculature and anterior spinal artery has previously been described.¹⁷ There is a significant possibility of encountering radicular vessels using either approach while performing transforaminal epidural injections. In theory, using ultrasonographic guidance could help identify and avoid these vessels. We were indeed able to see such vessels in a few of the sonograms ([Figure 4](#)). However, we did not

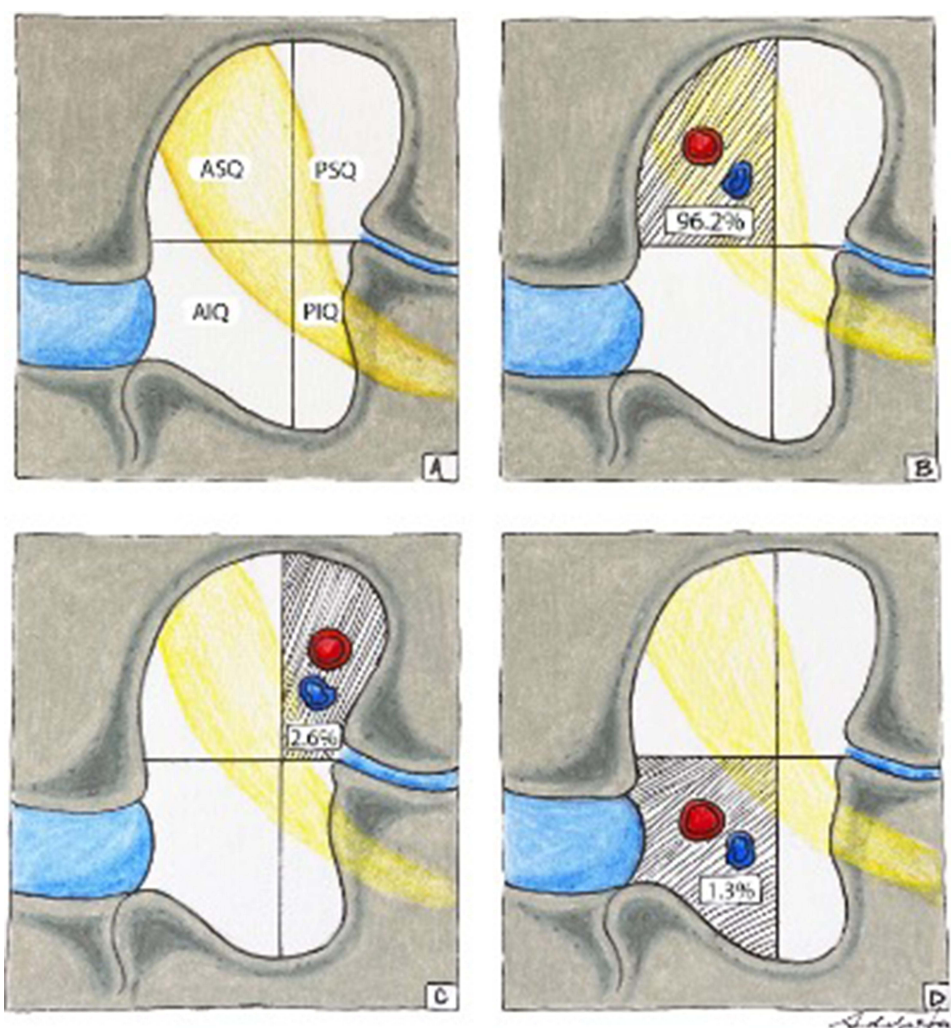


Figure 9 Lumbar intervertebral foramen noting the position of the nerve root and the radicular artery. You can see the radicular artery is most commonly present in the anterosuperior quadrant followed by the postero. (A) Denotes the division of the foramen into 4 quadrants; ASQ-Antero-superior quadrant, AIQ-Antero-inferior quadrant, PSQ-Postero-superior quadrant and PIQ-Postero-inferior quadrant. (B, C and D) denote the likely locations of the nerve root and radicular artery in the respective quadrants – 96.2% found in the ASQ, 2.6% in the PSQ and 1.3% in the AIQ.¹⁴

evaluate this in our study. We also surmise that nearby vessels, especially at the lower lumbar levels may be shielded by the corpus of the vertebra that may affect ultrasonographic visualization.

Our study does have limitations. We did not evaluate the approach in patients with higher BMI that is a significant subset of our population. We also did not evaluate the practicality of this approach as we did not measure the ease and duration of utilizing this technique in performing the procedure in comparison with fluoroscopic technique. Moreover, we found the approach to be challenging and likely to have a long learning curve. It is also very difficult to utilize at the L5 level, which is one of the most common levels that the transforaminal approach is usually used at. We also did not follow the patients over a period to determine any complications, but we also did not encounter any patient reported issues after the procedures.

Conclusion

In this study, we were able to demonstrate the feasibility of ultrasound in guiding needle placement for a TFESI at lumbar levels. Placement at L2, L3 and L4 levels could potentially be carried out safely using ultrasound guidance. Accuracy of the placement could not be demonstrated at the L5 level due to poor final needle tip visualization, and we recommend fluoroscopic confirmation at this level. Moreover, with advances in image quality, portability and the reducing cost of ultrasonography as compared to fluoroscopic image acquisition, ultrasonographic use to perform procedures may improve cost as well as access to patients needing these procedures. Further studies with larger patient populations will be needed to investigate safety of ultrasound use in performing transforaminal epidural injections.

Data Availability Statement

The data that support the findings of this study are available from the corresponding author upon reasonable request.

Author Contributions

All authors made a significant contribution to the work reported, whether that is in the conception, study design, execution, acquisition of data, analysis and interpretation, or in all these areas; took part in drafting, revising or critically reviewing the article; gave final approval of the version to be published; have agreed on the journal to which the article has been submitted; and agree to be accountable for all aspects of the work.

Disclosure

Dr Karina Gritsenko is a consultant for Pacira, outside the submitted work. The authors report no other conflicts of interest in this work.

References

1. Berkwits L, Davidoff SJ, Buttaci CJ, Furman MB. Lumbar transforaminal epidural steroid injection, supraneural (traditional) approach. In: Furman MB, Lee TS, Berkwits L, editors. *Atlas of Image-Guided Spinal Procedures*. 1st ed. Elsevier Saunders; 2013:93–103.
2. Mandell JC, Czuczman GJ, Gaviola GC, Ghazikhanian V, Cho CH. The lumbar neural foramen and transforaminal epidural steroid injections: an anatomic review with key safety considerations in planning the percutaneous approach. *Am J Roentgenol*. 2017;209(1):W26–W35. doi:10.2214/AJR.16.17471
3. Park K, Kim S. Digital subtraction angiography vs real-time fluoroscopy for detection of intravascular injection during transforaminal epidural block. *Yeungnam Univ J Med*. 2019;36(2):109–114. doi:10.12701/yujm.2019.00122
4. Hong JH, Huh B, Shin HH. Comparison between digital subtraction angiography and real-time fluoroscopy to detect intravascular injection during lumbar transforaminal epidural injections. *Reg Anesth Pain Med*. 2014;39(4):329–332. doi:10.1097/AAP.0000000000000096
5. Maus T, Schueler BA, Leng S, Magnuson D, Magnuson DJ, Diehn FE. Radiation dose incurred in the exclusion of vascular filling in transforaminal epidural steroid injections: fluoroscopy, digital subtraction angiography, and CT/fluoroscopy. *Pain Med*. 2014;15(8):1328–1333. doi:10.1111/pme.12455
6. Galiano K, Obwegeser AA, Bodner G, et al. Real-time sonographic imaging for periradicular injections in the lumbar spine: a sonographic anatomic study of a new technique. *J Ultrasound Med*. 2005;24(1):33–38. doi:10.7863/jum.2005.24.1.33
7. Gofeld M, Bristow SJ, Chiu SC, McQueen CK, Bollag L. Ultrasound-guided lumbar transforaminal injections: feasibility and validation study. *Spine*. 2012;37(9):808–812. doi:10.1097/BRS.0b013e3182340096
8. Loizides A, Gruber H, Peer S, Galiano K, Bale R, Obernauer J. Ultrasound-guided versus CT-controlled paravertebral injections in the lumbar spine: a prospective randomized clinical trial. *Am J Neuroradiol*. 2013;34(3):466–470. doi:10.3174/ajnr.A3206
9. Sato M, Simizu S, Kadota R, Takahashi H. Ultrasound- and nerve stimulation-guided L5 nerve root block. *Spine*. 2009;34(24):2669–2673. doi:10.1097/BRS.0b013e3181b43c62

10. Sekhadia MP, Benzon HT. Selective nerve root blocks and transforaminal epidural steroid injections. In: Benzon HT, Raja SN, Fishman SM, Liu SS, Cohen SP, editors. *Essentials of Pain Medicine*. 3rd ed. Elsevier Science; 2008:314–321.
11. Bogduk N. *Clinical and Radiological Anatomy of the Lumbar Spine*. 4th ed. Elsevier Churchill Livingstone; 2005:123–137,237–241.
12. Lin HH, Wang JP, Lin CL, et al. What is the difference in morphologic features of the lumbar vertebrae between Caucasian and Taiwanese subjects? A CT-based study: implications of pedicle screw placement via Roy-Camille and Weinstein method. *BMC Musculoskelet Disord*. 2019;20(1):252. doi:10.1186/s12891-019-2602-4
13. Yang H, Wang H, Lu J, Hu L. A novel simplified sonographic approach with fluoroscopy-controlled L5 transforaminal epidural injections in patients with high iliac crest: a retrospective study. *JA. Clin Rep*. 2024;10(43):1–9. doi:10.1186/s40981-024-00725-0
14. Greg L, Sorte DE, Gailloud P. Intraforaminal location of thoraco-lumbar radicular arteries providing an anterior radiculomedullary artery using flat-panel catheter angiotomography. *Am J Neuroradiol*. 2017;38(5):1054–1060. doi:10.3174/ajnr.A5104
15. Simon JI, McAuliffe M, Smoger D. Location of radicular spinal arteries in the lumbar spine from analysis of CT angiograms of the abdomen and pelvis. *Pain Med*. 2016;17(1):46–51. doi:10.1111/pme.12891
16. Demondion X, Lefebvre G, Fisch O, Vandenbussche L, Cepparo J, Balbi V. Radiographic anatomy of the intervertebral cervical and lumbar foramina (vessels and variants). *Diagn Interv Imaging*. 2012;93(9):690–697. doi:10.1016/j.diii.2012.07.008
17. Allah FA, Majidi S, Watnabe M, Chaudhry SA, Qureshi AI. Feasibility and validation of spinal cord vasculature imaging using high-resolution ultrasound. *J Vasc Surg*. 2012;56(3):637–643. doi:10.1016/j.jvs.2012.02.037

Journal of Pain Research

Publish your work in this journal

The Journal of Pain Research is an international, peer reviewed, open access, online journal that welcomes laboratory and clinical findings in the fields of pain research and the prevention and management of pain. Original research, reviews, symposium reports, hypothesis formation and commentaries are all considered for publication. The manuscript management system is completely online and includes a very quick and fair peer-review system, which is all easy to use. Visit <http://www.dovepress.com/testimonials.php> to read real quotes from published authors.

Submit your manuscript here: <https://www.dovepress.com/journal-of-pain-research-journal>

Dovepress
Taylor & Francis Group