

Cardiac Involvement in Idiopathic Inflammatory Myopathies

Hongji Zhu^{1,2,*}, Runzhao Li^{1,2,*}, Hongxia Tan^{1,*}, Tangdan Ding^{1,2}, Ying Yuan³, Zhihua Wen⁴, Jijun Zhao⁵, Min Liu¹, Qiong Shi¹, Liubing Li¹

¹Department of Laboratory Medicine, The First Affiliated Hospital, Sun Yat-sen University, Guangzhou, 510080, People's Republic of China;

²Department of Laboratory Medicine, Nansha Division of the First Affiliated Hospital, Sun Yat-sen University, Guangzhou, 510080, People's Republic of China; ³Department of Cardiology, The First Affiliated Hospital, Sun Yat-sen University, Guangzhou, 510080, People's Republic of China;

⁴Department of Radiology, The First Affiliated Hospital, Sun Yat-sen University, Guangzhou, Guangdong, 510080, People's Republic of China;

⁵Department of Rheumatology, The First Affiliated Hospital, Sun Yat-sen University, Guangzhou, 510080, People's Republic of China

*These authors contributed equally to this work

Correspondence: Liubing Li; Qiong Shi, Department of Laboratory Medicine, The First Affiliated Hospital, Sun Yat-sen University, Guangzhou, 510080, People's Republic of China, Email lilb8@mail.sysu.edu.cn; sq164258@163.com

Abstract: Idiopathic inflammatory myopathies (IIMs) are a group of autoimmune diseases that includes the main subtypes dermatomyositis, polymyositis, immune-mediated necrotizing myopathy, and inclusion body myositis. IIMs are characterized by the involvement of skeletal muscle and multiple organs, including the heart. This review summarizes the pathology, prevalence, biomarkers, imaging and treatment of cardiac involvement in patients with IIMs. The cardiac involvement in these patients is usually subclinical and rarely considered as the main clinical feature at the time of initial consultation, with a prevalence ranging from 4% to 26%. However, it results in a worse prognosis and represents the main cause of mortality in patients with IIMs. The selection of specific serum cardiac biomarkers is essential for the early detection of cardiac involvement in patients with IIMs, such as cardiac troponin I (cTnI), which is preferred over cardiac troponin T (cTnT), followed by diagnostic evaluations including electrocardiography (ECG), echocardiography (ECHO), and cardiac magnetic resonance imaging (CMR). The combination of glucocorticoids, immunosuppressants, and conventional cardiac medications is effective for the management of IIM patients with confirmed cardiac involvement.

Keywords: IIMs, cardiac involvement, prevalence, biomarkers, imaging, treatment

Introduction

Idiopathic inflammatory myopathies (IIMs) are chronic autoimmune diseases characterized by proximal symmetrical muscle weakness. The main subtypes of IIMs include dermatomyositis (DM), polymyositis (PM), immune-mediated necrotizing myopathy (IMNM), and inclusion body myositis (IBM).^{1,2} Although these subtypes have similar clinical manifestations, they are different in histological appearance and therapeutic approaches.³ The pathogenesis of IIMs is not well understood, but current studies showed that it is related to autoimmunity: (1) histopathological examination revealed that T cells, macrophages, dendritic cells, B cells, and plasma cells are infiltrated in the muscles of patients with IIMs; (2) autoantibodies against cellular components are detected in the blood of more than 50% of patients with IIMs.⁴

Multi-organ involvement is the main characteristic of IIMs, which includes muscles, skin, joints, respiratory and gastrointestinal systems, as well as heart.^{5,6} Symptoms of cardiac involvement in IIMs are usually subclinical, and the main manifestations include myocardial ischemia, valvular disease, pericarditis, myocarditis, arrhythmias, myocardial injury, and pulmonary hypertension.⁷ The top three causes of death in patients with IIMs are cardiac involvement, infection, and malignancy, with the cardiac involvement deaths accounting for 31%.⁸ Zhang et al reported that 132 of the 1530 patients with IIMs died, and 28% (37/132) of these death were caused by cardiac involvement.⁹ Cardiac involvement is one of the causes of poor prognosis and mortality in patients with IIMs. However, cardiac damage is

difficult to detect and diagnose due to the lack of well-established criteria to guide the screening of cardiac involvement in patients with IIMs, as well as because cardiac involvement is usually a subclinical manifestation.¹⁰

The purpose of this review is to summarize the current research on cardiac damage in patients with IIMs, including pathological examinations, prevalence, biomarkers, imaging, and treatment methods (Figure 1), so as to help clinicians in the detection of cardiac involvement on time and prevent adverse consequences.

Diagnosis and Pathological Examination

The 1975 Bohan and Peter criteria were once the most commonly used for the diagnosis of IIMs.¹¹ The current criteria for the diagnosis and classification of IIMs are those published in the 2017 American College of Rheumatology (ACR)/European League Against Rheumatism (EULAR).³ Patients with IIMs show muscle inflammation due to immune-mediated effects. Cardiac muscle has many similarities to skeletal muscle, and there may be a risk of some degree of damage due to immune-mediated effects. Inflammatory cell infiltration is the most common pathological lesion in myocardium, suggesting that patients with IIMs are more likely to suffer from cardiac problems than the general population.^{12–14}

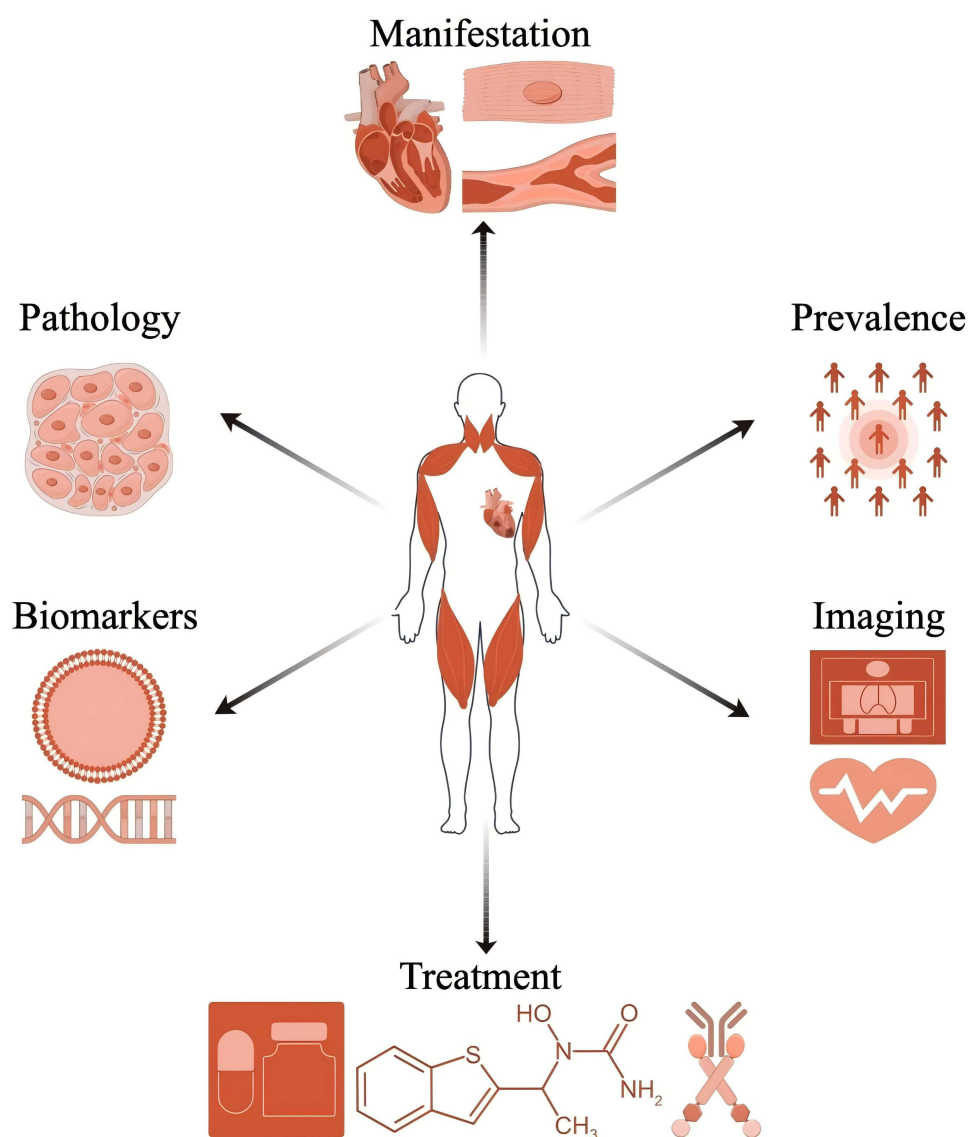


Figure 1 Schematic diagram of the main content of this review.

Cardiac involvement occurs if any of the following conditions are present: (1) myocardial ischemia: the electrocardiogram demonstrates T-wave flattening, inversion, or biphasic changes in three consecutive leads, accompanied by significant S-T segment depression of 0.5 mV or greater. (2) Arrhythmias: the electrocardiogram shows several signs of arrhythmias including frequent atrial premature beats, atrial fibrillation, atrial tachycardia, frequent ventricular premature beats, and sinus tachycardia. Physiological atrial premature beats, ventricular premature beats, ventricular tachycardia, ventricular bradycardia, and other types of conduction blocks are excluded. (3) Myocardial damage: echocardiography (ECHO) reveals atrial or ventricular enlargement, myocardial hypertrophy, abnormal ventricular wall motion, or impaired systolic and diastolic function. The electrocardiogram indicates left ventricular hypertrophy. (4) Pericarditis: ECHO shows the thickening of the pericardium or the presence of pericardial effusion. (5) Pulmonary arterial hypertension: ECHO reveals pulmonary artery systolic pressure and mean pressure at rest exceeding 30 and 20 mm Hg, respectively. (6) Valvular disease: ECHO reveals structural changes in the valves, excluding physiological valve abnormalities. (7) Conduction blocks: the electrocardiogram shows left bundle branch block, complete right bundle branch block, various atrioventricular conduction blocks, without incomplete right bundle branch block. (8) Limb lead low voltage: the electrocardiogram demonstrates a sum of voltages in 3 standard leads or 3 increased limb leads (R+S) less than 0.5 mV. (9) Other findings: electrocardiography (ECG) or ECHO identifies other specific abnormalities in the heart structure or function, including aortic dilatation and myocardial infarction.

Myocarditis is identified in 25% of patients with IIMs by autopsy.¹⁵ Single nuclear inflammatory cells simultaneously or separately infiltrate the endomyocardial and perivascular regions of patients with IIMs. Endomyocardial biopsy is the gold standard in the detection of myocarditis and inflammatory cardiomyopathy, but it is performed only under strict clinical indications because its invasive feature with a risk of myocardial perforation.^{16,17}

It has been reported that the risk of cardiac involvement is highest within the first five years following the diagnosis of IIMs, suggesting the need of closely monitoring the cardiac health of patients during the five-year period following their diagnosis of IIMs.¹⁸ The common clinical symptoms in IIM patients with cardiac involvement include dyspnea, chest pain, palpitations, and syncope,¹⁹ and they are more likely to develop skin ulcers, interstitial lung disease, and increased levels of cardiac troponin I, compared to those without cardiac involvement.²⁰ IIM patients with cardiac involvement are more likely to show anemia, elevated creatine kinase levels, and low levels of complement C3 and serum albumin, especially during flare-ups.²⁰ The association between disease activity status and the appearance of cardiac involvement is not yet fully understood, so still in need of clarification.

Prevalence

In 1899, Oppenheim was the first reporting that patients with PM have cardiac involvement,²¹ but the prevalence of IIMs with cardiac involvement was relatively limited in the past due to the limitations of examination methods. A large retrospective population-based study demonstrated that 774 patients with new IIM onset have a nearly four-fold increased risk of myocardial infarction compared with those without IIMs, while 424 patients with new PM onset have a six-fold increased risk of myocardial infarction in the first year after diagnosis.²² The incidence of cardiac involvement reported in studies that included more than 100 patients with IIMs ranges from 4.4% to 26% (Table 1). The

Table 1 Prevalence of Cardiac Involvement in Idiopathic Inflammatory Myopathies

Author	Region	Case Number	Number of Cardiac Involvement (%)
Sabbagh et al ²⁵	US	619	54 (8.7%)
Feng et al ²⁶	China	44	28 (63.6%)
Prieto et al ¹⁸	UK	603	94 (15.6%)
Huang et al ²⁷	China	2010	204 (10.1%)

(Continued)

Table I (Continued).

Author	Region	Case Number	Number of Cardiac Involvement (%)
Qiu et al ²⁸	China	43	33 (76.7%)
Sun et al ²⁹	China	39	14 (35.9%)
Liu et al ³⁰	China	62	31 (50.0%)
Jung et al ³¹	South Korea	3014	155 (5.1%)
Leclair et al ³²	Sweden	655	53 (8.1%)
Weng et al ³³	Taiwan	882	69 (7.8%)
Antovic et al ³⁴	Sweden	440	67 (15.2%)
Lilleker et al ³⁵	Denmark, UK	121	18 (14.9%)
Rai et al ²²	Canada	783	42 (5.4%)
Carruthers et al ³⁶	Canada	798	35 (4.4%)
Linos et al ³⁷	US	50322	10064 (20.0%)
Limaye et al ³⁸	Australia	167	43 (26.0%)
Taylor et al ³⁹	US	26	21 (80.8%)
Behan et al ⁴⁰	UK	55	33 (60.0%)
Henriksson et al ⁴¹	Sweden	86	52 (60.5%)
Gottdiener et al ⁴²	US	21	16 (76.2%)

data from the EuroMyositis registry declare that cardiac involvement occurs mainly in conjunction with myositis-overlap syndromes, antisynthetase syndrome, and PM among 1715 cases of IIMs with cardiac involvement, with the lowest incidence of cardiac involvement in IBM.²³ Although no correlation was found between the occurrence of cardiac involvement and the severity of IIMs, myocarditis, cardiomyopathy, congestive heart failure, and arrhythmias are important causes of death in patients with IIMs.²⁴

Biomarkers

Cardiac markers commonly used in clinical practice include creatine kinase (CK), creatine kinase isoenzyme MB (CK-MB), myoglobin (MYO), troponin, B-type natriuretic peptide (BNP), and N-terminal B-type natriuretic peptide (NT-proBNP). Muscle inflammation in patients with IIMs results in increased serum creatine muscle enzymes due to the destruction of muscle cells, but their increase does not accurately reflect whether it is caused by IIMs or cardiac involvement. Therefore, the use of CK and CK-MB to evaluate cardiac involvement is not effective in patients with IIMs. MYO begins to increase 0.5–1 hour after cardiac involvement and is often used in clinical practice as a marker for screening myocardial injury because of its high sensitivity. However, it has the same limitation as CK and CK-MB, that is, it has lower cardiac specificity.⁴³

Currently, cardiac troponin I (cTnI) and cardiac troponin T (cTnT) have higher sensitivity and specificity than CK, CK-MB, and MYO in detecting cardiac involvement in IIMs,⁴⁴ despite being different from each other in the evaluation of cardiac involvement in IIMs. CTnI is released only by cardiomyocytes, and its increase is primarily due to the damage of cardiomyocytes caused by inflammation.^{13,45} CTnI testing is essential in the screening for cardiac involvement among patients with IIMs.⁴⁶ A total of 62% of the patients with IIMs and abnormal cTnI have cardiac involvement, while only 21% of the patients with IIMs and abnormal cTnT have it. CTnI has better specificity and positive predictive value than

cTnT, but cTnT is more sensitive than cTnI.³⁵ CTnT derived from regenerated skeletal muscle, and it cross-reacts with skeletal muscle troponin T when detected; thus, increased cTnT in patients with IIMs may be due to the repair of skeletal muscle. This suggests that the combination of cTnT and cTnI may be more effective in determining the presence of cardiac involvement in patients with IIMs.^{24,45} A retrospective analysis revealed that individuals with elevated troponin levels at baseline (82% cTnT and 2.5% cTnI) but no clinical signs of cardiac involvement remained asymptomatic throughout an average follow-up period of 24.5 months.⁴⁷

BNP and NT-proBNP are commonly used in clinical practice as markers for diagnosing acute and chronic heart failure and are used for risk stratification.⁴⁸ In the study of IIMs, higher levels of BNP or NT-proBNP are associated with reduced cardiac function, while higher levels of natriuretic peptide predict poorer outcomes.⁴⁹

Emerging cardiac markers also include growth differentiation factor-15 (GDF-15), growth stimulating expression gene 2 protein (ST2), and galectin-3 (Gal-3). GDF-15 is a member of the β superfamily of transforming growth factors. It regulates inflammatory and apoptotic pathways in damaged tissues and disease processes, and its high expression is involved in a variety of diseases, including renal dysfunction, cancer, diabetes, respiratory disease, and cardiovascular disease. It also predicts the treatment and prognosis of cardiovascular disease.^{50,51} GDF-15 levels in peripheral blood are significantly higher in the IIM-related cardiac involvement group than in the non-cardiac involvement group. ROC curve analysis demonstrated that the optimal cut-off value for GDF-15 in predicting IIMs complicated with cardiac involvement is 929.505 pg/mL, with a sensitivity of 75% and a specificity of 90%, indicating that GDF-15 is an independent risk factor for IIM-related cardiac involvement.²⁸ ST2 is a member of the interleukin-1 receptor family and exists in 3 main forms, mainly soluble ST2 (sST2) in serum, and its concentration in the blood increases when heart disease or injury occurs. If its concentration in the blood is too high, it competitively binds to interleukin-33 (IL-33), preventing IL-33 from binding to the ST2 transmembrane binding subtype, and resulting in the loss of function of the cardiac defense signaling system. Consequently, it induces cardiomyocyte fibrosis and decreases myocardial function.^{52,53} SST2 is an independent predictor for cardiovascular disease, and patients with acute coronary syndromes with its high concentrations have a worse prognosis.⁵⁴ Gal-3 is a soluble β -galactoside-binding protein widely distributed in the heart, kidney, liver, lung, intestine and other tissues and organs, and is highly expressed in activated macrophages, basophils, and mast cells. It is involved in the inflammatory response and immune response, participating in the fibrotic process. Generally, Gal-3 is associated with heart failure and involved in cardiac fibrosis.^{52,53} Thus, sST2 and Gal-3 are emerging cardiac markers recommended by the American Heart Association for risk stratification in patients with acute and chronic heart failure.⁵⁵ Nevertheless, few reports are available on their use for the evaluation of cardiac involvement in patients with IIMs; thus, their use for this purpose needs to be further explored.

Autoantibody testing for IIMs is often used to predict complications and assist in the diagnosis and prognosis of myositis. Autoantibodies associated with cardiac involvement in IIMs include anti-Ro autoantibodies, anti-signal peptide recognition particle (SRP) autoantibodies, and anti-mitochondrial antibodies (AMAs). A total of 69% of the 55 patients with PM showing cardiac involvement are positive for anti-Ro autoantibodies, and 69% of those with specific conduction abnormalities are positive for anti-Ro autoantibodies.⁴⁰ Gupta et al reported that 25% of the 12 patients with PM who are positive for anti-SRP autoantibodies suffer from arrhythmias and 8.3% suffer from cardiomyopathy.⁵⁶ Hengstman et al reported that over half of the 23 patients with PM/DM who are positive for anti-SRP autoantibodies show ECG abnormalities or dyspnea, and 20% report palpitations and chest pain.⁵⁷ Cardiomyopathy and arrhythmias are present in 71.4% of patients who are positive for AMAs.⁵⁸ The incidence of ECG and echocardiographic abnormalities is significantly higher in patients positive for AMAs than in those negative (72.4% versus 28.4%, $P < 0.001$).⁵⁹

Examination

ECG, ECHO, cardiac magnetic resonance imaging (CMR) and other imaging techniques are clinically recognized approaches for the routine examination of cardiac involvement in IIMs.

ECG is mainly used to assess heart condition by recording the changes in electrical activity produced by each cardiac cycle. Arrhythmias and conduction abnormalities are the most prominent manifestations of PM/DM-related cardiac involvement, but ECG changes are mostly nonspecific.^{60,61} One-third of patients with PM/DM have ECG abnormalities, primarily involving conduction disturbances, chamber enlargement, and rhythm disorders, the latter including

supraventricular tachycardia, ventricular tachycardia, atrial fibrillation, and first-degree atrioventricular block. PM patients are more likely to have abnormal ECG such as left ventricular hypertrophy, left atrial enlargement, supraventricular and ventricular arrhythmias, as well as left anterior bundle branch block than DM patients ($P < 0.05$).⁶¹ PM/DM patients have a longer QTc interval and QRS complexes with a longer duration compared with healthy controls.^{62,63}

ECHO assesses not only heart function but also the condition of heart valves. ECHO abnormalities occur in 14 to 65% of patients with IIMs,²⁴ with left ventricular diastolic dysfunction being the most common (34.5%),¹⁹ and related to the duration of the disease, followed by cardiac involvement cases of left ventricular hypersystole and mitral valve prolapse.⁶³ Studies using global longitudinal strain to assess cardiac function show that it is significantly lower in the left and right ventricles in patients with IIMs than controls.^{62,64}

Although both ECG and ECHO can be used to perform a correct diagnosis of IIM-related cardiac involvement, they are not sensitive to early cardiac involvement. CMR, a noninvasive imaging modality for the detection of myocarditis, sarcoidosis, and ischemic myocardial infarction, is currently considered a reliable method for detecting myocarditis and myocardial fibrosis; multiparametric CMR has higher sensitivity than ECG and ECHO to detect early cardiac involvement.⁶⁵ Late gadolinium enhancement (LGE) lesions are milder in patients with DM than in those with PM, whereas LGE is not detected in IMNM patients.²⁹ Although patients with IIMs do not have significant clinical manifestations revealing cardiac involvement, CMR found that nearly 50% of patients suffer from LGE, suggesting that they suffer from acute myocardial necrosis or chronic myocardial fibrosis.⁶⁶ According to the results of CMR performed at first patient diagnosis and one year after treatment, CMR can be used to monitor the therapeutic effects in those with IIMs.^{67,68}

Other imaging techniques available for the heart include technetium 99m-pyrophosphate scintigraphy and nuclear cardiac imaging. Data on the use of these two techniques to discover cardiac involvement in patients with IIMs are limited and further research is needed.

Screening Strategy

When creating screening plans, it is essential to carefully choose the method, balancing clinical, technical, and economic factors. Chen et al proposed a screening strategy to evaluate heart involvement in patients with IIMs.⁴⁵ The screening strategy suggests the use of high-sensitivity cTnI tests, ECG and ECHO for all IIM patients. Myocardial involvement is unlikely if cTnI is below the upper reference limit and both ECG and echocardiogram show no abnormalities. If cTnI tests are negative but ECG or echocardiogram show abnormalities or the abnormalities are present on these three tests, a detailed heart assessment like CMR should follow to identify other potential causes, since CMR is time-consuming and expensive.

Treatment

Established consensus guidelines for the management of cardiac involvement in IIMs are currently lacking. The treatment approaches are predominantly derived from expert opinions and anecdotal case reports, rather than being informed by evidence-based guidelines. As regards IIM patients with cardiac involvement, either symptomatic or asymptomatic but with abnormal cardiac test findings, glucocorticoid treatment is the preferred treatment, similar to the management of general IIM patients. A short-term high-dose steroid regimen ameliorates myocardial inflammation, enhances impaired cardiac function, and mitigates heart failure.¹⁶ The combination of glucocorticoids and immunosuppressants results in superior clinical outcomes compared to glucocorticoid monotherapy.⁶⁹ Methylprednisolone pulse therapy, followed by immunosuppressants is beneficial in improving IIM patients with myocarditis, as evidenced by CMR parameters that exhibited a trend toward normalization after a six-month follow-up.⁷⁰ Furthermore, a patient with DM positive for anti-MDA5 autoantibody demonstrated substantial improvement in cardiac involvement after receiving treatment with prednisone and cyclophosphamide, with restored cardiac function and normalized NT-proBNP levels.⁷¹ The treatment strategies for IIM patients with confirmed cardiac involvement are primarily based on glucocorticoids combined with immunosuppressants and traditional cardiac medications. A case report regarding myocardial involvement in anti-mitochondrial antibody-positive myositis showed that, in addition to the use of methylprednisolone and tacrolimus to manage the primary disease, sacubitril/valsartan and metoprolol succinate were also concurrently used to improve cardiac function.⁷² However, statins should be used with caution because they may worsen IIMs.⁷³ Biologic

therapies and intravenous immunoglobulins can be used in patients with refractory IIMs; however, results on the application of biological and intravenous immunoglobulins for cardiac involvement in IIMs are very limited, and more clinical trials are needed to confirm the efficacy.^{74–76}

Conclusion

The clinical manifestations of cardiac involvement in IIMs are usually not immediately apparent, with a prevalence ranging from 4% to 26%. It is essential to select specific serum cardiac biomarkers for the early detection of cardiac involvement in patients with IIMs, including cTnI, which is preferred over cTnT, followed by diagnostic evaluations using ECG, ECHO, or CMR. The combination of glucocorticoids, immunosuppressants, and conventional cardiac medications is effective for the management of IIM patients with confirmed cardiac involvement. Any abnormality in either cardiac biomarkers or imaging evaluation needs a thorough assessment of the patient's cardiac involvement, facilitating the timely and effective treatment of such patients by clinicians. The analysis of large-scale medical data in future research to construct predictive models for patients with IIMs facilitates the early identification of cardiac involvement. It is necessary to investigate new biomarkers and integrate them into clinical practice, thereby creating personalized follow-up plans and interventions. Furthermore, improving pharmacotherapy and developing more precise interventional surgical techniques may enhance the safety and efficacy of treatments.

Author Contributions

All authors made a significant contribution to the work reported, whether that is in the conception, study design, execution, acquisition of data, analysis and interpretation, or in all these areas; took part in drafting, revising or critically reviewing the article; gave final approval of the version to be published; have agreed on the journal to which the article has been submitted; and agree to be accountable for all aspects of the work.

Funding

This research was supported by the Guangdong Basic and Applied Basic Research Fund (2020A1515110173).

Disclosure

The authors declare that the research was conducted in the absence of any commercial or financial relationships that could be construed as potential conflicts of interest.

References

1. Lundberg IE, Fujimoto M, Vencovsky J, et al. Idiopathic inflammatory myopathies. *Nat Rev Dis Primers*. 2021;7(1):86. doi:10.1038/s41572-021-00321-x
2. Dalakas MC. Polymyositis, dermatomyositis and inclusion-body myositis. *New Engl J Med*. 1991;325(21):1487–1498. doi:10.1056/nejm199111213252107
3. Lundberg IE, Tjälrlund A, Bottai M, et al. 2017 European League Against Rheumatism/American College of Rheumatology classification criteria for adult and juvenile idiopathic inflammatory myopathies and their major subgroups. *Ann Rheumatic Dis*. 2017;76(12):1955–1964. doi:10.1136/annrheumdis-2017-211468
4. Miller FW, Lamb JA, Schmidt J, Nagaraju K. Risk factors and disease mechanisms in myositis. *Nat Rev Rheumatol*. 2018;14(5):255–268. doi:10.1038/nrrheum.2018.48
5. Oldroyd AGS, Lilleker JB, Amin T, et al. British Society for Rheumatology guideline on management of paediatric, adolescent and adult patients with idiopathic inflammatory myopathy. *Rheumatology*. 2022;61(5):1760–1768. doi:10.1093/rheumatology/keac115
6. Long K, Danoff SK. Interstitial lung disease in polymyositis and dermatomyositis. *Clin Chest Med*. 2019;40(3):561–572. doi:10.1016/j.ccm.2019.05.004
7. Pan SY, Tian HM, Zhu Y, et al. Cardiac damage in autoimmune diseases: target organ involvement that cannot be ignored. *Front Immunol*. 2022;13:1056400. doi:10.3389/fimmu.2022.1056400
8. Limaye V, Hakendorf P, Woodman RJ, Blumbergs P, Roberts-Thomson P. Mortality and its predominant causes in a large cohort of patients with biopsy-determined inflammatory myositis. *Internal Med J*. 2012;42(2):191–198. doi:10.1111/j.1445-5994.2010.02406.x
9. Zhang L, Wang GC, Ma L, Zu N. Cardiac involvement in adult polymyositis or dermatomyositis: a systematic review. *Clin Cardiol*. 2012;35(11):686–691. doi:10.1002/clc.22026
10. Schwartz T, Diederichsen LP, Lundberg IE, Sjaastad I, Sanner H. Cardiac involvement in adult and juvenile idiopathic inflammatory myopathies. *RMD Open*. 2016;2(2):e000291. doi:10.1136/rmdopen-2016-000291
11. Bohan A, Peter JB. Polymyositis and dermatomyositis (first of two parts). *New Engl J Med*. 1975;292(7):344–347. doi:10.1056/nejm197502132920706

12. Parkes JE, Day PJ, Chinoy H, Lamb JA. The role of microRNAs in the idiopathic inflammatory myopathies. *Curr Opin Rheumatol*. 2015;27(6):608–615. doi:10.1097/bor.0000000000000225
13. Hughes M, Lilleker JB, Herrick AL, Chinoy H. Cardiac troponin testing in idiopathic inflammatory myopathies and systemic sclerosis-spectrum disorders: biomarkers to distinguish between primary cardiac involvement and low-grade skeletal muscle disease activity. *Ann Rheumatic Dis*. 2015;74(5):795–798. doi:10.1136/annrheumdis-2014-206812
14. Fairley JL, Wicks I, Peters S, Day J. Defining cardiac involvement in idiopathic inflammatory myopathies: a systematic review. *Rheumatology*. 2021;61(1):103–120. doi:10.1093/rheumatology/keab573
15. Haupt HM, Hutchins GM. The heart and cardiac conduction system in polymyositis-dermatomyositis: a clinicopathologic study of 16 autopsied patients. *Am J Cardiol*. 1982;50(5):998–1006. doi:10.1016/0002-9149(82)90408-8
16. Sharma K, Orbai AM, Desai D, et al. Brief report: antisynthetase syndrome-associated myocarditis. *J Card Fail*. 2014;20(12):939–945. doi:10.1016/j.cardfail.2014.07.012
17. Dieval C, Deligny C, Meyer A, et al. Myocarditis in patients with antisynthetase syndrome: prevalence, presentation, and outcomes. *Medicine*. 2015;94(26):e798. doi:10.1097/md.0000000000000798
18. Párraga Prieto C, Ibrahim F, Campbell R, Chinoy H, Galloway J, Gordon P. Similar risk of cardiovascular events in idiopathic inflammatory myopathy and rheumatoid arthritis in the first 5 years after diagnosis. *Clin Rheumatol*. 2021;40(1):231–238. doi:10.1007/s10067-020-05237-7
19. Gupta R, Wayangankar SA, Targoff IN, Hennebry TA. Clinical cardiac involvement in idiopathic inflammatory myopathies: a systematic review. *Int J Cardiol*. 2011;148(3):261–270. doi:10.1016/j.ijcard.2010.08.013
20. Li YH, Du Y, Li L, et al. [Analysis of immunological characteristics of dermatomyositis patients with myocardial involvement]. *Zhonghua yi xue za zhi*. 2020;100(10):753–756. Danish. doi:10.3760/cma.j.cn112137-20190815-01812
21. Oppenheim H. Zur dermatomyositis [About dermatomyositis]. *Berl Klin Wochenschr*. 1899;36:805–807. German.
22. Rai SK, Choi HK, Sayre EC, Aviña-Zubieta JA. Risk of myocardial infarction and ischaemic stroke in adults with polymyositis and dermatomyositis: a general population-based study. *Rheumatology*. 2016;55(3):461–469. doi:10.1093/rheumatology/kev336
23. Lilleker JB, Vencovsky J, Wang G, et al. The EuroMyositis registry: an international collaborative tool to facilitate myositis research. *Ann Rheumatic Dis*. 2018;77(1):30–39. doi:10.1136/annrheumdis-2017-211868
24. Jayakumar D, Zhang R, Wasserman A, Ash J. Cardiac manifestations in idiopathic inflammatory myopathies: an overview. *Cardiol Rev*. 2019;27(3):131–137. doi:10.1097/crd.0000000000000241
25. Sabbagh SE, Pinal-Fernandez I, Casal-Dominguez M, et al. Anti-mitochondrial autoantibodies are associated with cardiomyopathy, dysphagia, and features of more severe disease in adult-onset myositis. *Clin Rheumatol*. 2021;40(10):4095–4100. doi:10.1007/s10067-021-05730-7
26. Feng C, Liu W, Sun X, et al. Myocardial involvement characteristics by cardiac MR imaging in patients with polymyositis and dermatomyositis. *Rheumatology*. 2022;61(2):572–580. doi:10.1093/rheumatology/keab271
27. Huang Y, Liu H, Wu C, et al. Ventricular arrhythmia predicts poor outcome in polymyositis/dermatomyositis with myocardial involvement. *Rheumatology*. 2021;60(8):3809–3816. doi:10.1093/rheumatology/keaa872
28. Qiu M, Sun X, Qi X, et al. The diagnostic value of GDF-15 for myocardial involvement in idiopathic inflammatory myopathy. *Rheumatology*. 2021;60(6):2826–2833. doi:10.1093/rheumatology/keaa721
29. Sun J, Yin G, Xu Y, et al. Phenotyping of myocardial involvement by cardiac magnetic resonance in idiopathic inflammatory myopathies. *Eur Radiol*. 2021;31(7):5077–5086. doi:10.1007/s00330-020-07448-7
30. Liu Y, Fang L, Chen W, et al. Identification of characteristics of overt myocarditis in adult patients with idiopathic inflammatory myopathies. *Cardiovasc Diagn Ther*. 2020;10(3):405–420. doi:10.21037/cdt.2020.03.04
31. Jung KH, Kim HJ, Park W, et al. Incidence, survival, and risk of cardiovascular events in adult inflammatory myopathies in South Korea: a nationwide population-based study. *Scand J Rheumatol*. 2020;49(4):323–331. doi:10.1080/03009742.2019.1707281
32. Leclair V, Svensson J, Lundberg IE, Holmqvist M. Acute coronary syndrome in idiopathic inflammatory myopathies: a population-based study. *J Rheumatol*. 2019;46(11):1509–1514. doi:10.3899/jrheum.181248
33. Weng MY, Lai EC, Kao Yang YH. Increased risk of coronary heart disease among patients with idiopathic inflammatory myositis: a nationwide population study in Taiwan. *Rheumatology*. 2019;58(11):1935–1941. doi:10.1093/rheumatology/kez076
34. Antovic A, Notarnicola A, Svensson J, Lundberg IE, Holmqvist M. Venous thromboembolic events in idiopathic inflammatory myopathy: occurrence and relation to disease onset. *Arthritis Care Res*. 2018;70(12):1849–1855. doi:10.1002/acr.23560
35. Lilleker JB, Diederichsen ACP, Jacobsen S, et al. Using serum troponins to screen for cardiac involvement and assess disease activity in the idiopathic inflammatory myopathies. *Rheumatology*. 2018;57(6):1041–1046. doi:10.1093/rheumatology/key031
36. Carruthers EC, Choi HK, Sayre EC, Aviña-Zubieta JA. Risk of deep venous thrombosis and pulmonary embolism in individuals with polymyositis and dermatomyositis: a general population-based study. *Ann Rheumatic Dis*. 2016;75(1):110–116. doi:10.1136/annrheumdis-2014-205800
37. Linos E, Fiorentino D, Lingala B, Krishnan E, Chung L. Atherosclerotic cardiovascular disease and dermatomyositis: an analysis of the Nationwide Inpatient Sample survey. *Arthritis Res Therapy*. 2013;15(1):R7. doi:10.1186/ar4135
38. Limaye VS, Lester S, Blumbers P, Roberts-Thomson PJ. Idiopathic inflammatory myositis is associated with a high incidence of hypertension and diabetes mellitus. *Int J Rheum Dis*. 2010;13(2):132–137. doi:10.1111/j.1756-185X.2010.01470.x
39. Taylor AJ, Wortham DC, Burge JR, Rogan KM. The heart in polymyositis: a prospective evaluation of 26 patients. *Clin Cardiol*. 1993;16(11):802–808. doi:10.1002/clc.4960161110
40. Behan WM, Behan PO, Gairns J. Cardiac damage in polymyositis associated with antibodies to tissue ribonucleoproteins. *Br Heart J*. 1987;57(2):176–180. doi:10.1136/hrt.57.2.176
41. Henriksson KG, Sandstedt P. Polymyositis—treatment and prognosis. A study of 107 patients. *Acta neurol Scand*. 1982;65(4):280–300. doi:10.1111/j.1600-0404.1982.tb03087.x
42. Gottdiener JS, Sherber HS, Hawley RJ, Engel WK. Cardiac manifestations in polymyositis. *Am J Cardiol*. 1978;41(7):1141–1149. doi:10.1016/0002-9149(78)90871-8
43. Jacob R, Khan M. Cardiac biomarkers: what is and what can be. *Indian J Cardiovasc Dis Women WINCARS*. 2018;3(4):240–244. doi:10.1055/s-0039-1679104
44. Myhr KA, Pecini R. Management of myocarditis in myositis: diagnosis and treatment. *Curr Rheumatol Rep*. 2020;22(9):49. doi:10.1007/s11926-020-00925-4

45. Chen F, Peng Y, Chen M. Diagnostic approach to cardiac involvement in idiopathic inflammatory myopathies. *Int Heart J*. 2018;59(2):256–262. doi:10.1536/ihj.17-204
46. Zhang H, Chi H, Xie L, et al. The use of high-sensitivity cardiac troponin I in assessing cardiac involvement and disease prognosis in idiopathic inflammatory myopathy. *Adv Rheumatol*. 2023;63(1):52. doi:10.1186/s42358-023-00332-0
47. Aggarwal R, Lebiecz-Odrobina D, Sinha A, Manadan A, Case JP. Serum cardiac troponin T, but not troponin I, is elevated in idiopathic inflammatory myopathies. *J Rheumatol*. 2009;36(12):2711–2714. doi:10.3899/jrheum.090562
48. Rørth R, Jhund PS, Yilmaz MB, et al. Comparison of BNP and NT-proBNP in patients with heart failure and reduced ejection fraction. *Circulation*. 2020;13(2):e006541. doi:10.1161/circheartfailure.119.006541
49. Rosenbohm A, Buckert D, Gerischer N, et al. Early diagnosis of cardiac involvement in idiopathic inflammatory myopathy by cardiac magnetic resonance tomography. *J Neurol*. 2015;262(4):949–956. doi:10.1007/s00415-014-7623-1
50. Wollert KC, Kempf T, Wallentin L. Growth differentiation factor 15 as a biomarker in cardiovascular disease. *Clin Chem*. 2017;63(1):140–151. doi:10.1373/clinchem.2016.255174
51. Shin MY, Kim JM, Kang YE, et al. Association between Growth Differentiation Factor 15 (GDF15) and cardiovascular risk in patients with newly diagnosed type 2 diabetes mellitus. *J Korean Med Sci*. 2016;31(9):1413–1418. doi:10.3346/jkms.2016.31.9.1413
52. Meijers WC, Bayes-Genis A, Mebazaa A, et al. Circulating heart failure biomarkers beyond natriuretic peptides: review from the Biomarker Study Group of the Heart Failure Association (HFA), European Society of Cardiology (ESC). *Eur J Heart Fail*. 2021;23(10):1610–1632. doi:10.1002/ehf.2346
53. van der Velde AR, Lexis CP, Meijers WC, et al. Galectin-3 and sST2 in prediction of left ventricular ejection fraction after myocardial infarction. *Int J Clin Chem*. 2016;452:50–57. doi:10.1016/j.cca.2015.10.034
54. Chen J, Xiao P, Song D, Chen Z, Li H. Growth stimulation expressed gene 2 (ST2): clinical research and application in the cardiovascular related diseases. *Front cardiovasc med*. 2022;9:1007450. doi:10.3389/fcvm.2022.1007450
55. Yancy CW, Jessup M, Bozkurt B, et al. 2017 ACC/AHA/HFSA focused update of the 2013 ACCF/AHA guideline for the management of heart failure: a report of the American College of Cardiology/American Heart Association Task Force on Clinical Practice Guidelines and the Heart Failure Society of America. *Circulation*. 2017;136(6):e137–e161. doi:10.1161/cir.0000000000000509
56. Targoff IN, Johnson AE, Miller FW. Antibody to signal recognition particle in polymyositis. *Arthritis Rheum*. 1990;33(9):1361–1370. doi:10.1002/art.1780330908
57. Hengstman GJ, Ter Laak HJ, Vree Egberts WT, et al. Anti-signal recognition particle autoantibodies: marker of a necrotising myopathy. *Ann Rheumatic Dis*. 2006;65(12):1635–1638. doi:10.1136/ard.2006.052191
58. Albayda J, Khan A, Casciola-Rosen L, Corse AM, Paik JJ, Christopher-Stine L. Inflammatory myopathy associated with anti-mitochondrial antibodies: a distinct phenotype with cardiac involvement. *Semin Arthritis Rheum*. 2018;47(4):552–556. doi:10.1016/j.semarthrit.2017.06.004
59. Zhang L, Yang H, Lei J, et al. Muscle pathological features and extra-muscle involvement in idiopathic inflammatory myopathies with anti-mitochondrial antibody. *Semin Arthritis Rheum*. 2021;51(4):741–748. doi:10.1016/j.semarthrit.2021.05.019
60. Danielli MG, Gelardi C, Guerra F, Cardinaletti P, Pedini V, Gabrielli A. Cardiac involvement in polymyositis and dermatomyositis. *Autoimmunity Rev*. 2016;15(5):462–465. doi:10.1016/j.autrev.2016.01.015
61. Devezza LM, Miossi R, de Souza FH, et al. Electrocardiographic changes in dermatomyositis and polymyositis. *Revista brasileira de reumatologia*. 2016;56(2):95–100. doi:10.1016/j.rbre.2014.08.012
62. Zhong Y, Bai W, Xie Q, Sun J, Tang H, Rao L. Cardiac function in patients with polymyositis or dermatomyositis: a three-dimensional speckle-tracking echocardiography study. *Int J Cardiovasc Imaging*. 2018;34(5):683–693. doi:10.1007/s10554-017-1278-9
63. Diederichsen LP, Simonsen JA, Diederichsen AC, et al. Cardiac abnormalities in adult patients with polymyositis or dermatomyositis as assessed by noninvasive modalities. *Arthritis Care Res*. 2016;68(7):1012–1020. doi:10.1002/acr.22772
64. Guerra F, Gelardi C, Capucci A, Gabrielli A, Danielli MG. Subclinical cardiac dysfunction in polymyositis and dermatomyositis: a speckle-tracking case-control study. *J Rheumatol*. 2017;44(6):815–821. doi:10.3899/jrheum.161311
65. Shah M, Shinjo SK, Day J, Gupta L. Cardiovascular manifestations in idiopathic inflammatory myopathies. *Clin Rheumatol*. 2023;42(10):2557–2575. doi:10.1007/s10067-023-06599-4
66. Khoo T, Stokes MB, Teo K, et al. Cardiac involvement in idiopathic inflammatory myopathies detected by cardiac magnetic resonance imaging. *Clin Rheumatol*. 2019;38(12):3471–3476. doi:10.1007/s10067-019-04678-z
67. Huang L, Tao Q, Zhao P, et al. Using multi-parametric quantitative MRI to screen for cardiac involvement in patients with idiopathic inflammatory myopathy. *Sci Rep*. 2022;12(1):9819. doi:10.1038/s41598-022-13858-y
68. Xu Y, Sun J, Wan K, et al. Multiparametric cardiovascular magnetic resonance characteristics and dynamic changes in myocardial and skeletal muscles in idiopathic inflammatory cardiomyopathy. *J Cardiovasc Magn Reson*. 2020;22(1):22. doi:10.1186/s12968-020-00616-0
69. Mavrogeni S, Bratis K, Karabela G, Stavropoulos E, Sfendouraki E, Kolovou G. Myocarditis during acute inflammatory myopathies: evaluation using clinical criteria and cardiac magnetic resonance imaging. *Int J Cardiol*. 2013;164(1):e3–4. doi:10.1016/j.ijcard.2012.09.109
70. Allanore Y, Vignaux O, Arnaud L, et al. Effects of corticosteroids and immunosuppressors on idiopathic inflammatory myopathy related myocarditis evaluated by magnetic resonance imaging. *Ann Rheumatic Dis*. 2006;65(2):249–252. doi:10.1136/ard.2005.038679
71. Bandeira M, Dourado E, Melo AT, et al. Predictors of cardiac involvement in idiopathic inflammatory myopathies. *Front Immunol*. 2023;14:1146817. doi:10.3389/fimmu.2023.1146817
72. Wu J, Lu AD, Zhang LP, Zuo YX, Jia YP. Study of clinical outcome and prognosis in pediatric core binding factor-acute myeloid leukemia. *Zhonghua xue ye xue za zhi = Zhonghua xueyexue zazhi*. 2019;40(1):52–57. doi:10.3760/cma.j.issn.0253-2727.2019.01.010
73. Mammen AL, Chung T, Christopher-Stine L, et al. Autoantibodies against 3-hydroxy-3-methylglutaryl-coenzyme A reductase in patients with statin-associated autoimmune myopathy. *Arthritis Rheum*. 2011;63(3):713–721. doi:10.1002/art.30156
74. Oddis CV, Reed AM, Aggarwal R, et al. Rituximab in the treatment of refractory adult and juvenile dermatomyositis and adult polymyositis: a randomized, placebo-phase trial. *Arthritis Rheum*. 2013;65(2):314–324. doi:10.1002/art.37754
75. Anh-Tu Hoa S, Hudson M. Critical review of the role of intravenous immunoglobulins in idiopathic inflammatory myopathies. *Semin Arthritis Rheum*. 2017;46(4):488–508. doi:10.1016/j.semarthrit.2016.07.014
76. Miyasaka N, Hara M, Koike T, Saito E, Yamada M, Tanaka Y. Effects of intravenous immunoglobulin therapy in Japanese patients with polymyositis and dermatomyositis resistant to corticosteroids: a randomized double-blind placebo-controlled trial. *Mod Rheumatol*. 2012;22(3):382–393. doi:10.1007/s10165-011-0534-4

Journal of Inflammation Research**Dovepress**

Taylor & Francis Group

Publish your work in this journal

The Journal of Inflammation Research is an international, peer-reviewed open-access journal that welcomes laboratory and clinical findings on the molecular basis, cell biology and pharmacology of inflammation including original research, reviews, symposium reports, hypothesis formation and commentaries on: acute/chronic inflammation; mediators of inflammation; cellular processes; molecular mechanisms; pharmacology and novel anti-inflammatory drugs; clinical conditions involving inflammation. The manuscript management system is completely online and includes a very quick and fair peer-review system. Visit <http://www.dovepress.com/testimonials.php> to read real quotes from published authors.

Submit your manuscript here: <https://www.dovepress.com/journal-of-inflammation-research-journal>