


Dupilumab for Chronic Rhinosinusitis with Primary Nasal Polyps: a Case Report and Literature Review

Mingrui Deng , Rao Fu, Mei Lv, Ya Feng

Department of Otorhinolaryngology Head and Neck Surgery, The First Affiliated Hospital of Dalian Medical University, Dalian, Liaoning, People's Republic of China

Correspondence: Mei Lv; Ya Feng, Department of Otorhinolaryngology Head and Neck Surgery, The First Affiliated Hospital of Dalian Medical University, Dalian, 116011, People's Republic of China, Email Lv_mei@163.com; fengyal102@sina.com

Purpose: To report the efficacy of a case of IL-4 receptor subunit (IL-4R α) monoclonal antibody (dupilumab) in treating primary chronic rhinosinusitis with nasal polyps (CRSwNP) refractory repeated short-term oral corticosteroids.

Patients and Methods: The clinical efficacy, subjective and objective scores, and adverse events before and after dupilumab treatment were evaluated to determine the effect of dupilumab on CRSwNP.

Results: The patient's Lund-Mackay score on sinus Computed Tomography (CT) at the first visit was 21. After being treated with intranasal corticosteroids, oral corticosteroids, mucoregulatory agents, and nasal isotonic saline irrigation for 3 months, the symptoms did not improve significantly. The CT score was 20. The patient explicitly refused functional endoscopic sinus surgery (FESS) and was treated with dupilumab. During treatment, the patient did not experience dupilumab-related adverse reactions, and the patient's sinusitis symptoms were completely controlled. In particular, before dupilumab treatment, the patient lost their sense of smell, with a SNOT-25 score of 65; after the first dose of dupilumab, their sense of smell significantly improved. During the 6-month follow-up, the patient consciously recovered their sense of smell, with a SNOT-25 score of 3. After re-examining the sinus CT image, the Lund-Mackay score was 2.

Conclusion: By specifically inhibiting the IL-4 and IL-13 pathways, dupilumab can significantly improve sinusitis symptoms and olfactory function in CRSwNP patients, and significantly reduce the number of acute exacerbations of chronic rhinosinusitis, the range of sinusitis lesions, and the level of systemic corticosteroids.

Keywords: chronic rhinosinusitis with nasal polyps, dupilumab, biological agent, type II inflammation, IL-4R α

Introduction

Chronic rhinosinusitis (CRS) is a complex, chronic inflammatory disease of the sinonasal mucosa that mainly involves the sinuses and nasal mucosa; CRS lasts for 12 weeks or longer and affects 5–12% of the total global population.¹ CRS can be divided into two clinical subtypes: chronic rhinosinusitis without nasal polyps (CRSSNP) and chronic rhinosinusitis with nasal polyps (CRSwNP).² According to the extent of eosinophils, CRSwNP can be divided into two subtypes: eosinophilic chronic rhinosinusitis with nasal polyps (ECRSwNP) and non-eosinophilic chronic rhinosinusitis with nasal polyps (non-ECRSwNP). The severity of ECRSwNP inflammation is much higher than that of non-granulocytophils. According to existing studies, 60–80% of chronic sinusitis is eosinophilic type, and the degree of eosinophil infiltration is positively correlated with the level of mucosal inflammation. At present, the combination of nasal glucocorticoid use and nasal endoscopic surgery is mostly used as the first-line treatment method for ECRSwNP. But clinical follow-up found that 60% of ECRSwNP patients in standard drugs and surgical treatment after 18 months relapse, two years recurrence rate of 98.5%, 37% of patients even need repeated surgery, seriously affected the quality of life, to individual and society caused heavy economic and medical burden, and long-term use of glucocorticoid drugs can also produce certain side effects. The mechanism of chronic sinusitis is complex, and its different intrinsic classification also have highly heterogeneous immunopathological characteristics. ECRSwNP is mainly type 2 inflammation mediated by type 2 immune factors, and in the type inflammatory pathway causing ECRSwNP, IL-4 is one of the most direct factors that

produce eosinophils. The rapid development of biologic agents has yielded agents that exert therapeutic effects by combining key factors in specific pathways. Dupilumab binds to IL-4R α to affect the signalling of IL-4 and IL-13, key anti-inflammatory factors, to treat CRSwNP.³ At present, there are few relevant reports on the use of dupilumab to treat CRSwNP. This paper reports the clinical data related to the use of dupilumab, preliminarily summarizing the efficacy of dupilumab for treating primary CRSwNP refractory repeated short-term oral corticosteroids and progress in the use of dupilumab for treating chronic sinusitis with nasal polyps.

Case Report

General Information

Clinical data of a patient with CRSwNP who was treated with dupilumab at the First Affiliated Hospital of Dalian Medical University from August 2023 to August 2024 were collected. The patient was a 44-year-old female with a history of allergic rhinitis. There was no prior history of asthma, hypertension, diabetes, or associated immune diseases. The clinical manifestations were persistent nasal congestion, head and facial pain, purulent discharge, reflux, and loss of smell.

Treatment Methods

The initial sinus CT revealed sinusitis, and the patient was treated with “INCS, mucoregulatory agent, and nasal isotonic saline irrigation” along with 30 mg/d oral corticosteroids (OCSs) due to repeated aggravation of CRS symptoms. After 3 months of regular treatment, the curative effect was not significant and gradually increased. A follow-up sinus CT showed no significant improvement. The patient strongly refused to undergo ESS treatment. Dupilumab was administered, and INCS and isotonic saline nasal irrigation were continued during treatment. The initial dose of dupilumab used for CRSwNP is 600 mg, followed by 300 mg every 2 weeks for 3 months, which is changed to 300 mg every 3 weeks for maintenance. Our work has been reported in line with the SCARE 2020 criteria⁴ and has been approved by the ethics committee. Informed written consent was obtained from the patient for publication of this report and any accompanying images.

Observing Indicators

The symptoms were observed and recorded. The evaluation questionnaire that was used was the Sino-Nasal Outcome Test-25 (SNOT-25), which is used to evaluate the quality of life before and after treatment; the lower the SNOT-25 score, the greater the patient's quality of life. The Lund-Mackay score scores sinus CTs; a lower score indicates a smaller range of sinus lesions. The peripheral blood eosinophil Count (10^3 / mL) was used as an observed indicator of type 2 inflammation in this patient.

Efficacy Evaluation

According to the efficacy evaluation method outlined in the 2020 European Sinusitis and Nasal Polyps opinion,² treatment outcomes are categorized into complete, partial, and no control groups. The clinical reference evaluation indices that were used were nasal congestion, retronasal drip, facial pain or compression, olfactory loss, sleep disturbance, abnormal nasal endoscopy, and the need for rescue treatment. Partial control of the condition was defined as any 1 of the above items being present, an uncontrolled condition was defined as 3 or more symptoms being present, and complete control of the condition was defined as no symptoms being present.

Results

The Lund–Mackay score of the sinus CT scan at the initial visit was 21. After conventional treatment for 3 months, there was no obvious effect. The CT score was 20, and the SNOT-25 score was 65. During the use of dupilumab, the patient experienced no acute exacerbation of chronic rhinosinusitis, no adverse symptoms related to dupilumab, the sinusitis symptoms were completely controlled, and the subjective score of smell significantly improved, particularly after the first dose of dupilumab. During the 6-month follow-up, the patient consciously recovered their sense of smell, with a SNOT-25 score of 3 and a Lund–Mackay score of 2. Image changes in the sinus CT are shown in [Figure 1](#). The peripheral blood eosinophil Count decreased from 0.87×10^3 /mL to 0.28×10^3 /mL.

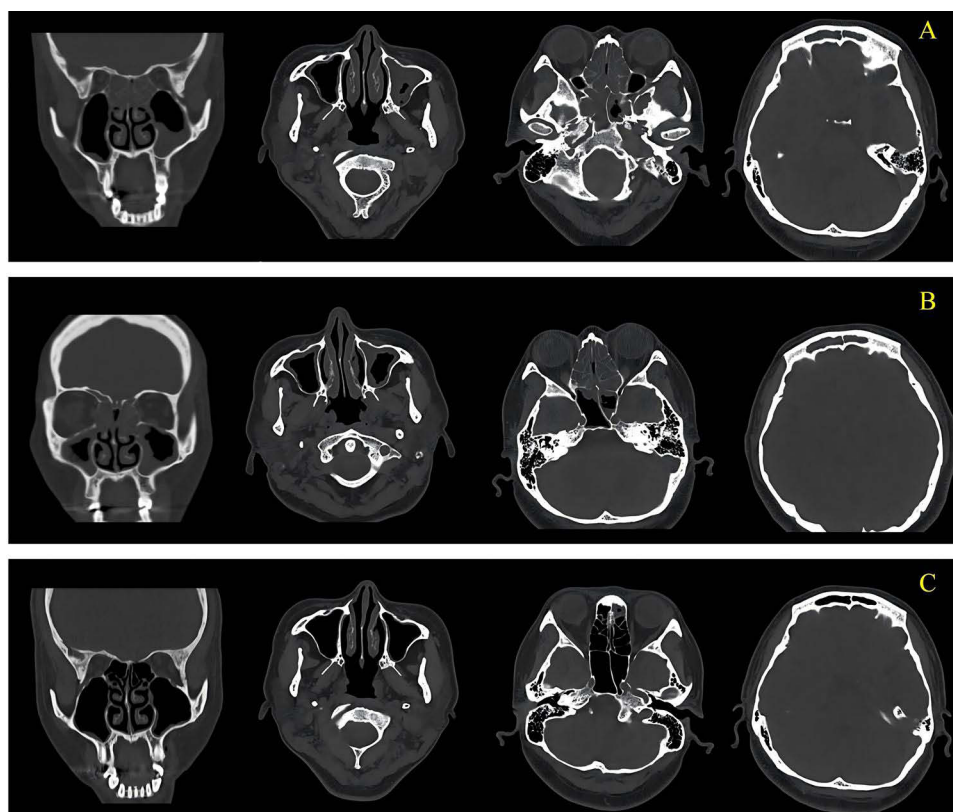


Figure 1 Imaging data of the case. CT before conventional medication (**A**), three months after conventional medication (**B**), and six months after dupilumab (**C**).

Discussion

CRS is a disease that severely affects quality of life, with an overall prevalence in the Chinese population of 8%.⁵ Current treatment options include INCS as the standard of care and sinus surgery when INCS alone is ineffective. For patients with CRSwNP and severe recurrent nasal polyps, short-term OCS treatment can be performed to quickly reduce nasal polyp volume, but its clinical efficacy is difficult to maintain.^{6,7} In addition, OCS treatment may lead to serious adverse reactions, and even short-term use of corticosteroids can increase the risk of acute complications, such as venous thromboembolism and fractures.^{8,9} ESS is the preferred surgical treatment, but the recurrence rate of nasal polyps from 18 months to 4 years is 20–60% and 79% at 12 years.^{10,11}

The pathogenesis of CRS is complex, and studies suggest that Th cells play an important role, especially since Th2-type CRSwNP symptoms tend to be more severe.^{12,13} Type II inflammation plays an important role in the development of CRSwNP. However, IL-4 and IL-13 are the key factors involved in inflammatory signalling pathways. The human IL-4 and IL-13 genes are adjacent to chromosome 5, with common cis- and trans-acting elements sharing receptor subunits and signalling molecules; these two cytokines initiate similar and specific biological responses.¹⁴ IL-4 can induce the differentiation of naive T cells into Th2 cells and Tc2 cells; IL-4 binds to the IL-4R α receptor, initiating GATA 3 transcription after phosphorylation of STAT 6. GATA 3 is the major transcription factor¹⁵ that determines the Th2 cell lineage and promotes the expression of Th2-specific cytokines.

Furthermore, B cells have a high density of IL-4R α receptors on their surface, and the binding of IL-4 to IL-4R α can induce the secretion of IgE by B cells, leading to inflammation development.¹⁶ In addition, IL-4 also acts by inducing the expression of intercellular cell adhesion molecule-1 (ICAM-1) and vascular cell adhesion molecule-1 (VCAM-1). Eosinophil tissue exudation plays a key role in promoting the inflammatory state of acidophilic tissue.⁴ Similar to IL-4, IL-13 also promotes the secretion of IgE by B cells.¹⁶ In addition, IL-13 regulates acidophil activity⁴ through the

induction of IL-5 and eotaxin-3 synthesis. Moreover, IL-4 and IL-13 promote the formation of nasal polyps in CRSwNP by inducing M2 macrophage activation and inhibiting fibrin degradation of IL-13.¹⁷

Dupilumab is a fully humanized monoclonal antibody that targets important cytokines in the same IL-4R α subunit, inhibits IL-4 and IL-13 signalling to regulate the inflammatory response and reduce⁴ multiple biomarkers of type 2 inflammation in nasal secretions and polyp tissue of CRSwNP patients. Jonstam et al¹⁸ studied the effects of dupilumab on intermediate-type inflammatory biomarkers of nasal secretions and nasal polyp tissue in patients with CRSwNP. The results showed that dupilumab treatment reduced the levels of biomarkers, including cationic protein, eotaxin-2, eotaxin-3, lung activation-regulated chemokines, IgE, and IL-13, in nasal polyp tissue. Moreover, Suggow suggested that dupilumab reduces the organismal-type inflammatory response by inhibiting the signalling of IL-4 and IL-13. In terms of safety, the results of the SINUS-24 and SINUS-52 trials revealed that the incidence of adverse events in the dupirizumab group was lower than that in the placebo group, and the tolerance and safety were good.^{19–21} Dupirizumab is also the first biological agent approved for treating CRSwNP and is recommended by the US guidelines and EP0S2020.^{2,22}

In the pathogenesis, IL-5 is also an important factor in regulating eosinophil value-added differentiation, activation, chemotaxis, and prolonged survival time. This pathway activates ILC 2 and activates TH 2 responses through its intrinsic lymphocytes 2s, enabling ILC 2 and TH 2 to release IL-4, IL-5, and IL-13. IL-5 as a chemokine, can promote the expression of nasal mucosa adhesion molecule (ICAM), enhance the adhesion of EOS and vascular endothelium, eosinophil selective migration from peripheral blood into tissue, and is highly specific to regulate eosinophil chemotaxis (Eotaxin), further strengthen EOS and vascular endothelium adhesion, form positive feedback. Bio-targeted drugs against anti-IL-5 antibody block IL-5 by binding to IL-5 and specific IL-5 receptor on eosinophils, which plays a competitive inhibition of IL-5, inhibiting its participation in JAK / STAT, Btk and Ras / Raf-ERK signaling transduction, so as to weaken the activation and recruitment of IL-5 to eosinophils in the inflammatory pathway, reduce the EOS level in tissues and peripheral blood, and control eosinophil inflammation. Mepolizumab is a high-affinity, humanized anti-IL-5 monoclonal antibody. Another anti-IL-5R α antibody can bind to specific IL-5R on EOS and basophils to block IL-5, while the other end of the antibody binds to NK cells to mediate the ADCC effect and kill EOS and basophils to apoptosis.

In 2022, Zhang et al compared various biological agents in NPS and nasal congestion, SNOT-22 and anosmia, and showed that dupilumab was the most effective and safe treatment route for CRSwNP compared with omalizumab, mepolizumab and benralizumab at 24 weeks of treatment and the end of follow-up.²³ However, one of the key and difficulties in the clinical use of biological agents still includes the selection of biological agents, and the study of this part is not sufficient.

In this study, the patient repeated short-term underwent INCS and OCS before treatment with dupilumab and showed no significant improvement in CRS symptoms at the therapeutic OCS dosage of 30 mg/d. After the use of dupilumab, the patient's quality of life and olfactory function significantly improved, and the sinus CT, SNOT-25, and Lund–Mackay scores confirmed that the range of sinusitis lesions and sinus mucosal oedema were significantly reduced compared with those before treatment. SINUS-24 and SINUS-52 have reported adverse effects, including nasopharyngitis, headache, epistaxis, injection site reactions, aggravated nasal polyps, and asthma, in a small number of patients with acidophilia and eosinophilic Wegener granulomas.¹⁹ Although the adverse effects associated with eosinophilia after dupilumab treatment were not temporarily observed in this patient, close observation of changes in eosinophils in the peripheral blood after treatment was still recommended.

Conclusion

For CRSwNP patients without INCS and short-term OCS or those who experience recurrence after ESS surgery, biological agents can be selected to alleviate their clinical symptoms. Among these agents, dupilumab can significantly improve the symptoms of sinusitis and olfactory function in CRSwNP patients, reduce the range of lesions, and result in few adverse reactions. However, the long-term efficacy and adverse effects of this drug during treatment of CRSwNP need further clarification in randomized controlled trials and long-term follow-up.

Ethical Approval

Ethical approval to report this case was obtained from *The First Affiliated Hospital of Dalian Medical University (approval number PJ-KS-BD-2024-16)*.

The patient included in the study have signed informed consent, and the treatment methods and testing methods adopted in this study are known safe methods in clinical practice; the general information and clinical data are only used for study analysis, not for other purposes. Informed written consent was obtained from the patient for publication of this report and any accompanying images.

Funding

There is no funding to report.

Disclosure

The authors report no conflicts of interest in this work.

References

1. Dietz de Loos D, Lourijsen ES, Wildeman MAM, et al. Prevalence of chronic rhinosinusitis in the general population based on sinus radiology and symptomatology. *J Allergy Clin Immunol*. 2018;143(3):1207–1214. doi:10.1016/j.jaci.2018.12.986
2. Fokkens WJ, Lund VJ, Hopkins C, et al. European position paper on rhinosinusitis and nasal polyps 2020. *Rhinology*. 2020;58(Suppl S29):1–464. doi:10.4193/Rhin20.600
3. Bachert C, Pawankar R, Zhang L, et al. ICON: chronic rhinosinusitis. *World Allergy Organ J*. 2014;7(1):25. doi:10.1186/1939-4551-7-25
4. Agha RA, Franchi T, Sohrabi C, et al. The scare 2020 guideline: updating consensus surgical case report (scare) guidelines. *Int J Surg*. 2020;84:226–230. doi:10.1016/j.ijsu.2020.10.034
5. Shi JB, Fu QL, Zhang H, et al. Epidemiology of chronic rhinosinusitis: results from a cross-sectional survey in seven Chinese cities. *Allergy*. 2015;70(5):533–539. doi:10.1111/all.12577
6. Pauwels B, Jonstam K, Bachea C. Emerging biologics for the treatment of chronic rhinosinusitis. *Expert Rev Clin Immunol*. 2015;11(3):349–361. doi:10.1586/1744666X.2015.1010517
7. Hissaria P, Smith W, Wormald PJ, et al. Short course of systemic corticosteroids in sinonasal polyposis: a double-blind, randomized, placebo-controlled trial with evaluation of outcome measures. *J Allergy Clin Immunol*. 2006;118(1):128–133. doi:10.1016/j.jaci.2006.03.012
8. Hox V, Lourijsen E, Jordens A, et al. Benefits and harm of systemic steroids for short-and long-term use in rhinitis and rhinosinusitis: all EAACI position paper. *Clin Transl Allergy*. 2020;10:1. doi:10.1186/s13601-019-0303-6
9. Waljee AK, Rogers MA, Lin P, et al. Short term use of oral corticosteroids and related harms among adults in the United States: population based cohort study. *BMJ*. 2017;357:j1415. doi:10.1136/bmj.j1415
10. Bhattacharyya N, Villeneuve S, Joish VN, et al. Cost burden and resource utilization in patients with chronic rhinosinusitis and nasal polyps. *Laryngoscope*. 2019;129(9):1969–1975. doi:10.1002/lary.27852
11. Caius L, Van Bmaene N, Bosteels C, et al. Twelve-year follow study after endoscopic sinus surgery in patients with chronic rhinosinusitis with nasal polyposis. *Clin Transl Allergy*. 2019;9. doi:10.1186/s13601-019-0247-x
12. Wang X, Zhang N, Bo M, et al. Diversity of TH cytokine profiles in patients with chronic rhinosinusitis: a multistudy in Europe, Asia, and Oceania. *J Allergy Clin Immunol*. 2016;138:1344–1353. doi:10.1016/j.jaci.2016.05.041
13. Kim DW, Cho SH. Emerging endotypes of chronic rhinosinusitis and its application to precision medicine. *Allergy Asthma Immun Res*. 2017;9. doi:10.4168/aair.2017.9.4.299
14. McCormick SM, Heller NM. Commentary: IL-4 and IL-13 receptors and. *Cytokine*. 2015;75:38–50. doi:10.1016/j.cyt.2015.05.023
15. Ouyang W, Löhning M, Gao Z, et al. Stat6-independent GATA-3 autoactivation directs IL-4-independent Th2 development and commitment. *Immunity*. 2000;12(1):27–37. doi:10.1016/s1074-7613(00)80156-9
16. Annunziato F, Romagnani C, Romagnani S. The 3 major types of innate and adaptive cell-mediated effector immunity. *J Allergy Clin Immunol*. 2014;135(3):626–635. doi:10.1016/j.jaci.2014.11.001
17. Demarre T, Holtappels G, De Ruyck N, et al. Type 2 inflammation in chronic rhinosinusitis without nasal polyps: another relevant endotype. *J Allergy Clin Immunol*. 2020;146(2):337–343. doi:10.1016/j.jaci.2020.04.040
18. Jonstam K, Swanson BN, Mannent LP, et al. dupilumab reduces local type 2 pro-inflammatory biomarkers in chronic rhinosinusitis with nasal polyposis. *Allergy*. 2019;74(4):743–752. doi:10.1111/all.13685
19. Bachert C, Han JK, Desrosiers M, et al. Efficacy and safety of dupilumab in patients with severe chronic rhinosinusitis with nasal polyps (LIBERTY NP SINUS-24 and HBERTY NP SINUS-52): results from two multicentre, randomised, double-blind, placebo. Controlled, parallel-group Phase 3 trials. *Lancet*. 2019;394(10209):1638–1650. doi:10.1016/S0140-6736(19)31881-1
20. Bachert C, Hellings PW, Mullol J, et al. dupilumab improves patient-reported outcomes in patients with chronic rhinosinusitis with nasal polyps and comorbid asthma. *J Allergy Clin Immunol Pract*. 2019;7(7):2447–2449. doi:10.1016/j.jaip.2019.03.023
21. Bachert C, Marment L, Naclerio RM, et al. Effect of subcutaneous dupilumab on nasal polyp burden in patients with chronic sinusitis and nasal polyposis: a randomized clinical trial. *JAMA*. 2016;315(5):469–479. doi:10.1001/jama.2015.19330
22. Anonymous. Adult chronic rhinosinusitis. *Nat Rev Dis Primers*. 2020;6(1):87. doi:10.1038/s41572-020-00229-y
23. Shen S, Yan B, Wang M, Wu D, Wang C, Zhang L. Anti-IL-4Rα monoclonal antibody (CM310) in patients with chronic rhinosinusitis with nasal polyps (CROWNS-2): rationale and design of a multicentre, randomized, double-blind, placebo-controlled, parallel-group study. *Asia Pac Allergy*. 2024;14(3):118–123. doi:10.5415/apallergy.0000000000000156

Journal of Inflammation Research**Publish your work in this journal**

The Journal of Inflammation Research is an international, peer-reviewed open-access journal that welcomes laboratory and clinical findings on the molecular basis, cell biology and pharmacology of inflammation including original research, reviews, symposium reports, hypothesis formation and commentaries on: acute/chronic inflammation; mediators of inflammation; cellular processes; molecular mechanisms; pharmacology and novel anti-inflammatory drugs; clinical conditions involving inflammation. The manuscript management system is completely online and includes a very quick and fair peer-review system. Visit <http://www.dovepress.com/testimonials.php> to read real quotes from published authors.

Submit your manuscript here: <https://www.dovepress.com/journal-of-inflammation-research-journal>

Dovepress
Taylor & Francis Group