


# Ocular Hypertension Following Open Globe Injury in Patients Undergoing Pars Plana Vitrectomy

Sam Karimaghaei , Hytham Al-Hindi, Muhammad Z Chauhan, Abdelrahman M Elhusseiny, Carina T Sanvicente, Sami H Uwaydat

Harvey and Bernice Jones Eye Institute, Department of Ophthalmology, University of Arkansas for Medical Sciences, Little Rock, AR, USA

Correspondence: Sami H Uwaydat, Department of Ophthalmology, Jones Eye Institute, University of Arkansas for Medical Sciences, 4301 W Markham Street # 523, Little Rock, AR, 72205, USA, Email SHUwaydat@uams.edu

**Purpose:** To identify risk factors and rates of post-traumatic ocular hypertension (OHT) in patients undergoing pars plana vitrectomy (PPV) for open-globe injuries.

**Patients and Methods:** Retrospective chart study including 98 eyes from 98 patients between 2008 and 2022 with open globe injuries who were hospitalized at a single academic institution and received first repair or exploration followed by PPV. Variables recorded included timing to the first PPV, best-corrected final visual acuity (VA) at the last follow-up, incidence of enucleation, type of injury, use of intravitreal antibiotics, number of eye surgeries, use of oral steroids, acetazolamide use, topical steroid use, lens status, silicone oil placement, and zone of injury (1–3). The ocular trauma score (OTS) was calculated using the variables globe rupture, development of endophthalmitis, initial VA, globe perforation, retinal detachment, and the presence of a relative afferent pupillary defect (RAPD). The primary endpoint was elevated intraocular pressure (IOP) sustained for more than six weeks following PPV. We performed a logistic regression to determine the factors that predicted the development of OHT post-PPV.

**Results:** Of 98 eyes included in the primary analysis, a total of 34 (34.69%) were diagnosed with sustained ocular hypertension (OHT) and 64 (65.31%) remained normotensive. The mean final IOP in the OHT group was 16.96 mmHg and 12.11 mmHg in the normotensive group ( $P < 0.01$ ). Sex, age, OTS, injury type, zone of injury, preoperative IOP, and final VA were comparable between the OHT and normotensive groups. When adjusting for OTS, the use of silicone oil significantly predicted the development of ocular hypertension (odds ratio [95% CI], 5.63 [1.57–20.11]).

**Conclusion:** The incidence of ocular hypertension in our cohort was slightly higher than previously reported at 34.69%. PPV has been independently associated with elevated IOP post-operatively, but the need for PPV surgery can indicate more severe trauma leading to higher rates of increased IOP. Patients who had silicone oil utilized in their PPV had an approximately 5.63-fold increased odds of developing OHT, suggesting that silicone oil use may be a potent predictor of post-PPV OHT.

**Keywords:** ocular hypertension, glaucoma, globe injury, vitrectomy, intraocular pressure

## Introduction

Glaucoma is a multifactorial family of progressive optic neuropathies associated with damage to retinal ganglion cells that can lead to irreversible blindness.<sup>1</sup> It is a leading cause of ocular morbidity in the world, being the second most common cause of blindness in adults aged 50 years or older.<sup>2</sup> In the United States, the prevalence of glaucoma in those over 40 years of age between the years 2005–2008 was estimated to be 2.1%, with 2.9 million individuals affected.<sup>3</sup>

The main risk factor for glaucoma is OHT. Glaucoma can be primary or secondary. Common causes of secondary glaucoma include trauma, aphakia, pars-plana vitrectomy (PPV)-associated, and neovascular glaucoma. The prevalence of these different causes varies by population and age group. For example, trauma was shown to be the most common etiology for secondary glaucoma among individuals younger than 20 years, while vitrectomy-induced glaucoma is an important cause in older patients.<sup>4</sup>

Post-traumatic glaucoma can be particularly problematic due to the possibility of glaucoma being unnoticed until irreversible optic nerve damage occurs.<sup>5,6</sup> The incidence of glaucoma has been estimated to be 3.39% six months following blunt ocular trauma, with varying factors being associated with an increased risk, including older age, iris injury, lens injury, hyphema, and angle recession.<sup>7</sup> The incidence of glaucoma goes up to 10% ten years following injury.<sup>8</sup> One important factor with regard to ocular injury is whether the injury involves open or closed-globe trauma.<sup>9</sup> Often, open globe injuries require multiple surgical interventions following the primary repair,<sup>8</sup> which could also impact IOP and visual outcomes in these eyes.

In the present report, we aimed to identify risk factors and rates of post-traumatic ocular hypertension in patients undergoing PPV for open-globe injuries.

## Methods

The Institutional Review Board of the University of Arkansas for the Medical Sciences (UAMS) authorized the study protocol, which was conducted in accordance with the Declaration of Helsinki. A retrospective chart review was conducted on 116 patients with open globe injuries who were hospitalized at UAMS between 2008 and 2022, and who underwent primary globe repair or exploration followed by PPV. All PPVs were performed by a single surgeon (S.H.U), while the primary wound closure and globe exploration were performed by multiple surgeons. Prior to analysis, all data were anonymized and de-identified. We excluded patients with less than 6 weeks of postoperative follow-up and patients without recorded initial visual acuity (VA). After exclusion criteria were applied, 98 patients were included in the primary analysis. 5000-centistoke silicone oil was used for all eyes that required silicone oil tamponade, and all patients were tapered off topical steroids 4 weeks post-PPV.

The indications for PPV were intraocular foreign bodies (IOFB), lens capsule rupture, dense vitreous hemorrhage, retinal detachment, and/or endophthalmitis. The 23-gauge Constellation system (Alcon Laboratories Inc, USA) was used to perform all vitrectomies. The primary endpoint was OHT sustained for more than six weeks following PPV. Patients were reported to have a diagnosis of sustained OHT based on having either of the following 3 variables post-PPV: (1) highest intra-ocular pressure (IOP) greater than 22 mmHg post-PPV on at least two consecutive visits, (2) use of  $\geq 1$  glaucoma drops, or (3) the need for glaucoma surgery. Variables recorded included timing to the first PPV from the initial injury, best-corrected final VA at the last follow-up (interval-based VA was not recorded), the type of injury (blunt force, IOFB, sharp injury, and injury from a high-velocity projectile), use of intravitreal antibiotics, number of ocular surgeries, use of oral steroids, acetazolamide use, topical steroid use, lens status, silicone oil placement, and zone of injury (1–3). The ocular trauma score (OTS) was calculated using the variables globe rupture, development of endophthalmitis, initial VA, globe perforation, retinal detachment, and the presence of a relative afferent pupillary defect (RAPD). The OTS measures the severity of ocular trauma on a scale from 1 to 5, with 1 being the most severe and 5 being the least severe.

## Statistical Analyses

Statistical analysis was conducted using STATA 14.2 (*StataCorp LP*, College Station, TX). Chi-square and the Wilcoxon rank-sum test were used to compare categorical and continuous data, respectively. Our primary analysis included performing a logistic regression to determine the factors that predicted the development of ocular hypertension post-PPV. Covariables in the model included age, sex, PPV timing, ocular trauma score, lens rupture, type of injury, number of surgeries, use of silicone oil, zone of injury (1–3), and presence of hyphema. A *P*-value of  $<0.05$  was considered significant in all cases.

## Results

A total of 116 eyes from 116 patients who underwent PPV following ocular trauma were followed for an average of 768 days. Of these patients, those with less than 6 weeks of follow-up were excluded, leaving 98 patients for the primary analysis. A total of 34 patients (34.69%) were diagnosed with sustained ocular hypertension. Fourteen of the 34 patients with sustained ocular hypertension (41.18%) had silicone oil at the time of diagnosis. There was no evidence of silicone oil emulsification in any silicone oil-filled eyes. Proliferative vitreoretinopathy developed in 21.5% of eyes. The demographic characteristics and preoperative data of patients with and without OHT are summarized in Table 1. Of the 34 patients with OHT, 28 (82.35%) were males, while there were 64 patients without OHT, of whom 51 (79.69%) were males ( $P=0.751$ ). The mean (standard deviation (SD)) age for OHT patients was 46.08 (19.71) years and 44.15

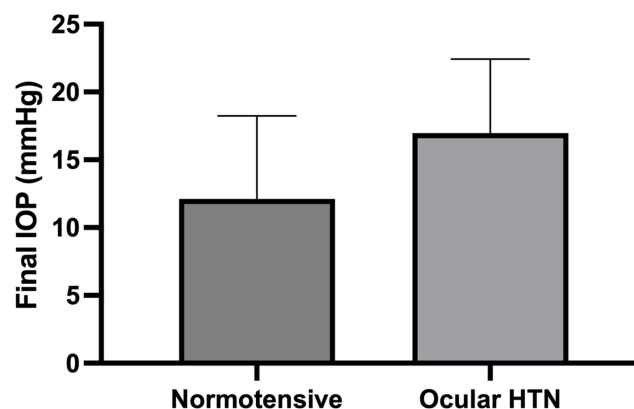
**Table 1** Patient Presenting Characteristics

Characteristic	Overall, N=98	Hypertensive (HTN) Status		P-value*
		Normotensive, n=64	Ocular HTN, n=34	
<b>Sex, N (%)</b>				0.751
Male	79 (80.61)	51 (79.69)	28 (82.35)	
Female	19 (19.39)	13 (20.31)	6 (17.65)	
<b>Age, Mean (SD)</b>	44.82 (18.77)	44.15 (18.36)	46.08 (19.71)	0.511
<b>OTS, Mean (SD)<sup>a</sup></b>	2.09 (0.86)	2.09 (0.92)	2.12 (0.71)	0.690
<b>Injury type, No. (%)</b>				0.505
Blunt	57 (58.16)	39 (60.94)	18 (52.94)	
Sharp	24 (24.49)	15 (23.44)	9 (26.47)	
IOFB	15 (15.31)	8 (12.50)	7 (20.59)	
Projectile	2 (2.04)	2 (3.12)	0 (0)	
<b>Zone 1 Injury, N (%)</b>	43 (44.33)	29 (45.31)	14 (41.18)	0.695
<b>Zone 2 Injury, N (%)</b>	48 (48.98)	32 (50.00)	16 (47.06)	0.782
<b>Zone 3 Injury, N (%)</b>	41 (41.84)	30 (46.88)	11 (32.35)	0.165
<b>Lens rupture, N (%)</b>	32 (38.56)	19 (36.54)	13 (41.94)	0.625
<b>Hyphema, No. (%)</b>	13 (13.27)	9 (14.06)	4 (11.76)	0.750
<b>Pre-operative IOP, Mean (SD)</b>	13.95 (9.60)	14.17 (8.97)	13.56 (10.84)	0.349

**Notes:**\*P-values for  $\chi^2$  test for categorical variables and Wilcoxon rank-sum for continuous. <sup>a</sup>OTS score utilizes the variables initial vision, globe rupture, endophthalmitis, perforating injury, retinal detachment, and afferent pupillary defect.

**Abbreviations:** OTS, ocular trauma score; IOP, intraocular pressure; VA, visual acuity; IOFB, intraocular foreign body; SD, standard deviation; N, number of eyes.

(18.36) years in the normotensive group ( $P=0.511$ ). The OTS was comparable between the two groups, with the OHT group having a mean (SD) score of 2.12 (0.71) and the normotensive group having a score of 2.09 (0.86) ( $P=0.690$ ). Injury type was also comparable between the normotensive and OHT groups, with a majority of cases caused by blunt trauma in both groups (60.94% and 52.94%, respectively) ( $P=0.505$ ). Most cases involved zone 2 injury in both the normotensive and OHT group (50.00% and 47.06%, respectively). The mean (SD) preoperative IOP was 14.17 (8.97) and 13.56 (10.84) mmHg in patients in the normotensive and OHT group, respectively. The preoperative IOP was not significantly different between the two groups ( $P=0.349$ ). The mean (SD) final IOP in the OHT group was 16.96 (5.46) and 12.11 (6.12) in the normotensive group ( $P<0.01$ ) (Figure 1). Final VA in logarithm of the minimum angle of



**Figure 1** Mean final postoperative intraocular pressure in ocular hypertensive and normotensive groups.

resolution (logMAR) was comparable between groups with a mean (SD) VA of 1.71 (0.94) in the OHT group and 1.47 (0.94) in the normotensive group ( $P=0.349$ ).

We applied a multivariable logistic regression to assess the factors associated with the development of OHT following ocular trauma while adjusting for OTS. We found that the use of silicone oil significantly predicted the development of OHT (odds ratio [95% CI], 5.63 [1.57–20.11],  $P=0.008$ ).

## Discussion

Ocular trauma remains a major cause of visual impairment worldwide. Open globe injury is a subset of ocular trauma in which there is a full-thickness wound through the cornea or the sclera.<sup>9</sup> This subset of ocular trauma is associated with significant ocular morbidity; one study found that 48.1% of patients with open-globe injury had a best-corrected VA of less than 0.02 logMAR, an outcome which was associated with hypotony, vitreous hemorrhage, iris dialysis, and worse VA at presentation.<sup>10</sup> In another study, 44.8% of patients with open-globe injury had a final VA at follow-up of less than 6/60, with RAPD, zone 3 injury, IOFB, and eyelid injury at presentation all being associated with this poor outcome.<sup>11</sup>

Persistent OHT and secondary glaucoma are also sequelae of ocular trauma that have been documented in the literature.<sup>6,7,12,13</sup> Unfortunately, the clinical course and long-term outcomes with regard to OHT following severe open-globe injury requiring PPV have not been extensively studied. Our study adds to this knowledge by elucidating specific risk factors for OHT in patients, with open globe injury undergoing PPV.

The overall incidence of OHT meeting the criteria outlined above in our cohort was 34.69%. This is in comparison to other studies in which the incidence of OHT ranged from 17% to 23.3%.<sup>12,14</sup> Differences in these rates can potentially be explained by our inclusion criteria, differences in background population characteristics, follow-up extent, and the fact that all of the patients in our cohort underwent PPV, which in and of itself has been shown to be associated with increased IOP in the post-operative period.<sup>15</sup> Furthermore, the need for PPV surgery can indicate more severe trauma leading to higher rates of increased IOP. Prior studies mentioned above showing lower rates of OHT following open-globe trauma had either a very low number of patients undergoing PPV (only 5) or an unreported number.<sup>12,14</sup>

The issue of PPV affecting IOP may raise questions as to whether this confounds the results that we have found. However, one study on the effect of PPV on IOP found that only 19.5% of patients had increased IOP following PPV, with criteria for increased IOP being IOP  $\geq 30$  mmHg within 24 hours after surgery, IOP  $\geq 25$  mmHg any time between postoperative day 2 and 6 weeks, or IOP  $\geq 22$  mmHg following 4 weeks postoperatively.<sup>15</sup> This is in comparison to our rate of IOP increase being 34.69% following open-globe injury in patients undergoing PPV, and while our criteria for OHT was slightly more inclusive in the period leading up to 6 weeks postoperatively, the criteria are similar to other studies that have shown that open-globe injury itself is an independent risk factor for increased IOP and glaucoma development.<sup>12,13</sup>

Of note, our study did not control for whether patients had glaucoma prior to their injury, as the vast majority of patients presented for the first time at their trauma. However, our patients represent a younger population with a mean age of 46.08 and 44.16 for patients in the OHT and normotensive groups, respectively. This is in comparison to reports showing the average age of patients with glaucoma to be 57.83 years, with 93% of patients diagnosed with glaucoma being age 55 and above.<sup>16,17</sup> Thus, we surmise that prior diagnosis of glaucoma was likely not a significant confounding factor. Our study is also limited by the fact that we did not have optic nerve head imaging and visual field testing for the patients during the follow-up period. These tests are usually unreliable in patients with a history of eye trauma, so we opted to assess for the development of OHT rather than the specific development of glaucoma in our study. Additionally, the retrospective nature of the study precluded our ability to further characterize specific analyzed risk factors, such as size and duration of hyphema and the amount of fill and duration of silicone oil. Documented gonioscopic exams were also not routinely available, so the presence of iridocorneal angle pathology, such as angle recession, iridodialysis, or cyclodialysis, could not be used as variables in our analysis.

Through a multivariable logistic regression analysis, we found a significant association between the use of silicone oil and the development of OHT. Patients who had silicone oil placed during PPV had an approximately 5.63-fold increased odds of developing OHT. This relationship persisted even after adjusting for the OTS, suggesting that silicone oil use may be a potent predictor of post-PPV OHT in the setting of open globe injury. It is well known that silicone oil-filled eyes in non-trauma settings are prone to developing OHT.<sup>18</sup> However, only 41.18% of eyes with sustained OHT in our study had silicone oil

tamponade. This suggests that ocular trauma independently contributed to the development of sustained OHT post-PPV. It is therefore reasonable to suggest that the increased risk of persistent OHT in trauma eyes requiring silicone oil tamponade is independent of the use of silicone oil itself but rather possibly because the need for silicone oil during PPV signifies more severe trauma. Our findings underscore the importance of vigilant postoperative monitoring for OHT in patients who undergo PPV for trauma-related complications, particularly in patients with silicone oil use.

## Ethics Statement

The study was approved by the institutional review board of the University of Arkansas for Medical Sciences, and the requirement for informed consent was waived, as the study was retrospective and no personal health information was collected. The study followed the tenets of the Declaration of Helsinki and the Health Insurance Portability and Accountability Act.

## Funding

There is no funding to report.

## Disclosure

No conflicting relationship exists for any author. The authors alone are responsible for the content and writing of this article.

## References

1. Greco A, Rizzo MI, De Virgilio A, et al. Emerging concepts in glaucoma and review of the literature. *Am J Med.* 2016;129(9):1000.e7–e13. doi:10.1016/j.amjmed.2016.03.038
2. Collaborators GBaVI, Study VLEGOT GBoD. Causes of blindness and vision impairment in 2020 and trends over 30 years, and prevalence of avoidable blindness in relation to VISION 2020: the right to sight: an analysis for the Global Burden of Disease Study. *Lancet Glob Health.* 2021;9(2):e144–e60. doi:10.1016/S2214-109X(20)30489-7
3. Gupta P, Zhao D, Guallar E, et al. Prevalence of glaucoma in the United States: the 2005–2008 National Health and Nutrition Examination Survey. *Invest Ophthalmol Vis Sci.* 2016;57(6):2905–2913. doi:10.1167/iovs.15-18469
4. Gadia R, Sihota R, Dada T, Gupta V. Current profile of secondary glaucomas. *Indian J Ophthalmol.* 2008;56(4):285–289. doi:10.4103/0301-4738.41411
5. Sihota R, Sood NN, Agarwal HC. Secondary juvenile glaucomas in India. *Indian J Ophthalmol.* 1991;39(3):94–96.
6. Sihota R, Sood NN, Agarwal HC. Traumatic glaucoma. *Acta Ophthalmol Scand.* 1995;73(3):252–254. doi:10.1111/j.1600-0420.1995.tb00279.x
7. Girkin CA, McGwin G, Long C, et al. Glaucoma after ocular contusion: a cohort study of the United States Eye Injury Registry. *J Glaucoma.* 2005;14(6):470–473. doi:10.1097/01.jig.0000185437.92803.d7
8. Kaufman JH, Tolpin DW. Glaucoma after traumatic angle recession. A ten-year prospective study. *Am J Ophthalmol.* 1974;78(4):648–654. doi:10.1016/S0002-9394(14)76303-2
9. Kuhn F, Morris R, Witherspoon CD, et al. A standardized classification of ocular trauma. *Graefes Arch Clin Exp Ophthalmol.* 1996;234(6):399–403. doi:10.1007/BF00190717
10. Puodžiuvienė E, Valeišaitė G, Žemaitienė R. Clinical characteristics, visual outcomes, and prognostic factors of open globe injuries. *Medicina.* 2021;57(11):1198.
11. Hoskin AK, Low R, Sen P, et al. Epidemiology and outcomes of open globe injuries: the international globe and adnexal trauma epidemiology study (IGATES). *Graefes Arch Clin Exp Ophthalmol.* 2021;259(11):3485–3499. doi:10.1007/s00417-021-05266-1
12. Turalba AV, Shah AS, Andreoli MT, et al. Predictors and outcomes of ocular hypertension after open-globe injury. *J Glaucoma.* 2014;23(1):5–10. doi:10.1097/IJG.0b013e318265bb4a
13. Osman EA. Glaucoma after open globe injury. *Saudi J Ophthalmol.* 2015;29(3):222–224. doi:10.1016/j.sjopt.2014.10.006
14. Bojikian KD, Stein AL, Slabaugh MA, Chen PP. Incidence and risk factors for traumatic intraocular pressure elevation and traumatic glaucoma after open-globe injury. *Eye.* 2015;29(12):1579–1584. doi:10.1038/eye.2015.173
15. Fang Y, Long Q, Wang X, et al. Intraocular pressure 1 year after vitrectomy in eyes without a history of glaucoma or ocular hypertension. *Clin Ophthalmol.* 2017;11:2091–2097. doi:10.2147/OPTH.S144985
16. Zhao Y, Fu JL, Li YL, et al. Epidemiology and clinical characteristics of patients with glaucoma: an analysis of hospital data between 2003 and 2012. *Indian J Ophthalmol.* 2015;63(11):825–831. doi:10.4103/0301-4738.171963
17. Tuck MW, Crick RP. The age distribution of primary open angle glaucoma. *Ophthalmic Epidemiol.* 1998;5(4):173–183. doi:10.1076/opep.5.4.173.4192
18. Ge L, Su N, Fan W, Yuan S. Risk factors and management of intraocular pressure elevation after vitrectomy combined with silicone oil tamponade. *Int J Gene Med.* 2024;17:447–456. doi:10.2147/IJGM.S446617

## Clinical Ophthalmology

### Publish your work in this journal

Clinical Ophthalmology is an international, peer-reviewed journal covering all subspecialties within ophthalmology. Key topics include: Optometry; Visual science; Pharmacology and drug therapy in eye diseases; Basic Sciences; Primary and Secondary eye care; Patient Safety and Quality of Care Improvements. This journal is indexed on PubMed Central and CAS, and is the official journal of The Society of Clinical Ophthalmology (SCO). The manuscript management system is completely online and includes a very quick and fair peer-review system, which is all easy to use. Visit <http://www.dovepress.com/testimonials.php> to read real quotes from published authors.

Submit your manuscript here: <https://www.dovepress.com/clinical-ophthalmology-journal>

**Dovepress**

Taylor & Francis Group