

# Novel *SLC16A2* Frameshift Mutation as a Cause of Allan-Herndon-Dudley Syndrome and its Implications for Carrier Screening

Peng Lin<sup>1,2,\*</sup>, Huituan Liu<sup>3,\*</sup>, Jiwu Lou<sup>1,2</sup>, Guizhen Lyu<sup>4,5</sup>, Yanwei Li<sup>4</sup>, Peiqing He<sup>1,2</sup>, Youqing Fu<sup>1,2</sup>, Ronghua Zhang<sup>1,2</sup>, Yuqiong Zhang<sup>3</sup>, Tizhen Yan<sup>1,2</sup>

<sup>1</sup>Prenatal Diagnostic Centre, Dongguan Maternal and Children Health Hospital, Dongguan, Guangdong, People's Republic of China; <sup>2</sup>Dongguan Key Laboratory of Precision Medicine for Prenatal Diagnosis of Genetic Diseases, Dongguan, Guangdong, People's Republic of China; <sup>3</sup>Department of Children's Rehabilitation, Dongguan Maternal and Children Health Hospital, Dongguan, Guangdong, People's Republic of China; <sup>4</sup>Dongguan Key Laboratory of Clinical Medical Test Diagnostic Technology for Oncology, Dongguan Labway Medical Testing Laboratory Co., Ltd., Dongguan, Guangdong, People's Republic of China; <sup>5</sup>Dongguan Molecular Diagnostic Technology and Infectious Disease Medical Test Engineering Research Centre, Dongguan Labway Medical Testing Laboratory Co., Ltd., Dongguan, Guangdong, People's Republic of China

\*These authors contributed equally to this work

Correspondence: Tizhen Yan; Yuqiong Zhang, Email yantizhen@gdmu.edu.cn; zyq226688@163.com

**Background:** Allan-Herndon-Dudley syndrome (AHDS) is a rare X-linked neurodevelopmental disorder caused by mutations in the solute carrier family 16-member 2 (*SLC16A2*) gene. This syndrome leads to significant psychomotor disabilities, thyroid dysfunction, and abnormal brain development. This case report describes the genetic cause of AHDS in a male proband and to expanding the mutation spectrum of the *SLC16A2* gene.

**Methods:** A blood specimen was collected from a one-year-old child with delayed development and abnormal thyroid function and this was followed by whole-exome sequencing (WES) was performed on the proband to identify potential genetic mutations. Sanger sequencing was subsequently used to confirm the findings and determine the inheritance pattern of the mutation within the family.

**Results:** The proband, who presented with developmental delay, thyroid dysfunction, and abnormal brain development, was found to have a novel hemizygous frameshift mutation, c.513\_538del (p.Ile172Cysfs\*60), in the *SLC16A2* gene (NM\_006517.5). This mutation was inherited from his asymptomatic mother, confirming the X-linked inheritance pattern. The mutation is classified as likely pathogenic, contributing to the clinical presentation observed in the proband.

**Conclusion:** This study identified a novel frameshift mutation in the *SLC16A2* gene associated with AHDS, thereby expanding the known mutation spectrum of this gene. Given the significant impact of AHDS on neural development and hormone secretion, it is recommended that this gene be included in carrier screening panels in China, particularly for families with a history of related neurodevelopmental disorders.

**Keywords:** *SLC16A2* gene, Allan-Herndon-Dudley syndrome, thyroid pathology, neurotransmitter development

## Introduction

Genetic disorders are a significant cause of morbidity and mortality worldwide, affecting millions of individuals across various populations.<sup>1</sup> These disorders result from alterations in the genome and can lead to a wide range of clinical manifestations, including developmental delays, metabolic abnormalities, and neurodegenerative conditions.<sup>2</sup> Among these, X-linked disorders are particularly noteworthy due to their inheritance pattern, which often results in more severe phenotypes in males due to the X-linked. One such disorder is Allan-Herndon-Dudley syndrome (AHDS, OMIM300523), a rare X-linked neurodevelopmental disorder.<sup>3</sup> The prevalence is not well-documented due to its rarity. However, it is recognized globally, including in North America, Europe, and Asia. The exact prevalence is estimated to be fewer than 1 in 1,000,000 live male births, but many cases may go undiagnosed, particularly in regions with limited access to genetic testing.<sup>4</sup> The AHDS are previously reported as X-linked mental retardation (XLMR) syndromes.<sup>5</sup> It was originally proposed by Allan, Herndon and Dudley in 1944, mainly

affecting males. AHDS's main phenotypes include severe developmental delay, hypotonia, spastic paraplegia, abnormal serum thyroid hormone (TH) and delayed myelin development. Some patients may exhibit symptoms of acquired microcephaly, abnormal myopathic facial features, dysarthria, scoliosis, reduced muscle volume, joint contractures, hyperreflexia, ataxia, and paroxysmal motor disorders.<sup>6</sup> AHDS caused by mutations in the *SLC16A2* gene encoding monocarboxylate transporter 8 (MCT8).<sup>7</sup> MCT8 is a commonly present thyroid hormone membrane transporter, particularly expressed in the liver, kidneys, thyroid, and brain.<sup>8</sup> Impaired T3 uptake and action in MCT8-deficient brain-like organs are the basis of AHDS and the deficiency of MCT8 would cause thyroid metabolic disorders and abnormal transport of thyroid hormones to the brain.<sup>9</sup> Delayed myelination can be revealed in brain magnetic resonance imaging (MRI) in the early years. Meanwhile, the diagnosis is confirmed by identifying a pathogenic mutation in the *SLC16A2* gene.<sup>10–12</sup> Here, we reported a new case of severe developmental delay, thyroid dysfunction, and brain development abnormalities associated with a hemizygous frameshift mutation c.513\_538del in the *SLC16A2* gene. This mutation results in the substitution of the 172nd amino acid Isoleucine (Ile) with Cysteine (Cys), leading to premature termination of translation (p.Ile172Cysfs\*60). To the best of our knowledge, this is the first case of this specific mutation reported in China. This novel mutation has not been previously identified in patients diagnosed with AHDS, and our findings expand the known mutation spectrum of the *SLC16A2* gene related to AHDS. Additionally, we retrospectively analyzed 23 previously reported Chinese patients with AHDS, outlining their clinical phenotypes, laboratory test results, and molecular characteristics to provide a comprehensive understanding of the disorder in this population.

## Subjects and Methods

This study was conducted in accordance with the principles outlined in the Helsinki Declaration. Ethical approval was obtained from the institutional review board of Dongguan Maternal and Children Health Hospital, Dongguan, China and communicated through Letter no 33 (2021), and informed consent was secured from the patient's guardians prior to all procedures. The legal guardian was made aware that the collected data would be considered for research and publication purposes.

## Whole Exome Sequencing (WES)

Blood samples of the proband and his parents were collected, genomic DNA was extracted using the nucleic acid extraction reagent (BGI (Wuhan) Co., Ltd., China) according to the manufacturer's instructions, and exon capture was performed using the exome hybridization capture kit (BGI (Wuhan) Co., Ltd., China) according to the instructions. Then sequencing was performed on the MGISEQ-2000 sequencing platform. The single nucleotide variants (SNVs) and copy number variants (CNVs) were classified according to the American College of Medical Genetics and Genomics (ACMG) guidelines.<sup>13</sup>

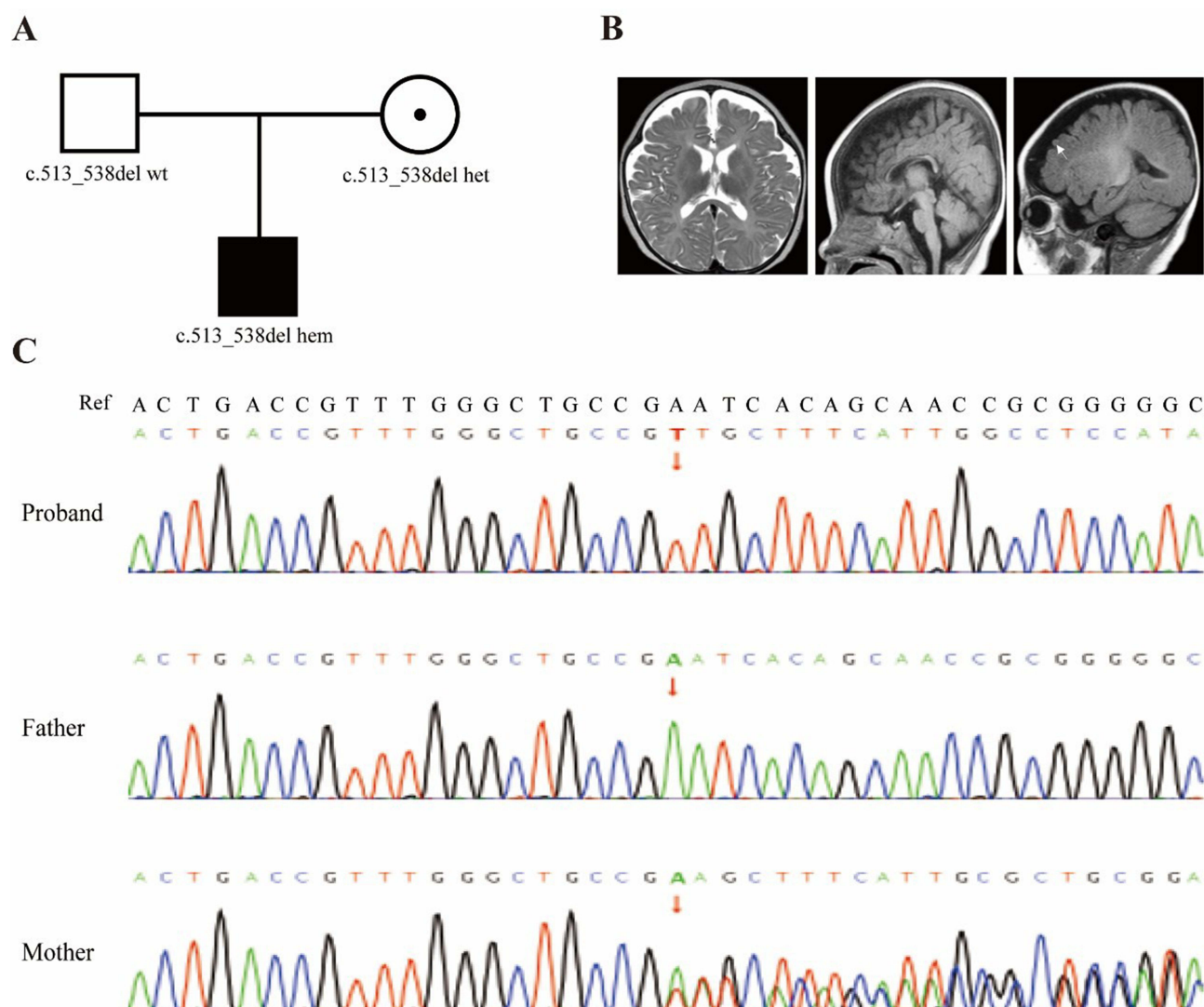
## Result

### Clinical Characteristics

A one-year-old Chinese (ethnicity unknown) boy was admitted to our outpatient department due to developmental delay and abnormal thyroid function. At the age of 3–4 months, the child had poor head control. At the age of 7 months, the physical examination of the child revealed unable to lift their head in a prone position, unable to sit still, unable to complete the flip action, limb muscle tension was too high and muscle weakness. The parents, both of whom are from Chinese, are in good health and have no known family history of genetic disorders, nor is there any consanguinity between them. They are of middle-class status, with both parents having completed higher education and being employed in stable professions.

### Laboratory Tests

At the age of 7 months, GMFM was used to assess the children's gross motor function. The total GMFM score is 6.76%, and the score for each zone is 25.49% in dimension A (lying and rolling); 8.33% in dimension B (sitting); 0.00% in dimension C (crawling and kneeling); 0.00% in dimension D (standing); 0.00% in dimension E (walking, running, and jumping). The neuropsychological development scale showed that he had developmental disorders (eg, Bayley Scales of Infant and Toddler Development). Asymmetric tonic neck reflex (ATNR) was positive. Then the proband is the child of a Chinese couple. The black square is the proband, the white square is the healthy father, and the dotted circle is the carrier mother (Figure 1A). The MRI of the proband revealed delayed myelination and widened bilateral frontal and left



**Figure 1** Pedigree chart, MRI test and Sanger sequencing results of the family. **(A)** Pedigree chart. **(B)** The Brain magnetic resonance imaging of the patient. The arrow indicates a widened gap. **(C)** The Sanger sequencing results of *SLC16A2* mutation c.513\_538del in family members.

temporal extra brain spaces (Figure 1B). At the age of 7 months, the thyroid function tests revealed elevated thyroid stimulating hormone (TSH) (5.93 $\mu$ IU/mL; reference range 0.27–4.2 $\mu$ IU/mL), elevated free triiodothyronine (FT3) (9.79pg/mL; reference range 2.0–4.4pg/mL) and decreased free tetraiodothyronine (FT4) (0.58ng/dL; reference range 1.0–1.7ng/dL). At the age of 1 year, the thyroid function tests revealed normal TSH (1.26  $\mu$ IU/mL), elevated FT3 (27.90pg/mL), elevated T3 (6.47ng/mL; reference range 0.8–2.0ng/mL), decreased FT4 (0.26ng/dL), decreased T4 (2.57 $\mu$ g/dL; reference range 5.1–14.1 $\mu$ g/dL).

## Whole-Exome Sequencing and Mutation Annotation

The whole-exome sequencing (WES) panel used for the family included approximately 22,000 protein-coding genes, achieving 100% target area coverage. The sequencing data demonstrated an average coverage depth of 313.4X, with 99.6% of the target regions covered at >10X depth and 99.93% at >20X depth. No abnormalities in chromosome numbers or pathogenic copy number variants (CNVs) were detected. In the proband, a hemizygous frameshift mutation, c.513\_538del(p.Ile172Cysfs\*60), was identified in the *SLC16A2* gene. This mutation was confirmed by Sanger sequencing, which showed that the mutation was inherited from the proband's mother, who is a carrier (Figure 1C). The mutation was not found in the gnomAD database, and no corresponding mutation was observed in our internal database.

According to the American College of Medical Genetics and Genomics (ACMG) guidelines,<sup>13</sup> this novel mutation is classified as likely pathogenic (PVS1+PM2).

## Discussion

In our study, we reported a case with a novel frameshift mutation c.513\_538del(p.Ile172Cysfs\*60) in *SLC16A2* identified by WES and Sanger sequencing. This mutation would lead to premature termination of MCT8 protein translation, resulting in the loss of its active domain and C-terminus, which leads to the loss of MCT8 protein function. An international retrospective multicentre cohort study on patients with MCT8 deficiency revealed that up to 90% of patients experienced systemic hypotonia, dystonia, and spastic paraplegia, accompanied by severe developmental delay, abnormal serum thyroid hormone (TH), and delayed myelin sheath development.<sup>14</sup> We summarized the clinical phenotypes, laboratory test results, and molecular characteristics of 23 reported Chinese patients (Table 1).<sup>15–25</sup> Meanwhile, we compared the clinical phenotypes and laboratory test results of 23 reported Chinese patients with a multicentre cohort study of 151 patients.<sup>14</sup> We found that the most common clinical phenotypes were intellectual disability (100%, 23/23), motor development delay (100%, 21/21), language development delay (100%, 19/19), and hypotonia (100%, 19/19), which were consistent with the results of the multicentre cohort study (Table 2). The main symptoms of the proband included developmental delay, hypotonia, abnormal thyroid function, and abnormal brain MRI (delayed myelination), which were highly consistent with the above statistical results.

All of these patients were male, with 4 pairs of brothers. There were 19 mutations, distributed in the exon and intron regions of the *SLC16A2* gene (Figure 2). All of these 19 mutations were single nucleotide variants (SNVs), including 9 frameshift mutations (47.4%), 5 splicing mutations (26.3%), 3 nonsense mutations (15.8%), 1 missense mutation (5.3%), and 1 in-frame mutation (5.3%). Among the 23 Chinese patients, 11 patients (47.8%, 2 pairs of brothers) had frameshift mutations, 5 patients (21.7%) had splicing mutations, 5 patients (21.7%, 2 pairs of brothers) had nonsense mutations, 1 patient (4.4%) had a missense mutation, and 1 patient (4.4%) had an in-frame mutation. Among the 23 Chinese patients, 17 patients (73.9%) had maternal-inherited mutations. The mothers of 3 patients were not sequenced, and 2 patients (a pair of brothers) of them both had c.511C>T (p.R171\*) mutation of *SLC16A2* gene. In addition, 3 patients (13.0%) had De novo mutations. The mutation c.513\_538del(p.Ile172Cysfs\*60) of the proband is a frameshift mutation inherited from the mother, which was highly consistent with the above statistical results.

The current diagnostic method for AHDS was built on neurological manifestations such as early onset (before 2 years of age) accompanied by hypotonia and feeding difficulties, mild/severe intellectual disability and developmental delay, medullary dysplasia, and seizures. Common facial manifestations include drooping of the upper eyelid, opening of the mouth, abnormal development of the ears, and facial features, such as a long face. Manifestations of thyroid dysfunction could be detected by blood tests. Typically, an increase in serum triiodothyronine (T3) and a decrease in serum thyroxine (T4), with a slight increase in the secretion of thyroid-stimulating hormone (TSH), were shown by the tests of thyroid function. The reduction of functional MCT8 in the developing brain may lead to intellectual disability.<sup>27</sup> Brain MRI of children under 5 years old typically showed severe delayed myelin formation, similar to insufficient myelin formation, which subsequently improves over time.<sup>28</sup> The transport process of thyroid hormones to the central nervous system could be severely impaired during the peak myelin formation and the central nervous system development process in the first two years of life.<sup>29</sup> The inability to transport T3 could cause neurological damage symptoms, such as central hypotonia, ataxia, paralysis, and aphasia.<sup>7</sup>

The genetic characteristics related to the X chromosome of AHDS were pathogenic in male probands of hemizygous mutation in the *SLC16A2* gene, while females with heterozygous mutation were generally carriers without obvious phenotypes. Molecular genetic testing was the most effective method to provide information on the pathogenic risk of mutations of *SLC16A2* in female carriers. According to the recommendations of the ACMG guidelines, carrier screening should be considered when the prevalence of X-linked gene-related genetic diseases is  $\geq 1/40,000$ ,<sup>30</sup> while the current global prevalence of AHDS is currently unknown. In 2024, the expert consensus was drawn up by the Genetic Diagnosis Branch of the Chinese Society of Genetics and the Clinical Genetics and Genetic Consulting Special Committee of the Shanghai Society of Genetics proposed, that the causes of the impact on the statistical data of prevalence included but were not limited to fetal or perinatal death and the limitations of Chinese population studies.<sup>30</sup> It would lead to the

**Table 1** Clinical Phenotypes, Laboratory Test Results, and Molecular Characteristics of Chinese Patients

Patients	Gender	Age	Family history	Microcephaly	FT3	FT4	TSH	Intellectual disability	Motor development delay	Language development delay	Hypotonia	Dystonia	MRI abnormalities	Maternal Thyroid Function	Others	Mutation types	Mutation	Inheritance	Reference
P1	Male	8Y9M	P1 and P2 are brothers.	NA	↑	↓	–	+	+	+	+	+	Delayed myelination	–	Knee hyperreflexia, long face, narrow forehead, narrow cheeks, open mouth, thick lips, tent-like upper lip, slightly large ears.	Nonsense	c.916C>T(p. Q306*)	Maternal	Wang et al, 2018 <sup>15</sup>
P2	Male	9M	P1 and P2 are brothers.	NA	↑	↓	–	+	+	+	+	+	–	–	Knee hyperreflexia	Nonsense	c.916C>T(p. Q306*)	Maternal	
P3	Male	8Y0.6M	–	NA	↑	↓	–	+	+	+	+	+	–	NA	Knee hyperreflexia	Nonsense	c.61G>T(p. E21*)	De novo	
P4	Male	1Y3M	–	NA	↑	↓	–	+	+	+	+	+	Delayed myelination, and widened extracranial spaces in bilateral frontal and temporal regions.	NA	Knee hyperreflexia, long face, narrow forehead, narrow cheeks, open mouth, thick lips, tent-like upper lip, slightly large ears.	Frameshift	c.695_699del(p. N232Sfs*7)	De novo	
P5	Male	9M	–	NA	↑	↓	–	+	+	+	+	+	Delayed myelination	–	Knee hyperreflexia	Frameshift	c.42del(p. W15Gfs*69)	Maternal	
P6	Male	8M	His mother's brother had similar symptoms and died at the age of one.	–	NA	NA	–	+	+	+	+	+	Delayed myelination, cerebral gap widened.	–	Scoliosis, long face, lre ears (cup-shaped), pneumonia.	Splicing	c.431–1G>C	Maternal	Tang et al, 2018 <sup>16</sup>
P7	Male	1Y6M	–	–	↑	↓	↑	+	+	+	+	+	Delayed myelination, and mild cortical atrophy.	–	Elongated face, bifrontal narrowing, flat nose	Splicing	c.431–2A>G	Maternal	Chen et al, 2022 <sup>17</sup>
P8	Male	1Y	NA	NA	↑	↓	NA	+	+	+	+	+	Local changes in the white matter around the posterior corners of the bilateral ventricles	NA	NA	Splicing	c.1026+1G>A	De novo	Wang et al, 2020 <sup>18</sup>
P9	Male	4M	–	NA	↑	↓	–	+	+	+	+	+	Delayed myelination (anterior limb of internal capsule), cerebral gap widened (bilateral frontoparietal), pachygyria (bifrontal lobes).	+	Pneumonia, thumb adduction, malnutrition	Frameshift	c.194del(p. P65Rfs*19)	Maternal	Jia et al, 2020 <sup>26</sup>

(Continued)

Table I (Continued).

Patients	Gender	Age	Family history	Microcephaly	FT3	FT4	TSH	Intellectual disability	Motor development delay	Language development delay	Hypotonia	Dystonia	MRI abnormalities	Maternal Thyroid Function	Others	Mutation types	Mutation	Inheritance	Reference
P10	Male	1Y5M	—	+	↑	↓	↑	+	+	+	+	+	Abnormal signals in the frontal parietal white matter widened ventricles and extracerebral spaces	—	Deafness, micrognathia	Splicing	c.1170+1G>A	Maternal	Xin et al, 2020 <sup>21</sup>
P11	Male	11M	—	—	↑	—	—	+	+	+	+	+	Patchy abnormal signals in the brain stem, are considered metabolic demyelination.	—	—	Inframe	c.467_469del(p. F156del)	Maternal	Zou et al, 2020 <sup>22</sup>
P12	Male	1M	His twin brother had similar symptoms.	+	—	—	—	+	+	+	+	+	—	+	Respiratory infections during infancy, malnutrition, apathy, slow response, ankle clonus, conjunctival congestion, and stridor.	Frameshift	c.942del(p. V315Cfs*28)	Maternal	Zhang et al, 2022 <sup>20</sup>
P13	Male	5M	—	+	↑	↓	—	+	+	+	+	+	A patchy long T1 and long T2 signal shadow in the left mid-cerebellar peduncle, with a slightly high signal on high bVue DWI and a slightly low signal on ADC.	+	Seizures, pneumonia, long face, cupped ear, esotropia.	Frameshift	c.1115_1121dup (p.G375Cfs*7)	Maternal	
P14	Male	7M	His half-brother had a delayed motor and intellectual development and died at the age of 17 months due to fever.	—	↑	↓	—	+	+	+	+	+	Widened extracranial spaces in bilateral frontal and temporal regions.	NA	—	Frameshift	c.1455del(p. I488Sfs*5)	Maternal	Lu et al, 2022 <sup>23</sup>
P15	Male	6M	P15 and P16 are brothers.	—	↑	↓	—	+	+	+	+	+	Slightly widened extracranial spaces in bilateral frontal and temporal regions.	NA	—	Frameshift	c.504_529del(p. I172Cfs*60)	Maternal	
P16	Male	4Y	P15 and P16 are brothers.	+	NA	NA	NA	+	+	+	+	+	NA	NA	Mild Achilles tendon contracture	Frameshift	c.504_529del(p. I172Cfs*60)	Maternal	
P17	Male	8M	—	—	↑	—	—	+	+	+	NA	—	Widened extracranial spaces in bilateral frontal and temporal regions.	NA	Long face, lRe ears, open mouth	Missense	c.448G>A(p. A150T)	Maternal	

P18	Male	4Y	P18 and P19 are brothers.	NA	↑	–	↑	+	+	+	+	NA	Delayed myelination and development of the cerebellum, hippocampus, and basal ganglia.	–	Seizures, esotropia, sudden death	Frameshift	c.584del(p. S195Tfs*72)	Maternal	Liu et al, 2022 <sup>24</sup>
P19	Male	8Y	P18 and P19 are brothers.	NA	↑	↓	–	+	+	+	+	NA	NA	–	Esotropia	Frameshift	c.584del(p. S195Tfs*72)	Maternal	Yiu et al, 2023 <sup>25</sup>
P20	Male	9M	–	+	↑	↓	↑	+	+	NA	NA	+	NA	–	–	Splicing	c.1170+2T>A	Maternal	
P21	Male	17Y	Eplpsy (in his grandmother), dystonia (in his maternal male cousin).	NA	–	↓	↑	+	+	NA	+	+	Minimal cerebral atrophy	NA	Recurrent pneumonia, deceased due to severe pulmonary infection	Frameshift	c.305dup(p. V103Gfs*17)	NA	
P22	Male	NA	P22 and P23 are brothers, with intellectual disability (mother, 1 sister, 1 brother born to a different father).	NA	NA	NA	NA	+	NA	NA	NA	NA	NA	+	Recurrent vomiting, recurrent pneumonia, epilepsy, deceased due to severe pulmonary infection	Nonsense	c.511C>T(p. R171*)	NA	This report
P23	Male	NA	P22 and P23 are brothers, with intellectual disability (mother, 1 sister, 1 brother born to a different father).	NA	NA	NA	NA	+	NA	NA	NA	NA	NA	+	Recurrent vomiting, recurrent pneumonia, epilepsy, deceased due to severe pulmonary infection	Nonsense	c.511C>T(p. R171*)	NA	
Proband	Male	1Y	–	–	↑	↓	↑	+	+	+	+	+	Delayed myelination	–	The EEG was detected as a borderline pediatric electro enceph alogram	Frameshift	c.513_538del(p. 1172Cfs*60)	Maternal	

**Abbreviations:** Y, year; M, month; FT3, free triiodothyronine; FT4, free tetraiodothyronine; TSH, thyroid stimulating hormone, +, abnormal; –, normal; NA, not available.

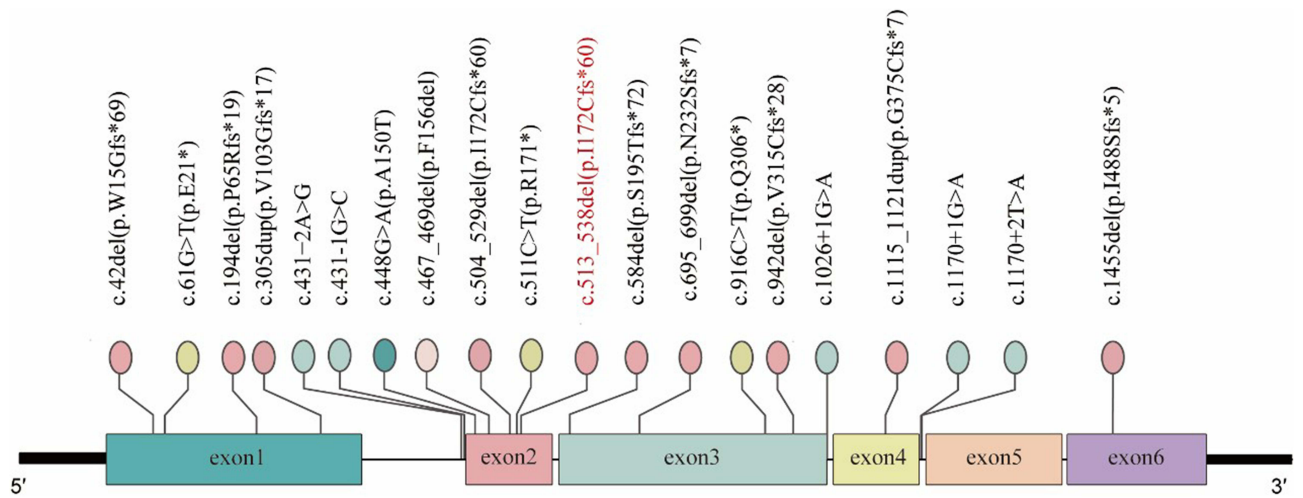


**Table 2** Comparison of Clinical Phenotype and Laboratory Test Results

	23 Chinese Patients			The Multicentre Cohort Study		
	Total	Abnormal	Scale (%)	Total	Abnormal	Scale (%)
Intellectual disability	23	23	100	86	86	100
Motor development delay	21	21	100	86	86	100
Language development delay	19	19	100	86	86	100
Hypotonia	19	19	100	72	72	100
Elevated FT3/T3	19	17	89.5	101	96	95.1
Decreased FT4	19	15	79.0	106	94	88.7
Normal TSH	19	14	73.7	105	93	88.6
MRI abnormalities	18	15	83.3	13	13	100
Delayed myelination	18	7	38.9	13	13	100
Dystonia	19	18	94.7	69	57	82.6
Microcephaly	11	5	45.5	59	19	32.2
Death	23	3	13.0	151	32	21.2

underestimated prevalence of AHDS in China. This was consistent with the results of our statistics that 13.0% of Chinese AHDS patients died, while the mortality rate in the multicentre cohort study was 21.2%. According to the method of assessment of disease severity proposed by Lazarin et al, reduction in life expectancy and mental retardation (disability) in the classification of disease characteristics were classified as Level I.<sup>31</sup> According to the recommendations of the ACMG guidelines,<sup>30</sup> carries with more than moderate severity be included in carrier screening. In summary, *SLC16A2*-related AHDS is recommended to be included in carrier screening.

Previous studies have emphasized that attributable to non-specific initial clinical features and clinical doctors' lack of awareness of AHDS, there was a severe delay in the diagnosis of this disease.<sup>14</sup> From the perspective of disease prevention and treatment, early diagnosis played a crucial role. However, limited treatment options can be chosen for AHDS. The T3 analog called triiodothyroacetic acid (TRIAC) entered cells without relying on MCT8 and stimulated endogenous thyroid hormone receptors, was demonstrated that it could stabilize thyroid function and reduce neurological damage in Phase 2 trials. In 2022, van Geest et al used the TRIAC to treat MCT8 deficiency pediatric and adult patients from 62 different families, including 46 different *SLC16A2* mutations from October 2014 to January 2020. Researchers presented a report on the efficacy and safety of this treatment, improving the symptomatic treatment plan for thyroid secretion abnormalities.<sup>32</sup> In 2022, Chen et al reported a novel mutation of the *SLC16A2* gene and were diagnosed with



**Figure 2** Distribution of *SLC16A2* mutations in Chinese patients with AHD.  
**Note:** \*symbol likely indicates nonsense mutations (stop codons) leading to premature termination of protein translation.



AHDS. The patient received TRIAC treatment which continued for 3 months. Thyroid function tests showed that the patient's indicators gradually stabilized within the normal range, making it the first case in China to receive TRIAC treatment for MCT8 deficiency.<sup>17</sup> An increasing number of clinical trials had demonstrated the safety and effectiveness of TRIAC in the treatment of AHDS. Meanwhile, earlier treatment can improve the quality of life and life expectancy of patients. Consequently, early awareness and diagnosis played a crucial role in this disease process.

## Conclusion

AHDS could be treated and intervened clinically. Due to the significant impact of AHDS on neural development and hormone secretion, as well as its broad phenotypic characteristics, it is recommended to include it in the carrier screening gene package testing in China. The importance is reducing developmental disorders and neurological damage caused by endocrine abnormalities in early detection and intervention of AHDS, alleviating patient symptoms and providing the corresponding rehabilitation treatment, and providing genetic counselling support for families during the pregnancy and preparation period.

## Data Sharing Statement

The data supporting the findings of this study are available upon request from the corresponding author.

## Ethical Approval

The study was approved by the ethics committee of the Dongguan Maternal and Child Health Care Hospital. The study was performed following the principles of the Declaration of Helsinki. The genetic testing and published ultrasound images were provided by the parents of the proband after a signed consent.

## Acknowledgments

Peng Lin and Huituan Liu are co-first authors for this study. This study was supported by the Dongguan Comprehensive Prevention and Control of Birth Defects Project (No.441900210000272762).

## Author Contributions

All authors made a significant contribution to the work reported, whether that is in the conception, study design, execution, acquisition of data, analysis and interpretation, or all these areas; took part in drafting, revising or critically reviewing the article; gave final approval of the version to be published; have agreed on the journal to which the article has been submitted; and agree to be accountable for all aspects of the work.

## Disclosure

The authors have no conflicts of interest to declare in this work.

## References

1. Jukarainen S, Kiiskinen T, Kuitunen S, et al. Genetic risk factors have a substantial impact on healthy life years. *Nat Med.* 2022;28(9):1893–1901. doi:10.1038/s41591-022-01957-2
2. Jackson M, Marks L, May GHW, Wilson JB. The genetic basis of disease. *Essays Biochem.* 2018;62(5):643–723. doi:10.1042/EBC20170053
3. Sarret C, Petit IO, Tonduti D. Allan-Herndon-Dudley Syndrome. In: *GeneReviews*® [Internet]. Seattle:University of Washington;2020. <https://www.ncbi.nlm.nih.gov/books/NBK26373/>.
4. Beheshti R, Aprile J, Lee C. Allan-Herndon-Dudley syndrome: a novel pathogenic variant of the SLC16A2 gene. *Cureus.* 2022;14(1):e21771. doi:10.7759/cureus.21771
5. Dumitrescu AM, Liao XH, Best TB, Brockmann K, Refetoff S. A novel syndrome combining thyroid and neurological abnormalities is associated with mutations in a monocarboxylate transporter gene. *Am J Hum Genet.* 2004;74(1):168–175. doi:10.1086/380999
6. Papadimitriou A, Dumitrescu AM, Papavasiliou A, Fretzayas A, Nicolaidou P, Refetoff S. A novel monocarboxylate transporter 8 gene mutation as a cause of severe neonatal hypotonia and developmental delay. *Pediatrics.* 2008;121(1):e199–202. doi:10.1542/peds.2007-1247
7. Schwartz CE, May MM, Carpenter NJ, et al. Allan-Herndon-Dudley syndrome and the monocarboxylate transporter 8 (MCT8) gene. *Am J Hum Genet.* 2005;77(1):41–53. doi:10.1086/431313
8. Arjona FJ, de Vrieze E, Visser TJ, Flik G, Klaren PHM. Identification and functional characterization of zebrafish solute carrier Slc16a2 (Mct8) as a thyroid hormone membrane transporter. *Endocrinology.* 2011;152(12):5065–5073. doi:10.1210/en.2011-1166
9. Salas-Lucia F, Escamilla S, Bianco AC, Dumitrescu A, Refetoff S. Impaired T3 uptake and action in MCT8-deficient cerebral organoids underlie Allan-Herndon-Dudley syndrome. *JCI Insight.* 2024;9(7):e174645. doi:10.1172/jci.insight.174645

10. Namba N, Etani Y, Kitaoka T, et al. Clinical phenotype and endocrinological investigations in a patient with a mutation in the MCT8 thyroid hormone transporter. *Eur J Pediatr*. 2008;167(7):785–791. doi:10.1007/s00431-007-0589-6
11. Vaur-Barrière C, Deville M, Sarret C, et al. Pelizaeus-Merzbacher-like disease presentation of MCT8 mutated male subjects. *Ann Neurol*. 2009;65(1):114–118. doi:10.1002/ana.21579
12. Gika AD, Siddiqui A, Hulse AJ, et al. White matter abnormalities and dystonic motor disorder associated with mutations in the SLC16A2 gene. *Dev Med Child Neurol*. 2010;52(5):475–482. doi:10.1111/j.1469-8749.2009.03471.x
13. Richards S, Aziz N, Bale S, et al. Standards and guidelines for the interpretation of sequence variants: a joint consensus recommendation of the American College of Medical Genetics and Genomics and the Association for Molecular Pathology. *Genet Med*. 2015;17(5):405–424. doi:10.1038/gim.2015.30
14. Groeneweg S, van Geest FS, Abaci A, et al. Disease characteristics of MCT8 deficiency: an international, retrospective, multicentre cohort study. *Lancet Diabetes Endocrinol*. 2020;8(7):594–605. doi:10.1016/S2213-8587(20)30153-4
15. Wang J, Zhang Q, Bao X, Chen Y, Yu S. [Clinical and genetic features of five patients with Allan-Herndon-Dudley syndrome]. *Zhonghua Yi Xue Yi Chuan Xue Za Zhi*. 2018;35(4):484–488. doi:10.3760/cma.j.issn.1003-9406.2018.04.005
16. Tang YL, Peng J, Xiong J, et al. [A family with Allan-Herndon-Dudley syndrome due to SLC16A2 gene mutation]. *Zhonghua Er Ke Za Zhi*. 2018;56(11):829–834. doi:10.3760/cma.j.issn.0578-1310.2018.11.008
17. Chen X, Liu L, Zeng C. A novel variant in SLC16A2 associated with typical Allan-Herndon-Dudley syndrome: a case report. *BMC Pediatr*. 2022;22(1):180. doi:10.1186/s12887-022-03259-5
18. Wang A, Xi J, Yuan F, et al. Generation of an induced pluripotent stem cell line (SHCDNi003-A) from a one-year-old Chinese Han infant with Allan-Herndon-Dudley syndrome. *Stem Cell Res*. 2020;46:101872. doi:10.1016/j.scr.2020.101872
19. La Piana R, Vanasse M, Brais B, Bernard G. Myelination Delay and Allan-Herndon-Dudley syndrome caused by a novel mutation in the SLC16A2 Gene. *J Child Neurol*. 2015;30(10):1371–1374. doi:10.1177/0883073814555189
20. Zhang Q, Yang Q, Zhou X, Qin Z, Yi S, Luo J. Characteristics of Allan-Herndon-Dudley Syndrome in Chinese children: identification of two novel pathogenic variants of the SLC16A2 gene. *Front Pediatr*. 2022;10:1050023. doi:10.3389/fped.2022.1050023
21. Xin Q, Zhao P, Cai C, et al. Identification of a novel SLC16A2 mutation that causes Allan-Herndon-Dudley syndrome. *Tianjin Med J*. 2020;48(2):132–136.
22. Zou P, Huang Y, Huang Z. SLC16A2 gene mutation: a case report and literature review. *Chin J Brain Dis Rehabil*. 2020;10(03):183. doi:10.3877/cma.j.issn.2095-123X.2020.03.012
23. Fen LU, Li Z, Jian T, Al E. Allan-Herndon-Dudley syndrome in 4 cases and literature review. *Chin J Pract Pediatr*. 2022;37(7):532. doi:10.19538/j.ek2022070613
24. Liu Z, Zhao S, Chen J, Ma L, Shi Q, Zhou Y. A novel frameshift mutation in Allan-Herndon-Dudley syndrome. *Int J Legal Med*. 2022;136(4):1181–1187. doi:10.1007/s00414-022-02823-z
25. Rs Y, Tk L, Ch K, et al. Allan-Herndon-Dudley syndrome in Hong Kong: implication for newborn screening. *Int j Clin chem*. 2023:551. doi:10.1016/j.cca.2023.117621
26. Jia QF, Zhou FJ, Cui QY. Allan-herndon-dudley syndrome caused by a novel mutation of SLC16A2 gene: a case report and literature review. *J. Clin. Pediatr*. 2020;12:953. doi:10.3969/j.issn.1000-3606.2020.12.017
27. Felmlee MA, Jones RS, Rodriguez-Cruz V, Follman KE, Morris ME. Monocarboxylate transporters (SLC16): function, regulation, and role in health and disease. *Pharmacol Rev*. 2020;72(2):466–485. doi:10.1124/pr.119.018762
28. Remerand G, Boespflug-Tanguy O, Tonduti D, et al. Expanding the phenotypic spectrum of Allan-Herndon-Dudley syndrome in patients with SLC16A2 mutations. *Dev Med Child Neurol*. 2019;61(12):1439–1447. doi:10.1111/dmen.14332
29. Friesema ECH, Visser WE, Visser TJ. Genetics and phenomics of thyroid hormone transport by MCT8. *mol Cell Endocrinol*. 2010;322(1–2):107–113. doi:10.1016/j.mce.2010.01.016
30. Gregg AR, Aarabi M, Klugman S, et al. Screening for autosomal recessive and X-linked conditions during pregnancy and preconception: a practice resource of the American College of Medical Genetics and Genomics (ACMG). *Genet Med*. 2021;23(10):1793–1806. doi:10.1038/s41436-021-01203-z
31. Lazarin GA, Hawthorne F, Collins NS, Platt EA, Evans EA, Haque IS. Systematic Classification of Disease Severity for Evaluation of Expanded Carrier Screening Panels. *PLoS One*. 2014;9(12):e114391. doi:10.1371/journal.pone.0114391
32. van Geest FS, Groeneweg S, van den Akker ELT, et al. Long-term efficacy of T3 Analogue Triac in Children and adults with MCT8 deficiency: a real-life retrospective Cohort Study. *J Clin Endocrinol Metab*. 2022;107(3):e1136–e1147. doi:10.1210/clinem/dgab750

## Pharmacogenomics and Personalized Medicine

### Publish your work in this journal

Pharmacogenomics and Personalized Medicine is an international, peer-reviewed, open access journal characterizing the influence of genotype on pharmacology leading to the development of personalized treatment programs and individualized drug selection for improved safety, efficacy and sustainability. This journal is indexed on the American Chemical Society's Chemical Abstracts Service (CAS). The manuscript management system is completely online and includes a very quick and fair peer-review system, which is all easy to use. Visit <http://www.dovepress.com/testimonials.php> to read real quotes from published authors.

Submit your manuscript here: <https://www.dovepress.com/pharmacogenomics-and-personalized-medicine-journal>

**Dovepress**  
Taylor & Francis Group