

A Rare Case of Small Bowel Ulceration Induced by COVID-19

Xizhuang Gao^{1,*}, Lihao Shi^{2,*}, Dehuai Jing¹, Cuimei Ma¹, Quanyi Wang³, Jiehuan Wang⁴, Fengqin Zhu¹, Mengmeng Zhao¹, Yun Chen¹, Guangxi Zhou¹ 

¹Department of Gastroenterology, Affiliated Hospital of Jining Medical University, Jining Medical University, Jining, Shandong, 272000, People's Republic of China; ²Cheeloo College of Medicine, Shandong University, Jinan, 250012, People's Republic of China; ³Department of Pathology, Affiliated Hospital of Jining Medical University, Jining Medical University, Jining, Shandong, 272000, People's Republic of China; ⁴Department of Imaging, Affiliated Hospital of Jining Medical University, Jining Medical University, Jining, Shandong, 272000, People's Republic of China

*These authors contributed equally to this work

Correspondence: Guangxi Zhou, Department of Gastroenterology, Affiliated Hospital of Jining Medical University, Jining Medical University, Jining, Shandong, 272000, People's Republic of China, Email zgx_viola@126.com

Background: COVID-19 can affect multiple organ systems beyond the respiratory tract, including the gastrointestinal tract, where gastrointestinal symptoms include nausea, vomiting, diarrhea, abdominal pain, and even serious manifestations such as ulcers, perforation, or gastrointestinal bleeding.

Case Presentation: We report a case of a 45-year-old male patient with small bowel ulcers caused by chronic COVID-19 infection. Initially presenting with fever and transient unconsciousness, he developed ischemic necrosis and required a mid-thigh amputation. Despite treatment with anti-infection therapy, extracorporeal membrane oxygenation, and continuous renal replacement therapy, he experienced persistent abdominal pain and gastrointestinal bleeding. Imaging and colonoscopy confirmed partial small bowel obstruction and inflammation. After treatment with methylprednisolone and enteral nutrition, his symptoms improved. However, he suffered a gastrointestinal perforation requiring emergency surgery and later underwent a successful stoma reversal. The patient was subsequently discharged with improvement and was discharged with a primary diagnosis of “enterostomal status, perforation of small intestinal ulcer, viral myocarditis, COVID-19 infection, and post right lower extremity amputation”. During the past year of follow-up, the patient has not experienced any recurrence of abdominal pain or rectal bleeding.

Conclusion: Although coronavirus pneumonia combined with small bowel ulcers is rare, it requires emergency treatment and has a high mortality rate. This case highlighted the severe gastrointestinal complications induced by COVID-19 infection and the effectiveness of comprehensive management strategies.

Keywords: novel coronavirus, extrapulmonary manifestations, small bowel ulcers

Introduction

Novel Coronavirus Disease (COVID-19) is a disease caused by Severe Acute Respiratory Syndrome Coronavirus 2 (SARS-CoV-2) that has become a global health concern and can cause a range of respiratory symptoms from mild illness to severe pneumonia and respiratory failure.¹ While the main manifestations of SARS-CoV infection primarily involve the respiratory system, emerging evidence suggests that it can potentially affect multiple organ systems, including the gastrointestinal tract.² Among these manifestations, small bowel ulcers are a noteworthy but under-recognized sequela.

COVID-19 can affect the gastrointestinal tract through several mechanisms: firstly, SARS-CoV-2 can directly invade and infect the epithelial cells of the gastrointestinal tract, leading to tissue damage and dysfunction.³ Secondly, the systemic inflammatory response induced by COVID-19 can also lead to gastrointestinal inflammation and mucosal damage.⁴ Finally, it should not be overlooked that COVID-19-induced changes in the composition and function of the gut microbiota may lead to gastrointestinal symptoms and inflammation.⁵ The incidence of gastrointestinal complications, including mesenteric ischaemia, haemorrhage, Ogilvie's syndrome and severe intestinal obstruction, is also higher in critically ill patients hospitalised for

COVID-19.⁶ In the gastrointestinal tract, lingering symptoms of gastrointestinal injury after the subsidence of pulmonary infection may be an important factor in the ongoing development of COVID-19.^{7,8} However, complications of intestinal ulceration due to COVID-19 infection remain unreported. Given these mechanisms, we present a case highlighting the severe gastrointestinal complications, specifically small bowel ulcers, associated with chronic COVID-19 infection.⁹

Case Description

On December 25, 2022, a middle-aged male patient presented with a fever (maximum temperature 37.8°C) and transient unconsciousness without any apparent cause. Initially seen in the neurology department, he was subsequently transferred to the intensive care unit for infectious shock and metabolic acidosis due to a COVID-19 infection. His initial treatment included anti-infection therapy, extracorporeal membrane oxygenation, and continuous renal replacement therapy. During this period, he developed ischemic necrosis of the right lower limb, necessitating a mid-thigh amputation.

On February 3, 2023, the patient exhibited dark red stools but no hematemesis. Laboratory tests showed a continuous decline in hemoglobin level of 73 g/L from the previous level. An abdominal CT scan revealed thickening and roughening of the small intestinal walls, exudation in the right lower abdomen, rectal dilation, and gas-liquid levels (Figure 1A and B). A subsequent colonoscopy confirmed gastrointestinal bleeding (Figure 2), but no apparent cause of bleeding was found. The patient received blood transfusions, octreotide, and acetate hemostasis, which halted the bleeding.

Despite these interventions, the patient continued to experience abdominal pain, primarily around the umbilicus, without nausea or vomiting. A follow-up abdominal CT scan without contrast scan (Figure 1C and D) showed improvements in the terminal ileum's inflammation but also indicated small bowel obstruction and fecaliths. The patient was treated with scopolamine for its antispasmodic and analgesic effects and was discharged on February 18, 2023, after improvement of the condition.

On March 7, 2023, the patient presented to our outpatient clinic with intermittent abdominal pain, predominantly around the umbilicus, characterized by paroxysmal dull pain. A whole abdominal CT scan without contrast revealed thickening and roughening of the terminal ileum wall, with exudates and partial small bowel obstruction (Figure 1E). Laboratory results showed hemoglobin at 86 g/L and C-reactive protein (CRP) at 47 mg/L. A colonoscopy identified small bowel ulcers, and no obvious abnormalities were found in the colon. The endoscope was reached approximately 30 cm from the end of the ileum. We found that the ulcers were circumferential and covered with white moss, from which three biopsies were taken from these ulcers, which were firm in texture. Pathological examination revealed inflammatory granulation tissue, exudation, and necrosis. No abnormalities were seen in the remaining areas (Figure 3). Based on these findings, continued anti-inflammatory (mesalazine) and probiotic supplementation therapy was recommended. Then, the patient was discharged after the symptoms improved.

On April 10, 2023, the patient was readmitted with persistent abdominal pain. Laboratory results showed a hemoglobin of 98 g/L and a CRP of 44.2 mg/L. The test results suggest no specific abnormalities were seen in *Mycobacterium tuberculosis*, *Salmonella*, EBV, and cytomegalovirus. A chest CT scan without contrast did not reveal evidence of tuberculosis infection. Contrast-enhanced CT of the small intestine shows segmental thickening and luminal narrowing of the terminal ileum, with marked mucosal enhancement and a comb-like appearance. Enlarged lymph nodes are nearby, with proximal small bowel dilatation, gas, and residual contents (Figure 4). For further diagnosis, this patient underwent gastroscopy, colonoscopy, and enteroscopy. Gastroscopy and colonoscopy revealed no significant abnormalities. Small bowel endoscopy advanced to approximately 30 cm from the terminal ileum revealed ulcerative lesions with a white coating and additional ulcers at a distance, with circumferential narrowing preventing the endoscope passage. Eight biopsy samples from two ulcerative sites were brittle in texture. Pathological examination showed inflammatory granulation tissue, exudation, necrosis, and chronic inflammatory cell infiltration. No abnormalities were found in the jejunum and upper ileum (Figure 5).

Subsequently, a multidisciplinary team meeting was convened at our hospital, led by Qilu Hospital, including specialists from radiology, pathology, infectious diseases, rheumatology and immunology, hematology, general surgery, and gastroenterology. After a thorough discussion, it was concluded that the patient's condition was unlikely to be due to a tumor. Importantly, the patient did not have a history of NSAID use, and diagnostic imaging (chest CT) and tests (T-spot) effectively excluded tuberculosis and common viral infections such as cytomegalovirus and Epstein-Barr virus.

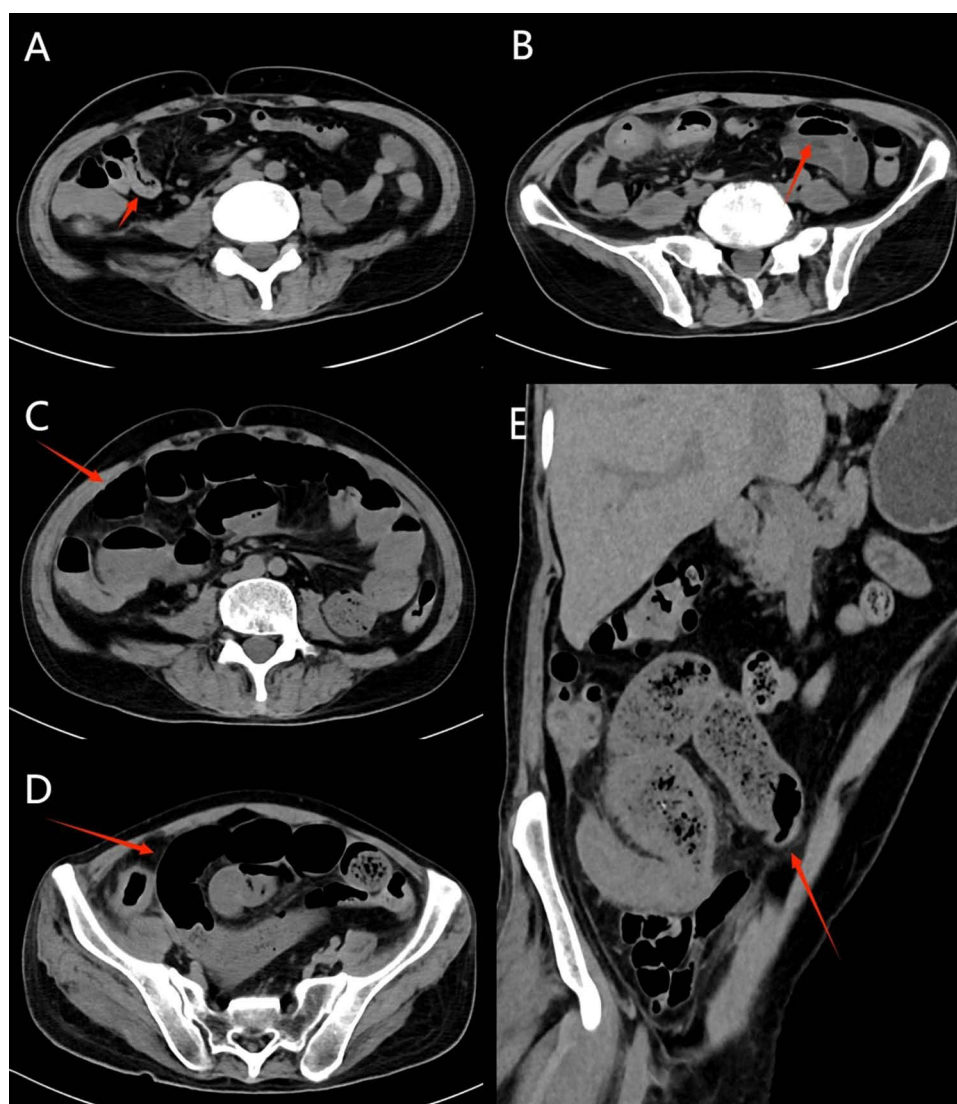

Figure 1 Abdominal CT scans Without Contrast (Total Image). (A and B) Thickening of the small bowel wall with perienteric exudation and rectal dilation (arrows) on February 4, 2024. (C and D) Improvement in terminal ileum inflammation with new small bowel obstruction (arrows) on February 16, 2024. (E) Persistent thickening of the terminal ileum with partial obstruction (arrows) on March 7, 2024.

Abbreviation: CT, computed tomography.

However, given the patient's history of COVID-19, acute inflammation caused by the coronavirus cannot be excluded, nor can immune-mediated bowel involvement relate to COVID-19 infection.¹⁰ Crohn's, Behçet's, and other immune-related disorders cannot be completely ruled out. Diagnostic measures may include corticosteroid therapy to assess response or surgical intervention. Given the complex clinical presentation, the treatment plan involves fasting, enteral nutrition, surgical evaluation, treatment with methylprednisolone, repeated endoscopic assessments, and biopsies. After discussing with the family, the patient received methylprednisolone, calcium supplements, and low-fat enteral nutrition. This regimen reduced CRP levels by 10.1 mg/L and improved abdominal pain symptoms. The patient was stabilized and discharged from the hospital with a primary diagnosis of "multiple ulcers and luminal stenosis of the small bowel, incomplete intestinal obstruction, multiple diverticula of the small bowel, multiple polyps of the colon, and post-treatment viral myocarditis" He was discharged from the hospital on April 30, 2023, with intermittent abdominal pain after discharge, but to an improved extent.

On May 6, 2023, the patient experienced an acute onset of abdominal pain and coma. Emergency diagnostics revealed gastrointestinal perforation, irregular small bowel, and pelvic effusion in the right lower abdomen (Figure 6). Diagnosed with

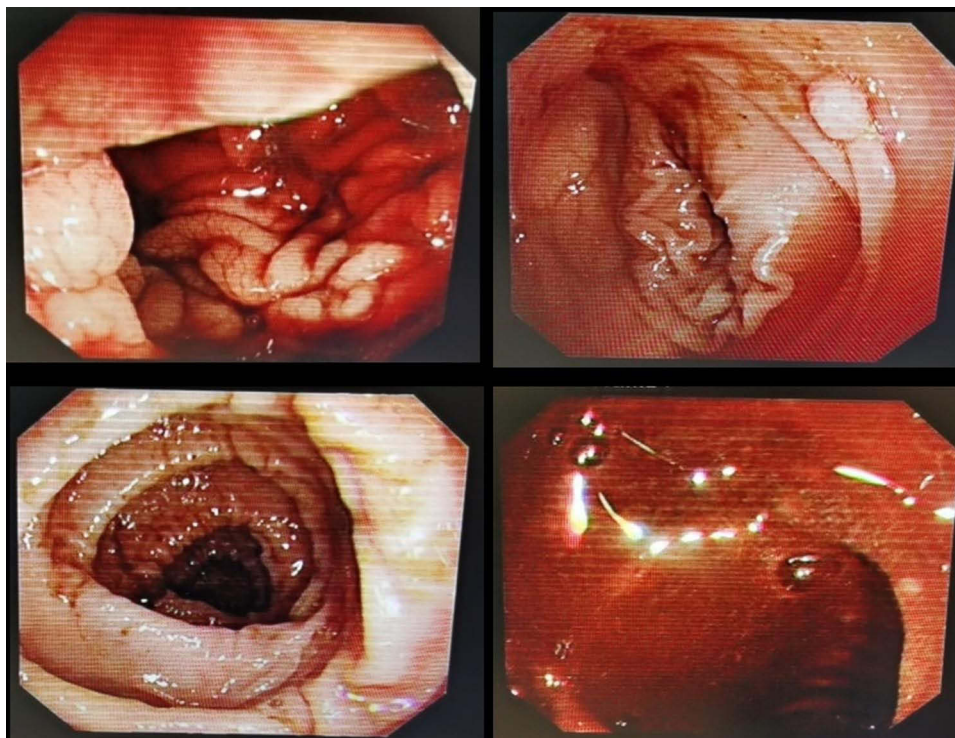


Figure 2 Total colonoscopy images. Colonoscopy showed dark red blood and clots, obscuring the view. No bleeding source was found. Multiple diverticula were noted, with rectal congestion but no active bleeding.

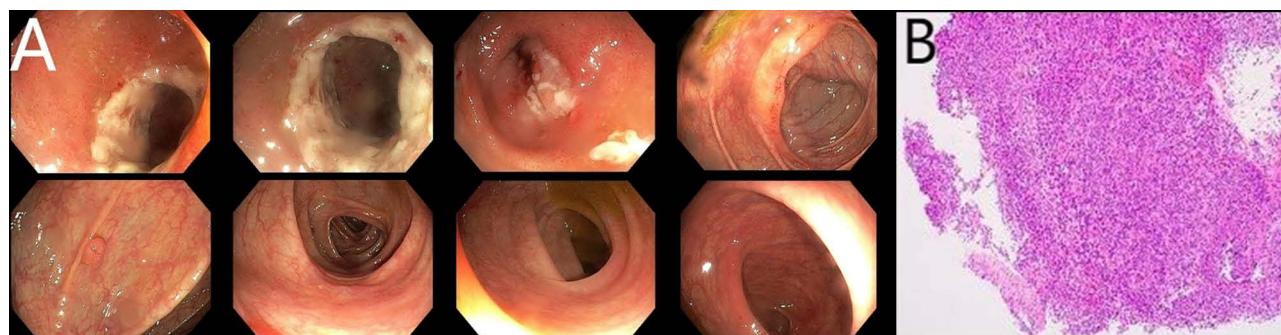


Figure 3 Colonoscopy gross images and pathologic findings. (A) A colonoscopy revealed ring-shaped ulcers 30 cm from the terminal ileum, with additional ulcers and mucosal elevations. (B) Pathological examination revealed inflammatory granulation tissue, exudation, and necrosis.

infectious shock, diffuse peritonitis, and small bowel perforation, he underwent emergency surgery for abdominal abscess drainage, partial small bowel resection, proximal stoma creation, and distal closure. Histopathology of the surgically excised tissue suggested an inflammatory cell infiltration with granulation tissue formation and perforation, accompanied by interstitial vasodilatation (Figure 7). Postoperatively, the patient was treated with imipenem-cilastatin, intravenous fluids, and nutritional support. His condition stabilized post-surgery, and he was advised to undergo stoma reversal.

On August 26, 2023, the patient was readmitted for stoma reversal surgery. Postoperatively, his condition remained stable. Subsequent follow-ups showed significant improvement with no new complications, good wound healing, and stable weight. During the past year of follow-up, the patient has not experienced any recurrence of abdominal pain or rectal bleeding.

Discussion

COVID-19 is an infectious disease caused by SARS-CoV-2, a novel coronavirus. First identified in December 2019 in the Hubei province of China, specifically Wuhan,¹¹ COVID-19 has since precipitated a global pandemic, significantly affecting

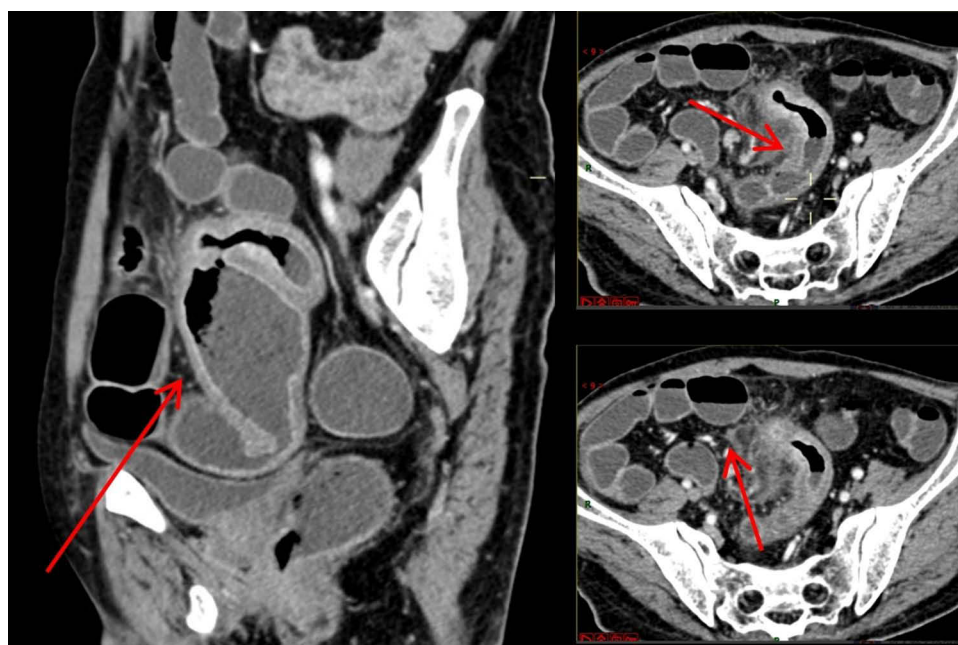


Figure 4 Contrast-enhanced CT of the small intestine images. A contrast-enhanced CT of the small intestine shows thickening and narrowing of the terminal ileum, with marked mucosal enhancement. Enlarged lymph nodes, proximal small bowel dilation, and gas are noted.

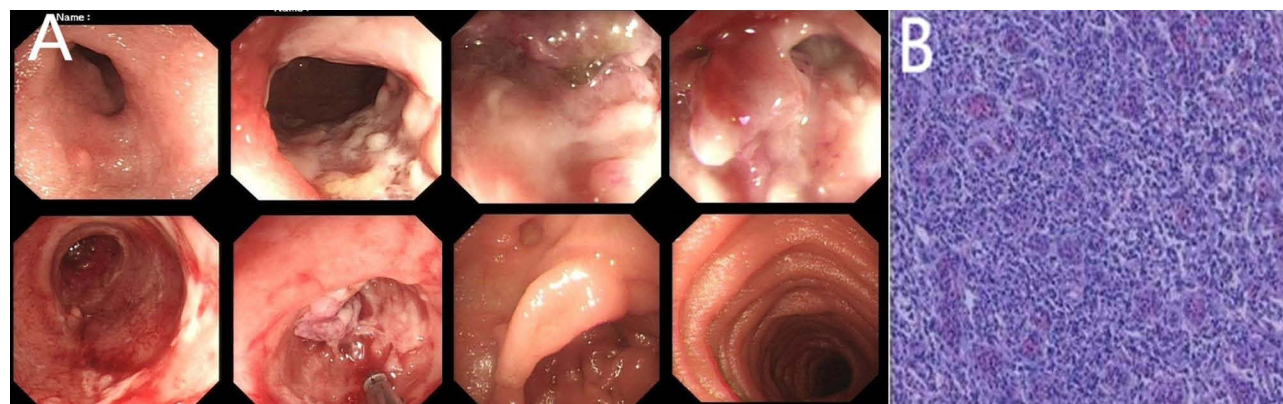


Figure 5 Small bowel endoscopy images. (A) A small bowel endoscopy revealed ulcerative lesions 30 cm from the terminal ileum, obstructing the endoscope. (B) Biopsies showed inflammation, necrosis, and chronic inflammatory cell infiltration.

millions of individuals worldwide regarding health, economic stability, and social dynamics. The clinical spectrum of COVID-19 ranges from asymptomatic or mild respiratory symptoms to severe pneumonia, acute respiratory distress syndrome, and significant morbidity and mortality.¹² Notably, gastrointestinal symptoms such as diarrhea, nausea, and abdominal pain are also common, particularly in severe cases.¹³ The rapid transmission of SARS-CoV-2 has overwhelmed healthcare infrastructures worldwide, postponed elective procedures, including essential gastroenterological services, disrupted economic activities, and triggered profound social and political repercussions.¹⁴

As of June 2024, the World Health Organization (WHO) has reported over 700 million confirmed COVID-19 cases and 10 million deaths globally. These data highlight the continued impact of the pandemic and underscore the ongoing public health crisis. This widespread and rapid virus dissemination has led to unprecedented public health challenges. SARS-CoV-2 primarily spreads through respiratory droplets but can also be transmitted via aerosols and contact with contaminated surfaces, entering the human body predominantly through the respiratory tract. SARS-CoV-2 targets angiotensin-converting enzyme 2 (ACE-2) receptors,¹⁵ which are abundant in lung alveolar epithelial cells and present

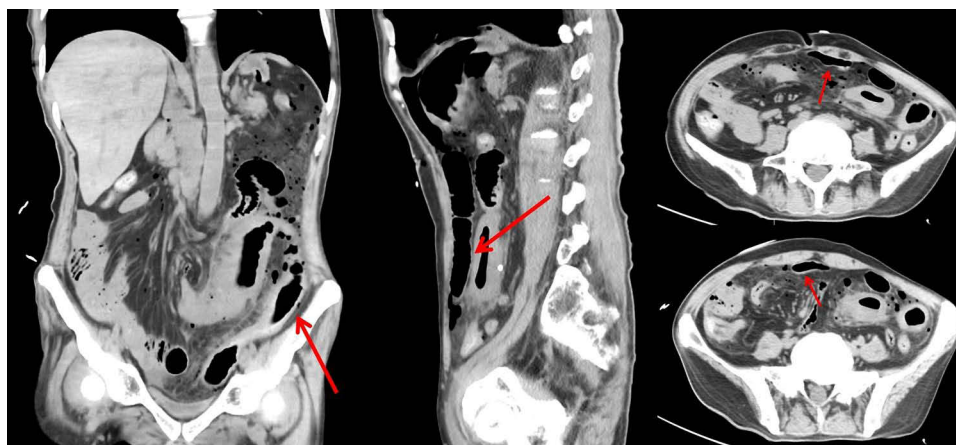


Figure 6 Emergency abdominal CT images. The images reveal gastrointestinal perforation (indicated by arrows), irregular morphology of the small bowel, and pelvic effusion localized in the right lower abdomen on May 6, 2023.

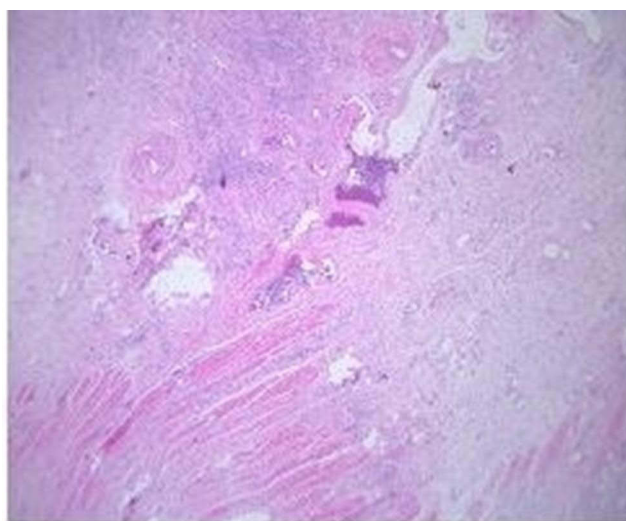

Figure 7 Histopathologic image of surgically removed tissue. The specimen shows inflammation, abscesses, perforation, and serosal necrosis. Both ends are normal, and four perienteric lymph nodes are reactively hyperplastic.

in other organs such as the gastrointestinal tract, heart, and kidneys. This widespread distribution of ACE-2 receptors allows the virus to infect multiple organ systems.¹⁶ The virus's binding solid to ACE-2 facilitates systemic infection, triggering widespread inflammatory responses.¹⁷ This inflammation, often termed a “cytokine storm”, can cause significant damage to lung tissue, leading to conditions such as acute respiratory distress syndrome (ARDS). Additionally, the gastrointestinal tract, liver, and other organs can suffer from inflammation and dysfunction, contributing to the disease's overall severity and complexity.^{18,19}

COVID-19-induced organ damage is complex, involving both direct viral effects and severe systemic inflammation.²⁰ The observed extensive organ damage is thought to result from a hyperinflammatory response, with upregulated T-lymphocytes, macrophages, natural killer cells, and cytokines such as GM-CSF, IL-2, IL-6, IL-7, IL-10, and TNF- α . This cytokine storm amplifies inflammation, leading to cellular damage, necrosis, and multiorgan failure.²¹ Extensive research has highlighted a significant link between COVID-19 and systemic organ damage, affecting the liver, intestines, and other abdominal and pelvic organs.²² This is due to the virus's ability to bind to ACE-2 receptors, found not only in lung alveolar cells but also gastrointestinal epithelial cells, the liver, and other tissues.^{15,23} This binding facilitates local infection and viral replication, leading to cellular damage through direct effects, immune-mediated injury, and apoptosis, causing tissue dysfunction. The gastrointestinal system is notably affected, with symptoms like abdominal pain, bleeding,

diarrhea, and intestinal obstruction.²⁴ Gastrointestinal ulcers may develop due to direct viral invasion, systemic inflammation, or immune responses, causing mucosal injury and ulceration.²⁵

The mechanisms by which COVID-19 causes small intestinal ulcers are complex and varied, mainly involving dysbiosis of the intestinal flora and impairment of the intestinal barrier function, systemic inflammation, and over-activation of the immune system, as well as specific intestinal microbiota related to the severity of the disease. COVID-19 infection leads to the reduction of beneficial flora such as *Faecalibacterium prausnitzii*, weakening intestinal barrier integrity, increasing intestinal permeability, allowing harmful substances to enter the circulation, exacerbating systemic inflammation and directly damaging the intestinal mucosa and forming ulcers.²⁶ In addition, COVID-19 triggers a “cytokine storm” that hyperactivates the immune system and further exacerbates the intestinal inflammatory response. Increases in specific intestinal flora, such as *Ruminococcus torques*, correlate with the severity of COVID-19 and may promote ulcer formation through inflammatory pathways.²⁷ In patients with long COVID, the intestinal dysbiosis, mitochondrial dysfunction, and persistent inflammation caused by the continued presence of the virus make intestinal ulcers a long-lasting and difficult-to-treat digestive problem.²⁸

In this case, the patient initially presented with a severe systemic infection response, and the small intestine ulcer was discovered after the diagnosis of COVID-19. This aligns with our understanding of the process, where the virus’s high affinity for ACE-2 receptors facilitates systemic infection, subsequently triggering a cytokine storm.²⁹ This is characterized by the rapid release of large quantities of pro-inflammatory cytokines and chemokines, leading to immune system dysregulation, further causing tissue damage and multi-organ dysfunction.³⁰ Despite receiving anti-inflammatory treatment, including corticosteroid therapy, the patient continued to experience persistent ulcer-related symptoms. It is noteworthy that these symptoms resolved only after enteral nutritional therapy and, in conjunction with the patient’s history of COVID-19 infection, it can be considered that the etiology of the ulcer is more closely related to viral infection rather than a simple inflammatory mechanism.³¹

This case is significant as it highlights the complex interplay between COVID-19 and gastrointestinal complications, specifically the development of small intestinal ulcers. While gastrointestinal symptoms in COVID-19 patients, such as diarrhea and abdominal pain, are well-documented, the occurrence of severe gastrointestinal complications, including ulceration, remains less frequently reported. In comparison to previously documented cases of COVID-19-related gastrointestinal complications, such as intestinal ischemia and necrosis, our case presents a unique perspective. For instance, Gartland and Velmahos reported cases of intestinal necrosis associated with COVID-19, emphasizing the potential for severe outcomes if not addressed promptly.³⁰ Without timely and appropriate surgical intervention, intestinal ulcers can progress to necrosis, significantly increasing the mortality rate.^{32,33} Furthermore, while some studies have focused on the direct effects of the virus on the gastrointestinal tract, our case underscores the importance of recognizing the potential for immune-mediated injury and the role of dysbiosis in ulcer formation. The patient’s persistent symptoms, despite anti-inflammatory treatment, and the resolution of these symptoms following enteral nutritional therapy, suggest a complex etiology that intertwines viral infection, systemic inflammation, and microbiota alterations.

By comparing our findings with existing literature, we aim to emphasize the novelty of this case and its implications for clinical practice. It serves as a reminder of the importance of vigilant monitoring for gastrointestinal complications in COVID-19 patients, as these conditions can present unique diagnostic and therapeutic challenges. This case contributes to the growing body of evidence that highlights the need for a multidisciplinary approach to managing COVID-19-related complications, particularly in patients presenting with gastrointestinal symptoms.

Conclusion

Although coronavirus pneumonia combined with small bowel ulcers is rare, it requires emergency treatment and has a high mortality rate. This case highlighted the severe gastrointestinal complications associated with COVID-19 infection and the effectiveness of comprehensive management strategies. Given the complexity of such cases, early detection and prompt intervention are crucial in improving patient outcomes. Future clinical implications include the need for heightened awareness among healthcare providers regarding gastrointestinal symptoms in COVID-19 patients, as well as the implementation of preventive measures, such as regular gastrointestinal assessments and close monitoring for potential complications. This proactive approach can help mitigate the risks associated with COVID-19 and enhance overall patient care.

Data Sharing Statement

The data that support the findings of this study are available on request from the corresponding author.

Ethical Approval Statement

The study received approval from the ethics committees of the Affiliated Hospital of Jining Medical University (2021-09-C002). Participant's written informed consent was obtained from the patients and patient's next of kin.

Author Contributions

All authors made a significant contribution to the work reported, whether that is in the conception, study design, execution, acquisition of data, analysis and interpretation, or in all these areas; took part in drafting, revising or critically reviewing the article; gave final approval of the version to be published; have agreed on the journal to which the article has been submitted; and agree to be accountable for all aspects of the work.

Funding

This work was supported by grants from the Tai Shan Young Scholar Foundation of Shandong Province (tsqn202103190), the National Natural Science Foundation of China (82270562, 82200591), Medical and Health Technology Project in Shandong Province (2023BJ000046), TCM science and technology development plan of Shandong Province (M-2023173), Key R&D Program of Jining City (2023 YXNS 086).

Disclosure

The authors declare that there are no conflicts of interest for this work.

References

- Guan WJ, Ni Z-Y, Hu Y, et al. Clinical characteristics of coronavirus disease 2019 in China. *N Engl J Med*. 2020;382:1708–1720. doi:10.1056/NEJMoa2002032
- Gu J, Han B, Wang J. COVID-19: gastrointestinal manifestations and potential fecal-oral transmission. *Gastroenterology*. 2020;158:1518–1519. doi:10.1053/j.gastro.2020.02.054
- Atasoy H, Ucar V. Gastrointestinal system involvement characteristics in Covid -19 patients. *J Pak Med Assoc*. 2025;75:224–231. doi:10.47391/jpma.11349
- Pu Z, Li L, Zhang Y, et al. Exploring the therapeutic potential of HAPC in COVID-19-induced acute lung injury. *Phytomedicine*. 2025;139:156563. doi:10.1016/j.phymed.2025.156563
- Scalzo PL, Marshall AG, Soriano S, et al. Gut microbiome dysbiosis and immune activation correlate with somatic and neuropsychiatric symptoms in COVID-19 patients. *J Transl Med*. 2025;23:327. doi:10.1186/s12967-025-06348-y
- Endo K, Satoh T, Yoshino Y, et al. A case of relapsed pan-colonic ulcerative colitis accompanied with gastroduodenal lesions immediately after COVID-19. *Clin J Gastroenterol*. 2025. doi:10.1007/s12328-025-02107-0
- Zhang D, Stein R, Lu Y, et al. Pediatric gastrointestinal tract outcomes during the postacute phase of COVID-19. *JAMA Network Open*. 2025;8:e2458366. doi:10.1001/jamanetworkopen.2024.58366
- Lima RAC, Blaser AR, Ramalho JFP, et al. Prognostic significance of gastrointestinal dysfunction in critically ill patients with COVID-19. *Crit Care Sci*. 2024;36:e20240020en. doi:10.62675/2965-2774.20240020-en
- Williams BS, Huynh TA, Mahmoud AG. Duodenal, and small bowel emergencies. *Surg Clin North Am*. 2023;103:1097–1112. doi:10.1016/j.suc.2023.05.012
- Wagner A, Zandanell S, Kiesslich T, et al. Systematic review on optical diagnosis of early gastrointestinal neoplasia. *J Clin Med*. 2021;10(13):2794. doi:10.3390/jcm10132794
- Huang C, Wang Y, Li X, et al. Clinical features of patients infected with 2019 novel coronavirus in Wuhan, China. *Lancet*. 2020;395(10223):497–506. doi:10.1016/s0140-6736(20)30183-5
- Wu Z, McGoogan JM. Characteristics of and important lessons from the coronavirus disease 2019 (COVID-19) outbreak in china: summary of a report of 72 314 cases from the Chinese Center for Disease Control and Prevention. *JAMA*. 2020;323:1239–1242. doi:10.1001/jama.2020.2648
- Cheung KS, Hung IFN, Chan PPY, et al. Gastrointestinal MANIFESTATIONS of SARS-CoV-2 infection and virus load in fecal samples from a hong kong cohort: systematic review and meta-analysis. *Gastroenterology*. 2020;159:81–95. doi:10.1053/j.gastro.2020.03.065
- Wang Y, Huang G, Li Z. Prognostic significance of inflammatory biomarkers in patients with breast cancer skeletal metastases. *Cancer Manage Res*. 2020;12:11463–11475. doi:10.2147/cmar.S277291
- Hoffmann M, Kleine-Weber H, Schroeder S, et al. SARS-CoV-2 cell entry depends on ACE2 and TMPRSS2 and is blocked by a clinically proven protease inhibitor. *Cell*. 2020;181:271–280.e278. doi:10.1016/j.cell.2020.02.052
- Flores-Opazo M, McGee SL, Hargreaves M. Exercise and GLUT4. *Exer Sport Sci Rev*. 2020;48:110–118. doi:10.1249/jes.0000000000000224
- Hamming I, Timens W, Bulthuis M, et al. Tissue distribution of ACE2 protein, the functional receptor for SARS coronavirus. A first step in understanding SARS pathogenesis. *J Pathol*. 2004;203:631–637. doi:10.1002/path.1570

18. Huang Q, Wu X, Zheng X, et al. Targeting inflammation and cytokine storm in COVID-19. *Pharmacol Res.* **2020**;159:105051. doi:10.1016/j.phrs.2020.105051
19. Ye Q, Wang B, Mao J. The pathogenesis and treatment of the 'cytokine storm' in COVID-19. *J Infect.* **2020**;80:607–613. doi:10.1016/j.jinf.2020.03.037
20. Ramasamy S, Subbian S. Critical determinants of cytokine storm and type I interferon response in COVID-19 pathogenesis. *Clin Microbiol Rev.* **2021**;34. doi:10.1128/cmr.00299-20
21. Camacho V, Kuznetsova V, Welner RS. Inflammatory cytokines shape an altered immune response during myeloid malignancies. *Front Immunol.* **2021**;12:772408. doi:10.3389/fimmu.2021.772408
22. Vadvala HV, Shan A, Fishman EK, Gawande RS. CT angiography of abdomen and pelvis in critically ill COVID-19 patients: imaging findings and correlation with the CT chest score. *Abdom Radiol.* **2021**;46:3490–3500. doi:10.1007/s00261-021-03164-y
23. Wang W, Xu Y, Gao R, et al. Detection of SARS-CoV-2 in different types of clinical specimens. *JAMA.* **2020**;323:1843–1844. doi:10.1001/jama.2020.3786
24. Mehta P, McAuley DF, Brown M, et al. COVID-19: consider cytokine storm syndromes and immunosuppression. *Lancet.* **2020**;395(10229):1033–1034. doi:10.1016/s0140-6736(20)30628-0
25. Xiao F, Tang M, Zheng X, et al. Evidence for gastrointestinal infection of SARS-CoV-2. *Gastroenterology.* **2020**;158:1831–1833.e1833. doi:10.1053/j.gastro.2020.02.055
26. Zhang F, Lau RI, Liu Q, et al. Gut microbiota in COVID-19: key microbial changes, potential mechanisms and clinical applications. *Nat Rev Gastroenterol Hepatol.* **2023**;20:323–337. doi:10.1038/s41575-022-00698-4
27. Wang M, Zhang Y, Li C, Chang W, Zhang L. The relationship between gut microbiota and COVID-19 progression: new insights into immunopathogenesis and treatment. *Front Immunol.* **2023**;14:1180336. doi:10.3389/fimmu.2023.1180336
28. Li H, Wen J, Zhang X, et al. Large-scale genetic correlation studies explore the causal relationship and potential mechanism between gut microbiota and COVID-19-associated risks. *BMC Microbiol.* **2024**;24:292. doi:10.1186/s12866-024-03423-0
29. Zheng L, Xie J, Liu X, et al. Unveiling the electronic interaction in ZnO/PtO/Pt nanoarrays for catalytic detection of triethylamine with ultrahigh sensitivity. *ACS Appl. Mater. Interfaces.* **2020**;12:46267–46276. doi:10.1021/acsami.0c09130
30. Gartland RM, Velmahos GC. Bowel Necrosis in the Setting of COVID-19. *J Gastrointest Surg.* **2020**;24:2888–2889. doi:10.1007/s11605-020-04632-4
31. Shi L, Chen L, Gao X, et al. Comparison of different sources of mesenchymal stem cells: focus on inflammatory bowel disease. *Inflammopharmacology.* **2024**;32:1721–1742. doi:10.1007/s10787-024-01468-1
32. Fox R. Too much compromise in today's CRISPR pipelines. *CRISPR J.* **2019**;2:143–145. doi:10.1089/crispr.2019.0015
33. Zhang Y, Han C, Li J, et al. Efficacy and safety for Apatinib treatment in advanced gastric cancer: a real world study. *Sci Rep.* **2017**;7:13208. doi:10.1038/s41598-017-13192-8

Journal of Inflammation Research

Publish your work in this journal

The Journal of Inflammation Research is an international, peer-reviewed open-access journal that welcomes laboratory and clinical findings on the molecular basis, cell biology and pharmacology of inflammation including original research, reviews, symposium reports, hypothesis formation and commentaries on: acute/chronic inflammation; mediators of inflammation; cellular processes; molecular mechanisms; pharmacology and novel anti-inflammatory drugs; clinical conditions involving inflammation. The manuscript management system is completely online and includes a very quick and fair peer-review system. Visit <http://www.dovepress.com/testimonials.php> to read real quotes from published authors.

Submit your manuscript here: <https://www.dovepress.com/journal-of-inflammation-research-journal>

Dovepress
Taylor & Francis Group