


Treatment Strategies for Distal Clavicle Fractures: A Narrative Review

Lei Yue ^{*}, Changsheng Huang^{*}, Jianming Zhang, Ziqi Wang, Shijun Wang, Haolin Sun 

Department of Orthopedics, Peking University First Hospital, Beijing, People's Republic of China

^{*}These authors contributed equally to this work

Correspondence: Haolin Sun, Department of Orthopedics, Peking University First Hospital, 8 Xishiku Street, Xicheng District, Beijing, 100034, People's Republic of China, Email sunhaolin@vip.163.com

Abstract: Distal clavicle fractures, accounting for a significant portion of clavicle fractures, present a treatment challenge due to their high non-union rate and the controversy surrounding operative versus non-operative management strategies. This review synthesizes recent studies and clinical evidence to compare the effectiveness of operative and non-operative approaches for distal clavicle fractures. It discusses the anatomical and classification aspects of these fractures, the indications for surgery, and the rationale behind different treatment options. Surgical fixation, predominantly through locking plates or hook plates, generally provides high union rates and stable outcomes; however, complications such as hardware irritation, subacromial impingement, and implant removal rates are significant concerns. Recent surgical advancements, including ligament repair, distal augmentation, and arthroscopic techniques, have shown promise in improving outcomes. Conversely, conservative treatment is recommended for certain fracture types, with emerging evidence suggesting it provides comparable functional outcomes to those of surgical methods. Despite a high non-union rate, non-operative treatment can be effective in restoring functions. However, challenges such as symptomatic nonunion and osteoarthritis are noted. The choice between surgical and conservative treatments depends on multiple factors, including fracture type, patient age, activity level, and overall health status. This review highlights the need for a personalized approach in managing distal clavicle fractures, considering the evolving evidence and advancements in treatment strategies.

Keywords: distal clavicle fracture, surgery, conservative treatment, neer classification

Introduction

Distal clavicle fractures, a common traumatic injury encountered in emergency rooms, account for approximately 10%–30% of all clavicle fractures and represent 2.6%–3.3% of all fractures.^{1–3} Distal clavicle fractures typically result from direct or indirect trauma to the shoulder region. The most common injury mechanism reported was a simple fall (57%), followed by a high-energy fall (29%).⁴ Allman classified clavicle fractures into medial, distal, and proximal types based on the anatomic location.⁵ Among all clavicle fractures, those involving the distal segment are often controversial. Distal clavicle fractures are less common than medial clavicle fractures but are more susceptible to high non-union rate (10%–44%) compared with other subtypes, due to the combination of bony and ligamentous injury and the subsequent instability.⁶

The controversy between operative and non-operative treatments for distal clavicle fractures stems from differing perspectives on optimal healing outcomes, risk management, and patient-specific considerations. Multiple studies on distal clavicle fractures have emerged in recent years, and there is an urgent need to summarize these results to guide clinical decisions. In this review, we summarize the updated evidence comparing operative and non-operative approaches for distal clavicle fractures.

Anatomy and Classification

Understanding the precise anatomy and classification of distal clavicle fractures is essential for guiding treatment. The distal clavicle, which articulates laterally with the acromion forming the acromioclavicular (AC) joint, is anatomically

thin and biomechanically vulnerable. Due to its structural characteristics, it is particularly susceptible to fractures when subjected to downward or compressive forces. Its vulnerability directly impacts the stability and function of the shoulder joint, influencing treatment decisions for distal clavicle injuries. The structures that maintain the stability of the AC joint include the AC capsule, the AC ligament, coracoclavicular (CC) ligaments, and coracoacromial (CA) ligaments⁷ (Figure 1). The horizontal stability of the AC joint is mediated by the AC ligament while vertical stability is mediated by the CC ligaments (ie the conoid and trapezoid ligaments).^{8,9} However, the CC ligaments act as a substitute in resisting horizontal forces when the AC ligaments are ruptured.¹⁰

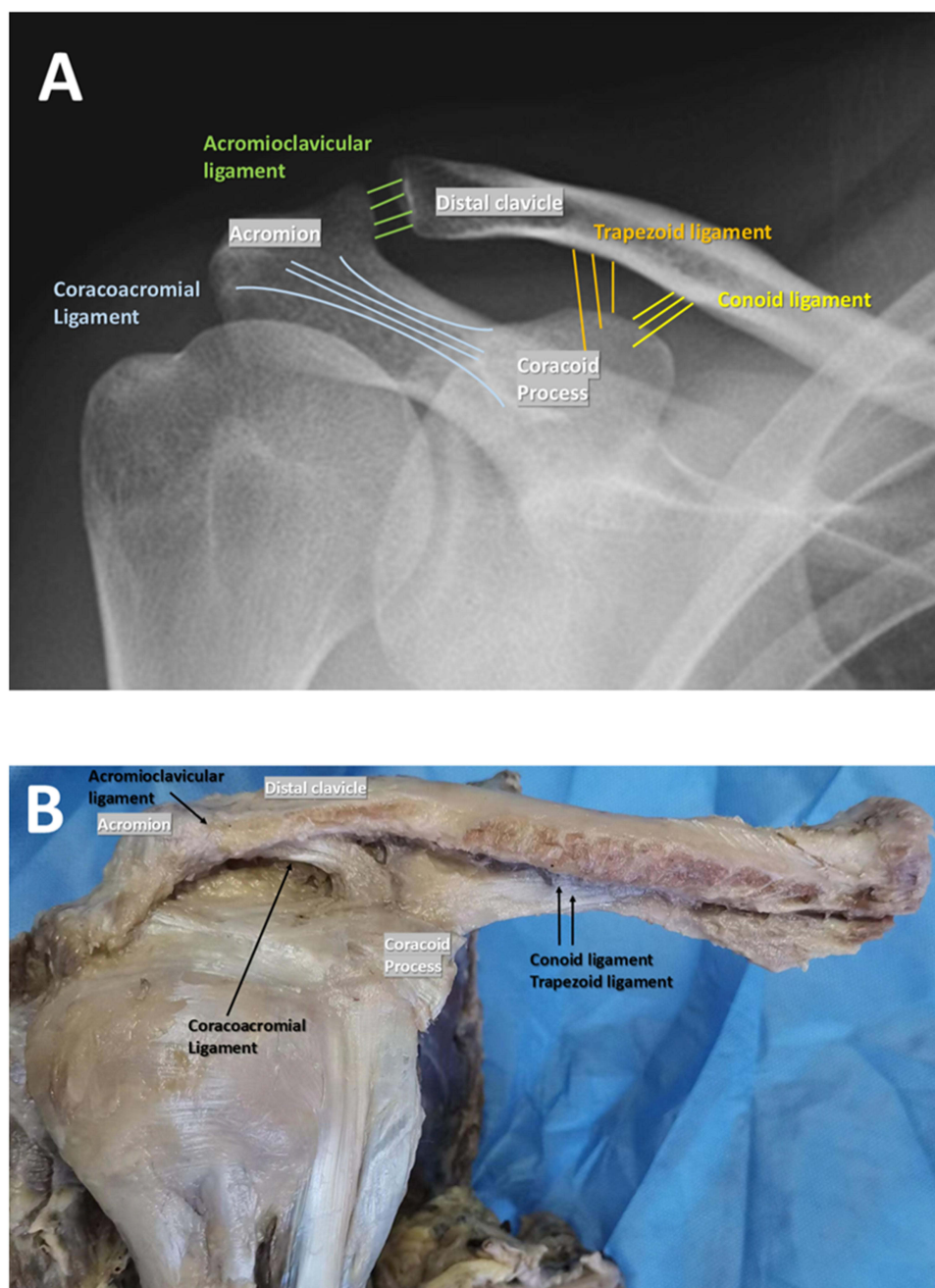


Figure 1 The composition of stability structures of acromioclavicular (AC) joint. (A) shows the clavicular structure under X-ray; (B) shows the related structures of the clavicular ligament on the cadaveric specimen. AC ligament contributes to vertical stability and coracoclavicular (CC) ligaments contribute to horizontal stability. The conoid and trapezoid ligaments compose of the CC ligaments.

In the 1960s, Neer et, al. categorized distal clavicle fractures based on the relationship between fracture line and CC ligaments on plain X-Ray radiographs, and over two decades later Craig et, al modified the Neer classification by considering two additional conditions, ie, periosteal sleeve avulsions and comminuted fractures.^{11,12} Several classification systems for distal clavicle fractures have been described, including the AO classification, Jäger classification, Edinburgh classification, Cho classification, and Xue classification.^{13–16} A summary of these classification methods is provided in Table 1. However, given the widespread use and validation, the modified Neer classification remains the preferred choice for guiding treatment and prognosis.

Radiographic Evaluation of Distal Clavicle Fractures

Standard radiographs, including anteroposterior, axial, and Zanca views, are essential for visualizing the fracture pattern, displacement, and comminution. The Zanca view, a specialized anteroposterior projection with 10–15 degrees of cephalic

Table 1 The Classifications of Distal Clavicle Fracture

Classification	Basis of Classification	Key Features
Neer classification (1963) ¹¹	Relationship of fracture line to coracoclavicular (CC) ligaments and acromioclavicular (AC) joint	Type I: Lateral to CC ligaments; Type II: Medial to CC ligaments; Type III: Involving AC joint
Neer modification (1984) ¹⁷	Included considerations for rare fracture presentations	Added Type IV, involving displacement at the metaphyseal-physeal junction with the epiphysis adjacent to the AC joint, and Type V, characterized by a small inferior clavicular fragment attached to the CC ligaments.
Craig's modification to Neer classification (1990) ¹²	Incorporation of periosteal sleeve avulsions and comminution for Neer Type II	Expanded Neer Type II: periosteal sleeve avulsion (Type IIa) and comminution (Type IIb)
Jäger Classification (1984) ¹⁵	Fracture relation to CC ligament and intactness	Type I: Fracture lateral to intact CC ligaments Type IIa: Fracture at CC ligaments; conoid ligament ruptured, trapezoid ligament intact Type IIb: Fracture at CC ligaments; conoid intact, trapezoid ligament ruptured Type III: Fracture medial to the intact coracoclavicular ligament Type IV: Pediatric periosteal sleeve avulsion; superior displacement of distal fragment
Edinburgh Classification (1998) ¹⁸	Subclassify shaft fractures according to their displacement and degree of comminution	Type 3A1: Non-displaced extra-articular distal clavicle fracture Type 3A2: Non-displaced intra-articular distal clavicle fracture Type 3B1: Displaced extra-articular distal clavicle fracture Type 3B2: Displaced intra-articular distal clavicle fracture
AO Classification (2018) ¹⁹	Based on fracture pattern, anatomical location, and complexity	15.3A: Extra-articular simple fractures 15.3B: Extra-articular wedge fractures 15.3C: Complex intra-articular fractures
Cho Classification (2018) ¹³	Fracture displacement and stability as well as fracture location	Type I fractures: stable and minimally displaced (< 5 mm) Type II fractures involve displacement (≥5 mm)—IIA (fracture medial to the CC ligaments: conoid and trapezoid intact), IIB (fracture medial to the CC ligaments: conoid torn, trapezoid intact), IIC (fracture lateral to the CC ligaments: conoid and trapezoid torn), and IID (comminuted fracture: CC ligaments attached to inferior ligament).
Xue Classification (2024) ¹⁶	Relationship of fracture line to ligament footprints	Type I: Lateral to trapezoid ligament Type II: Between trapezoid and conoid ligament Type III: Medial to conoid ligament

tilt, offers a clear image of the AC joint and distal clavicle, aiding in precise fracture classification.²⁰ Fractures are classified based on their location relative to the CC ligaments, the degree of displacement, presence of comminution, and intra-articular involvement. CT scanning provides better present better visual of shortening, displacement, and progression of union. MRI provides detailed evaluation of soft tissues and fracture stability, aiding accurate diagnosis and optimal treatment planning. However, MRI is not routinely indicated for all distal clavicle fractures but may be valuable in specific circumstances. Indications for MRI evaluation include: (1) suspicion of ligamentous injuries, particularly when clinical or radiographic findings suggest instability not clearly defined by plain radiographs,²¹ and (2) assessment of associated soft-tissue injuries, such as rotator cuff tears, labral tears, or capsular injuries.

Considerations and Complications of Surgical Treatment

Distal clavicle fractures may be treated conservatively or surgically, and the decision in their management is primarily centered around bone healing effectiveness, functional recovery, and complication risks. Generally accepted surgical indications for distal clavicle fractures include unstable fractures without bony contact and all open fractures involving skin compromise or associated neurovascular injury.^{11,22,23}

Neer type II and type V distal clavicle fractures are commonly recognized as indications for surgical treatment. Neer type II fractures are unstable due to detachment of the CC ligaments from the medial fragment, causing unstable displacement. Similarly, Neer type V fractures, characterized by comminution with only a small inferior fragment remaining attached to the CC ligaments, also demonstrate significant instability.²⁴ The primary benefit of surgical intervention is the direct anatomical reduction of the fracture, which can accelerate the bone healing process, facilitate earlier mobilization, and improve the appearance of the shoulder. Evidence reveals that the union rate of surgical intervention is 95%-98.6% for Neer types II and V distal clavicle fractures, significantly higher than that of conservative treatment (69%-70%).²⁵⁻²⁸

Although numerous surgical techniques have been described, plate osteosynthesis using either a locking plate or a hook plate—with or without ligament reconstruction—remains the predominant approach. Currently, there is no consensus regarding the superiority of locking plates versus hook plates. A UK nationwide survey indicated a preference among most surgeons for locking plates (68%), while another nationwide review by Raval et al found greater utilization of hook plates (43%) compared to locking plates (21%).^{4,29} Both locking plates and hook plates demonstrate high fracture union rates, but hook plates have a significantly higher complication rate (40.7%-76.6%) compared to locking plates (23.3%).^{30,31} Additionally, hook plates are associated with inferior functional outcomes and a higher implant removal rate (86.9% versus 27% for locking plates).^{30,32,33} One significant limitation of locking plate systems is the biomechanical requirement for a minimum distal fragment size of 10 mm to ensure secure fixation. This restricts their clinical applicability in fractures characterized by high comminution or osteoporotic bone, especially in periarticular regions where fragment sizes frequently fall below this threshold.³⁴

Conversely, hook plates provide robust mechanical stability by hooking beneath the acromion, allowing fixation of smaller lateral fragments and enhancing vertical stability in cases with associated AC joint dislocation.³⁵ Thus, hook plates have broader indications compared to locking plates. Hook plates also demonstrate lower incidences of AC joint subluxation and implant reduction loss.³⁶ However, hook plates carry substantial drawbacks. The hook frequently irritates subacromial structures, leading to a high incidence of acromial erosion (50%), subacromial impingement syndrome (37.5%), and potential rotator cuff injury (15%).³⁷ Therefore, routine hardware removal is required, making hook plates less suitable for individuals with high functional demands.

Other fixation methods include Kirschner wire fixation combined with CC repair, intramedullary screw fixation, interfragmentary suture fixation, and arthroscopic fixation employing cortical button coracoclavicular stabilization. Additionally, distal augmentation techniques such as distal wire augmentation are utilized.³⁸ These methods, either independently or in conjunction with traditional plate fixation, have demonstrated effectiveness in promoting bone union and reducing complication rates.³⁹⁻⁴¹

Considerations on Conservative Treatment

The operative approach has its drawbacks. A systematic review by Thurston et al reported complications in surgically treated patients, including implant-related pain (14.4%), hardware failure (2.1%), infection (2.1%), scar sensitivity (6.4%), wound issues (8%), nonunion (3.7%), and sensory deficits (2.7%). The overall complication rate was 41.2%, with a reoperation rate of 40.1%.⁴² Even for endoscopic treatment, two meta-analyses showed that the complication rate of arthroscopic intervention for distal clavicle fracture can be up to 27.4%-28.6%.^{43,44} Additionally, there is an inherent risk associated with any surgical procedure, including reactions to anesthesia and the potential for blood loss. Therefore, the decision regarding surgical treatment should be made with caution, taking into consideration factors including age, activity level, comorbidities, and overall health of the patient.

If surgery can be avoided, patients with distal clavicle fractures may benefit from conservative treatment by reducing economic burdens and avoiding surgical complications. Most Neer types III and I distal clavicle fractures, and non-displaced Neer II distal clavicle fractures may be considered for initial conservative treatment.^{6,45} However, whether the non-displaced Neer types II distal clavicle fractures should be conservatively or surgically treated remains controversial.⁴⁵

Recently, evidence has emerged that despite high non-union rate, nonoperative treatment achieves similar functional outcomes and strength to that of surgical procedures.^{25,46-48} Additionally, the meta-analysis by Uittenbogaard et al, showed that only half of the non-unions was symptomatic.⁴⁹ Nonunion in displaced distal clavicle fractures seems to cause minimal functional deficit in some populations, such as elderly sedentary individuals. A simple sling is sufficient for nonoperative management for two weeks for pain control of the fracture, and to initiate passive range of motion exercises simultaneously. Figure-of-eight bracing is not recommended.^{50,51} Radiography may be conditionally repeated within 1 to 2 weeks if fracture stability is uncertain, and routinely repeated at 6 weeks for assessing bony union. Strengthening exercises can be incorporated into physical therapy if signs of radiographic union are captured.⁴⁵

We again emphasize that the choice between operative and non-operative treatment is influenced by patient-specific factors. Younger, more active patients or those with high functional or cosmetic demands might benefit more from surgical intervention due to the importance of quickly restoring function and appearance. In contrast, older patients or those with lower functional demands might be better candidates for non-operative treatment. Common complications of conservative treatment include symptomatic nonunion (15%), osteoarthritis (12%), and impingement syndrome (8%).⁴⁹

Conclusion

In summary, the management of distal clavicle fractures can be challenging because of difficulty in identifying potential fracture instability and balancing the risks and benefits of each approach, tailored to the individual patient's needs. Ongoing studies and advancements in both surgical techniques and conservative management strategies continue to shape the landscape of treatment options, aiming to optimize outcomes for patients suffering from this common orthopedic injury.

Author Contributions

Haolin Sun conceived the overall concept and designed the manuscript outline. Lei Yue and Changsheng Huang contributed to the manuscript design, discussion, and figure preparation. Lei Yue, Ziqi Wang, Shijun Wang, and Jianming Zhang were involved in writing the manuscript and conducting the literature review. All authors made a significant contribution to the work reported, whether that is in the conception, study design, execution, acquisition of data, analysis and interpretation, or in all these areas; took part in drafting, revising or critically reviewing the article; gave final approval of the version to be published; have agreed on the journal to which the article has been submitted; and agree to be accountable for all aspects of the work.

Funding

This work were granted by Taiyuan "Six batches" scientific research projects (Z2023001) and National High Level Hospital Clinical Research Funding - Scientific Research Seed Fund of Peking University First Hospital (2023SF52).

Disclosure

Lei Yue and Changsheng Huang are co-first authors for this study. The authors report no potential conflicts of interest to this work.

References

- Postacchini F, Gumina S, De Santis P, et al. Epidemiology of clavicle fractures. *J Shoulder Elbow Surg.* 2002;11(5):452–456. doi:10.1067/mse.2002.126613
- Court-Brown CM, Caesar B. Epidemiology of adult fractures: a review. *Injury.* 2006;37(8):691–697. doi:10.1016/j.injury.2006.04.130
- Liu ZQ, Zhang M-S, Zhou Z-F, et al. Comparative study of three different fixation techniques for the treatment of Neer type IIb distal clavicle fractures: a retrospective cohort study. *Front Surg.* 2023;10:1100720. doi:10.3389/fsurg.2023.1100720
- Raval P, See A, Singh HP. Distal third clavicle fractures: a nationwide trainee-led collaborative review of current practice. *Bone Jt Open.* 2022;3(12):953–959. doi:10.1302/2633-1462.312.BJO-2022-0061.R1
- Allman FL Jr. Fractures and ligamentous injuries of the clavicle and its articulation. *J Bone Joint Surg Am.* 1967;49(4):774–784. doi:10.2106/00004623-196749040-00024
- Banerjee R, Waterman B, Padalecki J, et al. Management of distal clavicle fractures. *J Am Acad Orthop Surg.* 2011;19(7):392–401. doi:10.5435/00124635-201107000-00002
- Culham E, Peat M. Functional anatomy of the shoulder complex. *J Orthop Sports Phys Ther.* 1993;18(1):342–350. doi:10.2519/jospt.1993.18.1.342
- Saccomanno MF, C DEI, Milano G. Acromioclavicular joint instability: anatomy, biomechanics and evaluation. *Joints.* 2014;2(2):87–92. doi:10.11138/jts/2014.2.2.087
- Lee K-W, Debski RE, Chen C-H, et al. Functional Evaluation of the Ligaments at the Acromioclavicular Joint during Anteroposterior and Superiorinferior Translation. *Am J Sports Med.* 1997;25(6):858–862. doi:10.1177/036354659702500622
- Minkus M, Wieners G, Maziak N, et al. The ligamentous injury pattern in acute acromioclavicular dislocations and its impact on clinical and radiographic parameters. *J Shoulder Elbow Surg.* 2021;30(4):795–805. doi:10.1016/j.jse.2020.10.026
- Neer CS. Fractures of the distal third of the clavicle. *Clin Orthop Relat Res.* 1968;58:43–50. doi:10.1097/00003086-196805000-00007
- Craig EJT. Fracture of the clavicle. *shoulder.* 1990;367–412.
- Cho C-H, Kim BS, Kim DH, Choi CH, Dan J, Lee H, et al. Distal clavicle fractures: a new classification system. *Orthopaedics & Traumatology.* 2018;104(8):1231–1235.
- Nambiar M, West LR, Bingham R. AO surgery reference: a comprehensive guide for management of fractures. *Br J Sports Med.* 2017;51(6):545–546. doi:10.1136/bjsports-2016-096677
- Jäger M, Breiter S. Therapy related classification of lateral clavicular fracture. *Unfallheilkunde.* 1984;87(11):467–473.
- Xue C, Yang W, Rui Y, et al. A new classification system for distal clavicle fractures: based on fracture location and ligament integrity. *Arch Orthop Trauma Surg.* 2024;145(1):8. doi:10.1007/s00402-024-05633-7
- Rockwood C. Subluxations and dislocations about the shoulder. *Fractures.* 1984;1:910–948.
- Robinson CM. Fractures of the clavicle in the adult. *Epidemiology and Classification J Bone Joint Surg Br.* 1998;80(3):476–484. doi:10.1302/0301-620X.80B3.0800476
- Clavicle. *J Orthop Trauma.* 2018;32 Suppl 1:S105. PMID: 29256958. doi:10.1097/BOT.0000000000001056
- Murphy A, Ismail BD, et al. Acromioclavicular joint (Zanca view).
- Fleischhacker E, Siebenbürger G, Gleich J, et al. The accuracy of distal clavicle fracture classifications-do we need an amendment to imaging modalities or fracture typing? *J Clin Med.* 2022;11(19):5638. doi:10.3390/jcm11195638
- Khan LA, Bradnock TJ, Scott C, et al. Fractures of the clavicle. *J Bone Joint Surg Am.* 2009;91(2):447–460. doi:10.2106/JBJS.H.00034
- Kim DW, Kim D-H, Kim B-S, et al. Current concepts for classification and treatment of distal clavicle fractures. *Clin Orthop Surg.* 2020;12(2):135–144. doi:10.4055/cios20010
- Ochen Y, Frima H, Houwert RM, et al. Surgical treatment of neer type II and type V lateral clavicular fractures: comparison of hook plate versus superior plate with lateral extension: a retrospective cohort study. *Eurn J of Orthop Surg and Traumatol.* 2019;29(5):989–997. doi:10.1007/s00590-019-02411-9
- Hall JA, Schemitsch CE, Vicente MR, et al. Operative versus nonoperative treatment of acute displaced distal clavicle fractures: a multicenter randomized controlled trial. *J of Orthop Trauma.* 2021;35(12):660–666. doi:10.1097/BOT.0000000000002211
- Singh A, Schultzel M, Fleming JF, et al. Complications after surgical treatment of distal clavicle fractures. *Orthop Traumatol Surg Res.* 2019;105(5):853–859. doi:10.1016/j.otsr.2019.03.012
- Deafenbaugh MK, Dugdale TW, Staeheli JW, et al. Nonoperative treatment of Neer type II distal clavicle fractures: a prospective study. *Contemp Orthop.* 1990;20(4):405–413.
- Uittenbogaard SJ, van Es LJM, den Haan C, et al. Outcomes, union rate, and complications after operative and nonoperative treatments of neer type II distal clavicle fractures: a systematic review and meta-analysis of 2284 patients. *Am J Sports Med.* 2021;51(2):534–544. doi:10.1177/03635465211053336
- Sharma V, Modi A, Armstrong A, et al. The management of distal clavicle fractures - a survey of UK shoulder and elbow surgeons. *Cureus.* 2021;13(8):e17305. doi:10.7759/cureus.17305
- Patel R, Khan MM, Gibson W, et al. Comparison of hook plates vs. locking plates for Neer type IIB fractures of lateral end clavicle: a systematic review. *Chin J Traumatol.* 2025. doi:10.1016/j.cjtee.2024.03.012
- Oh JH, Kim SH, Lee JH, et al. Treatment of distal clavicle fracture: a systematic review of treatment modalities in 425 fractures. *Arch Orthop Trauma Surg.* 2011;131(4):525–533. doi:10.1007/s00402-010-1196-y
- Takahashi H, Takegami Y, Tokutake K, et al. <Editors' Choice> Hook plate fixation versus locking plate fixation for distal clavicle fracture: a multicenter propensity score-matched study. *Nagoya J Med Sci.* 2023;85(2):223–232. doi:10.18999/nagjms.85.2.223
- Li L, Li T-Y, Jiang P, et al. Clavicle hook plate versus distal clavicle locking plate for Neer type II distal clavicle fractures. *J Orthop Surg Res.* 2019;14(1):472. doi:10.1186/s13018-019-1518-x

34. Sheth MM, Shybut TB. Operative management for displaced distal clavicle fractures. *Clin Sports Med.* 2023;42(4):695–711.
35. Shaty W. The results of hook plate fixation in acute acromioclavicular joint dislocation and distal clavicle fractures. *Orthop Rev.* 2024;16:120306. doi:10.52965/001c.120306
36. Elrih M, Quinlan J. hook plate versus distal locking plate for the fixation of unstable distal clavicle injuries, outcomes and complications: a meta-analysis. *Cureus.* 2022;14(10):e30806. doi:10.7759/cureus.30806
37. Lin HY, Wong P-K, Ho W-P, et al. Clavicular hook plate may induce subacromial shoulder impingement and rotator cuff lesion--dynamic sonographic evaluation. *J Orthop Surg Res.* 2014;9:6. doi:10.1186/1749-799X-9-6
38. Duralde XA, Pennington SD, Murray DH. Interfragmentary suture fixation for displaced acute type II distal clavicle fractures. *J Orthop Trauma.* 2014;28(11):653–658. doi:10.1097/BOT.000000000000122
39. Kraus N, Stein V, Gerhardt C, et al. Arthroscopically assisted stabilization of displaced lateral clavicle fractures with coracoclavicular instability. *Arch Orthop Trauma Surg.* 2015;135(9):1283–1290. doi:10.1007/s00402-015-2271-1
40. Cho CH, Jung JH, Kim BS. Coracoclavicular stabilization using a suture button device for Neer type IIB lateral clavicle fractures. *J Shoulder Elbow Surg.* 2017;26(5):804–808. doi:10.1016/j.jse.2016.09.048
41. Yagnik GP, Brady PC, Zimmerman JP, et al. A biomechanical comparison of new techniques for distal clavicular fracture repair versus locked plating. *J Shoulder Elbow Surg.* 2019;28(5):982–988. doi:10.1016/j.jse.2018.11.041
42. Thurston D, Jordan RW, Thangarajah T, et al. Are displaced distal clavicle fractures associated with inferior clinical outcomes following nonoperative management? A systematic review. *J Shoulder Elbow Surg.* 2024;33(8):1847–1857. doi:10.1016/j.jse.2023.12.006
43. Malik SS, Tahir M, Malik S, et al. Arthroscopically assisted coraco-clavicular ligament reconstruction in treatment of acute displaced distal clavicle fractures provides good to excellent shoulder function despite low union rates and high complication rates: a systematic review. *Arthroscopy.* 2022;38(2):567–582. doi:10.1016/j.arthro.2021.06.034
44. Yagnik GP, Seiler JR, Vargas LA, et al. Outcomes of arthroscopic fixation of unstable distal clavicle fractures: a systematic review. *Orthop J Sports Med.* 2021;9(5):23259671211001773. doi:10.1177/23259671211001773
45. Lian J, Chan FJ, Levy BJ. Classification of Distal Clavicle Fractures and Indications for Conservative Treatment. *Clin Sports Med.* 2023;42(4):685–693. doi:10.1016/j.csm.2023.05.007
46. Srinivasan A, Haque A, Kheiran A, et al. Radiological and long-term functional outcomes of displaced distal clavicle fractures. *J Orthop Trauma.* 2023;37(2):89–95. doi:10.1097/BOT.0000000000002485
47. Rokito AS, Zuckerman JD, Shaari JM, et al. A comparison of nonoperative and operative treatment of type II distal clavicle fractures. *Bull Hosp Jt Dis.* 2002;61(1–2):32–39.
48. Chen NC. In patients with displaced type-II distal clavicle fractures, operative and nonoperative therapies did not differ for functional outcomes at 1 year. *J Bone Joint Surg Am.* 2022;104(16):1503. doi:10.2106/JBJS.22.00484
49. Uittenbogaard SJ, van Es LJM, den Haan C, et al. Outcomes, Union rate, and complications after operative and nonoperative treatments of neer Type ii distal clavicle fractures: a systematic review and meta-analysis of 2284 patients. *Am J Sports Med.* 2023;51(2):534–544.
50. Andersen K, Jensen PØ, Lauritzen J. Treatment of clavicular fractures: figure-of-eight bandage versus a simple sling. *Acta Orthop Scand.* 1987;58(1):71–74. doi:10.3109/17453678709146346
51. Ersen A, Atalar AC, Birisik F, et al. Comparison of simple arm sling and figure of eight clavicular bandage for midshaft clavicular fractures: a randomised controlled study. *Bone Joint J.* 2015;97(11):1562–1565. doi:10.1302/0301-620X.97B11.35588

Orthopedic Research and Reviews

Publish your work in this journal

Orthopedic Research and Reviews is an international, peer-reviewed, open access journal that focusing on the patho-physiology of the musculoskeletal system, trauma, surgery and other corrective interventions to restore mobility and function. Advances in new technologies, materials, techniques and pharmacological agents are particularly welcome. The manuscript management system is completely online and includes a very quick and fair peer-review system, which is all easy to use. Visit <http://www.dovepress.com/testimonials.php> to read real quotes from published authors.

Submit your manuscript here: <https://www.dovepress.com/orthopedic-research-and-reviews-journal>

Dovepress
Taylor & Francis Group