

Dissecting Cellulitis of the Scalp Successfully Treated with a Combination of Ixekizumab and Tofacitinib

Miaoqi Qiu, Xiaoyong Man, Jing Jing

Department of Dermatology, Second Affiliated Hospital, Zhejiang University School of Medicine, Hangzhou, People's Republic of China

Correspondence: Jing Jing, Department of Dermatology, Second Affiliated Hospital, Zhejiang University School of Medicine, Hangzhou, People's Republic of China, 88th Jiefang Road, Tel +86-13758189389, Email haitong1987@163.com

Aim: Dissecting Cellulitis of the Scalp (DCS) is a rare form of neutrophilic primary cicatricial alopecia (PCA). It usually occurs in black males and is less commonly reported in Asian populations. There are no systematic treatment guidelines for this disease, the hypothetical co-pathogenesis of DCS and hidradenitis suppurativa (HS) has led to the fact that most of the current biological therapies for DCS are based on the experience of HS, such as biologics and JAK inhibitors. Both agents alone have been reported in the treatment of HS and DCS, but the efficacy is uncertain. For severely refractory DCS, the combination of biologics and Janus kinase inhibitors (JAKi) may be a new strategy. In this case, we describe a 28-year-old Chinese young man with a confirmed diagnosis of severe DCS who experienced nodules resolve and hair regrowth after a combination use of ixekizumab and tofacitinib. This is the first case of DCS treated with a combination of IL-17 inhibitors and JAKi.

Purpose: We hope that dermatologists should be aware that early diagnosis of DCS and the application of biologics are essential to quickly control symptoms and prevent from PCA and keloids.

Patients and Methods: This is a patient from the Department of Dermatology, the Second Affiliated Hospital of Zhejiang University School of Medicine.

Keywords: dissecting cellulitis of the scalp, primary cicatricial alopecia, treatment, ixekizumab, tofacitinib

A 28-year-old man presented with multiple painful nodules and alopecia patches on the scalp for 3 years (Figure 1A). Previous treatment included oral and topical antibiotics and traditional Chinese medicine. Physical examination showed fluctuant subcutaneous nodules with patches of alopecia on the vertex, with some of the nodules evolve to abscesses and sinus tracts. And the body mass index of the patient is 32.8. His baseline laboratory examination showed elevated white blood cell count, hyperlipidemia and fatty liver. He also had a history of severe acne (healed after puberty) and smoking. Biopsy of the scalp lesion demonstrated a mixed dermal infiltrate with predominant lymphocytes and numerous plasma cells, and focal areas with neutrophils and multinucleated giant cells. Chronic inflammatory cells extend into hair follicles and subcutaneous tissues, with significant folliculitis and abscess formation (Figure 1C and D). The diagnosis of dissecting cellulitis of the scalp (DCS) was made according to the clinical and histopathologic manifestation. The patient was prescribed 160 mg ixekizumab for the first dose, followed by 80 mg every 2 weeks, combined with oral 10 mg tofacitinib per day, 200 mg doxycycline per day for 10 days then transferred to 20 mg isotretinoin per day. After 3 months, his scalp abscesses and exudate were significantly regressed, and new hair grew. The white blood cells dropped below the normal value. Isotretinoin was stopped, and ixekizumab was reduced to 80 mg per 4 weeks. After 10 months' treatment, most of the nodules disappeared and the dermatology life quality index decreased from 18 to 6 (Figure 1B). No serious adverse events were reported.

DCS is a rare chronic inflammatory skin disease characterized by multiple painful nodules, abscesses, and sinus tracts on the scalp that slowly progress to primary cicatricial alopecia (PCA) and keloids.¹ Trichoscopy shows yellow dots, black dots and exclamation mark hairs in the early stage, similar to alopecia areata. As the disease progresses, follicles

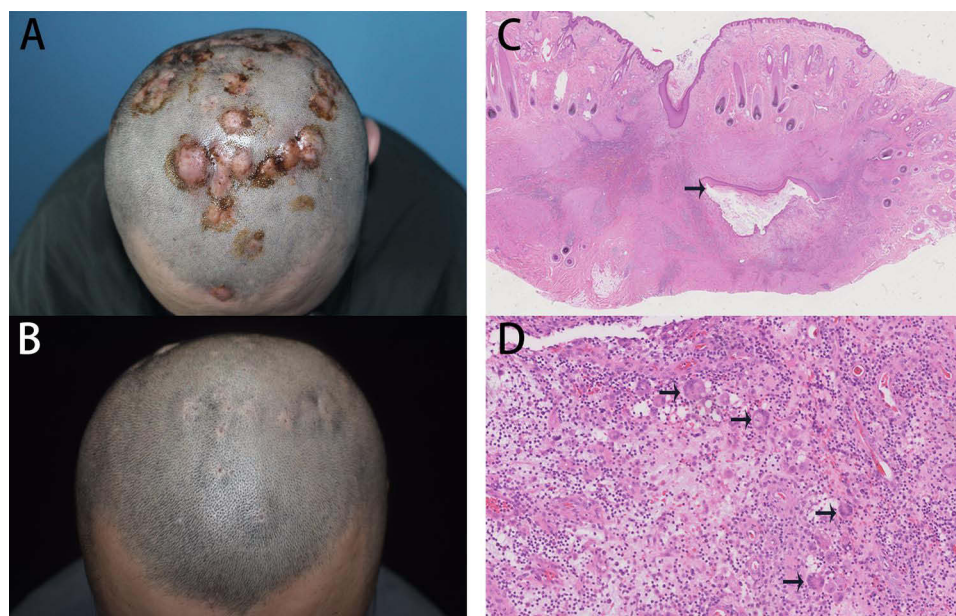


Figure 1 The clinical and histopathologic manifestations for dissecting cellulitis of the scalp. The lesions before treatment (**A**) and the lesions after 10-month-treatment (**B**) Histopathologic manifestations, hematoxylin-eosin staining: 1.25X (**C**), black arrow shows sinus tract; 40X (**D**), back arrows show multinucleated giant cells.

become fibrotic and loss of follicular openings appear. The differential diagnosis includes other scalp nodules or patches of alopecia disease, including mycosis fungoides, tinea capitis and folliculitis decalvans. Early diagnosis and effective treatment are essential to prevent DCS to keloids. The basic treatment, oral antibiotics and isotretinoin, usually achieved partial or complete remission, but frequent relapses after discontinuation.² Most of the novel therapies for DCS are based on the experience of hidradenitis suppurativa (HS), another disease in the same spectrum, including biologics targeting tumor necrosis factor (TNF)- α , interleukin (IL)-17, IL-36, IL-1, and small molecules Janus kinase inhibitors (JAKi).³

The TNF- α inhibitor adalimumab and the IL-17 inhibitor secukinumab are the only two biologics approved for HS, but have shown only moderate efficacy, and there are still one-quarter to one-third of patients do not respond to the treatment.^{4,5} Thus, experts recommend a combination between biologics and other biologics or small molecules to widely cover the pathological processes and rapidly control the inflammation response.⁶ Drugs targeting the IL-17 and JAK pathways are the most advanced in both ongoing and completed Phase 3 studies for HS, the combination of IL-17 inhibitors and JAKi in the treatment of severe HS or DCS is expected to produce a more promising deep response. To the best of our knowledge, two cases of secukinumab^{7,8} and one case of upadacitinib have been reported for the treatment of severe DCS.⁹ We are the first case of DCS treated with the combination of IL-17 inhibitors and JAKi, but there was already case report of a Chinese boy who was successfully treated with adalimumab and baricitinib.¹⁰ IL-17 inhibitors have demonstrated superior efficacy and safety profile in the treatment of psoriasis compared to TNF- α inhibitors, giving us more confidence in their off-label use for other inflammatory skin conditions.

Although the combination of biologics and JAKi were suspected to be associated with a higher risk of adverse events, like infections, tumors,¹¹ our case suggests that with regular follow-up, satisfactory clinical efficacy can be obtained within a controllable range. This case provides new experience for the management of severe DCS, but larger randomized controlled trials in the future are needed to provide more reliable evidence for the treatment strategy for this disruptive disease.

Acknowledgments

The patient involved in this article has provided written informed consent for the publication of the images and other case details. And the publication of the case has been approved by the Department of Dermatology, the Second Affiliated Hospital of Zhejiang University School of Medicine.

Disclosure

The authors report no conflicts of interest in this work.

References

1. Spitzer L. Dermatitis follicularis et perifollicularis conglobata. *Dermatology*. 1903;10(2):109–120. doi:10.1159/000242207
2. Masson R, Jeong CY, Ma E, et al. Treatments for dissecting cellulitis of the scalp: a systematic review and treatment algorithm. *Dermatol Ther*. 2023;13(11):2487–2526. doi:10.1007/s13555-023-01018-7
3. Mansilla-Polo M, Escutia-Muñoz B, Botella-Estrada R. Narrative review and update on biologic and small molecule drugs for hidradenitis suppurativa: an entity with a promising future. *Actas Dermosifiliogr*. 2023;114(9):T772–T783. doi:10.1016/j.ad.2023.08.001
4. Kashetsky N, Mufti A, Alabdulrazzaq S, et al. Treatment outcomes of IL-17 inhibitors in hidradenitis suppurativa: a systematic review. *J Cutan Med Surg*. 2022;26(1):79–86. doi:10.1177/12034754211035667
5. Shih T, Lee K, Grogan T, De DR, Shi VY, Hsiao JL. Infliximab in hidradenitis suppurativa: a systematic review and meta-analysis. *Dermatol Ther*. 2022;35(9):e15691. doi:10.1111/dth.15691
6. Maronese CA, Moltrasio C, Genovese G, Marzano AV. Biologics for Hidradenitis suppurativa: evolution of the treatment paradigm. *Expert Rev Clin Immunol*. 2024;20(5):525–545. doi:10.1080/1744666X.2023.2298356
7. Schettini N, Marzola E, Pacetti L, Cavaliere S, Bettoli V. A case of dissecting cellulitis of the scalp, hidradenitis suppurativa, and conglobate acne successfully treated with secukinumab. *Skin Appendage Disord*. 2024;10(3):232–235. doi:10.1159/000537914
8. De Bedout V, Harper H, Miteva M, Lev-Tov H. Treatment dissecting cellulitis of the scalp with secukinumab. *J Drugs Dermatol*. 2021;20(7):776–777. doi:10.36849/JDD.5615
9. Islam Z, Toker M, Gandhi IM, Sher A, Campton K. Improvement of recalcitrant dissecting cellulitis of the scalp after a trial of upadacitinib. *Cureus*. 2024;16:1.
10. Yu Y, Ding X, Guo F, Ze K, Sun X, Li X. Perifolliculitis capitis abscedens et suffodiens treatment with tumor necrosis factor inhibitors and baricitinib: a case report and literature review. *Front Med*. 2023;10:1132574.
11. Mansilla-Polo M, Morgado-Carrasco D. Biologics versus JAK inhibitors. part II: risk of infections. a narrative review. *Dermatol Ther*. 2024;14(8):1983–2038. doi:10.1007/s13555-024-01203-2

Journal of Inflammation Research

Publish your work in this journal

The Journal of Inflammation Research is an international, peer-reviewed open-access journal that welcomes laboratory and clinical findings on the molecular basis, cell biology and pharmacology of inflammation including original research, reviews, symposium reports, hypothesis formation and commentaries on: acute/chronic inflammation; mediators of inflammation; cellular processes; molecular mechanisms; pharmacology and novel anti-inflammatory drugs; clinical conditions involving inflammation. The manuscript management system is completely online and includes a very quick and fair peer-review system. Visit <http://www.dovepress.com/testimonials.php> to read real quotes from published authors.

Submit your manuscript here: <https://www.dovepress.com/journal-of-inflammation-research-journal>

Dovepress
Taylor & Francis Group