

Drug-Induced Uveitis: Patterns, Pathogenesis and Clinical Implications

Lucy M Lu^{1,2}, Vince MT Wilkinson^{1,2}, Rachael L Niederer^{1,2}

¹Department of Ophthalmology, University of Auckland, Auckland, New Zealand; ²Eye Clinic, Greenlane Clinical Centre, Auckland, New Zealand

Correspondence: Rachael L Niederer, Department of Ophthalmology, University of Auckland, Park Road, Grafton, Auckland, New Zealand, Email eye-health@outlook.com

Abstract: Drug-induced uveitis is a recognized but often underdiagnosed cause of ocular inflammation, with an increasing number of systemic and topical medications implicated. The clinical presentation is highly variable, ranging from anterior to posterior uveitis, often mimicking autoimmune or infectious etiologies. This review examines the mechanisms underlying drug-induced uveitis, including immune-mediated reactions, direct toxicity, and idiosyncratic responses. A comprehensive evaluation of specific drug classes is provided, covering topical agents (prostaglandin analogues, brimonidine), intravitreal therapies (anti-VEGF agents, triamcinolone and vancomycin), antimicrobials (cidofovir, rifabutin), bisphosphonates, tumor necrosis factor (TNF) inhibitors, immune checkpoint inhibitors, BRAF and MEK inhibitors, and vaccines. For each category, the review discusses the pathogenesis, frequency of occurrence, clinical presentation, diagnostic approach and management strategies. Diagnosing drug-induced uveitis requires a high index of suspicion and a systemic drug history. A structured approach to differentiating drug-induced uveitis from other inflammatory and infectious causes is outlined, emphasizing the key clinical and imaging features that aid in diagnosis. The expanding list of medications associated with uveitis underscores the need for heightened awareness in patients presenting with ocular inflammation. Establishing causality requires a careful balance of clinical pattern recognition, temporal correlation, and structured assessment tools. Understanding the pathogenesis of drug-induced uveitis not only informs treatment decisions, including whether to discontinue or modify therapy, but also helps refine guidelines for drug safety monitoring. As novel therapies, particularly in oncology, immunomodulation and vaccination, continue to evolve, ongoing research and robust pharmacovigilance efforts will be critical in identifying risks, improving diagnostic accuracy, and optimizing patient care.

Keywords: ocular inflammation, intravitreal injections, bisphosphonates, TNF inhibitor, cancer immunotherapy, vaccines

Introduction

Uveitis, a group of inflammatory conditions affecting the uveal tract, is a significant cause of visual morbidity worldwide.¹ It is estimated to account for up to 10% of vision loss globally, disproportionately affecting individuals of working age, and placing a considerable burden on healthcare systems.^{1,2} Early recognition and management of uveitis are essential to prevent complications such as cataract, glaucoma, and irreversible retinal damage.^{3–5}

Among the numerous etiologies of uveitis, drug-induced uveitis is a rare but important and potentially modifiable cause. Drug-induced uveitis accounts for approximately 0.38–1.4% of all uveitis cases and is associated with a range of systemic and topical medications.^{6–9} Unlike many other forms of uveitis, the risk of ongoing disease activity in drug-induced uveitis can often be mitigated through early detection and medication optimization with the prescribing physician.

Drug-induced ocular inflammation became more widely recognized in the 1990s following the use of rifabutin and cidofovir in AIDS patients.⁶ In recent years, the emergence of novel intravitreal medications, immunotherapies and vaccines have led to more reports of drug-induced uveitis. Common medications implicated include systemic agents such as bisphosphonates, immune checkpoint inhibitors, antibiotics, and antiviral therapies.^{7,10} Additionally, some topical agents, such as prostaglandin analogues used in glaucoma therapy, are known to provoke uveitis in susceptible

individuals.¹¹ Recognizing these associations is crucial for optometrists, who often serve as the first point of contact for patients experiencing ocular symptoms.

Literature Search

A literature search was performed using the databases PubMed, MEDLINE and Google Scholar using the following search terms: “drug-induced uveitis”; “medication-induced uveitis”; “drug-induced ocular inflammation”; “vaccine-induced uveitis”. Further search terms used the specific drug class and individual names in each category of medications discussed. For example, “bisphosphonate AND uveitis” and “zoledronate AND uveitis”. Only English articles were included. There was no limit on the time period. Article titles and abstracts were screened. Only papers with full text available were included. Where there are multiple publications describing the same drug, review papers and larger case series were favored over single case reports.

Mechanisms of Drug-Induced Uveitis

The pathogenesis of drug-induced uveitis remains poorly understood; however, several mechanisms have been proposed, broadly categorized as direct or indirect. Direct mechanisms are hypothesized to be due to the direct toxic effect of the drug, its metabolite or the vehicle. Indirect mechanisms are due to the drug’s interaction with the immune system.¹⁰

The inflammatory response caused by the direct mechanism is typically immediate (within 24–48 hours).¹² Drugs administered via topical, intravitreal, or intracameral routes can penetrate the ocular environment causing cytotoxicity. Likewise, systemic medications, their metabolites or excipients can cross the blood-retinal barrier (BRB) or blood-aqueous-barrier (BAB) and accumulate in ocular tissues causing toxicity and inflammation. This toxicity disrupts the integrity of the BAB and BRB, which are critical in maintaining immune privilege in the eye.¹³ Damage to these barriers allows the influx of immune cells and inflammatory mediators, triggering uveitis.

Indirect mechanisms involve drug-induced modulation of the immune system, leading to inflammation mediated by cytokines, immune complexes, or activated immune cells.¹⁰ Three main indirect pathways have been described:

1. Immune complex deposition – uveitis can occur when drugs induce production of antibodies which result in immune complexes being deposited in uveal tissues, activating the complement system and recruiting immune cells such as neutrophils and macrophages. Cytokines like tumor necrosis factor-alpha (TNF- α) and interleukin-6 (IL-6) are released, amplifying the inflammatory response. This mechanism is thought to contribute to uveitis associated with bisphosphonates.^{10,14}
2. Immune reaction to antigens released from antibiotic-induced death of microorganisms – uveitis may occur when antibiotics liberate antigens from dead microorganisms, which then form antigen-antibody complexes. These complexes are deposited in the uveal tissues, activating innate immune responses.¹⁰ One example is rifabutin-associated uveitis, where the cell wall proteins of dead organisms are thought to lead to formation of antigen-antibody immune complexes.^{15,16}
3. Activation of immune cells – targeted immunotherapy medications, such as immune checkpoint inhibitors, act on the immune system, causing activation of T cells which can target uveal antigens and cause drug-induced uveitis. Cytokine storms involving TNF- α , IL-17 and IL-2 have been observed in such cases, exacerbating tissue damage and barrier dysfunction.¹⁷

Vaccines have also been implicated in cases of uveitis.¹⁸ Currently there are three main mechanisms proposed for vaccine-induced uveitis. The first mechanism is through direct infection of ocular structures by live-attenuated vaccines such as the herpes zoster live vaccine.¹⁹ The second mechanism proposes adjuvants or additives used in vaccines (such as aluminum) that accumulate in uveal tissues as the trigger for inflammation.²⁰ The third mechanism is molecular mimicry between antigens used in the vaccine and ocular structures resulting in immune cross-reaction to uveal tissues.^{20,21}

In addition to the above mechanisms, patient-level risk factors also play a major role in the development of ocular inflammation in response to a medication or a vaccine. These include genetic predisposition, pre-existing underlying autoimmune conditions, and history of uveitis. Human leukocyte antigens (HLA) have been known to be strongly

associated with uveitis, such as HLA-B27 in anterior uveitis, HLA-A29 in birdshot chorioretinopathy, HLA-B51 in Behçet's disease and HLA-DR4/B1*04 in Vogt-Koyanagi-Harada (VKH) disease.²² It has been postulated that the presence of these HLAs can predispose to the development of drug-induced uveitis.²³

Topical Medications

The most common topical ocular medications reported in association with drug-induced uveitis are prostaglandin analogues and brimonidine, used in glaucoma treatment.

Prostaglandin Analogues

Topical prostaglandin analogues (PGA) such as latanoprost, bimatoprost and travoprost increase uveoscleral outflow to lower intraocular pressure, and are used in management of glaucoma. There has long been concern over increased risk of uveitis and cystoid macular edema (CME) associated with topical PGA use.²⁴ One study estimated the rate of latanoprost-induced uveitis and CME to be 0.48% and 0.19% respectively.¹¹ The mechanism is thought to be due to increased breakdown in the blood-aqueous and blood-retina barrier and increased production of cytokines in the anterior chamber.¹⁷ However, a recent large scale retrospective study of 67,517 glaucoma patients newly started on topical glaucoma therapy has drawn this into question, observing no increased risk with PGA use.²⁵

Patients may present with typical symptoms of anterior uveitis, such as red eye, photophobia, blurred vision, or metamorphopsia due to CME (Figure 1). Treatment involves cessation of the medication and topical steroid drops. Careful liaison with the patient's glaucoma specialist is important to ensure that their glaucoma remains adequately monitored and controlled. In cases where the patient was rechallenged with topical latanoprost, the majority had recurrence of uveitis, but all cases were reversible with drug-cessation and treatment.¹¹

Brimonidine

Brimonidine is a selective alpha-2 adrenergic agonist that reduces aqueous production and increases uveoscleral outflow. It is a common first or second line agent used in primary and secondary glaucoma. It can cause a granulomatous anterior uveitis, even years after initiation. The time of onset of brimonidine-induced uveitis is highly variable, ranging from

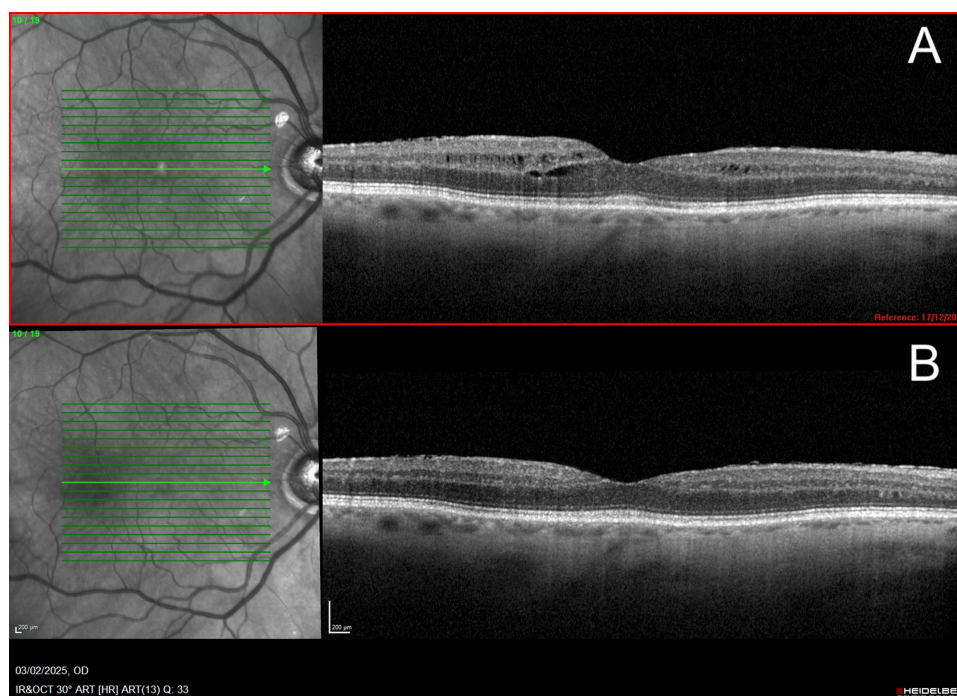

Figure 1 Latanoprost induced cystoid macular edema. (A) a few months after starting topical latanoprost. (B) resolution on cessation of latanoprost.

a week to five years in one case series.²⁶ Based on the delayed onset of brimonidine-induced uveitis in most cases, it is postulated to be due to a secondary cell-mediated immune response as opposed to a direct toxic reaction.²⁷

Patients with brimonidine-related uveitis classically present with acute or subacute onset of bilateral granulomatous anterior uveitis.²⁶ Symptoms include redness, pain, watering, photophobia and blurred vision, however patients can also be asymptomatic. Classic signs include conjunctival ciliary injection, granulomatous keratic precipitates, and anterior chamber cells and flare. It may be accompanied by raised intraocular pressure.²⁸ Brimonidine-related uveitis can be misdiagnosed as conjunctivitis by general practitioners without awareness of this condition, especially as it can occur after years of being on brimonidine treatment.

Assessment of the uveitis involves careful exclusion of posterior uveitis involvement and considering infectious and non-infectious differential diagnoses of granulomatous uveitis. Viral uveitis is an important differential in the presentation of hypertensive anterior uveitis. Routine uveitis screening laboratory investigations should be carried out. A chest X-ray should be performed to rule out sarcoidosis and pulmonary tuberculosis. Treatment requires cessation of brimonidine, usually with a course of topical steroids. The prognosis is good and most patients recover fully. A rechallenge typically results in uveitis recurrence.¹⁷

It is important to take a detailed ocular and medication history when evaluating these patients as they may fail to disclose their topical glaucoma medications. In any patient with glaucoma, it is crucial to liaise with the treating clinician before stopping a medication to ensure monitoring of intraocular pressure and timely initiation of appropriate alternative treatment.

Intravitreal Medications

Intravitreal medications are used for a variety of ocular indications. Drug-induced uveitis and sterile endophthalmitis has been reported following anti-vascular endothelial growth factor (anti-VEGF) agents, the intraocular steroid triamcinolone acetonide and the antibiotic vancomycin.

Anti-Vascular Endothelial Growth Factor

Intravitreal Anti-VEGF agents are widely used in the treatment of retinal conditions such as age-related macular degeneration (AMD) and diabetic macular edema (DME). Ranibizumab (Lucentis), aflibercept (Eylea), brolucizumab (Beovu) and faricimab (Vabysmo) have been approved by the Food and Drug Administration (FDA) for intraocular use, while bevacizumab (Avastin) has been used off-label for decades for various ophthalmic indications.²⁹ Anti-VEGF agents have been found to cause non-infectious intraocular inflammation, in the form of anterior uveitis, sterile endophthalmitis and retinal vasculitis. The overall incidence of post-injection intraocular inflammation mimicking endophthalmitis varies widely in the literature, ranging between 0.005% and 4.4%.²⁹ A retrospective review reported rates of sterile endophthalmitis following anti-VEGF injection to be 0.16%, 0.10% and 0.02% for aflibercept, bevacizumab and ranibizumab respectively.³⁰ Brolucizumab carries a higher risk of drug-induced uveitis of 4.6%, which includes a risk of retinal vasculitis, reported in 3.3% in the HAWK and HARRIER post hoc analyses.³¹ Faricimab is the latest anti-VEGF agent to receive FDA approval for neovascular AMD and DME and has also been reported to cause uveitis.³² At the two-year mark of the Phase 3 YOSEMITE and RHINE trials, between 0.3–1% of patients receiving faricimab developed uveitis.³³ A more recent retrospective review found the overall incidence of intraocular inflammation with faricimab to be 0.87%, with vitritis specifically observed in 0.63% of cases.³⁴

Inflammation associated with intravitreal anti-VEGF injection can present with a range of clinical features. Broadly, there are two distinct presentations. The first and more common, is an acute onset sterile inflammation, which can range from subclinical anterior chamber inflammation to significant inflammation mimicking infectious endophthalmitis. The second is a delayed onset retinal vasculitis which has been described most commonly with brolucizumab but more recently also with faricimab.^{31,35,36} The average time of presentation of retinal vasculitis post brolucizumab injection was reported to be 25–53 days.^{31,37}

The mechanism of anti-VEGF-related intraocular inflammation may relate to patient-specific factors or medication-specific factors. Patient-specific factors include the presence of anti-drug antibodies against the anti-VEGF drug molecules, an underlying condition that leads to breakdown of the blood-ocular barrier (eg, diabetes), or previous history

of uveitis. Medication-specific risk factors include the presence of impurities and endotoxins, and the presence of the Fc antibody portion on aflibercept and bevacizumab which may trigger an immune response.²⁹ The mechanism for the delayed onset of retinal vasculitis following brolucizumab is most likely related to a delayed type III or type IV hypersensitivity reaction.^{38,39} The timing of onset also points towards a delayed hypersensitivity reaction, where repeat exposure may result in a more rapid immune response. Bauman et al³⁸ observed that retinal vasculitis occurred earlier in patients who had received more than one injection of brolucizumab compared to those who had a reaction to the first injection (20 days post injection vs 35.5 days post injection, respectively).

The exact immunologic trigger for this reaction to brolucizumab and not to other anti-VEGF agents still remains unknown. The brolucizumab molecule is much smaller than the other anti-VEGFs (with a molecular weight of only 26 kDa compared with 48 kDa for ranibizumab and 115 kDa for aflibercept), and thus allows for higher molecular concentration, better tissue penetration, and a prolonged therapeutic effect.⁴⁰ This increased tissue penetration may lead to increased exposure to the immune system in eyes with a potentially compromised blood retinal barrier such as neovascular AMD and diabetes.⁴¹

The presentation of anti-VEGF induced uveitis is variable. It can present with acute anterior uveitis symptoms of red eye, pain, photophobia, or it can present with floaters and blurry vision without redness or pain. Differentiating sterile inflammation from infectious endophthalmitis can therefore be challenging. The timing and clinical symptoms and signs can help the clinician to differentiate the two, however, when in doubt, it is safest to treat the inflammation as infectious with an urgent vitreous tap and injection of intravitreal antibiotics and/or vitrectomy surgery.

The treatment of anti-VEGF related uveitis requires intensive topical steroids, with addition of periocular and systemic steroids depending on the extent of posterior inflammation. Most patients experience improvement with steroid treatment and regain their baseline vision. With very mild reactions, some individuals will tolerate further injections with a course of topical steroid, but most will require cessation of treatment or a switch to another agent.

The cumulative risk of endophthalmitis post intravitreal anti-VEGF injection increases with the number of injections and occurs at a higher rate earlier in the treatment course.⁴² Currently, there is no data to confirm if a similar risk profile exists for sterile inflammation post anti-VEGF injection. In our literature search, we are unable to find reports on whether the risk of developing uveitis when switching to a different anti-VEGF agent is impacted by prior anti-VEGF-related uveitis. This highlights a gap in our current knowledge of drug-induced uveitis and may warrant further investigation.

Triamcinolone

Triamcinolone acetonide is a long acting, water insoluble, crystallized corticosteroid. The incidence of sterile endophthalmitis following intravitreal triamcinolone (IVTA) is reported to be between 0.20% and 6.73%.⁴³ This occurs less commonly with preservative-free preparations. The etiology of IVTA-induced ocular inflammation is thought to include several factors: contamination with endotoxins, direct toxic effect of preservatives within certain triamcinolone preparations, and an immune-mediated reaction to the drug or the preservatives.^{43,44} Triamcinolone associated sterile endophthalmitis tend to present earlier (within 3 days), with less pain and less vision loss compared to infectious endophthalmitis.⁴⁴ Hypopyon formation is rare, and should be differentiated from a pseudohypopyon (Figure 2), which is a collection of triamcinolone crystals in the anterior chamber seen soon after IVTA in vitrectomized patients with posterior capsular defect or zonular weakness.⁴⁵ In a case of suspected sterile endophthalmitis post IVTA, it may be prudent to observe the patient closely as an inpatient with intensive topical steroid therapy to ensure that the inflammation improves within a few hours of treatment. The visual prognosis is generally good.

Vancomycin

Vancomycin is a large glycopeptide and one of the few antibiotics that is available for treatment of methicillin-resistant *Staphylococcus aureus* and methicillin-resistant, coagulase-negative *Staphylococcus* species.⁴⁶ In ophthalmic use, vancomycin can be delivered topically, intracamerally or intravitreally. Intracameral vancomycin is commonly used as part of routine phacoemulsification cataract surgery in the United States.⁴⁷

A rare but serious adverse effect of intraocular vancomycin is hemorrhagic occlusive retinal vasculitis (HORV). The exact incidence of vancomycin-associated HORV is unreported but is thought to be exceedingly rare.⁴⁸ Our current

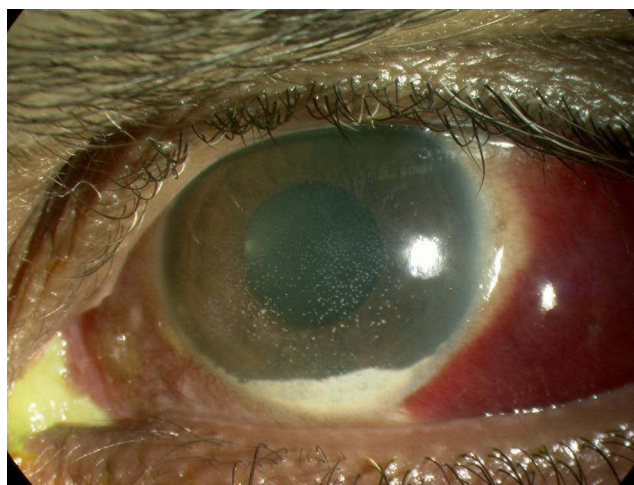


Figure 2 Pseudohypopyon formed by triamcinolone crystals in the anterior chamber.

knowledge of the condition primarily relies on a small number of case reports.^{47,49–51} Patients with HORV typically present with painless blurred vision, multiple peripheral scotomas and minimal anterior segment or vitreous inflammation.^{47,52} The mean time to presentation is 9 days after intraocular vancomycin.⁵² Due to the relatively delayed onset, it is thought that direct toxicity is unlikely to be the main mechanism for vancomycin-associated HORV. Rather, it is postulated to be due to a type III hypersensitivity reaction where antibody–antigen complexes in vessel walls result in an inflammatory cascade.⁴⁷ Interestingly, on histological analysis of an enucleated eye, Todorich et al⁵⁰ found no evidence of leukocytoclastic vasculitis but rather marked and severe chronic non-granulomatous choroiditis accompanying necrosis of the retinal vascular network. The authors propose that the underlying pathophysiology of HORV may be a primary choroidal process with secondary effects on the retina.⁵⁰ Further studies are needed to fully understand the underlying pathophysiology of this rare drug-associated adverse reaction. Corticosteroid treatment, early panretinal laser photocoagulation, and anti-VEGF therapy are recommended for management of vancomycin-associated HORV.⁵² Visual outcomes are poor and 56% of the involved eyes develop neovascular glaucoma within 1–2 months.⁴⁷

Antimicrobials

A number of antimicrobial medications have been reported to cause uveitis. The two most well-recognized and widely reported are the antiviral cidofovir and antibiotic rifabutin.

Cidofovir

Cidofovir is a nucleoside DNA polymerase inhibitor with activity against herpes viruses. The main indication for its use is treatment of cytomegalovirus (CMV) retinitis in acquired immunodeficiency syndrome (AIDS) patients, but it is also used for non-ocular CMV infection in other immunocompromised individuals.⁵³ There are many case reports of systemic cidofovir inducing anterior uveitis with or without hypotony.^{54–56} In patients with human immunodeficiency virus (HIV) on protease inhibitor treatment, a higher CD4+ T-lymphocyte count was associated with a higher risk of developing cidofovir-induced uveitis.⁵⁴ The pathophysiology of cidofovir-induced anterior uveitis is poorly understood, though possibly results from an intraocular accumulation of the drug through a breakdown of the BRB and a direct toxic effect on the ciliary body.⁵⁵ The average time of onset of uveitis ranged between 6–11 doses of intravenous cidofovir across several case series.^{54–56} Symptoms can include red eye, pain, photophobia and blurred vision. Most cases are treated successfully with cessation of cidofovir, and a course of topical steroids and mydriatics. Rarely, the hypotony is chronic and refractory to treatment.⁵⁷

It is important to reiterate that drug-induced uveitis is a diagnosis of exclusion. In the context of an immunocompromised person, it is important to rule out infection as a cause of the uveitis, particularly CMV. Whilst CMV will normally cause either retinitis in the immunocompromised, or hypertensive anterior uveitis in the immunocompetent, it is

unlikely to cause hypotony. Immune reconstitution uveitis may occur, particularly in those starting HIV therapy, but this usually takes longer to develop than cidofovir-induced uveitis.

Rifabutin

Rifabutin, a semi-synthetic derivative of rifampicin, is an anti-mycobacterial antibiotic used to treat mycobacterial infections including tuberculosis. It is most commonly used for *Mycobacterium Avium* Complex infection or prophylaxis in AIDS patients. Rifabutin is known to cause an anterior uveitis with hypopyon, and rarely intermediate uveitis, panuveitis, and retinal vasculitis.^{58–62} Rifabutin-induced uveitis is dosage and duration dependent, and can occur weeks to months from initiation of the drug. Co-treatment with another drug that inhibits cytochrome P450 (a family of enzymes involved in drug metabolism) increases the risk of drug-induced uveitis.⁶² The uveitis typically responds well to topical corticosteroids therapy and discontinuation of rifabutin. Like with cidofovir, in patients with AIDS, rifabutin-induced uveitis is more likely to occur when the CD4+ count is rising.⁶¹

Bisphosphonates

Bisphosphonates are a class of drugs derived from inorganic phosphates that are used to prevent or treat osteoporosis by reducing bone resorption by osteoclasts. They are used in age-related osteoporosis, glucocorticoid-induced osteoporosis, hypercalcemia, bone malignancy and Paget's disease. The commonly used oral forms include alendronate and risedronate. The intravenous forms include zoledronate and pamidronate. These are all nitrogen-containing bisphosphonates. Non-nitrogen containing bisphosphonates such as etidronate and clodronate are less potent and less commonly used. Both the oral and intravenous forms can cause ocular inflammation in the form of uveitis, scleritis or orbital inflammation.^{63–67} Bisphosphonate-induced uveitis is the most common form of drug-induced uveitis, accounting for over two-thirds of all cases.⁷

There are several mechanisms proposed for bisphosphonate-induced ocular inflammation. Nitrogen-containing bisphosphonates are known to cause an acute phase reaction in 40% of patients due to a drug-induced release of inflammatory cytokines.⁶⁸ This reaction produces symptoms of a flu-like illness (fever, chills, muscle and bone aches), and occurs within 24–48 hours after intravenous bisphosphonate and usually resolves by 72 hours. The risk is highest with the first infusion and less likely with subsequent doses. Early onset ocular inflammation is thought to be due to a similar mechanism, with inflammation mediated by TNF- α and IL-6.⁶⁹ Other proposed mechanisms include macrophage polarization, T cell proliferation, and immune-complex deposition, which are more likely to play a part in delayed onset uveitis.⁶⁷

Intravenous zoledronate is the most frequently reported bisphosphonate to cause ocular inflammation, likely because it is one of the most potent bisphosphonates. [Figure 3](#) demonstrates a case of bilateral scleritis and orbital inflammation following zoledronate infusion. The estimated incidence of acute anterior uveitis after zoledronate therapy is reported to be 0.8% - 1.1% among post-menopausal women.^{70,71} Ocular inflammation typically occurs within 1–7 days of intravenous administration (average 5 days) and within 15–21 days of oral administration, although late uveitis onset may occur.^{7,67} Treatment involves discontinuation of the drug and topical steroids for anterior uveitis and systemic corticosteroids for scleritis and orbital inflammation. The prognosis is good, as the ocular inflammation responds well to steroid therapy.⁷²

There is no consensus on restarting bisphosphonate therapy after an episode of ocular inflammation. The literature reports a mix of recurrence and no recurrence upon rechallenge with the same bisphosphonate.^{7,72,73} Others report no recurrence upon switching to a different bisphosphonate or prophylactically administering corticosteroids before rechallenging with the same bisphosphonate.⁶⁷ If a rechallenge of bisphosphonate is planned, we recommend reviewing the individual within a week of treatment re-initiation to enable early identification of any adverse response and initiation of treatment.

Tumor Necrosis Factor Inhibitors

Tumor necrosis factor (TNF) is a pro-inflammatory cytokine and the target of several biologic immunomodulatory medications. FDA approved TNF inhibitors include infliximab, adalimumab, etanercept, golimumab, and

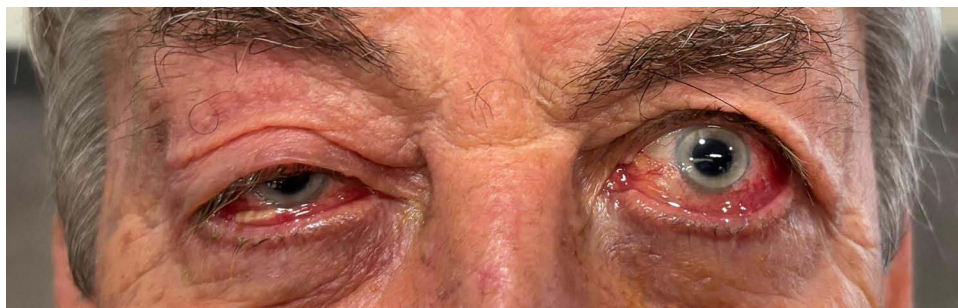

Figure 3 Bilateral scleritis and orbital inflammation after first dose of intravenous zoledronate infusion.

certrolizumab.⁷⁴ TNF inhibitors have demonstrated efficacy in many inflammatory diseases such as rheumatoid arthritis, ankylosing spondylitis, psoriatic arthritis, juvenile idiopathic arthritis, inflammatory bowel disease and inflammatory eye disease.⁷⁵ While these drugs have been shown to be effective in uveitis, they can also rarely cause paradoxical worsening of preexisting uveitis or induce new onset uveitis in patients on anti-TNFs for other inflammatory conditions.^{76–78} Of the abovementioned TNF inhibitors, etanercept is the most likely of this class to cause drug-induced uveitis.^{79–82}

Infliximab and adalimumab are monoclonal antibodies against TNF alpha, while etanercept is a soluble TNF receptor. Infliximab and adalimumab exclusively inhibit TNF alpha, while etanercept inhibits both TNF alpha and TNF beta. These differences may partly explain the differences in their efficacy and side effect profile.⁷⁹ The mechanism behind anti-TNF induced uveitis is not well understood. It is postulated that the inverse relationship between TNF and interferon could affect immune cell activation, autoantibody formation, and immune complex deposition, leading to autoimmune disease.⁸³

Non-granulomatous anterior uveitis is the most common presentation, but intermediate uveitis, cystoid macular edema (see Figure 4) and retinal vasculitis have also been reported.^{79,80} There are also reports of drug-induced sarcoid uveitis following TNF inhibitor therapy.⁸⁴ The time from drug exposure to onset of uveitis is variable, ranging from days to years, averaging 12–13 months in one series and 19.5 months in another.^{79,80} However, there have been reports of new-onset uveitis within days to weeks of starting a TNF inhibitor.⁸⁵ Wendling et al⁸⁰ conducted a literature review of new-onset uveitis in patients receiving TNF inhibitors and found that etanercept was the most frequently implicated agent (84.3%), followed by infliximab (12.4%) and adalimumab (3.3%). The inflammatory condition being treated was most commonly ankylosing spondylitis (72%), followed by juvenile idiopathic arthritis (11%), rheumatoid arthritis (10%), and

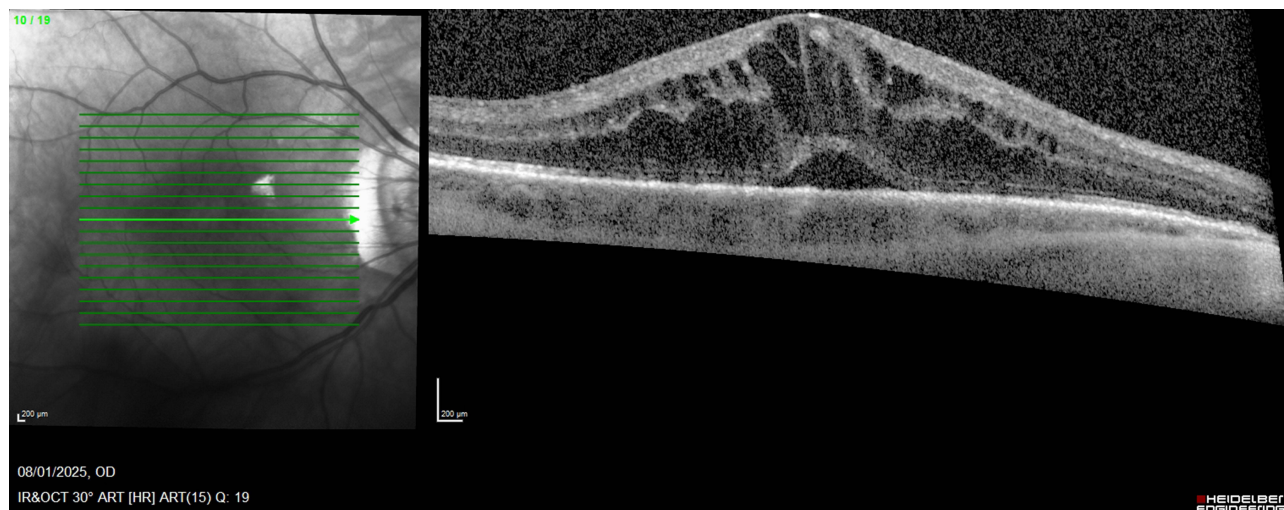


Figure 4 New onset of cystoid macular edema in a patient with history of HLA-B27 anterior uveitis on etanercept for psoriatic arthritis.

psoriatic arthritis (6%).⁸⁰ Lie et al⁸¹ found a fourfold increase in the risk of anterior uveitis in patients with ankylosing spondylitis on etanercept compared with adalimumab, and a twofold increase for etanercept compared with infliximab.⁸¹

It is important to rule out infectious causes of uveitis in these immunosuppressed individuals, in particular tuberculosis (Tb). TNF inhibitors increase the risk of Tb infection or reactivation, as TNF alpha is thought to play a crucial role in the immune system's defense against tuberculosis infection.⁸⁶ New onset ocular Tb has been reported in patients on anti-TNF therapy for ankylosing spondylitis, Behcet's disease and Crohn's disease.^{87,88} Clinicians should be aware of the increased risk of Tb infection or reactivation in patients on anti-TNF drugs, even with previous negative Tb screening tests. Patients who develop new onset uveitis during treatment should be reinvestigated for Tb, particularly if the pattern of uveitis does not match the known inflammatory condition they are being treated for. TNF inhibitor induced uveitis should not be diagnosed without ruling out other etiologies.

Most reported cases responded well to topical steroid treatment and discontinuation of the TNF inhibitor, but sometimes required addition of systemic and/or periocular steroid. In those with an inflammatory condition associated with uveitis (such as ankylosing spondylitis, psoriatic arthritis and Crohn's disease), a switch from etanercept to infliximab or adalimumab is usually able to control both the systemic and ocular disease. If etanercept is causing new onset of uveitis, or increased flare-ups of pre-existing uveitis, a discussion should be had between the patient's ophthalmologist or optometrist and rheumatologist regarding switching the anti-TNF agent.

Targeted Cancer Immunotherapies

Targeted cancer immunotherapies, such as immune checkpoint inhibitors and BRAF/MEK inhibitors, represent an important group of drugs increasingly recognized as potential causes of uveitis. Cancer immunotherapies work by improving the ability of the body to generate an immune response to tumor cells. In doing so, the anti-cancer drug can also cause immune-related adverse events, including uveitis.⁸⁹

Immune Checkpoint Inhibitors

Immune checkpoint inhibitors (ICIs) are monoclonal antibodies used in various malignancies including metastatic melanoma, small cell and non-small cell lung cancer, renal cell carcinoma and Hodgkin's lymphoma.⁹⁰ To escape the immune system, tumor cells over-express immunosuppressive molecules which reduces anti-tumor T cell function. ICIs block these immunosuppressive molecules and reactivate the cytotoxic T cells. There are three main types of checkpoint inhibitors, classified by the ligand it targets: programmed cell death 1 (PD-1) inhibitors (nivolumab, pembrolizumab, and cemiplimab), programmed cell death ligand 1 (PD-L1) inhibitors (atezolimumab, durvalumab and avelumab), and cytotoxic T lymphocyte associated protein 4 (CTLA4) inhibitors (ipilimumab).⁹⁰

Uveitis occurs in about 1% of patients commenced on an ICI, with anterior uveitis being the most common, followed by posterior uveitis and panuveitis.⁹¹⁻⁹³ A VKH disease like presentation with multifocal serous retinal detachments is the most common form of posterior/panuveitis reported with ICIs.^{94,95} Isolated intermediate uveitis is rare.⁹⁶ Ipilimumab (CTLA-4 inhibitor) was associated with the highest incidence of uveitis among ICIs, but VKH-like uveitis was most associated with PD1/PD-L1 inhibitors.⁹⁷ Uveitis occurred most commonly in patients being treated for cutaneous melanoma.⁹⁴ In one study, melanoma patients were 6.45 times more likely to develop uveitis in the first year of ICI therapy compared to non-melanoma patients.⁹⁷ Reported cases of uveitis developed between 2 weeks and 2 years after starting ICI, with a median of 9 weeks and the majority presenting within 6 months.^{94,96,98} Individuals with a history of uveitis who receive ICI therapy are at increased risk of uveitis recurrence.⁹⁹ Braun et al⁹⁷ reported 38.9% of patients with a known history of anterior uveitis experienced flare-ups on ICI treatment, while those with recorded past intermediate, posterior, or panuveitis had a combined recurrence rate of 51.1%.⁹⁷

The pathogenesis of ICI-induced uveitis is unclear. The activation of T cells may result in increased immune activity against uveal antigens. The preponderance of ICI-induced uveitis in patients treated for cutaneous melanoma suggests that there is an association between lysis of melanoma cells and T cell mediated immune activity against uveal melanin.¹⁰⁰ Other proposed mechanisms include activation of the complement cascade and loss of immune privilege.¹⁰¹

Patients may present with a variety of symptoms including painful red eye with photophobia, or reduced vision without pain. The presentation of uveitis is bilateral in 90%.⁹⁶ It is important to differentiate a drug related reaction from

a cancer-related process such as a paraneoplastic syndrome (eg, melanoma-associated retinopathy) or ocular metastasis. Careful dilated examination and multi-modal imaging should be conducted in all patients suspected of uveitis who are on cancer treatment with particular attention to excluding ocular metastases.¹⁰² Figure 5 shows an ultra-widefield fundus image of ocular metastases from lung cancer.

The management of ICI-related uveitis depends on the severity of the ocular inflammation and the balance of risk and benefit of continuation of the drug. When possible, local corticosteroids are preferred over systemic corticosteroids as the impact of systemic immunosuppression on immunotherapy efficacy and tumor progression is not completely understood. If systemic steroids are used, the American Society of Clinical Oncology (ASCO) guidelines recommend that ICIs are withheld until the patient is either off all steroids or is receiving a daily dose of 10 mg oral prednisolone (or equivalent) or less.⁹³ The decision to discontinue an ICI should be made in collaboration with both the patient and their oncologist. Due to the low incidence of ocular adverse effects, we do not routinely screen these patients for uveitis, but all individuals on ICIs should be made aware of the risk of uveitis and symptoms to look out for.

V-Raf Murine Sarcoma Viral Oncogene Homologue B (BRAF) Inhibitors and Mitogen-Activated Protein Kinase (MEK) Inhibitors

BRAF inhibitors and MEK inhibitors are small molecule protein kinase inhibitors used to treat metastatic melanoma in patients with mutation of the BRAF gene. The BRAF mutation results in increased kinase activity which mediates cellular responses to growth signals. BRAF inhibitors specifically target mutated BRAF proteins, which are abnormally active and drive uncontrolled cell proliferation.¹⁰³ MEK inhibitors inhibit MEK1 and MEK2 downstream of BRAF in the mitogen-activated protein kinase (MAPK) signaling pathway and can be an alternative to BRAF inhibitors in patients that develop resistance. MEK inhibitors are frequently used in combination with BRAF inhibitors to counteract acquired resistance during BRAF inhibitor monotherapy.¹⁰⁴

FDA approved BRAF inhibitors include vemurafenib, dabrafenib and encorafenib. MEK inhibitors include trametinib, cobimetinib and binimetinib.¹⁰⁵ These targeted therapies have revolutionized the treatment of unresectable BRAF-mutant metastatic melanoma, and significantly improved the survival rate. However, with their increasing use, there is also increasing reporting of ocular adverse events associated with BRAF and MEK inhibitors. The incidence of uveitis associated with BRAF inhibitor use ranges from 1–4%.¹⁰⁶ In a cohort study by Dimitriou et al¹⁰⁴ involving patients with advanced melanoma treated with either ICI or BRAF/MEK inhibitors, 1.3% of patients in the ICI group and 3.8% in the

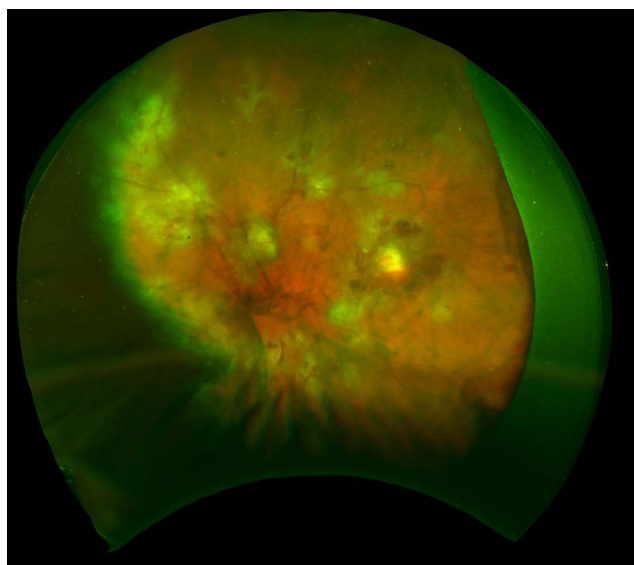


Figure 5 Ocular metastases from small cell lung cancer.

BRAF/MEK inhibitor group developed uveitis.¹⁰⁴ Figures 6 and 7 depicts a case of BRAF inhibitor associated panuveitis with multifocal choroiditis appearance on indocyanine green angiogram.

A national medical claims-based study in South Korea reviewed 77,323 patients with cutaneous melanoma or lung cancer who received BRAF inhibitor therapy, ICI therapy or conventional cytotoxic chemotherapy only. They found the one-year cumulative incidence of uveitis was 0.33% in the conventional group, 0.35% in the ICI group, and 2.27% in the BRAF inhibitor group. They also found the uveitis risk increased 3.71-fold after BRAF-inhibitor exposure. Most cases occurred within 160 days after drug administration.¹⁰⁷

The mechanism driving BRAF/MEK inhibitor induced uveitis has not been fully elucidated. It has been postulated that MAPK inhibition might trigger the production of reactive oxygen species, leading to the breakdown of the BRB and subsequent loss of the immune-privileged ocular site. This could potentially initiate an autoimmune response, resulting in uveitis. Another accepted mechanism for uveitis in patients with melanoma is the autoimmunity against antigens shared between melanoma cells and melanocytes of the choroid, similar to ICI-associated uveitis.¹⁰⁶

Like ICI-associated uveitis, the uveitis location is most commonly anterior uveitis.^{23,103} There are also reported cases of VKH-like panuveitis related to BRAF/MEK inhibitors in melanoma patients, and it is suggested that individuals with HLA-DRB1*04 detected is predisposed to this VKH-like inflammatory response to BRAF/MEK inhibitors.²³

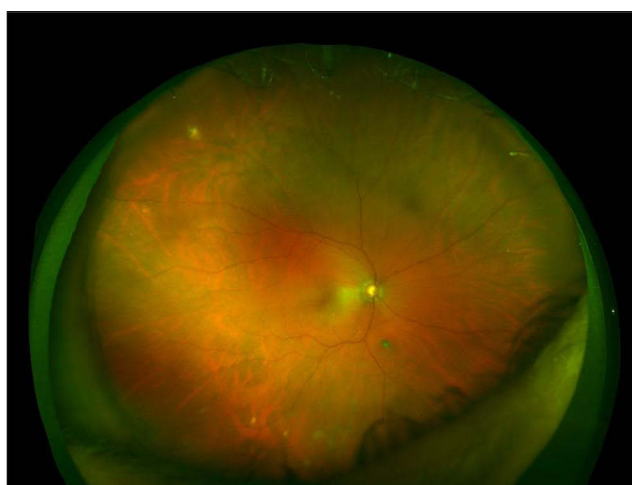

Figure 6 Bilateral panuveitis in a patient on BRAF inhibitor dabrafenib for metastatic melanoma.

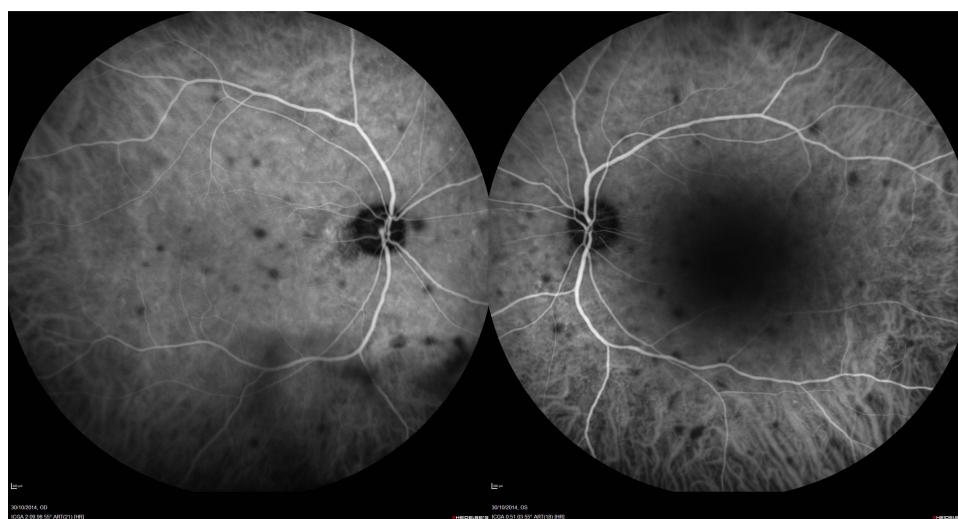

Figure 7 Indocyanine green angiogram of bilateral BRAF inhibitor induced panuveitis.

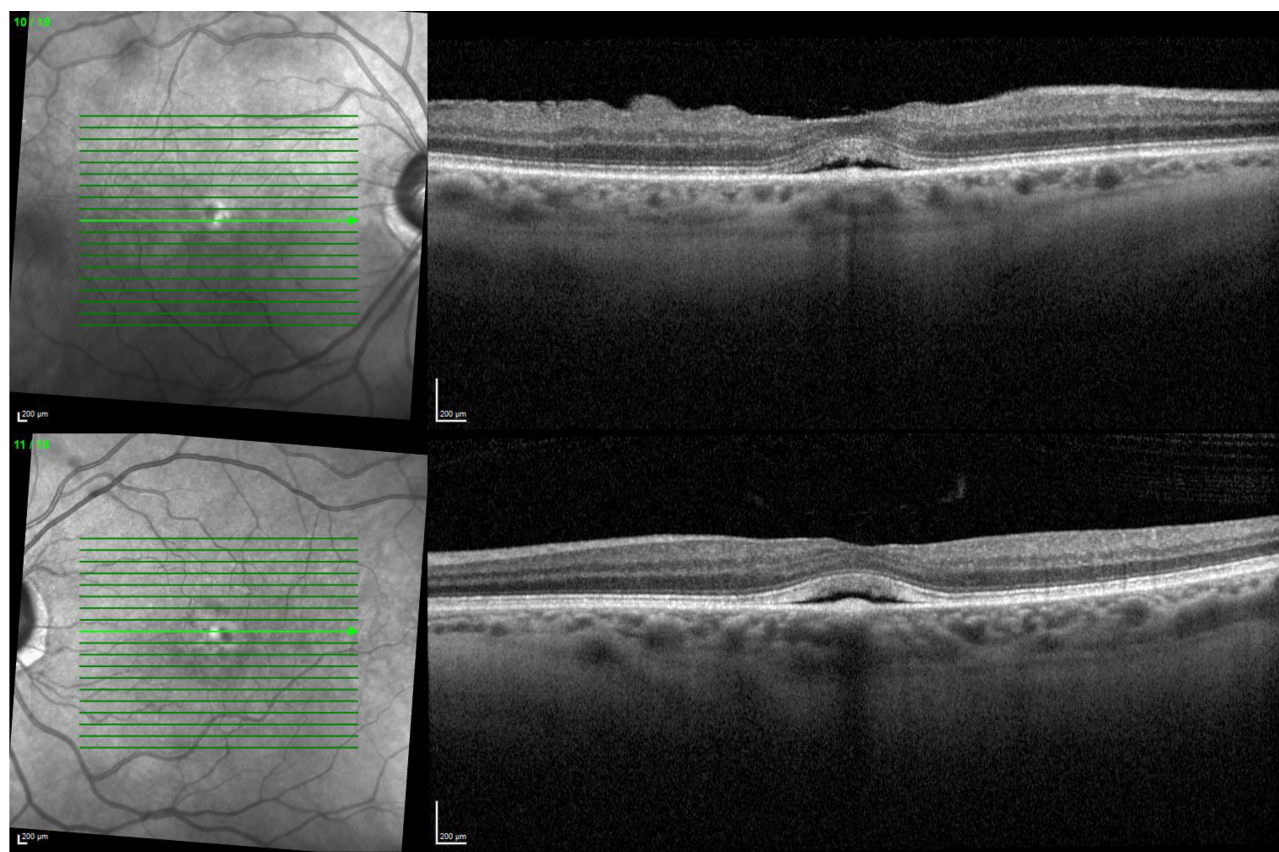


Figure 8 BRAF inhibitor associated acute exudative paraneoplastic polymorphous vitelliform maculopathy.

Vemurafenib has also been associated with a reversible acute vitelliform-like paraneoplastic maculopathy (see Figure 8).^{108,109}

In addition to uveitis, MEK inhibitors can induce central serous retinopathy, subfoveal neurosensory retinal detachment, and retinal vein occlusion.¹¹⁰ The most common ocular side effect of MEK inhibitors is in fact MEK inhibitor induced retinopathy. This presents as bilateral subretinal fluid accumulation with minimal visual symptoms, typically occurring within the first few weeks of treatment. Figure 9 is one example of bilateral MEK-inhibitor retinopathy with subretinal fluid. In one study of the MEK inhibitor binimetinib, retinopathy was observed in 92% of patients on MEK inhibitor monotherapy and 100% of those on BRAF/MEK inhibitor combination treatment.¹¹¹ MEK inhibitor-induced retinopathy is considered to be a class effect, and thought to be related to drug toxicity as opposed to an upregulation of the immune system as in the cases of drug-induced uveitis.¹¹¹

Like with ICIs, the decision to discontinue the treatment depends on the severity of uveitis and the risk of drug discontinuation. Most cases of uveitis can be managed successfully with local steroids and/or systemic steroid therapy. A retrospective study including 54 patients from different countries who developed uveitis while on cancer immunotherapy reported that cessation of immunotherapy was necessary only in a minority of cases. Out of all patients, 54% recovered fully or partially, 28% experienced only a single episode of uveitis, while 18% of the patients developed chronic disease.¹¹²

Vaccines

Another category of drug-induced uveitis is vaccine-induced uveitis. Many vaccines have been implicated in triggering ocular inflammation, including de novo uveitis or flare of existing uveitis. A recent literature review on uveitis linked to anti-viral vaccination by Zou et al²¹ identified a total of 51 reported cases, involving 61 patients, spanning from 1978 to 2023. This included case reports of uveitis following vaccination against hepatitis B virus, human papilloma virus,

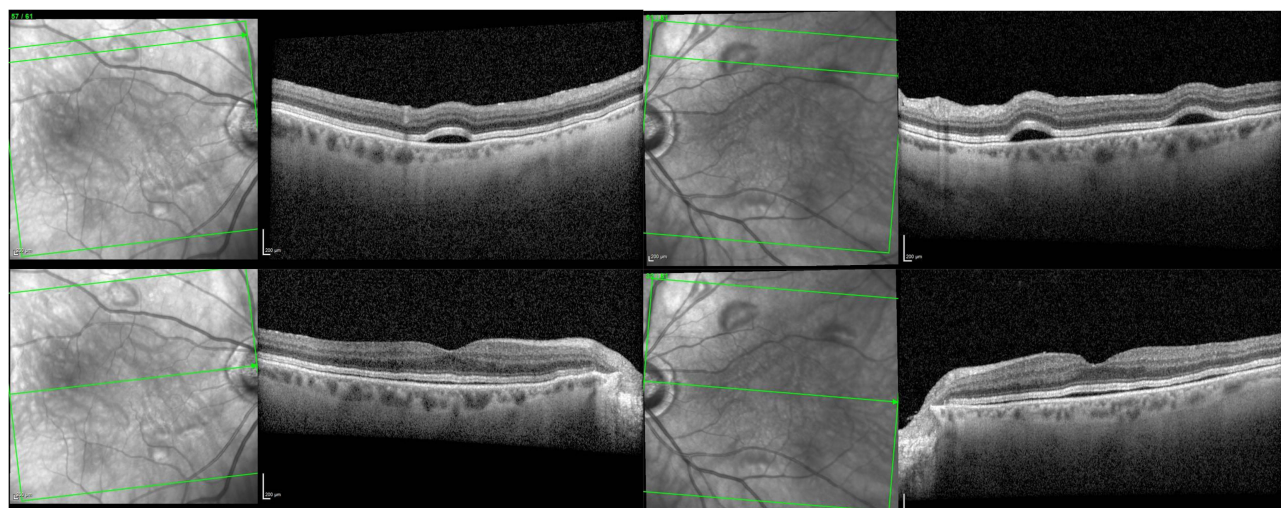


Figure 9 MEK inhibitor associated retinopathy in a patient on binimetinib for metastatic melanoma.

influenza, measles-mumps-rubella, varicella zoster virus, yellow fever, hepatitis A virus and rabies virus.²¹ The time of onset reported in the majority of these cases was 24 hours to 2 weeks post vaccination. A range of uveitis types were reported, including anterior, intermediate, posterior uveitis and panuveitis, as well as distinct forms of uveitis including tubular interstitial nephritis and uveitis syndrome (TINU), VKH, acute posterior multifocal placoid pigment epitheliopathy (APMPPE) and multiple evanescent white dot syndrome (MEWDS).²¹ The authors of this present review have also treated a case of atypical APMPPE following Monkeypox (Mpox) vaccination (unpublished).

The Coronavirus disease 2019 (COVID-19) vaccines are one of the newest groups of vaccines used globally and have been the subject of scrutiny since their introduction in 2020. There is an abundance of published cases of de novo uveitis or recurrence of pre-existing uveitis after COVID-19 vaccination.^{113,114} Tomkins-Netzer et al¹¹⁵ conducted a population-based study of non-infectious uveitis following COVID-19 vaccination, and found an increased risk of uveitis after the first and second dose of vaccination compared to pre-vaccination. Anterior uveitis was the most common site of inflammation, occurring in 91% of eyes.¹¹⁵ Types of ocular inflammation reported following COVID-19 vaccines include anterior uveitis, intermediate uveitis, posterior uveitis, panuveitis, multifocal choroiditis,^{116,117} retinal vasculitis,^{118,119} episcleritis and scleritis,¹²⁰ VKH disease,^{121,122} MEWDS,^{123,124} APMPPE,¹²⁵ acute macular neuroretinopathy (AMN),^{126–128} paracentral acute middle maculopathy (PAMM)¹²⁹ and acute zonal occult outer retinopathy (AZOOR).^{130–132} It has also been associated with recurrence of secondary choroidal neovascular membranes in uveitis conditions such as punctate inner choroidopathy (PIC).¹³³ The reported entities appear to overlap with the ocular manifestations observed in patients with COVID-19 infection, suggesting a shared immunopathogenic mechanism underlying both virus- and vaccine-mediated immune responses.¹³⁴ Jordan et al¹³⁵ published a comprehensive retrospective review of recurrence of uveitis following COVID-19 vaccination. The authors found the rate of uveitis flare was 12.3 per 1000 patient-months at baseline, 20.7 after the first dose, 15.0 after the second dose and 12.8 after the third dose. This increase in rate of uveitis recurrence was seen in both infectious and non-infectious uveitis entities. Median time to uveitis flare was 0.53 months after the first vaccination.¹³⁵

The exact mechanism of vaccine-associated uveitis is not well-understood, but theories include molecular mimicry, antigen-specific cell and antibody-mediated hypersensitivity reactions, and reactions to vaccine adjuvants or additives.²⁰ Cross-reactivity occurs when peptide fragments presented to T cells closely resemble peptides of the uvea, triggering an immune response against uveal antigens. This is similar to the pathogenesis of post-infectious uveitis. Recombinant vaccines may induce delayed hypersensitivity reactions, and the deposition of immune complexes with subsequent complement activation causing uveitis.²¹

The diagnosis of vaccine-induced uveitis is based on the temporal relationship between vaccination and onset of symptoms, and the exclusion of other causes. There are no laboratory tests to confirm the diagnosis. Treatment is the

same as other drug-induced uveitis and most cases respond well to local and/or systemic steroid treatment. Most reported cases of de novo uveitis achieved complete resolution with standard treatment.¹³⁶ Although systemic steroid therapy often improves the ocular inflammation, there is a concern that immunosuppressive agents may hamper the protective immune response to vaccination.^{137,138} However, real-world, population-based data provide reassuring results that vaccines remained effective in the prevention of COVID-19 in immunocompromised individuals who were taking glucocorticoids and disease-modifying antirheumatic drugs.¹³⁹

There is also concern regarding subsequent vaccination with the same vaccine after an adverse ocular reaction. This is particularly relevant when additional doses are required to achieve optimal immunity against the targeted infection, or in the case of the influenza vaccine, annual updated doses. The COVID-19 vaccination roll-out was a vital public health tool in the management of the global pandemic, and booster doses were recommended to maximize protection against the virus. The risk of uveitis flare with subsequent boosters has not been reported, however, within the author's own series, of 48 subjects with existing uveitis who flared following COVID-19 vaccination, 29 underwent a second COVID-19 vaccine. Flares occurred in 4 subjects (13.8%), with further flares more likely if the first flare occurred ≤ 21 days after vaccination ($p = 0.011$).¹³⁴ Based on currently available evidence, patients with pre-existing ocular inflammatory conditions should not be discouraged from receiving COVID-19 vaccination. Additionally, there is currently insufficient evidence to support prophylactic treatment post vaccination in patients with pre-existing ocular inflammatory conditions.¹¹³ However, patients with a background of systemic autoimmune disease or previous uveitis should be counselled regarding the potential symptoms associated with vaccine-associated uveitis.

Patients with vaccine-related uveitis should be managed on a case-by-case basis, balancing the severity of the uveitis and the benefits of vaccination. The decision to forgo future vaccinations should be made cautiously and only after thorough consultation with the patient and their primary physician.

Discussion

This review paper provides an updated overview of medications and vaccines associated with uveitis. It adds to the small number of existing review papers on the topic, since the first drug-induced uveitis review was published by Fraunfelder and Rosenbaum in 1997.^{6,10,12,14,17} The most important additions in this paper are the inclusion of the novel cancer immunotherapies and the latest publications on COVID-19 vaccine related uveitis. A limitation of this review is its reliance on retrospective case series and case reports, which are inherently subject to publication and reporting bias. The incidence of uveitis caused by each drug type is therefore difficult to estimate. The diagnosis of drug-induced uveitis can be challenging in practice. The following sections provide some general guidance to aid the diagnostic process and management.

Diagnosis of Drug-Induced Uveitis

The Naranjo criteria is a standardized tool used to assess the probability that an adverse reaction is attributable to a specific medication. It comprises ten questions that either support or refute the likelihood of a drug-related event, generating a cumulative score that categorizes the reaction as “definite”, “probable”, “possible” or “doubtful” (Tables 1 and 2).¹⁴⁰ This is a useful tool when evaluating a patient with a potential drug-induced uveitis.

The diagnosis of drug-induced uveitis relies on a high index of suspicion and careful exclusion of other causes. The diagnosis should be considered if a patient presents with a new onset of ocular inflammation or a recurrence of pre-existing uveitis condition soon following initiation of a new medication. For some drugs, such as brimonidine or etanercept, the clinician should also be aware of possible late presentations. A thorough medication history, including recent ocular or systemic drug use and vaccinations, is crucial for diagnosis.

It must be emphasized that drug-induced uveitis is a diagnosis of exclusion. So standard uveitis screening investigations should still be carried out based on the patient's clinical presentation and risk factors. The investigations are necessary to rule out infectious etiologies and identify associated systemic inflammatory conditions. All new episodes of anterior uveitis should be investigated with full blood count, renal function, liver function, serum ACE, treponemal serology, HbA1c, and HLA-B27. Investigations should also include Quantiferon gold and chest X-ray for bilateral uveitis, intermediate and posterior uveitis. Urine beta-2 microglobulin and urinalysis is indicated in bilateral uveitis

Table 1 Naranjo Scale

Question	Yes	No	Do Not Know	Score
1. Are there previous conclusive reports on this reaction?	+1	0	0	
2. Did the adverse event appear after the suspected drug was administered?	+2	-1	0	
3. Did the adverse event improve when the drug was discontinued or a specific antagonist was administered?	+1	0	0	
4. Did the adverse event reappear when the drug was readministered?	+2	-1	0	
5. Are there alternative causes that could on their own have caused the reaction?	-1	+2	0	
6. Did the reaction reappear when a placebo was given?	-1	+1	0	
7. Was the drug detected in blood or other fluids in concentrations known to be toxic?	+1	0	0	
8. Was the reaction more severe when the dose was increased or less severe when the dose was decreased?	+1	0	0	
9. Did the patient have a similar reaction to the same or similar drugs in any previous exposure?	+1	0	0	
10. Was the adverse event confirmed by any objective evidence?	+1	0	0	
Total Score:				

Table 2 Naranjo Score Interpretation

Total Score	Interpretation of Scores
≥9	Definite. The reaction (1) followed a reasonable temporal sequence after a drug or in which a toxic drug level had been established in body fluids or tissues, (2) followed a recognized response to the suspected drug, and (3) was confirmed by improvement on withdrawing the drug and reappeared on re-exposure.
5 to 8	Probable. The reaction (1) followed a reasonable temporal sequence after a drug, (2) followed a recognized response to the suspected drug, (3) was confirmed by withdrawal but not by exposure to the drug, and (4) could not be reasonably explained by the known characteristics of the patient's clinical state.
1 to 4	Possible. The reaction (1) followed a temporal sequence after a drug, (2) possibly followed a recognized pattern to the suspected drug, and (3) could be explained by characteristics of the patient's disease.
≤0	Doubtful. The reaction was likely related to factors other than a drug.

particularly if the renal function is impaired. In retinal vasculitis, further testing for systemic vasculitis should include ANCA, ANA, ENA, dsDNA, in addition to aforementioned tests for uveitis. It is important to note that drug-induced uveitis can still occur in a patient with pre-existing autoimmune uveitis, as these patients may have increased susceptibility to drug-induced inflammation, and it is not always possible to differentiate the two.

General Advice on Management

The definitive management of a drug-induced uveitis usually requires cessation of the offending drug. However, this must be done in consultation with the patient's treating ophthalmologist and physician. As described above, anti-cancer immunotherapy can cause various ocular adverse reactions but the life-prolonging benefit of the medication may outweigh the risk of uveitis. Certain medications may have a suitable alternative that carries a lower risk of uveitis. For example, in patients with inflammatory joint disease who develop etanercept-induced uveitis, the rheumatologist may wish to switch to another TNF inhibitor such as adalimumab or infliximab. [Figure 10](#) presents a flowchart that summarizes the diagnostic and management approach for suspected drug-induced uveitis.

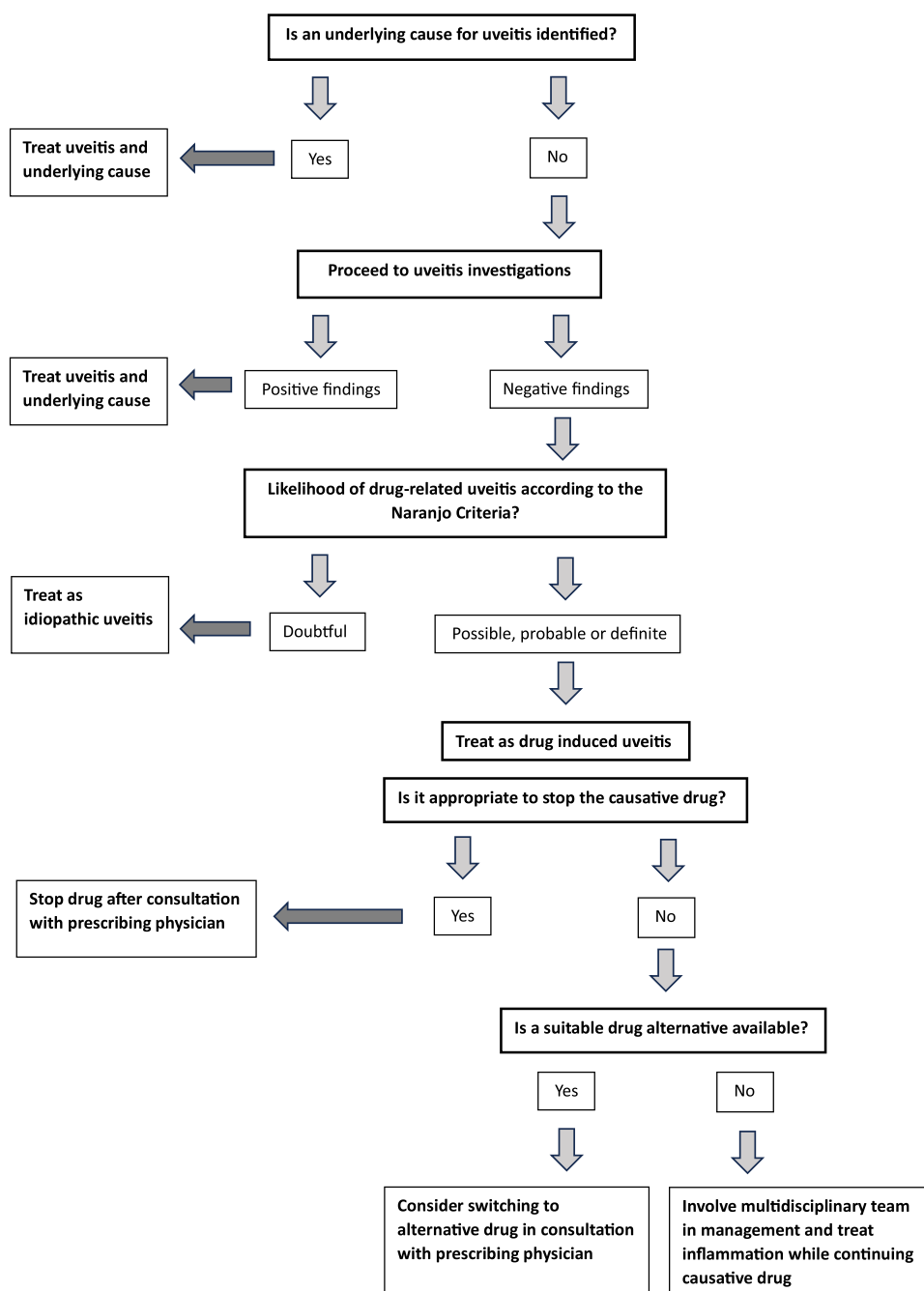


Figure 10 Diagnostic and management approach for drug-induced uveitis.

The mainstay of drug-induced uveitis treatment is corticosteroids. In anterior uveitis, topical steroids will generally suffice, while posterior uveitis and retinal vasculitis will require systemic steroid therapy or local steroid injections. Most cases of drug-induced uveitis carry a good prognosis with prompt diagnosis and treatment and recurrence is low once the causative drug is stopped. Where a rechallenge of the same medication or a trial of a different medication of the same class is planned, we recommend an ophthalmology review within 1–2 weeks of drug retrieval. Working together with the patient's general practitioner and medical specialists will help prevent the future recurrence of uveitis.

Conclusion

Drug-induced uveitis is a complex and often underrecognized entity that underscores the importance of a thorough clinical assessment and a systemic drug history in patients presenting with ocular inflammation. Given the expanding range of medications implicated in uveitis, multidisciplinary collaboration between optometrists, ophthalmologists, rheumatologists, immunologists, general practitioners and pharmacologists is essential for accurate diagnosis and optimal management. Optometrists and ophthalmologists play a pivotal role in early recognition of emerging drug-related associations, as highlighted by recent cases linking vaccines to uveitis. This up-to-date and comprehensive review summarizes the current literature on drug-induced uveitis. Due to the rarity of the condition, the evidence presented consists mainly of case reports and retrospective studies, which is susceptible to reporting bias. Future prospective studies or registries to better quantify incidence and outcomes would improve our understanding of this entity. Vigilance in reporting suspected cases, coupled with robust pharmacovigilance systems, will be crucial in refining our understanding of drug-induced uveitis and mitigating its impact on patient outcomes.

Disclosure

The authors report no conflicts of interest in this work.

References

1. Wakefield D, Chang JH. Epidemiology of uveitis. *Int Ophthalmol Clin*. 2005;45(2):1–13. doi:10.1097/01.iio.0000155938.83083.94
2. Suttorp-Schulten MS, Rothova A. The possible impact of uveitis in blindness: a literature survey. *Br J Ophthalmol*. 1996;80(9):844–848. doi:10.1136/bjo.80.9.844
3. Tomkins-Netzer O, Talat L, Bar A, et al. Long-term clinical outcome and causes of vision loss in patients with uveitis. *Ophthalmology*. 2014;121(12):2387–2392. doi:10.1016/j.ophtha.2014.07.007
4. Niederer RL, Wong ABC, Ma T, Chew S, Sims J. Predictors of glaucoma in patients with uveitis and scleritis. *Eye*. 2023;37(6):1254–1257. doi:10.1038/s41433-022-02101-7
5. Al-Ani HH, Sims JL, Tomkins-Netzer O, Lightman S, Niederer RL. Vision loss in anterior uveitis. *Br J Ophthalmol*. 2020;104(12):1652–1657. doi:10.1136/bjophthalmol-2019-315551
6. Fraunfelder FW, Rosenbaum JT. Drug-induced uveitis. incidence, prevention and treatment. *Drug Saf*. 1997;17(3):197–207. doi:10.2165/00002018-199717030-00005
7. Samalia P, Sims J, Niederer R. Drug-induced ocular inflammation. *N Z Med J*. 2020;133(1527):83–94.
8. Kalogeropoulos D, Asproudis I, Stefanitou M, et al. The large Hellenic study of uveitis: epidemiology, etiologic factors and classification. *Int Ophthalmol*. 2023;43(10):3633–3650. doi:10.1007/s10792-023-02772-5
9. de-la-Torre A, Mejia-Salgado G, Cifuentes-González C, et al. Epidemiology, clinical features, and classification of 3404 patients with uveitis: Colombian uveitis multicenter study (COL-UVEA). *Graefes Arch Clin Exp Ophthalmol*. 2024;262(8):2601–2615. doi:10.1007/s00417-024-06422-z
10. Agarwal M, Dutta Majumder P, Babu K, et al. Drug-induced uveitis: a review. *Indian J Ophthalmol*. 2020;68(9):1799–1807. doi:10.4103/ijo.IJO_816_20
11. Hu J, Vu JT, Hong B, Gottlieb C. Uveitis and cystoid macular oedema secondary to topical prostaglandin analogue use in ocular hypertension and open angle glaucoma. *Br J Ophthalmol*. 2020;104(8):1040–1044. doi:10.1136/bjophthalmol-2019-315280
12. Cordero-Coma M, Salazar-Mendez R, Garzo-Garcia I, Yilmaz T. Drug-induced uveitis. *Expert Opin Drug Saf*. 2015;14(1):111–126. doi:10.1517/14740338.2015.972363
13. Tomkins-Netzer O, Niederer R, Greenwood J, et al. Mechanisms of blood-retinal barrier disruption related to intraocular inflammation and malignancy. *Prog Retin Eye Res*. 2024;99:101245. doi:10.1016/j.preteyeres.2024.101245
14. Iqbal KM, Hay MW, Emami-Naeini P. Medication-induced Uveitis: an Update. *J Ophthalmic Vis Res*. 2021;16(1):84–92. doi:10.18502/jovr.v16i1.8254
15. Jacobs DS, Piliero PJ, Kuperwaser MG, et al. Acute uveitis associated with rifabutin use in patients with human immunodeficiency virus infection. *Am J Ophthalmol*. 1994;118(6):716–722. doi:10.1016/s0002-9394(14)72550-4
16. Testi I, Agarwal A, Agrawal R, et al. Drug-induced uveitis in HIV patients with ocular opportunistic infections. *Ocul Immunol Inflamm*. 2020;28(7):1069–1075. doi:10.1080/09273948.2019.1691240
17. Moorthy RS, Moorthy MS, Cunningham ET. Drug-induced uveitis. *Curr Opin Ophthalmol*. 2018;29(6):588–603. doi:10.1097/ICU.0000000000000530
18. Benage M, Fraunfelder FW. Vaccine-associated uveitis. *Mo Med*. 2016;113(1):48–52.

19. Willis ED, Woodward M, Brown E, et al. Herpes zoster vaccine live: a 10 year review of post-marketing safety experience. *Vaccine*. 2017;35(52):7231–7239. doi:10.1016/j.vaccine.2017.11.013
20. Cunningham ET, Moorthy RS, Fraunfelder FW, Zierhut M. Vaccine-associated uveitis. *Ocul Immunol Inflamm*. 2019;27(4):517–520. doi:10.1080/09273948.2019.1626188
21. Zou Y, Kamoi K, Zong Y, Zhang J, Yang M, Ohno-Matsui K. Ocular inflammation post-vaccination. *Vaccines*. 2023;11(10):1626. doi:10.3390/vaccines11101626
22. Huang X-F, Brown MA. Progress in the genetics of uveitis. *Genes Immun*. 2022;23(2):57–65. doi:10.1038/s41435-022-00168-6
23. Amagai R, Fujimura T, Yamazaki E, et al. Vogt-Koyanagi-Harada disease-like uveitis after drug therapy including BRAF/MEK inhibitors in melanoma patients with HLA-DRB1*04. *J Dermatol*. 2024;51(6):854–857. doi:10.1111/1346-8138.17082
24. Fechtner RD, Khouri AS, Zimmerman TJ, et al. Anterior uveitis associated with latanoprost. *Am J Ophthalmol*. 1998;126(1):37–41. doi:10.1016/s0002-9394(98)00071-3
25. Chauhan MZ, Elhusseiny AM, Marwah S, et al. Incidence of uveitis following initiation of prostaglandin analogs versus other glaucoma medications: a study from the sight outcomes research collaborative repository. *Ophthalmol Glaucoma*. 2024;8(2):126–132. doi:10.1016/j.ogla.2024.10.010
26. Beltz J, Zamir E. Brimonidine induced anterior uveitis. *Ocul Immunol Inflamm*. 2016;24(2):128–133. doi:10.3109/09273948.2015.1037845
27. Hopf S, Mercieca K, Pfeiffer N, Prokosch-Willing V. Brimonidine-associated uveitis - a descriptive case series. *BMC Ophthalmol*. 2020;20(1):489. doi:10.1186/s12886-020-01762-w
28. Boualila L, Bouirig K, El Hamidi S, Boutimzine N, Cherkaoui LO. Brimonidine induced bilateral hypertensive anterior uveitis: case report and review of the literature. *J Fr Ophthalmol*. 2023;46(5):e143–e145. doi:10.1016/j.jfo.2022.10.014
29. Anderson WJ, da Cruz NFS, Lima LH, Emerson GG, Rodrigues EB, Melo GB. Mechanisms of sterile inflammation after intravitreal injection of antiangiogenic drugs: a narrative review. *Int J Retina Vitreous*. 2021;7(1):37. doi:10.1186/s40942-021-00307-7
30. Williams PD, Chong D, Fuller T, Callanan D. Noninfectious vitritis after intravitreal injection of anti-VEGF agents: variations in rates and presentation by medication. *Retina*. 2016;36(5):909–913. doi:10.1097/IAE.0000000000000801
31. Mones J, Srivastava SK, Jaffe GJ, et al. Risk of inflammation, retinal vasculitis, and retinal occlusion-related events with brotacizumab: post hoc review of HAWK and HARRIER. *Ophthalmology*. 2021;128(7):1050–1059. doi:10.1016/j.ophtha.2020.11.011
32. Palmieri F, Younis S, Bedan Hamoud A, Fabozzi L. Uveitis following intravitreal injections of faricimab: a case report. *Ocul Immunol Inflamm*. 2024;32(8):1873–1877. doi:10.1080/09273948.2023.2293925
33. Wong TY, Haskova Z, Asik K, et al. Faricimab treat-and-extend for diabetic macular edema: two-year results from the randomized phase 3 YOSEMITE and RHINE Trials. *Ophthalmology*. 2024;131(6):708–723. doi:10.1016/j.ophtha.2023.12.026
34. Bourdin A, Cohen SY, Nghiem-Buffet S, et al. Vitritis following intravitreal faricimab: a retrospective monocentric analysis. *Graefes Arch Clin Exp Ophthalmol*. 2025;263(4):965–972. doi:10.1007/s00417-025-06736-6
35. Chen X, Wang X, Li X. Intra-ocular inflammation and occlusive retinal vasculitis following intravitreal injections of faricimab: a case report. *Ocul Immunol Inflamm*. 2024;32(10):2544–2547. doi:10.1080/09273948.2024.2361834
36. Li Y, Chong R, Fung AT. Association of occlusive retinal vasculitis with intravitreal faricimab. *JAMA Ophthalmol*. 2024;142(5):489–491. doi:10.1001/jamaophthalmol.2024.0928
37. Witkin AJ, Hahn P, Murray TG, et al. Occlusive retinal vasculitis following intravitreal brotacizumab. *J Vitreoretin Dis*. 2020;4(4):269–279. doi:10.1177/2474126420930863
38. Bauman CR, Spaide RF, Vajzovic L, et al. Retinal vasculitis and intraocular inflammation after intravitreal injection of brotacizumab. *Ophthalmology*. 2020;127(10):1345–1359. doi:10.1016/j.ophtha.2020.04.017
39. Sharma A, Kumar N, Parachuri N, et al. Brotacizumab and immunogenicity. *Eye*. 2020;34(10):1726–1728. doi:10.1038/s41433-020-0853-9
40. Holz FG, Dugel PU, Weissgerber G, et al. Single-chain antibody fragment VEGF inhibitor RTH258 for neovascular age-related macular degeneration: a randomized controlled study. *Ophthalmology*. 2016;123(5):1080–1089. doi:10.1016/j.ophtha.2015.12.030
41. Haug SJ, Hien DL, Uludag G, et al. Retinal arterial occlusive vasculitis following intravitreal brotacizumab administration. *Am J Ophthalmol Case Rep*. 2020;18:100680. doi:10.1016/j.ajoc.2020.100680
42. Israilevich RN, Mansour H, Patel SN, et al. Risk of endophthalmitis based on cumulative number of Anti-VEGF intravitreal injections. *Ophthalmology*. 2024;131(6):667–673. doi:10.1016/j.ophtha.2023.12.033
43. Marticorena J, Romano V, Gomez-Ulla F. Sterile endophthalmitis after intravitreal injections. *Mediators Inflamm*. 2012;2012:928123. doi:10.1155/2012/928123
44. Roth DB, Chieh J, Spirm MJ, Green SN, Yarian DL, Chaudhry NA. Noninfectious endophthalmitis associated with intravitreal triamcinolone injection. *Arch Ophthalmol*. 2003;121(9):1279–1282. doi:10.1001/archophth.121.9.1279
45. Chen SD, Lochhead J, McDonald B, Patel CK. Pseudohypopyon after intravitreal triamcinolone injection for the treatment of pseudophakic cystoid macular edema. *Br J Ophthalmol*. 2004;88(6):843–844. doi:10.1136/bjo.2003.033589
46. Rybak MJ. The pharmacokinetic and pharmacodynamic properties of vancomycin. *Clin Infect Dis*. 2006;42 Suppl 1(Supplement_1):S35–9. doi:10.1086/491712
47. Witkin AJ, Chang DF, Jumper JM, et al. Vancomycin-associated hemorrhagic occlusive retinal vasculitis: clinical characteristics of 36 eyes. *Ophthalmology*. 2017;124(5):583–595. doi:10.1016/j.ophtha.2016.11.042
48. Witkin AJ, Shah AR, Engstrom RE, et al. Postoperative hemorrhagic occlusive retinal vasculitis: expanding the clinical spectrum and possible association with vancomycin. *Ophthalmology*. 2015;122(7):1438–1451. doi:10.1016/j.ophtha.2015.03.016
49. Ehmann DS, Adam MK, Kasi SK, Sivalingam A, Dunn JP. Hemorrhagic occlusive retinal vasculitis and nonhemorrhagic vasculitis after uncomplicated cataract surgery with intracameral vancomycin. *Retin Cases Brief Rep*. 2017;11 Suppl 1(1):S155–S158. doi:10.1097/ICB.0000000000000389
50. Todorich B, Faia LJ, Thanos A, et al. Vancomycin-associated hemorrhagic occlusive retinal vasculitis: a clinical-pathophysiological analysis. *Am J Ophthalmol*. 2018;188:131–140. doi:10.1016/j.ajo.2018.01.030
51. Arepalli S, Modi YS, Deasy R, Srivastava SK. Mild bilateral hemorrhagic occlusive retinal vasculitis following intracameral vancomycin administration in cataract surgery. *Ophthalmic Surg Lasers Imag Retina*. 2018;49(5):369–373. doi:10.3928/23258160-20180501-12

52. Matovic K, Mekjavic PJ, Groznik AL, et al. Vancomycin-associated hemorrhagic occlusive retinal vasculitis: a case series and systematic review. *Ophthalmic Surg Lasers Imag Retina*. 2022;53(12):702–712. doi:10.3928/23258160-20221026-03
53. Scott RA, Pavesio C. Ocular side-effects from systemic HPMPC (Cidofovir) for a non-ocular cytomegalovirus infection. *Am J Ophthalmol*. 2000;130(1):126–127. doi:10.1016/s0002-9394(00)00486-4
54. Ambati J, Wynne KB, Angerame MC, Robinson MR. Anterior uveitis associated with intravenous cidofovir use in patients with cytomegalovirus retinitis. *Br J Ophthalmol*. 1999;83(10):1153–1158. doi:10.1136/bjo.83.10.1153
55. Cochereau I, Doan S, Diraison MC, et al. Uveitis in patients treated with intravenous cidofovir. *Ocul Immunol Inflamm*. 1999;7(3–4):223–229. doi:10.1076/ocii.7.3.223.3999
56. Lopez V, Sola E, Gutierrez C, et al. Anterior uveitis associated with treatment with intravenous cidofovir in kidney transplant patients with BK virus nephropathy. *Transplant Proc*. 2006;38(8):2412–2413. doi:10.1016/j.transproceed.2006.08.067
57. Cunningham ET. Uveitis in HIV positive patients. *Br J Ophthalmol*. 2000;84(3):233–235. doi:10.1136/bjo.84.3.233
58. Wang HH, Chung YM, Lin YC, Hu HC, Wong WW. Rifabutin-induced hypopyon uveitis in patients with acquired immunodeficiency syndrome infected with Mycobacterium avium complex. *J Chin Med Assoc*. 2007;70(3):136–139. doi:10.1016/S1726-4901(09)70345-4
59. Jetton J, Gavia JG, Patterson TF, Johnson DA. Rifabutin-associated uveitis in an immunocompetent individual with Mycobacterium simiae. *Can J Ophthalmol*. 2009;44(4):468–469. doi:10.3129/j09-103
60. Smith WM, Reddy MG, Hutcheson KA, Bishop RJ, Sen HN. Rifabutin-associated hypopyon uveitis and retinal vasculitis with a history of acute myeloid leukemia. *J Ophthalmic Inflamm Infect*. 2012;2(3):149–152. doi:10.1007/s12348-012-0059-9
61. Nair N, Sudharshan S, Koladiya NA, Biswas J. Rifabutin induced hypopyon uveitis mimicking endophthalmitis as a manifestation of IRU in patients with HIV. *Indian J Pharmacol*. 2022;54(1):67–68. doi:10.4103/ijp.ijp_62_22
62. Sood S, Du J, Chen A, Medina A, Do BK. Segmental retinal arteritis in a case of presumed bilateral rifabutin-associated hypopyon uveitis. *Am J Ophthalmol Case Rep*. 2024;36:102170. doi:10.1016/j.ajoc.2024.102170
63. Tan YL, Sims J, Chee SP. Bilateral uveitis secondary to bisphosphonate therapy. *Ophthalmologica*. 2009;223(3):215–216. doi:10.1159/000202646
64. Fraunfelder FW, Fraunfelder FT, Jensvold B. Scleritis and other ocular side effects associated with pamidronate disodium. *Am J Ophthalmol*. 2003;135(2):219–222. doi:10.1016/s0002-9394(02)01840-8
65. Peterson JD, Bedrossian EH. Bisphosphonate-associated orbital inflammation—a case report and review. *Orbit*. 2012;31(2):119–123. doi:10.3109/01676830.2011.648818
66. Gendelman O, Tripto-Shkolnik L, Vered I, Lidar M. Bisphosphonates related ocular side effects: a case series and review of literature. *Ocul Immunol Inflamm*. 2022;30(7–8):1995–1999. doi:10.1080/09273948.2021.1922705
67. Chartrand NA, Lau CK, Parsons MT, et al. Ocular side effects of bisphosphonates: a review of literature. *J Ocul Pharmacol Ther*. 2023;39(1):3–16. doi:10.1089/jop.2022.0094
68. Olson K, Van Poznak C. Significance and impact of bisphosphonate-induced acute phase responses. *J Oncol Pharm Pract*. 2007;13(4):223–229. doi:10.1177/1078155207080806
69. Hewitt RE, Lissina A, Green AE, Slay ES, Price DA, Sewell AK. The bisphosphonate acute phase response: rapid and copious production of proinflammatory cytokines by peripheral blood gd T cells in response to aminobisphosphonates is inhibited by statins. *Clin Exp Immunol*. 2005;139(1):101–111. doi:10.1111/j.1365-2249.2005.02665.x
70. Patel DV, Horne A, House M, Reid IR, McGhee CN. The incidence of acute anterior uveitis after intravenous zoledronate. *Ophthalmology*. 2013;120(4):773–776. doi:10.1016/j.ophtha.2012.10.028
71. Patel DV, Bolland M, Nisa Z, et al. Incidence of ocular side effects with intravenous zoledronate: secondary analysis of a randomized controlled trial. *Osteoporos Int*. 2015;26(2):499–503. doi:10.1007/s00198-014-2872-5
72. Wu Z, Sun W, Zhou Y, Wang C. Clinical features, treatment, and prognosis of zoledronic acid-induced uveitis. *Eye*. 2025;39(3):538–543. doi:10.1038/s41433-024-03586-0
73. Patel DV, Horne A, Mihov B, Stewart A, Reid IR, McGhee CN. The effects of re-challenge in patients with a history of acute anterior uveitis following intravenous zoledronate. *Calcif Tissue Int*. 2015;97(1):58–61. doi:10.1007/s00223-015-0015-4
74. American college of rheumatology: tumor necrosis factor (TNF) Inhibitors. 2024. Available from: <https://rheumatology.org/patients/tumor-necrosis-factor-tnf-inhibitors>. Accessed January 02, 2025.
75. Smith JR, Levinson RD, Holland GN, et al. Differential efficacy of tumor necrosis factor inhibition in the management of inflammatory eye disease and associated rheumatic disease. *Arthritis Rheum*. 2001;45(3):252–257. doi:10.1002/1529-0131(200106)45:3<252::AID-ART257>3.0.CO;2-5
76. Wang F, Wang NS. Etanercept therapy-associated acute uveitis: a case report and literature review. *Clin Exp Rheumatol*. 2009;27(5):838–839.
77. Singla MB, Hodge DK, Moawad FJ. Infliximab-induced anterior uveitis in a patient with ulcerative Colitis. *J Crohns Colitis*. 2015;9(5):432. doi:10.1093/ecco-jcc/ijv030
78. Bouladi M, Ben Othmen A, Sawssen M, Kalou M, Laater A, El Fekih L. New onset of uveitis during infliximab treatment: a case report. *Tunis Med*. 2024;102(1):58–60. doi:10.62438/tunismed.v102i1.4564
79. Lim LL, Fraunfelder FW, Rosenbaum JT. Do tumor necrosis factor inhibitors cause uveitis? A registry-based study. *Arthritis Rheum*. 2007;56(10):3248–3252. doi:10.1002/art.22918
80. Wendling D, Paccou J, Berthelot JM, et al. New onset of uveitis during anti-tumor necrosis factor treatment for rheumatic diseases. *Semin Arthritis Rheum*. 2011;41(3):503–510. doi:10.1016/j.semarthrit.2011.05.005
81. Lie E, Lindstrom U, Zverkova-Sandstrom T, et al. Tumour necrosis factor inhibitor treatment and occurrence of anterior uveitis in ankylosing spondylitis: results from the Swedish biologics register. *Ann Rheum Dis*. 2017;76(9):1515–1521. doi:10.1136/annrheumdis-2016-210931
82. Kwon HY, Kim YJ, Kim TH, Ahn SJ. Comparison of incidence or recurrence of anterior uveitis in patients with ankylosing spondylitis treated with tumor necrosis factor inhibitors. *J Clin Med*. 2024;13(3):912. doi:10.3390/jcm13030912
83. Cunningham ET, Pasadhika S, Suhler EB, Zierhut M. Drug-induced inflammation in patients on TNFalpha inhibitors. *Ocul Immunol Inflamm*. 2012;20(1):2–5. doi:10.3109/09273948.2011.644383
84. Sobolewska B, Baglivo E, Edwards AO, et al. Drug-induced sarcoid uveitis with biologics. *Ocul Immunol Inflamm*. 2022;30(4):907–914. doi:10.1080/09273948.2020.1850799

85. Reddy AR, Backhouse OC. Does etanercept induce uveitis? *Br J Ophthalmol*. 2003;87(7):925. doi:10.1136/bjo.87.7.925
86. Wang Q, Wen Z, Cao Q. Risk of tuberculosis during infliximab therapy for inflammatory bowel disease, rheumatoid arthritis, and spondyloarthritis: a meta-analysis. *Exp Ther Med*. 2016;12(3):1693–1704. doi:10.3892/etm.2016.3548
87. Hernanz I, Miguel Escuder L, Chamorro L, et al. Tuberculosis-related uveitis in patients under anti-TNF-alpha therapy: a case series. *Ocul Immunol Inflamm*. 2022;30(4):839–844. doi:10.1080/09273948.2020.1834588
88. Ganesh S, Thatikonda D. A case report of probable ocular tuberculosis following biologics. *Indian J Ophthalmol*. 2021;1(4):683. doi:10.4103/ijo.IJO_227_21
89. Dalvin LA, Shields CL, Orloff M, Sato T, Shields JA. Checkpoint inhibitor immune therapy: systemic Indications and ophthalmic side effects. *Retina*. 2018;38(6):1063–1078. doi:10.1097/iae.0000000000002181
90. Vaddepally RK, Kharel P, Pandey R, Garje R, Chandra AB. Review of indications of FDA-approved immune checkpoint inhibitors per NCCN guidelines with the level of evidence. *Cancers*. 2020;12(3):738. doi:10.3390/cancers12030738
91. Brahmer JR, Lacchetti C, Schneider BJ, et al. Management of immune-related adverse events in patients treated with immune checkpoint inhibitor therapy: American society of clinical oncology clinical practice guideline. *J Clin Oncol*. 2018;36(17):1714–1768. doi:10.1200/JCO.2017.77.6385
92. Bhatti MT, Salama AKS. Neuro-ophthalmic side effects of molecularly targeted cancer drugs. *Eye*. 2018;32(2):287–301. doi:10.1038/eye.2017.222
93. Shahzad O, Thompson N, Clare G, Welsh S, Damato E, Corrie P. Ocular adverse events associated with immune checkpoint inhibitors: a novel multidisciplinary management algorithm. *Ther Adv Med Oncol*. 2021;13:1758835921992989. doi:10.1177/1758835921992989
94. Martens A, Schauwvlieghe PP, Madoe A, Casteels I, Aspeslagh S. Ocular adverse events associated with immune checkpoint inhibitors, a scoping review. *J Ophthalmic Inflamm Infect*. 2023;13(1):5. doi:10.1186/s12348-022-00321-2
95. Wu Z, Sun W, He B, Wang C. Clinical characteristics, treatment, and outcomes of nivolumab-induced uveitis. *Immunopharmacol Immunotoxicol*. 2025;1–6. doi:10.1080/08923973.2025.2461056
96. Dow ER, Yung M, Tsui E. Immune checkpoint inhibitor-associated uveitis: review of treatments and outcomes. *Ocul Immunol Inflamm*. 2021;29(1):203–211. doi:10.1080/09273948.2020.1781902
97. Braun D, Getahun D, Chiu VY, et al. Population-based frequency of ophthalmic adverse events in melanoma, other cancers, and after immune checkpoint inhibitor treatment. *Am J Ophthalmol*. 2021;224:282–291. doi:10.1016/j.ajo.2020.12.013
98. Sun Mm Md P, Levinson RM, Filipowicz AD, et al. Uveitis in patients treated with CTLA-4 and PD-1 checkpoint blockade inhibition. *Ocul Immunol Inflamm*. 2020;28(2):217–227. doi:10.1080/09273948.2019.1577978
99. Sumimoto H, Noda S, Koide H, et al. Pre-existing autoimmune disease as a risk factor for immune-related adverse events in cancer patients receiving immune checkpoint inhibitors. *PLoS One*. 2024;19(7):e0306995. doi:10.1371/journal.pone.0306995
100. Cunningham ET, Moorthy RS, Zierhut M. Immune checkpoint inhibitor-induced uveitis. *Ocul Immunol Inflamm*. 2020;28(6):847–849. doi:10.1080/09273948.2020.1801286
101. Zhang H, Houadj L, Wu KY, Tran SD. Diagnosing and managing uveitis associated with immune checkpoint inhibitors: a review. *Diagnostics*. 2024;14(3). doi:10.3390/diagnostics14030336
102. Manusow JS, Khoja L, Pesin N, Joshua AM, Mandelcorn ED. Retinal vasculitis and ocular vitreous metastasis following complete response to PD-1 inhibition in a patient with metastatic cutaneous melanoma. *J Immunother Cancer*. 2014;2(1):41. doi:10.1186/s40425-014-0041-1
103. Mackin AG, Peccei PE, Dinsmore AL, et al. Inflammatory side effects of BRAF and MEK inhibitors. *Melanoma Res*. 2019;29(5):522–526. doi:10.1097/CMR.0000000000000599
104. Dimitriou F, Urner-Bloch U, Eggenschwiler C, et al. The association between immune checkpoint or BRAF/MEK inhibitor therapy and uveitis in patients with advanced cutaneous melanoma. *Eur J Cancer*. 2021;144:215–223. doi:10.1016/j.ejca.2020.11.027
105. Food and drug administration: oncology (Cancer)/hematologic malignancies approval notifications. Available from: <https://www.fda.gov/drugs/resources-information-approved-drugs/oncology-cancerhematologic-malignancies-approval-notifications>. Accessed December 02, 2025.
106. Choe CH, McArthur GA, Caro I, Kempen JH, Amaravadi RK. Ocular toxicity in BRAF mutant cutaneous melanoma patients treated with vemurafenib. *Am J Ophthalmol*. 2014;158(4):831–837.e2. doi:10.1016/j.ajo.2014.07.003
107. Jung H, Kim S, Lee CS, et al. Real-world incidence of incident noninfectious uveitis in patients treated with BRAF inhibitors: a nationwide clinical cohort study. *Am J Ophthalmol*. 2024;267:142–152. doi:10.1016/j.ajo.2024.07.002
108. Samalia P, Niederer R. Reversible BRAF inhibitor-induced acute exudative paraneoplastic polymorphous vitelliform maculopathy. *N Z Med J*. 2021;134(1540):89–92.
109. Sandhu HS, Kolomeyer AM, Lau MK, et al. Acute exudative paraneoplastic polymorphous vitelliform maculopathy during vemurafenib and pembrolizumab treatment for metastatic melanoma. *Retin Cases Brief Rep*. 2019;13(2):103–107. doi:10.1097/icb.0000000000000604
110. Mendez-Martinez S, Calvo P, Ruiz-Moreno O, et al. Ocular adverse events associated with mek inhibitors. *Retina*. 2019;39(8):1435–1450. doi:10.1097/IAE.0000000000002451
111. Urner-Bloch U, Urner M, Jaberg-Bentele N, Frauchiger AL, Dummer R, Goldinger SM. MEK inhibitor-associated retinopathy (MEKAR) in metastatic melanoma: long-term ophthalmic effects. *Eur J Cancer*. 2016;65:130–138. doi:10.1016/j.ejca.2016.06.018
112. Thureau S, Engelke H, McCluskey P, et al. Uveitis in tumor patients treated with immunological checkpoint- and signal transduction pathway-inhibitors. *Ocul Immunol Inflamm*. 2022;30(7–8):1588–1594. doi:10.1080/09273948.2021.1910850
113. Wang MTM, Niederer RL, McGhee CNJ, Danesh-Meyer HV. COVID-19 vaccination and the eye. *Am J Ophthalmol*. 2022;240:79–98. doi:10.1016/j.ajo.2022.02.011
114. Habet-Wilner Z, Neri P, Okada AA, et al. COVID vaccine-associated uveitis. *Ocul Immunol Inflamm*. 2023;31(6):1198–1205. doi:10.1080/09273948.2023.2200858
115. Tomkins-Netzer O, Sar S, Barnett-Griness O, Friedman B, Shyriaeva H, Saliba W. Association between vaccination with the BNT162b2 mRNA coronavirus disease 2019 vaccine and noninfectious uveitis: a population-based study. *Ophthalmology*. 2022;129(10):1087–1095. doi:10.1016/j.ophtha.2022.05.015
116. Goyal M, Murthy SI, Annum S. Bilateral multifocal choroiditis following COVID-19 vaccination. *Ocul Immunol Inflamm*. 2021;29(4):753–757. doi:10.1080/09273948.2021.1957123

117. Kakarla PD, Venugopal R, Manechala UB, Rijey J, Anthwal D. Bilateral multifocal choroiditis with disc edema in a 15-year-old girl following COVID-19 vaccination. *Indian J Ophthalmol.* **2022**;70(9):3420–3421. doi:10.4103/ijo.IJO_861_22
118. Mohamed S, Chan CKM, Tsang CW, et al. Case report: retinal vasculitis in two adolescents after COVID-19 vaccination. *Ocul Immunol Inflammation.* **2023**;31(6):1245–1249. doi:10.1080/09273948.2022.2129694
119. Yi Z, Chen L, Zheng H, Chen C. Retinal vasculitis following COVID-19 vaccination: causation or coincidence? *Ocul Immunol Inflammation.* **2023**;31(6):1283–1285. doi:10.1080/09273948.2023.2176887
120. Sanjay S, Handa A, Kawali A, Shetty R, Bhakti Mishra S, Mahendradas P. Scleritis and episcleritis following coronavirus disease (COVID-19) vaccination. *Ocul Immunol Inflammation.* **2023**;31(6):1184–1190. doi:10.1080/09273948.2023.2182324
121. Koong LR, Chee WK, Toh ZH, Ng XL, Agrawal R, Ho SL. Vogt-Koyanagi-Harada disease associated with COVID-19 mRNA vaccine. *Ocul Immunol Inflamm.* **2021**;29(6):1212–1215. doi:10.1080/09273948.2021.1974492
122. Accorinti M, Saturno MC, Manni P. Vogt-Koyanagi-Harada relapse after COVID-19 vaccination. *Ocul Immunol Inflamm.* **2022**;30(5):1228–1233. doi:10.1080/09273948.2022.2027469
123. Inagawa S, Onda M, Miyase T, et al. Multiple evanescent white dot syndrome following vaccination for COVID-19: a case report. *Medicine.* **2022**;101(2):e28582. doi:10.1097/MD.0000000000002852
124. Ng HW, Niederer RL. Lightning can strike twice: recurrent multiple evanescent white dot syndrome (MEWDS) following both COVID-19 vaccination and subsequent COVID-19 infection. *J Ophthalmic Inflamm Infect.* **2023**;13(1):36. doi:10.1186/s12348-023-00355-0
125. Jakirlic N, Harris T. Case report: acute posterior multifocal placoid pigment epitheliopathy after SARS-CoV-2 vaccination. *Optom Vis Sci.* **2022**;99(6):534–539. doi:10.1097/OPX.0000000000001900
126. Mambretti M, Huemer J, Torregrossa G, Ullrich M, Findl O, Casalino G. Acute macular neuroretinopathy following coronavirus disease 2019 vaccination. *Ocul Immunol Inflamm.* **2021**;29(4):730–733. doi:10.1080/09273948.2021.1946567
127. Druke D, Pleyer U, Hoerauf H, Feltgen N, Bemme S. Acute macular neuroretinopathy (AMN) following COVID-19 vaccination. *Am J Ophthalmol Case Rep.* **2021**;24:101207. doi:10.1016/j.ajoc.2021.101207
128. Book BAJ, Schmidt B, Foerster AMH. Bilateral acute macular neuroretinopathy after vaccination against SARS-CoV-2. *JAMA Ophthalmol.* **2021**;139(7):e212471. doi:10.1001/jamaophthalmol.2021.2471
129. Vinzamuri S, Pradeep TG, Kotian R. Bilateral paracentral acute middle maculopathy and acute macular neuroretinopathy following COVID-19 vaccination. *Indian J Ophthalmol.* **2021**;69(10):2862–2864. doi:10.4103/ijo.IJO_1333_21
130. Maleki A, Look-Why S, Manhapra A, Foster CS. COVID-19 recombinant mRNA vaccines and serious ocular inflammatory side effects: real or coincidence? *J Ophthalmic Vis Res.* **2021**;16(3):490–501. doi:10.18502/jovr.v16i3.9443
131. Lee Y-K, Huang Y-H. Ocular manifestations after receiving COVID-19 vaccine: a systematic review. *Vaccines.* **2021**;9(12):1404. doi:10.3390/vaccines9121404
132. Testi I, Brandão-de-Resende C, Agrawal R, et al. Ocular inflammatory events following COVID-19 vaccination: a multinational case series. *J Ophthalmic Inflamm Infection.* **2022**;12(1):4. doi:10.1186/s12348-021-00275-x
133. Scott DAR, Niederer RL. Punctate Inner Choroidopathy (PIC) disease recurrence with inflammatory choroidal neovascular membrane (iCNVM) post-COVID-19 vaccine. *Eur J Ophthalmol.* **2024**;34(5):NP78–NP82. doi:10.1177/11206721241257969
134. Ng HW, Scott DAR, Danesh-Meyer HV, Smith JR, McGhee CN, Niederer RL. Ocular manifestations of COVID-19. *Prog Retin Eye Res.* **2024**;102:101285. doi:10.1016/j.preteyeres.2024.101285
135. Jordan CA, Townend S, Allen N, Sims J, McGhee CNJ, Niederer RL. Navigating coronavirus disease 2019 vaccination and uveitis: identifying the rates and risk of recurrent uveitis after coronavirus disease vaccination. *Ophthalmology.* **2023**;130(5):501–508. doi:10.1016/j.ophtha.2022.12.013
136. Cherif YYS, Djeflal C, Abu Serhan H, et al. The characteristics of COVID-19 vaccine-associated uveitis: a summative systematic review. *Vaccines.* **2022**;11(1):69. doi:10.3390/vaccines11010069
137. Geisen UM, Berner DK, Tran F, et al. Immunogenicity and safety of anti-SARS-CoV-2 mRNA vaccines in patients with chronic inflammatory conditions and immunosuppressive therapy in a monocentric cohort. *Ann Rheum Dis.* **2021**;80(10):1306–1311. doi:10.1136/annrheumdis-2021-220272
138. Furer V, Eviatar T, Zisman D, et al. Immunogenicity and safety of the BNT162b2 mRNA COVID-19 vaccine in adult patients with autoimmune inflammatory rheumatic diseases and in the general population: a multicentre study. *Ann Rheum Dis.* **2021**;80(10):1330–1338. doi:10.1136/annrheumdis-2021-220647
139. Shen C, Risk M, Schiopu E, et al. Efficacy of COVID-19 vaccines in patients taking immunosuppressants. *Ann Rheum Dis.* **2022**;81(6):875–880. doi:10.1136/annrheumdis-2021-222045
140. Naranjo CA, Busto U, Sellers EM, et al. A method for estimating the probability of adverse drug reactions. *Clin Pharmacol Ther.* **1981**;30(2):239–245. doi:10.1038/clpt.1981.154

Clinical Optometry

Publish your work in this journal

Clinical Optometry is an international, peer-reviewed, open access journal publishing original research, basic science, clinical and epidemiological studies, reviews and evaluations on clinical optometry. All aspects of patient care are addressed within the journal as well as the practice of optometry including economic and business analyses. Basic and clinical research papers are published that cover all aspects of optics, refraction and its application to the theory and practice of optometry. The manuscript management system is completely online and includes a very quick and fair peer-review system, which is all easy to use. Visit <http://www.dovepress.com/testimonials.php> to read real quotes from published authors.

Submit your manuscript here: <https://www.dovepress.com/clinical-optometry-journal>

Dovepress
Taylor & Francis Group