

Congenital chloride diarrhea: a review of twelve Arabian children

Fawaz Elrefae¹

Ahmed Farag Elhassanien²

Hesham Abdel-Aziz

Alghiaty³

¹Pediatric Gastroenterology, Al-Adan Hospital, Kuwait; ²Faculty of Medicine, Elmansoura University, El Mansoura, El Dakahleya, Egypt; ³Faculty of Medicine, Benha University, Egypt

Background: Congenital chloride diarrhea (CCD), a rare autosomal recessive disorder, is characterized by sustained watery diarrhea (due to defect of active Chloride/HCO₃ exchange in the ileum and colon) with high fecal chloride.

Objective: To spotlight the common presentation of CCD for early management and prevention of complications.

Subjects and methods: This is a retrospective case series study of patients diagnosed as CCD who were followed up in the pediatric department of Al-Adan Hospital, Kuwait.

Results: Twelve patients diagnosed with CCD were born to consanguineous parents; had antenatal history of intrauterine growth retardation (IUGR); polyhydramnios; and distended hypoechoic fetal bowel; and presented with abdominal distension, hypotonia and muscle wasting. 90% of patients had maternal hypertension and 75% of patients had absence of normal meconium at birth. Our patients showed a decrease in serum sodium, potassium, chloride and urine chloride.

Conclusion: A high level of suspicion for an early diagnosis of CCD should be considered for any infant presenting with chronic diarrhea, especially in the presence of consanguineous marriage, and the characteristic features in antenatal ultrasound. Thus, allowing for early investigations and appropriate management.

Keywords: congenital chloride diarrhea, children, chronic diarrhea, metabolic alkalosis, prenatal diagnosis

Introduction

Congenital chloride diarrhea (CCD) is a rare, genetically determined cause of persistent, life threatening, watery diarrhea, which is characterized by excessive chloride loss in stools. CCD is an autosomal recessive disorder. Most cases have been reported in Finland and the Middle East.¹⁻³ Gamble et al,⁴ and Darrow⁵ first described the condition in 1945. Recently, the CCD gene has been accurately located on chromosome 7.⁶

Most children with CCD are born preterm and their antenatal ultrasound usually reveal polyhydramnios with significant dilatation of the fetal intestinal loops.⁷ Postnatally, these children exhibit significant abdominal distension, profuse and watery stools, and failure to thrive. Some infants survive for several months without diagnosis but any intercurrent infection, particularly gastroenteritis, disturbing the delicate water and electrolyte balance can lead to their demise.⁸

Hyponatremia, hypokalemia, hypochloremia, and metabolic alkalosis are features of the disease. High fecal chloride (>100 mmol/L), exceeding the sum of fecal sodium and potassium and a chloride-free urine confirm the diagnosis.⁹

Correspondence: Ahmed Farag Elhassanien
Faculty of Medicine, Elmansoura
University, Elgomhoria Street, El
Mansoura, El Dakahleya, Egypt
Tel +20 50 233 9981
Email ahmedfaraj66@yahoo.com

Since the intestinal defect cannot be corrected, life-long treatment with both sodium and potassium chloride solutions is required. With early diagnosis and adequate treatment children with CCD can achieve normal physical growth and mental development.¹⁰

Aim of the work

The aim of our study is to spotlight antenatal and early neonatal diagnosis of infants with congenital chloride diarrhea which appears not to be an uncommon disorder in Kuwait and Arabian Peninsula for early management and prevention of complications.

Patients and methods

The inpatient database of the Pediatric Department at Al-Adan Hospital, Kuwait was broadly searched for patients with the diagnosis of chronic diarrhea presented in the first year of life. Sixty-seven cases diagnosed between January 2006 and January 2011 were identified. The diagnosis of CCD was based on antenatal onset of clinical presentation and laboratory finding of excess chloride loss in stool and low serum chloride level. Of the 67 patients, twelve patients fulfilled the diagnostic criteria for CCD (seven females and five males). Their ages at diagnosis ranged from antenatal up to 8 months. Seventeen out of 55 were diagnosed as infectious diarrhea, 33 patients as cow's milk protein allergy, three patients as celiac disease, one patient as congenital enteropathy, and one patient as galactose–glucose malabsorption.

Medical records of the patients was obtained from the inpatient medical records. The following data were extracted; history of previous fetal loss, antenatal history (polyhydramnios, maternal hypertension, fetal abdominal distension, distended hypoechoic fetal bowel, intrauterine growth retardation [IUGR]), neonatal history (gestational age, birth weight, prematurity, absence of meconium at birth), age of onset of diarrhea, and age of diagnosis, presenting complaint (diarrhea, loose stool, abdominal distension). Laboratory data were extracted from laboratory reports and progress notes in the individual charts. The laboratory data collected from the files at the time of presentation were; serum electrolytes, serum bicarbonate, blood pH, urine chloride, stool electrolytes, serum aldosterone, and plasma rennin activity. Antenatal ultrasonography reports were available for nine patients. In the cases of available antenatal ultrasonography, radiological and gynecological reports were reviewed.

SPSS program version 11 (IBM Corporation, Armonk, NY, USA) was used to analyze patient data. Descriptive statistics and *t*-test were used to analyze the data.

Results

Twelve patients were diagnosed as CCD; seven females (58.3%) and five males (41.7%). All twelve patients were born to consanguineous parents and two of them were siblings. Antenatal diagnosis was made in four cases, three patients were diagnosed in the neonatal period, three at 2 months, one at 4 months, and one at 8 months of age. Antenatal diagnosis was based on the presence of maternal polyhydramnios, hypertension, and ultrasonographic findings. Ten patients were delivered prematurely (83.33%). All patients (100%) had IUGR, polyhydramnios, and distended hypoechoic fetal bowel but eight patients (66.6%) had maternal hypertension, and nine patients (75%) had fetal abdominal distension. A family history of fetal loss was obtained in six cases (50%). As regards clinical presentation; nine patients (75%) showed absence of normal meconium at birth, six patients (50%) showed stool-like urine and four patients (33.3%) showed abdominal distension. Mild to moderate abdominal distension, hypotonia, and muscle wasting were present in all patients at the time of admission.

In the eight patients with long-term follow-up, weight and linear and head circumference growth have been satisfactory. There had been no developmental delays. Two patients had renal tubular dysfunction after their first year of life.

The laboratory investigations of our patients were compared with that of patients diagnosed as cow's milk protein allergy. Patients with CCD showed significant decrease in serum potassium ($P = 0.001$), serum chloride ($P = 0.001$) and urine chloride ($P = 0.001$) compared with that of patients with cow's milk protein allergy. Whereas serum bicarbonates and stool chloride were significantly increased in our patients with CCD ($P = 0.001$). Our CCD patients showed high stool chloride loss as evidenced by increased ratio stool Cl/serum Cl (1.875 ± 0.508) and stool Cl/Na + K ratio (1.35 ± 0.6274). Increased plasma rennin activity (61.166 ± 15.95) and serum aldosterone (1538 ± 1133), were observed also in our CCD patients.

Discussion

Congenital chloride diarrhea is a rare intestinal disorder affecting electrolyte transportation, presenting clinically with a persistent life-threatening diarrhea with high fecal chloride content (>90 mmol/L).^{1,2} It is inherited as an autosomal recessive disorder with its gene located on chromosome 7.⁶

Since the first case report of CCD published by Gamble et al,⁴ and Darrow⁵ in 1945, more than 140 cases have

Table 1 Summary of clinical finding of congenital chloride diarrhea cases

No	Sex	GA (w)	BW (gm)	Diarrh age (days)	Diagn age	Early clinical neonatal features			Antenatal features suggesting of CCD						
						PT	IUGR	Abs of mecon	Stool like urine	Abd distension	H/O fetal loss	Poly	M hypert	Fetal abd distension	Distended hypoechoic fetal bowel
1	F	35	1650	4	AN	+	+	+	-	+	+	+	+	+	+
2	F	34	1600	6	AN	+	+	+	-	+	+	+	+	+	+
3	F	33	1450	7	LNP	+	+	+	-	+	+	+	+	+	+
4	M	34	1550	5	2 m	+	+	+	+	-	-	+	-	-	+
5	M	37	1900	45	4 m	+	+	+	+	-	-	+	-	+	+
6	M	36	1560	6	LNNP	+	+	+	+	-	-	+	-	+	+
7	F	32	1300	5	2 m	+	+	-	+	-	+	+	-	+	+
8	M	40	2400	75	8 m	-	+	-	+	-	+	+	+	+	+
9	F	40	2200	7	LNP	-	+	-	-	-	-	+	+	-	+
10	F	36	1700	8	AN	+	+	+	+	-	-	+	+	-	+
11	M	34	1500	5	AN	+	+	+	-	-	-	+	+	+	+
12	F	33	1450	7	2 m	+	+	+	-	+	+	+	+	+	+
%					AN 33.3% LNP 25% 2 m 25% 4 m 8.3% 8 m 8.3%	83.3%	100%	75%	50%	33.33%	50%	100%	66.66%	75%	100%

Abbreviations: CCD, congenital chloride diarrhea; GA, gestational age; H/O, history of; BW, birth weight; Diarrh age, age of onset of diarrhea; Diagn age, age of diagnosis; PT, prematurity; IUGR, intrauterine growth retardation; Abs of mecon, absence of meconium; Abd distension, abdominal distension; Poly, polyhydramnios; M hypert, maternal hypertension; Fetal abd distension, Fetal abdominal distension; AN, antenatal; LNP, late neonatal period; M, months; W, weeks.

been recognized all over the world. The incidence of CCD was established to be 1/14,000 in Kuwait² compared to that of Finland 1/43,000.¹ This high incidence in Kuwait may be due to the multigenerational practice of consanguineous marriage and the autosomal recessive manner of inheritance of the disease. Consanguinity was a constant feature in our cases.

Before 31 weeks of gestation, maternal polyhydramnios was evident in all patients (100%), which should attract the attention of obstetricians to the possibility of a CCD affected baby, especially in the presence of distended fetal hypoechoic bowel (Figure 1A and B). This polyhydramnios can be explained presumably by intrauterine diarrhea. The other factors supporting the antenatal diagnosis of CCD were presence of maternal hypertension (eight cases [66.6%]), fetal abdominal distension (nine patients [75%]), and family history of fetal loss (six cases [50%]). These mothers had no hypertension either before or during previous pregnancies, and this high blood pressure settled down after labor. So it seems that maternal hypertension is secondary to the fetal illness, most probably due to high fetal rennin⁹ but this association remains to be established.

Fetal abdominal distension (due to fluid accumulating in their intestine)⁷ can be considered pathognomonic for CCD, however dilated bowel loops could be present in other diseases like cystic fibrosis or intestinal obstruction. However, in cystic fibrosis, the dilated bowel loops are hyperechoic due to the viscosity of meconium¹¹ and in intestinal obstruction dilated intestinal loops is associated with increased peristalsis in few dilated bowel loops.¹²

After delivery, our patients showed watery diarrhea, usually in the early neonatal period in ten patients (83.33%), and after the neonatal period in two patients (16.66%). The diagnosis is often delayed as neonatal stools are usually mistaken as urine. Other features supporting the diagnosis were prematurity in ten patients (83.33%), IUGR in all patients (100%), lack of meconium at birth observed in nine patients (75%), and abdominal distention in four patients (33.3%).

In CCD, there is absence or impairment of active chloride/bicarbonate exchange in both the ileum and colon.

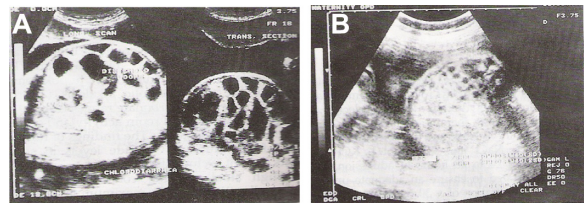


Figure 1 Antenatal ultrasounds. (A and B) show antenatal ultrasounds of two patients with distended fetal hypoechoic intestinal loops.

The defective chloride absorption leads to osmotic diarrhea. This malabsorption also explains the metabolic abnormalities seen in these patients.⁸

Serum electrolytes in our patients before treatment showed hyponatremia, hypokalemia, hypochloremia, and metabolic alkalosis (Table 2). Diagnosis was confirmed by high stool chloride concentration and high stool/serum chloride ratio. Concurrent urine chloride concentration was normal or low. Although CCD is characterized by high stool chloride,¹³ lower fecal chloride content has been reported among infants with severe dehydration as well as in neonates.¹¹ In those patients the ratio of stool Chloride/Na + K is more valuable in the diagnosis of CCD. The mean value in normal stools is 0.24¹³, while in our patients the mean value was 1.35 (range = 0.5–2.3). Fecal/serum chloride ratio was also significantly elevated (1.87) expressing the magnitude of fetal chloride losses (Table 2).

Since the intestinal defect cannot be corrected, life-long treatment with both sodium and potassium chloride solutions is required. The rationale behind this therapy is the normal jejunal absorption of these electrolytes. Such treatment will not correct the diarrhea but will prevent its secondary effects. With early diagnosis and adequate treatment, children with CCD can achieve normal physical growth and mental development. Treatment of our patients started by adequate replacement of chloride with sodium and potassium salts, initially intravenously and subsequently orally. Oral therapy was started in our patients within 24 to 48 hours of admission. The dose was titrated to ensure adequate urinary chloride concentration of >30 mmol/L

Table 2 Comparison of demographic and laboratory data of congenital chloride diarrhea and cow's milk protein allergy patients

	CCD patients (n = 12)	Cow's milk protein allergy patients (n = 33)	P-value
Serum Na	131.75 ± 5.01	134 ± 4.03	0.059
Serum K	2.708 ± 0.36	3.6 ± 1.9	0.001*
Serum Cl	77.98 ± 16.21	105 ± 5.8	0.001*
Serum HCO ₃	36 ± 6.367	23 ± 3.2	0.001*
Blood pH	7.4025 ± 0.12	7.31 ± 0.5	0.02*
Stool Cl (20 ± 4 mmol/L)	150 ± 55.1	14.5 ± 2.4	0.001*
Stool Cl/ serum Cl (0.2)	1.875 ± 0.508	0.185 ± 0.06	0.001*
Urine Cl (8–30 mmol/L)	7.5833 ± 6.0971	21.3 ± 3.2	0.001*

Note: *significant if $P < 0.05$.
Abbreviation: CCD, congenital chloride diarrhea.

(indicator of normal extracellular fluid volume and adequacy of the chloride substitution dose).¹⁴ All patients had excellent clinical responses with increased alertness, weight gain, and increased muscle tone. However, 20% of the cases had developmental delay which may be due to their late diagnosis and treatment.¹⁵

The most common complications occurring in those patents were renal tubular dysfunction resulting from chronic hypovolemia and hypokalemia, and volvulus which may occur at any age from 2 days to 15 years.¹⁰ Many studies have shown that renal calcium deposits with arrested renal growth and impaired renal function were significant in patients with CCD.^{15,16} Our patients did not show any impaired renal growth or functions, or evidence of nephrocalcinosis on follow-up, a finding reported also by Kagalwalla³ but this may be due to early diagnosis and receiving adequate therapy.

Conclusion

Diagnosis of CCD must be considered in any newborn presenting with prolonged diarrhea especially in the presence of consanguineous marriage, maternal polyhydramnios, and antenatal hypertension. In these suspected cases antenatal ultrasound should concentrate on characteristic features of the disease in fetal intestine and early investigations and appropriate management should be instituted postnatally.

Disclosure

The authors report no conflicts of interest in this work.

References

1. Holmberg C, Perheentupa J, Launiala K, Hallman N. Congenital chloride diarrhea; clinical analysis of 21 Finnish patients. *Arch Dis Child.* 1977;52:255–267.
2. Lubani MM, Doudin KI, Sharda DC, et al. Congenital chloride diarrhea in Kuwaiti children. *Eur J Pediatr.* 1989;148:333–336.
3. Kagalwalla AF. Congenital chloride diarrhea; a study in Arab children. *J Clin Gastroenterol.* 1994;19:36–40.
4. Gamble JL, Fahey KR, Appleton I, MacLachlan EA. Congenital alkalosis with diarrhea. *J Ped.* 1945;26:509–518.
5. Darrow DC. Congenital alkalosis with diarrhea: *J Ped.* 1945;26: 519–532.
6. Hoglund P, Sistonen P, Norio R, et al. Fine mapping of congenital chloride diarrhea gene by linkage disequilibrium. *Am J Hum Genet.* 1995;57:95–102.
7. Kirkinen P, Jouppila P. Prenatal ultrasonic findings in congenital chloride diarrhea. *Prenat Diagn.* 1984;4:457–461.
8. Turnberg LA. Abnormalities in intestinal electrolyte transport in congenital chloride diarrhea. *GVT.* 1971;12:544–551.
9. Holmberg C. Electrolyte economy and its hormonal regulation in congenital chloride diarrhea. *Pediatr Res.* 1978;12:82–86.
10. Lundkvist K, Anneen G, Esscher T, Weald U, Hardell L. Surgical implication of congenital chloride diarrhea. *Z Kinderchir.* 1983;38: 217–219.
11. Nyberg DA, Mastrup H, Mack LH. Dilated fetal bowel: a sonographic sign of cyst fibrosis. *J Ultrasound Med.* 1987;6:257–260.
12. Lundkvist K, Ewald, V, Lindgren PG. Congenital chloride diarrhea: a prenatal differential diagnosis of small bowel atresia. *Acta Pediatr.* 1996;53(3):295–298.
13. Ghislian W. Gastrointestinal disease. In: Ichikawa I, editor. *Pediatric Text Book of Fluids and Electrolytes.* Baltimore: Williams & Wilkins Publishers; 1990:385.
14. Peter JM. Congenital diarrhea. In: Field, editor. *Current Topics in Gastroenterology.* New York: El Serier Science Publishing Co; 1991: 373–394.
15. Al-Abbad A, Nazer H, Sanjad A, Al-Sabban E. Congenital chloride diarrhea: A single center experience with 10 patients. *Ann Saudi Med.* 1995;15(5):466–469.
16. Holmberg C, Perheentupa J, Pasternack A. The renal lesions in congenital chloride diarrhea. *J Pediatr.* 1997;91:738–743.

Clinical and Experimental Gastroenterology

Publish your work in this journal

Clinical and Experimental Gastroenterology is an international, peer-reviewed, open access journal, publishing all aspects of gastroenterology in the clinic and laboratory, including: Pathology, pathophysiology of gastrointestinal disease; Investigation and treatment of gastrointestinal disease; Pharmacology of drugs used in the alimentary tract;

Submit your manuscript here: <http://www.dovepress.com/clinical-and-experimental-gastroenterology-journal>

Dovepress

Immunology/genetics/genomics related to gastrointestinal disease. This journal is indexed on CAS. The manuscript management system is completely online and includes a very quick and fair peer-review system. Visit <http://www.dovepress.com/testimonials.php> to read real quotes from published authors.