

Nimotuzumab as a radiosensitizing agent in the treatment of high grade glioma: challenges and opportunities

Arlhee Diaz-Miqueli^{1,*}
Giselle Saurez Martinez^{2,*}

¹Department of System Biology, Center of Molecular Immunology, Havana, Cuba; ²Medical Division, Center of Molecular Immunology, Havana, Cuba

*Both authors contributed equally to this manuscript

Abstract: Nimotuzumab is a humanized monoclonal antibody that binds specifically to human epidermal growth factor receptor, blocking receptor activation. Evidence of its radiosensitizing capacity has been widely evaluated. This article integrates published research findings regarding the role of nimotuzumab in the treatment of high grade glioma in combination with radiotherapy or radiochemotherapy in adult and pediatric populations. First, the mechanisms of action of nimotuzumab and its current applications in clinical trials containing both radiation and chemoradiation therapies are reviewed. Second, a comprehensive explanation of potential mechanisms driving radiosensitization by nimotuzumab in experimental settings is given. Finally, future directions of epidermal growth factor receptor targeting with nimotuzumab in combination with radiation containing regimens, based on its favorable toxicity profile, are proposed. It is hoped that this review may provide further insight into the rational design of new approaches employing nimotuzumab as a useful alternative for the therapeutic management of high grade glioma.

Keywords: nimotuzumab, radiation, high grade gliomas

Introduction

Gliomas are the most frequently occurring primary tumor of the central nervous system, classified as grade 1 to 4 on the basis of histopathological features and clinical criteria established by the World Health Organization. This classification includes pilocytic astrocytoma (grade 1), diffuse astrocytoma (grade 2), anaplastic astrocytoma ([AA] grade 3), and glioblastoma multiform ([GBM] grade 4).¹ Grade 3 and 4 tumors are considered malignant or high grade gliomas (HGG). HGG are the most aggressive form of primary brain tumor without an effective therapy. Despite its relatively low incidence, which is approximately 5 cases per 100,000 people,² the highly aggressive nature of this tumor remains a challenge for oncologists. HGG usually proliferate and invade extensively into surrounding areas in the brain yielding short life expectancies despite new aggressive modalities of treatment. Therefore, a need for further therapy options, as well as new approaches that evaluate potential combinations of existing modality treatments, is urgently needed. The aim of this review is to integrate published research findings regarding the role of nimotuzumab, a monoclonal antibody against the epidermal growth factor receptor (EGFR) in combination with radiotherapy and chemoradiation in the treatment of HGG, focusing on its additional value for enhancing the efficacy of radiotherapy through accumulated nonclinical and clinical evidence.

Correspondence: Arlhee Diaz-Miqueli
Center of Molecular Immunology,
216 St, PO Box 16040,
Havana 11600, Cuba
Tel +53 7 271 5057
Fax +53 7 273 3509
Email arlhee@cim.sld.cu

Current standard therapies in HGG

The current standard treatment in HGG consists of a combined approach of surgery and radiation, or combined radiation and chemotherapy, depending on the site of the disease as well as a patient's health condition.^{3,4} Surgery is the first treatment choice and a maximal surgical resection is indicated whenever possible. However, because of their highly infiltrative nature, HGG cannot be completely eliminated surgically. Indeed, the value of surgery in prolonging patient survival is still controversial.⁵⁻⁸

Subsequent to an optimal surgical resection or biopsy, ionizing radiation is the dominant form of therapy administered postoperatively, prolonging median survival for a maximum of 6 to 8 months.² Indeed, ionizing radiation is prescribed in the majority of patients with HGG. However, despite the fact that new methods have increased the therapeutic potential of radiation in oncology, a curative treatment remains dismal. The local failure of radiotherapy has been previously outlined by others with respect to the application of sublethal doses of irradiation that may promote the migration and invasiveness of glioma cells.⁹ Tumor recurrences at the original site invariably occur after radiation therapy impairing its efficacy.¹⁰ Migrating tumor cells may reach the edges of the target volume of postoperative radiotherapy, escape delivery of a cumulatively lethal dose, and form the basis for locoregional relapse during or after a few months of radiotherapy.¹⁰ Radiotherapy is also frequently indicated in glioblastoma patients with palliative intention, however, with significant limitations. Such limitations include intrinsic resistance of glioma cells to damage induced by ionizing radiation.¹¹ Furthermore, an important proportion of glioma cells can survive irradiation, inducing their proliferation to accelerate tumor cell repopulation during radiation challenge.^{12,13}

More recently, chemotherapy has gained prominence in the management of malignant gliomas. The 1-year patient survival rate increased from 6% to 10% after adjuvant chemotherapy.¹⁴ However, despite the moderate success of several agents such as temozolomide, an oral alkylating agent with encouraging results, current conventional protocols still demonstrate a high incidence of locoregional failure and poor overall survival (OS) rates. The introduction of temozolomide has significantly prolonged patient survival, but its efficacy strongly depends on the presence of the DNA repair enzyme, O⁶-methyl-guanine-DNA methyltransferase (MGMT). DNA promoter methylation status of MGMT is emblematic of repair enzyme activity in the tumor,¹⁵ particularly in GBM.^{14,16} Patients with unmethylated MGMT

promoters, which accounts for approximately half of GBM patients,¹⁷ who receive concurrent and adjuvant temozolomide chemotherapy with radiotherapy have 2- and 5-year survival rates of 15% and 8%, respectively.¹⁸ The success of this modality is mainly limited due to the appearance of a remarkable resistance of tumors to cytotoxic agents. Attempts to overcome such resistance with higher doses of chemotherapeutics result in unacceptable toxicity and bystander damage to the normal tissues.

Due to the limited efficacy of conventional therapies, further attempts to increase patient survival have recently focused on molecular pathways that underlie malignant processes in HGG. The identification of specific molecular traits that underlie the processes of malignant progression has allowed the development of new therapeutic approaches targeting specific differences between normal and malignant cells. A better understanding of molecular mechanisms employed by tumor cells to evade the inhibitory activity of cytotoxic therapies is essential to the rational design of novel strategies that may help to improve their effectiveness in HGG treatment.^{12,19}

One of the well known molecular features of HGG is the amplification of the *EGFR* gene, which occurs in approximately 40% to 50% of patients.^{20,21} EGFR overexpression has been found in approximately half of HGG patients and shows a significant association with *EGFR* gene amplification.²² Furthermore, EGFR overexpression has been reported to correlate with more aggressive disease, resistance to both radio- and chemotherapy, and a poor prognosis in patients.^{23,24} In the HGG pediatric population, despite being less frequent, EGFR expression has been also correlated with a more aggressive phenotype and worse patient prognosis.²⁵ EGFR has been considered a promising target in the treatment of HGG and several therapeutic agents, such as tyrosine kinase inhibitors and specific anti-EGFR monoclonal antibodies, are currently under evaluation.²⁶ The EGFR class of molecularly targeted agents is attractive for several reasons. First, EGFR is frequently found to be overexpressed in a substantial proportion of human tumors, warranting broad application. Second, the activation of signal transduction pathways driven by the EGFR family is central to many malignant processes. Third, EGFR overexpression has been largely associated with a poor prognosis and resistance to conventional therapies in many tumor types. In line with this, promising preclinical studies have prompted the development of several clinical trials testing the tolerability and efficacy of various EGFR inhibitors, both as a single agent therapy, and in combination with conventional cytotoxic therapies (radiotherapy

and chemotherapy). However, despite the large number of compounds under evaluation, the success of these agents in the management of HGG has been limited and clinical results are still modest.

Nimotuzumab: a monoclonal antibody to EGFR

Nimotuzumab is a humanized IgG1 monoclonal antibody which recognizes the extracellular domain of EGFR.²⁷ It competitively binds to the receptor preventing further ligand binding and subsequent EGFR activation. As a result of such a blockade, an antagonistic biological effect on the tumor cell proliferation is exerted.^{28,29} Also in response to EGFR blockade by nimotuzumab, tumor cells decrease their capacity to secrete proangiogenic factors, such as vascular endothelial growth factor (VEGF), leading to decreased blood vessel formation and increased apoptotic cell death in human tumor xenografts overexpressing EGFR.^{30,31} In addition, nimotuzumab has shown an ability to recruit other immunological mechanisms such as antibody mediated cellular cytotoxicity and complement dependent cytotoxic effects.²⁸ Currently, nimotuzumab has been granted approval for use in patients with advanced squamous cell carcinoma of the head and neck,^{32,33} HGG,^{34,35} and advanced esophageal carcinoma.³⁶ In all these indications, the efficacy of nimotuzumab is based on the combination of the antibody with radiotherapy or radiochemotherapy.

Our group has previously demonstrated the ability of nimotuzumab to increase the antitumor activity of radiation in the U87MG human glioblastoma xenografted mouse model.³⁷ Based on these studies it was determined that adding nimotuzumab to radiation treatment significantly increased the inhibition of EGFR related signaling pathway activation, increasing the antiproliferative activity of both therapies. Such inhibition was not apparent for tumors treated with radiation alone, suggesting a rationale for combining the antibody with radiotherapy in this tumor model. Based upon such observations of a synergistic effect of nimotuzumab in xenograft models, nimotuzumab has been administered in combination with radiation therapy, enhancing its antitumor activity in a number of clinical trials.

Clinical experience of nimotuzumab in combination with radiotherapy or radiochemotherapy in HGG

Several clinical trials have evaluated nimotuzumab concomitant with radiation containing regimens in HGG patients, demonstrating a clinical benefit of the combination therapy in terms of response rate, control disease rate, and OS. Tables 1 and 2 summarize the main results of those clinical trials.

Adult population

The first clinical trial regarding the use of nimotuzumab in HGG was a multicenter, one arm study that evaluated the

Table 1 Clinical trials of nimotuzumab in combination with radiation and chemoradiation in adult high grade glioma

Trial number (country)	Indication	Phase	Study design	Main results	Publications (reference)
IIC RD EC053 (Cuba)	GBM and AA	I/II	Nimotuzumab + RT	ORR: 37.9% (11/29) DCR: 79.3% (23/29) PFS-12 months: 68.8% (GBM) and 91.7% (AA) MSV: 17.5 months (GBM) and not reached for AA SVR-24 months: 24% (GBM) and 55% (AA)	Ramos et al ³⁴
IIC RD EC069 (Cuba)	GBM and AA	II/III	Nimotuzumab ± RT	MSV: 17.8 months (nimotuzumab + RT) versus 12.6 months (RT + placebo)	Solomon et al ³⁹
Not available (People's Republic of China)	GBM	I/II	Nimotuzumab ± RT + TMZ	ORR: 70.0% (nimotuzumab + RT + TMZ) versus 52.4% (RT + TMZ) MSV: 16.5 months (nimotuzumab + RT + TMZ) versus 10.5 months (RT + TMZ) SVR-12 months: 81.3% (nimotuzumab + RT + TMZ) versus 69.1% (RT + TMZ)	Hong et al ⁴⁰
OSAG 101-BSA-5 (Germany)	GBM	III	Nimotuzumab ± RT + TMZ	MSV: 22.3 months (nimotuzumab + RT + TMZ) versus 19.6 months (RT + TMZ) EGFR amplified, nonmethylated, residual tumor MSV: 23.8 months (nimotuzumab + RT + TMZ) versus 13.8 months (RT + TMZ)	Westphal and Bach ⁴¹

Abbreviations: AA, anaplastic astrocytoma; DCR, disease control rate; EGFR, epidermal growth factor receptor; GBM, glioblastoma; MSV, median survival; ORR, objective response rate; PFS, progression free survival; RT, radiotherapy; SVR, survival rate; SVR-24, survival rate at 24 months; TMZ, temozolomide.

Table 2 Clinical trials of nimotuzumab in combination with radiation and chemoradiation in pediatric high grade glioma

Trial number (country)	Indication	Phase	Study design	Main results	Publications (reference)
OSAG 101-BSC-05 (Germany)	DIPG	III	Nimotuzumab + RT	ORR: 9.8% DCR: 75.6% PFS-6 months: 33.3% MSV: 9.4 months	Fleischhack et al ⁴¹
IIC RD EC097 (Cuba)	DIPG	II	Nimotuzumab + RT	DCR: 75.0% (6/8)	Crombet et al ⁴²
Not available (Italy)	DIPG	II	Nimotuzumab + RT + vinorelbine	PFS-6 months: 90%	Massimino et al ³⁵

Abbreviations: DCR, disease control rate; DIPG, diffuse intrinsic pontine glioma; MSV, median survival; ORR, objective response rate; PFS, progression free survival; RT, radiotherapy.

safety and preliminary efficacy of the antibody in combination with radiation in newly diagnosed HGG (Table 1).³⁴ This study included 29 patients: 12 patients with AA, 16 patients with GBM, and one patient with anaplastic oligodendroglioma. The objective response rate for patients treated with the combination therapy was 37.9% (11 of 29 patients) and the control disease rate was 79.3% (23 patients). The progression free survival to 1 year was 68.8% for patients with GBM and 91.7% for patients with AA. The median survival time for patients with GBM was 17.5 months, whereas the median survival time for AA patients had not been reached at the time the final report was written. Moreover, the survival rate at 2 years was 24% among patients with GBM and 55% in the AA group. Antibody infusions were well tolerated, and the most commonly reported adverse events were headache, chills, fever, nausea, and transaminase elevation, all of them classified as mild according to Common Toxicity Criteria (CTCAE, version 3.0).³⁸ However, the study was limited in that the trial did not compare the nimotuzumab combination with a temozolomide based chemoradiotherapy treatment, which is currently the standard of care for patients with HGG. Based on the response rate and improvement in survival, nimotuzumab was approved as a radiation sensitizing agent for HGG patients undergoing primary radiation based treatment.

A new randomized multicenter clinical trial was conducted in HGG patients that received radiation plus nimotuzumab or placebo (Table 1).³⁹ This study included 70 patients: 41 AA and 29 GBM. The median survival time for patients treated with nimotuzumab and radiation was 17.8 months, while the median survival time in the control arm was 12.6 months. According to histologic stratum analysis, the median survival among AA patients was 44.6 months for nimotuzumab group versus 14.6 months in the control group; whereas among GBM patients, the median survival was 16.1 months in nimotuzumab group versus 8.4 months

in the control group. Moreover, the combination of nimotuzumab and radiation was safe and the most frequent related adverse events were nausea, fever, tremors, and anorexia, all of them classified as grade 1 and 2.

The fact that patients with HGG who failed to respond to temozolomide based therapy had a 2-year survival rate of 15% (patients treated with radiation only have a 2-year survival of 2%),¹⁸ has led to clinical trials of nimotuzumab in combination with temozolomide and radiation therapy in patients with GBM. A Phase I/II trial evaluated whether nimotuzumab enhanced the effect of radiochemotherapy in HGG (Table 1).⁴⁰ A total of 41 patients were randomized to receive 6 weekly infusions of nimotuzumab (200 mg), or placebo in addition to radiotherapy (46–66 Gy) and a temozolomide based regime. Temozolomide was administered daily (75 mg/m²) during radiation therapy. On completion of radiation therapy, there was a 28-day treatment break, followed by a second phase of up to six 28-day cycles of adjuvant temozolomide treatment at 150 mg/m² once daily for 5 days followed by 23 days without treatment. At the start of cycle 2, the dose was escalated to 200 mg/m²/day if hematological toxicity was within prescribed limits. Mean and median survival time of the treatment group was 14.3 and 16.5 months, respectively, compared to 10.4 and 10.5 months in the control group. The 1-year survival rates of the treatment and control groups were 81.3% and 69.1%, respectively. Nimotuzumab also showed a synergistic effect in combination with chemoradiation; 14 of 20 evaluable patients achieved major responses (70%), including three patients with complete responses (15%).

A confirmatory Phase III study was conducted in Germany in 149 patients with newly diagnosed GBM, 142 of them evaluable for efficacy (Table 1).⁴¹ In this study patients were randomized to receive nimotuzumab/temozolomide/radiation versus temozolomide/radiation. After daily dosage

during radiotherapy, the temozolomide schedule was changed to a 5-day, 4-weekly schedule until week 36. In the nimotuzumab arm, patients received weekly infusions of the antibody (400 mg) until week 11, which was changed to a biweekly application at week 13 (consolidation phase), and discontinued after 1 year of treatment. The median survival time for the nimotuzumab arm was 22.3 months in comparison to 19.6 months in the radiation/temozolomide arm. The difference in median OS in both arms did not achieve a statistical significance, probably due to the unexpected survival registered in the control arm. A subsequent subgroup analysis showed a longer survival time when patients with EGFR positive tumors, nonmethylated MGMT promoters, and incompletely resected GBM received nimotuzumab in addition to standard treatment (Table 1).⁴¹ This subgroup of patients had an OS of 23.8 months when treated with nimotuzumab in comparison with 13.8 months in the control group ($P = 0.03$). Patients with nonmethylated MGMT (unresponsive to temozolomide) that received nimotuzumab had a median survival time of 19.6 months, as compared to 15.0 months for the same patients not receiving the antibody. The results compared favorably with results of the study by Hegi et al in which the median survival time was 12.7 months in the temozolomide/radiation arm.⁴² These therapeutic outcomes reinforce the importance of prospectively identified efficacy predictors in targeted therapies, a hypothesis that should be evaluated in future clinical trials. As in other trials, nimotuzumab was well tolerated and did not exacerbate the toxicity of standard therapy. The most common adverse events were headache, fatigue, nausea, vomiting, thrombocytopenia, aphasia, and mild to moderate acneiform rash.

Pediatric population

A landmark multinational Phase III trial recently evaluated the safety and efficacy of nimotuzumab in combination with radiotherapy in newly diagnosed diffuse intrinsic pontine glioma (DIPG) (Table 2).⁴³ Forty-two patients (of which 41 were evaluable) were treated with a 12-week induction therapy of nimotuzumab given weekly at a dose of 150 mg/m², concomitantly with standard radiotherapy at weeks 3 to 8 (total dose of 54 Gy). In case of nonprogressive disease, the antibody was subsequently administered biweekly in a consolidation phase until disease progression. The best response was a partial response in four patients (9.8%) and stable disease in 27 patients (65.8%). The median progression free survival and OS were 5.8 and 9.4 months, respectively. Two patients were alive 2 years after the start of treatment,

and one patient was stable and well 6 years after the primary treatment.⁴³ Moreover, significantly longer survival times were documented in radiological responder patients (partial response, stable disease) when compared to nonresponder (progressive disease) patients ($P < 0.005$). Repeated applications of nimotuzumab in combination with radiotherapy were safe and well tolerated. There were, again, only minor side effects like fever and erythema (grade 1 and 2) due to the antibody and no patient discontinued the treatment due to adverse events.

Two other ongoing Phase II clinical trials are testing the safety and efficacy of nimotuzumab in combination with different cytotoxic regimens in DIPG.^{35,44} A Phase II multinational study is being conducted in Cuba and Brazil to evaluate the safety and efficacy of nimotuzumab in combination with radiotherapy (Table 2).⁴⁴ So far, nine patients have been evaluated. Despite the small number of patients under evaluation, six evaluable patients were reported with stabilized disease after 24 weeks of treatment. The combination therapy was well tolerated and only one mucositis (grade 1–2) has been reported.

Vinorelbine has shown efficacy in the treatment of gliomas, and a new trial is evaluating the feasibility of including it with radiotherapy and nimotuzumab in a pediatric population as part of a Phase II study conducted at the Istituto Nazionale Tumori, in Milan (Table 2).³⁵ So far, 22 patients have been treated and the 1- and 2-year PFS is 26% and 20%, while the 1-year OS is 73%, and the 2-year OS is 25%. Prior to final evaluation of the study, preliminary results are encouraging and suggest the feasibility of combining nimotuzumab with radiotherapy and vinorelbine for the treatment of DIPG. Therefore, these results suggest that combination therapy with nimotuzumab may prolong patient survival without adding toxicity to the standard therapy.

Potential mechanisms driving the radiosensitization of nimotuzumab

A series of nonclinical studies, including head and neck squamous cell carcinoma (HNSCC), non-small-cell lung carcinoma (NSCLC), and GBM xenografts, have shown the radiosensitizing capability of nimotuzumab and therefore its ability to synergize with ionizing radiation.^{37,45,46} Indeed, the clearest benefit of nimotuzumab treatment to date comes from studies where the antibody was combined with radiotherapy to treat advanced tumors. A schematic illustration depicting different mechanisms involved in radiosensitization of

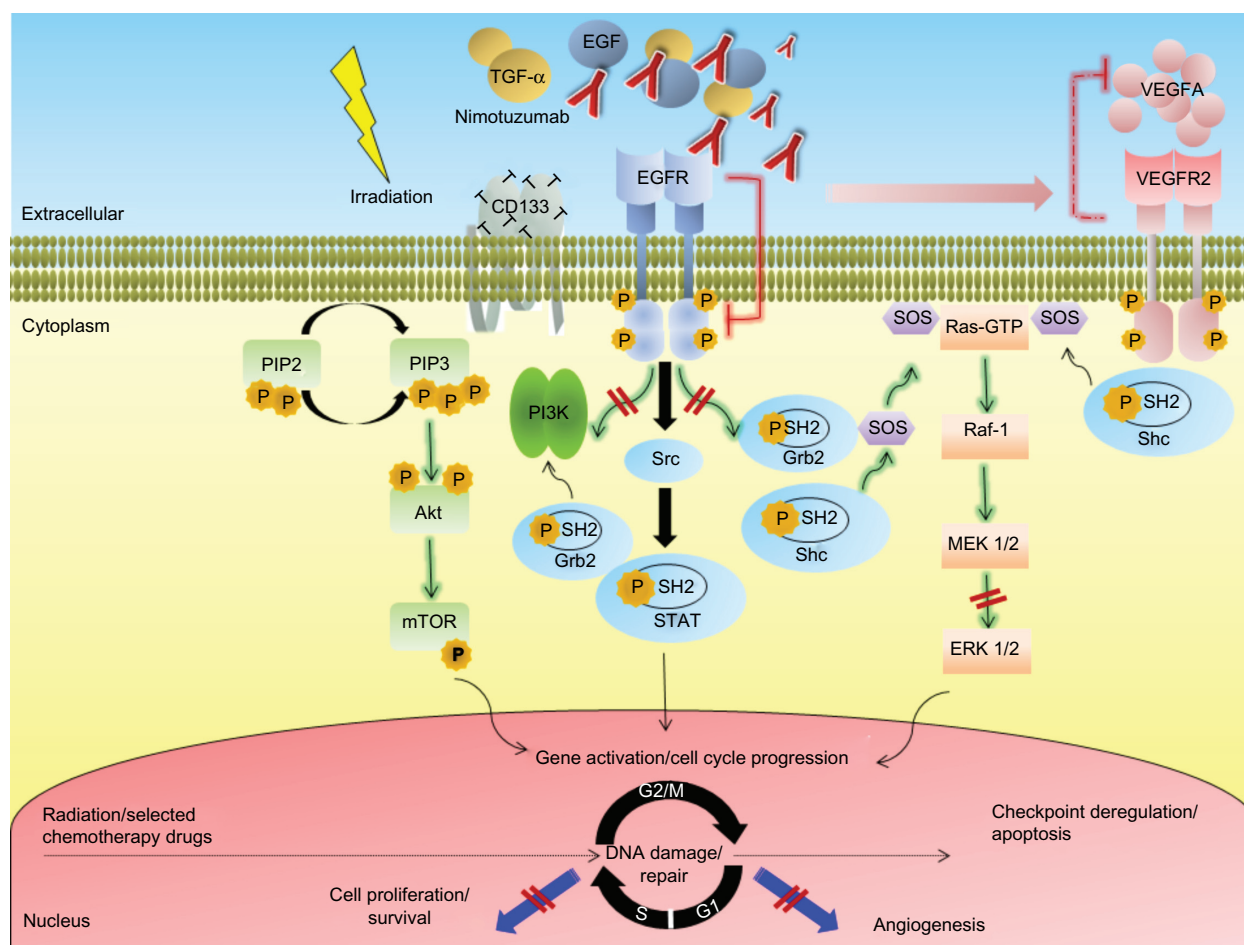


Figure 1 Simplified schematic illustration depicting different mechanisms implicated in radiosensitization by the anti-epidermal growth factor receptor monoclonal antibody nimotuzumab in high grade glioma.

Notes: After ligand binding, tyrosine phosphorylation of tyrosine kinase domains may initiate signaling events or provide docking sites for adaptor molecules, including the SH2 domain containing proteins Shc and Grb, which in turn promotes the activation of multiple intracellular kinases, such as extracellular signal-regulated kinase (ERK) 1/2. The activation of ERK 1/2 leads to increased cell proliferation. The exposure of tumor cells to ionizing radiation may also increase epidermal growth factor receptor (EGFR) phosphorylation and activation of mitogen activated protein kinase (arrows shaded in green) and other related pathways. Nimotuzumab binds to the extracellular domain of the EGFR inhibiting receptor phosphorylation and ERK 1/2 activation, which results in inhibition of cell proliferation. Nimotuzumab also decreases angiogenic processes, probably by inhibiting the secretion of vascular endothelial growth factor type A by tumor cells (dashed arrows shaded in red). In addition, nimotuzumab induces G_2/G_1 cell cycle arrest, that in combination with radiation induced G_2/M cell cycle arrest, might lead to increased apoptosis of tumor cells.

Abbreviations: Akt, protein kinase B; CD, cluster differentiation; EGF, epidermal growth factor; EGFR, epidermal growth factor receptor; ERK, extracellular signal-regulated kinase; Grb2, growth factor receptor-bound protein 2; GTP, guanosine-5'-triphosphate; MEK, mitogen activated protein kinase kinase; mTOR, mammalian target of rapamycin; PI3K, phosphatidylinositol 3 kinase; PIP2, phosphatidylinositol 4,5-bisphosphate; PIP3, phosphatidylinositol 3,4,5-trisphosphate; Raf, rapidly accelerated fibrosarcoma; Ras, rat sarcoma; SH2, Src homology-2; shc, Src-homology collagen protein; SOS, son of sevenless homolog 1; Src, sarcoma; STAT, signal transducer and activator of transcription; TGF- α , transforming growth factor alpha; VEGFA, vascular endothelial growth factor type A; VEGFR2, VEGF receptor 2.

nimotuzumab is shown in Figure 1. Interesting findings could explain why nimotuzumab has a positive and different quality to potentiate the effects of radiotherapy.^{12,47}

Antiproliferative effects of nimotuzumab

The effect of radiation on tumor cell proliferation has been extensively evaluated in the preclinical setting using different tumor models. Previous findings indicate that in cell lines that overexpress EGFR, the receptor becomes rapidly phosphorylated and activated after the administration of clinically relevant doses of radiation.⁴⁸ A rapid repopulation after radiotherapy, by increased cell proliferation, shortens the time to recurrence of the disease, impairs local tumor

control, and decreases the OS of patients. Antiproliferative effects of anti-EGFR monoclonal antibodies have also been shown consistently in preclinical experiments.⁴⁹ In combination with radiotherapy, the inhibition of cell proliferation induced by anti-EGFR monoclonal antibodies would be expected to lead to tumor regression or slower tumor growth. Among the several mechanisms of activation that have been proposed, at least one of them involves ligand stimulated activation. EGFR radiation induced activation was associated with increased tumor cell proliferation, through a mechanism involving the processing and release of transforming growth factor alpha.⁵⁰ Thus, it is expected that molecular agents that effectively block EGFR activation might potentiate

the radiation induced antiproliferative activity, especially in those tumors overexpressing the receptor. In line with this consideration, nimotuzumab was shown to prevent the radiation induced activation of EGFR, as well as to increase its antiproliferative activity in U87MG GBM xenografts when administered in combination with radiation.³⁷ The antiproliferative activity of the combination therapy in this tumor model was shown to be higher than that exerted by each individual therapy, suggesting that nimotuzumab may improve radiation response, at least in part, by blocking radiation induced proliferation.

Targeting of CD133+ cancer stem cells by nimotuzumab

Cancer stem cells (CSC) are defined as those cancer cells that have the capacity to self-renew and to cause the heterogeneous lineages of cells that comprise the tumor.⁵¹ Gliomas were among the first solid cancers in which CSC were identified.^{52,53} In these tumors, the CD133⁺ but not CD133⁻ cells were reported to be responsible for tumor outgrowth.^{11,54,55} Furthermore, the CSC population was shown to be a source of radiation resistance within brain tumors.^{11,56,57} Thus, additional targeting of CSC by a further treatment would be expected to have additive effects on local tumor control. Several studies have established a potential relationship between CSC and the EGFR system and its ligands in brain tumors. The capacity of nimotuzumab to decrease the population of CD133⁺ CSC in U87MG xenografts has been reported.³⁷ Such inhibition was associated with the ability of the antibody to increase the cytotoxic activity of radiation in this tumor model. Subsequent studies have shown that GBM CSC that express EGFR have a more aggressive functional and molecular phenotype than noncancer stem cells, and modulation of EGFR expression markedly decreases its tumorigenic potential.^{58,59} Actually, GBM CSC are more sensitive to Akt signaling inhibition than noncancer stem cells.⁶⁰ The ability of anti-EGFR monoclonal antibodies to target the CSC population may occur as a consequence of a direct inhibition of the EGFR expressed on these tumor cells, since the latest studies conducted in our group revealed that the CSC markers nestin and CD133 are coexpressed alongside EGFR on the cell surface of the U87MG cells (Diaz-Miqueli, unpublished data, 2009). Alternatively, an indirect targeting of CSC by nimotuzumab might also result from the disruption of the vascular microenvironment of tumors as a result of the antiangiogenic activity of nimotuzumab on tumor xenografts. Since the hypothesis that CSC depends critically upon the presence of an intact vascular niche microenvironment for self-renewal, the disruption of

these niche microenvironments by drugs with antiangiogenic potential may ablate the fraction of CSC in brain tumors and arrest tumor growth.⁶¹

Perturbations in cell cycle control

Perturbations in cell cycle control induced by monoclonal antibodies may also increase tumor cell response to ionizing radiation.⁶² Previous separate studies have consistently shown nimotuzumab induces G₀/G₁ cell cycle arrest in the human epithelial cell line A431.^{28,30} Ionizing radiation also induces cell cycle arrest, involving checkpoint control at several phases of the cell cycle.⁶³ Thus, the radiosensitizing effect of nimotuzumab may arise from decreasing the fraction of cells in the relatively radioresistant S-phase, with a concomitant increase in the more radiosensitive G₁ phase of the cell cycle. This point of view constituted an early premise for rationale combining EGFR inhibitors with ionizing radiation.⁶⁴ In addition, the combined therapy may prolong the cell cycle, contributing to avoidance of a rapid repopulation after the administration of ionizing radiation.⁴⁹ Alternatively, a simultaneous cell cycle arrest at both G₀/G₁ phases induced by nimotuzumab, and G₂/M arrest mediated by ionizing radiation might result in cell cycle checkpoint deregulation and subsequent apoptosis.⁶⁵

Antiangiogenic effects of nimotuzumab

The radiosensitization effects of nimotuzumab, and EGFR inhibitors in general, are more pronounced *in vivo*, suggesting a potential association with its ability to interfere in tumor-stromal interactions. Complicated interactions between ionizing radiation, EGFR, and the angiogenic processes have been postulated. VEGF and EGFR are key elements in the growth and dissemination of epithelial tumors. Both pathways are closely related, sharing common downstream signaling molecules.^{66,67} Furthermore, epidermal growth factor (EGF) is one of the growth factors that drive VEGF expression.⁶⁸ Whereas radiation induced EGFR activation has been postulated to upregulate the secretion of VEGF, a previous study has demonstrated that nimotuzumab decreases VEGF secretion in A431 tumor cells after incubation with the antibody.³⁰ Similar findings have also been consistently demonstrated with other EGFR inhibitors.^{9,69} Moreover, VEGF receptor expression is increased in A431 mutant cells and the mutant cells acquired resistance to nimotuzumab therapy, despite persistence of antibody treatment.³¹ Therefore, EGFR inhibition caused by nimotuzumab treatment might sensitize endothelial cells to radiation. However, in contrast to these findings, we found that administration of nimotuzumab concomitant with radiation did not decrease the number of tumor associated

vessels in U87MG xenografts when compared to those mice treated with the antibody alone.³⁷ These observations could be explained by the fact that EGFR inhibition exerted by nimotuzumab did not block VEGF, thereby allowing tumor angiogenesis to continue. These observations suggest that the potential mechanistic relevance of the antiangiogenic effect of nimotuzumab should be further evaluated in brain tumors as a radiosensitizer agent.

Signaling pathways affected by nimotuzumab

Aberrant EGF mediated signaling plays an essential role to increase the capacity of tumor cells to proliferate and migrate during the process of tumor growth. The main activated EGFR downstream signaling pathways include the Ras mitogen activated protein kinase (MAPK) cascade, the phosphatidyl inositol 3 kinase (PI3K) cascade, and the signal transducer and activator of transcription (STAT) cascade (Figure 1). Interestingly, activation of EGFR signaling can also be mediated by radiation in a ligand-independent fashion.⁷⁰ As a consequence, exposure of tumor cells overexpressing EGFR to radiation activates proliferation mechanisms through stimulated PI3K and MAPK signaling.⁷¹ Thus, in combination with radiotherapy, EGFR inhibitors would be expected to enhance sensitivity of tumor cells to ionizing radiation.

Akashi et al have previously reported the synergistic potential of nimotuzumab to increase the antitumor activity of radiation in NSCLC cell lines of differing EGFR status.⁴⁵ In this study, nimotuzumab inhibited the EGF induced phosphorylation of EGFR in H292 and Ma-1 cells, with high and moderate levels of EGFR expression, respectively, consistent with the mode of action of this antibody. In contrast, nimotuzumab did not block EGFR phosphorylation in H460, H1299, or H1975 cells with low levels of EGFR expression.⁴⁵ These observations suggest that the inhibition of the EGFR signaling by nimotuzumab may be related to the surface expression level of EGFR. Moreover, despite irradiation of tumor cells that was shown to activate EGFR, possibly accounting for radiation induced acceleration of tumor cell repopulation and radioresistance,⁴⁸ such activation might increase the ability of nimotuzumab to effectively blockade the EGFR downstream signaling in tumors. Similar findings were documented when nimotuzumab was administered concomitant with radiation in U87MG xenografts.³⁷ In the GBM model, combination therapy significantly increased the capacity of nimotuzumab to inhibit both EGFR phosphorylation and

extracellular signal-regulated kinase (ERK) 1/2 induced activation when compared with nimotuzumab alone.³⁷ Altogether, these findings support the notion that inhibition of EGFR signaling by nimotuzumab is responsible, at least in part, for the enhancement of the cytotoxic effect of radiation by this antibody. Such radiation induced activation of EGFR dependent processes may represent a rationale for treatment combination.

Nimotuzumab: an EGFR inhibitor with a unique toxicity profile

In contrast to other EGFR inhibitors, nimotuzumab has a very low toxicity profile and its use in combination with cytotoxic therapies does not exacerbate the toxicity inherent with such therapies. These observations have been largely documented in HGG patients, but they are not restricted to brain tumors. Evidence gathered from more than 20,000 patients treated with the antibody in clinical trials and in open populations with advanced tumors, including HNSCC,^{32,33,72} NSCLC,^{73,74} and gastrointestinal cancer among others, support the therapeutic efficacy of nimotuzumab.^{36,75–77} The clinical benefit of nimotuzumab was equivalent or superior to those of other anti-EGFR monoclonal antibodies with a very low incidence of adverse related events (especially skin rash, which accounts for less than 10% of treated patients) making this antibody an appropriate agent that may be efficaciously administered under long-term schedules and in combination with standard cytotoxic therapies.⁷⁸ Accumulated clinical experience in HGG patients, especially in the pediatric population, has provided evidence for the feasibility to prolong nimotuzumab therapy with a significant survival benefit.⁷⁹

An explanation for nimotuzumab's unique toxicity profile has emerged from several pieces of experimental and modeling data generated by separate groups. In 2004, Crombet and coworkers proposed the existence of an optimal affinity window for antibodies with intermediate affinity for EGFR, based on a mathematical model.³² The hypothesis predicted that antibodies with an intermediate affinity would have a higher ratio of accumulation in tissues with higher EGFR expression levels (tumors) when compared to low density EGFR tissues (healthy tissues) than high affinity antibodies. In contrast to nimotuzumab, higher affinity antibodies would induce a rapid uptake by normal tissues reducing the therapeutic index of these agents. This might be particularly relevant in brain tumors, located in an anatomical area difficult to access for high molecular weight compounds,

such as antibodies.⁸⁰ A subsequent pharmacodynamic trial conducted in HNSCC patients demonstrated that even though nimotuzumab produces downstream inhibition of the EGFR signaling pathway in normal skin cells, the characteristic lymphocytic infiltrates, folliculitis, or perifolliculitis induced by other EGFR inhibitors is not observed in nimotuzumab treated skin patient samples.⁸¹ These findings may help to explain the lack of skin rash in patients treated with nimotuzumab.

A more recent study published in Cancer Biology and Therapy has given further support to this hypothesis.⁸² In this study, the authors evaluated the binding properties of nimotuzumab and cetuximab, and their corresponding Fab fragments, in several cell lines with different levels of surface EGFR expression. Experimental observations demonstrated that the binding properties of nimotuzumab were strongly dependent on the EGFR surface density in tumor cells, whereas cetuximab bound to EGFR expressed in tumor cells irrespective of receptor density. Moreover, the binding properties of the Fab component of nimotuzumab were significantly reduced, even in cell lines with high EGFR expression, while remaining unaffected with cetuximab, even in cell lines with lower levels of EGFR expression. These results strongly support that nimotuzumab receptor attachment is reliant on the antibody's bivalent binding (two arms of the antibody binds simultaneously to EGFR molecules) and therefore, it is only possible when the EGFR surface density is above a certain threshold (a condition favored in tumors with high EGFR expression).

These observations may have important clinical implications. Firstly, from these findings we could predict a preferential uptake of the antibody in EGFR overexpressing tumors, suggesting a greater benefit from nimotuzumab treatment in those patients with tumors that overexpress the receptor. An increasing interest has arisen over the last few years in identifying molecular traits in HGG that can help predict a response, so that a group of patients who are likely to benefit from a selected treatment might be prospectively selected.^{83,84} Whether EGFR levels in tumors may have a prognostic value as a predictive marker for nimotuzumab efficacy or not needs to be confirmed in definitive Phase III clinical trials, but recently emerging findings from studies in different tumor indications may support this idea. Two separate Phase II and Phase II/III clinical trials published in 2010 evaluated the efficacy of nimotuzumab in combination with standard cytotoxic therapies in 106 and

92 HNSCC patients, respectively.^{33,85} In both studies, the EGFR detection by immunohistochemistry showed a significant survival improvement for nimotuzumab treated patients with tumors that overexpressed EGFR. In addition, a new study performed in 68 nonresectable esophageal cancer patients compared the advantage of adding nimotuzumab to a standard regimen of radiation and chemotherapy.³⁶ For nimotuzumab treated patients that overexpress EGFR, the objective response and disease control rate was 60% and 80%, which compares very favorably with the response and disease control rate seen in the control group. Finally, in the above mentioned Phase III study conducted in newly diagnosed GBM patients who received nimotuzumab in addition to temozolomide and radiation, patients with *EGFR* gene amplification had a trend to benefit in OS when compared to control group (Table 1).⁸⁶ In contrast, OS in patients with no amplifications in the *EGFR* gene was 16.2 months in nimotuzumab treated patients compared with 21.0 months in the control group.

Altogether, these observations suggest a potential synergy of nimotuzumab with agents that increase EGFR expression, such as radiation containing regimens. The mutual benefit expected from concomitant use of nimotuzumab with cytotoxic therapies, together with a low toxicity profile, makes nimotuzumab a useful candidate for combining with standard cytotoxic agents such radiation in the management of patients with HGG.

Concluding remarks

The current cytotoxic standard therapies have yielded limited efficacy in the treatment of patients with HGG. Unfortunately, despite the aggressive nature of new approaches, modest and transient clinical responses are observed due to the appearance of resistance that develops to these therapies. Thus, novel treatments that can overcome or avoid such limitations are urgently needed to improve patient survival. Nimotuzumab has shown a radiosensitizing capacity and its use concomitant to radiation or chemoradiation may exert synergistic effects with DNA damaging cytotoxic agents, without increasing the toxicity of these standard treatments. The studies presented here summarize published data on the activity of nimotuzumab in combination with radiation containing regimens in HGG. Unusual response rates and longer survival time of HGG patients seen in controlled Phase II and III studies are promising. Moreover, the possibility of using nimotuzumab under long-term schedules due to its low toxicity profile opens new avenues in the therapeutic management of HGG.

Based on currently encouraging results, a better understanding of underlying mechanisms of radiosensitization should guide the future optimal implementation of nimotuzumab radiosensitization approaches in HGG.

Acknowledgments

The authors are indebted to Dr Thomas P Quinn for his excellent review of the manuscript for language corrections prior to its publication.

Disclosure

The authors report no conflicts of interest in this work.

References

- Louis DN, Ohgaki H, Wiestler OD, et al. The 2007 WHO classification of tumours of the central nervous system. *Acta Neuropathol*. 2007;114:97–109.
- Laperriere N, Zuraw L, Cairncross G. Radiotherapy for newly diagnosed malignant glioma in adults: a systematic review. *Radiother Oncol*. 2002;64:259–273.
- Hart MG, Grant R, Garside R, Rogers G, Somerville M, Stein K. Temozolomide for high grade glioma [review]. *Cochrane Database Syst Rev*. 2008;CD007415.
- Koshy M, Villano JL, Dolecek TA, et al. Improved survival time trends for glioblastoma using the SEER 17 population-based registries. *J Neurooncol*. 2012;107:207–212.
- Nazzaro JM, Neuwelt EA. The role of surgery in the management of supratentorial intermediate and high-grade astrocytomas in adults. *J Neurosurg*. 1990;73:331–344.
- Lorenzoni J, Torrico A, Villanueva P, Gederlini A, Torrealba G. Surgery for high-grade gliomas in a developing country: survival estimation using a simple stratification system. *Surg Neurol*. 2008;70:591–597; discussion 7.
- Wolff JE, Drierer PH, Erdlenbruch B, et al. Intensive chemotherapy improves survival in pediatric high-grade glioma after gross total resection: results of the HIT-GBM-C protocol. *Cancer*. 2010;116:705–712.
- Oszwald A, Guresir E, Setzer M, et al. Glioblastoma therapy in the elderly and the importance of the extent of resection regardless of age. *J Neurosurg*. 2012;116:357–364.
- Wild-Bode C, Weller M, Rimmer A, Dichgans J, Wick W. Sublethal irradiation promotes migration and invasiveness of glioma cells: implications for radiotherapy of human glioblastoma. *Cancer Res*. 2001;61:2744–2750.
- Garden AS, Maor MH, Yung WK, et al. Outcome and patterns of failure following limited-volume irradiation for malignant astrocytomas. *Radiother Oncol*. 1991;20:99–110.
- Bao S, Wu Q, McLendon RE, et al. Glioma stem cells promote radioresistance by preferential activation of the DNA damage response. *Nature*. 2006;444:756–760.
- Ciardiello F, Tortora G. EGFR antagonists in cancer treatment. *N Engl J Med*. 2008;358:1160–1174.
- Hennequin C, Quero L, Favaudon V. Determinants and predictive factors of tumour radiosensitivity. *Cancer Radiother*. 2008;12:3–13.
- Stupp R, Mason WP, van den Bent MJ, et al; European Organization for Research and Treatment of Cancer Brain Tumor and Radiotherapy Groups, National Cancer Institute of Canada Clinical Trials Group. Radiotherapy plus concomitant and adjuvant temozolomide for glioblastoma. *N Engl J Med*. 2005;352:987–996.
- Weller M, Stupp R, Reifenberger G, et al. MGMT promoter methylation in malignant gliomas: ready for personalized medicine? *Nat Rev Neurol*. 2010;6:39–51.
- Yabroff KR, Harlan L, Zeruto C, Abrams J, Mann B. Patterns of care and survival for patients with glioblastoma multiforme diagnosed during 2006. *Neuro Oncol*. 2012;14:351–359.
- Zawlik I, Vaccarella S, Kita D, Mittelbronn M, Franceschi S, Ohgaki H. Promoter methylation and polymorphisms of the MGMT gene in glioblastomas: a population-based study. *Neuroepidemiology*. 2009;32:21–29.
- Stupp R, Mayer M, Kann R, et al. Neoadjuvant chemotherapy and radiotherapy followed by surgery in selected patients with stage IIIB non-small-cell lung cancer: a multicentre phase II trial. *Lancet Oncol*. 2009;10:785–793.
- Sartor CI. Mechanisms of disease: Radiosensitization by epidermal growth factor receptor inhibitors. *Nat Clin Pract Oncol*. 2004;1:80–87.
- Viana-Pereira M, Lopes JM, Little S, et al. Analysis of EGFR overexpression, EGFR gene amplification and the EGFRvIII mutation in Portuguese high-grade gliomas. *Anticancer Res*. 2008;28:913–920.
- Jarvela S, Helin H, Haapasalo J, et al. Amplification of the epidermal growth factor receptor in astrocytic tumours by chromogenic in situ hybridization: association with clinicopathological features and patient survival. *Neuropathol Appl Neurobiol*. 2006;32:441–450.
- Bredel M, Pollack IF, Hamilton RL, James CD. Epidermal growth factor receptor expression and gene amplification in high-grade non-brainstem gliomas of childhood. *Clin Cancer Res*. 1999;5:1786–1792.
- Mellinghoff IK, Wang MY, Vivanco I, et al. Molecular determinants of the response of glioblastomas to EGFR kinase inhibitors. *N Engl J Med*. 2005;353:2012–2024.
- Fedrico CA, Grivicich I, Schunemann DP, et al. Radioresistance of human glioma spheroids and expression of HSP70, p53 and EGFR. *Radiat Oncol*. 2011;6:156.
- Gilbertson RJ, Hill DA, Hernan R, et al. ERBB1 is amplified and overexpressed in high-grade diffusely infiltrative pediatric brain stem glioma. *Clin Cancer Res*. 2003;9:3620–3624.
- Yarden Y, Pines G. The ERBB network: at last, cancer therapy meets systems biology. *Nat Rev Cancer*. 2012;12:553–563.
- Mateo C, Moreno E, Amour K, Lombardero J. Humanization of a mouse monoclonal antibody that blocks the epidermal growth factor receptor: recovery of antagonistic activity. *Immunotechnology*. 1997;3:71–81.
- Diaz Miqueli A, Blanco R, Garcia B, et al. Biological activity in vitro of anti-epidermal growth factor receptor monoclonal antibodies with different affinities. *Hybridoma (Larchmt)*. 2007;26:423–431.
- Spicer J, Harper P. Targeted therapies for non-small cell lung cancer. *Int J Clin Pract*. 2005;59:1055–1062.
- Crombet-Ramos T, Rak J, Perez R, Vilorio-Petit A. Antiproliferative, antiangiogenic and proapoptotic activity of h-R3: A humanized anti-EGFR antibody. *Int J Cancer*. 2002;101:567–575.
- Vilorio-Petit A, Crombet T, Jothy S, et al. Acquired resistance to the antitumor effect of epidermal growth factor receptor-blocking antibodies in vivo: a role for altered tumor angiogenesis. *Cancer Res*. 2001;61:5090–5101.
- Crombet T, Osorio M, Cruz T, et al. Use of the humanized anti-epidermal growth factor receptor monoclonal antibody h-R3 in combination with radiotherapy in the treatment of locally advanced head and neck cancer patients. *J Clin Oncol*. 2004;22:1646–1654.
- Rodriguez MO, Rivero TC, del Castillo Bahi R, et al. Nimotuzumab plus radiotherapy for unresectable squamous-cell carcinoma of the head and neck. *Cancer Biol Ther*. 2010;9:343–349.
- Ramos TC, Figueredo J, Catala M, et al. Treatment of high-grade glioma patients with the humanized anti-epidermal growth factor receptor (EGFR) antibody h-R3: report from a phase I/II trial. *Cancer Biol Ther*. 2006;5:375–379.
- Massimino M, Bode U, Biassoni V, Fleischhack G. Nimotuzumab for pediatric diffuse intrinsic pontine gliomas. *Expert Opin Biol Ther*. 2011;11:247–256.

36. Ramos-Suarez M, Lorenzo-Luaces P, Lazo NG, et al. Treatment of malignant, non-resectable, epithelial origin esophageal tumours with the humanized anti-epidermal growth factor antibody nimotuzumab combined with radiation therapy and chemotherapy. *Cancer Biol Ther.* 2012;13:600–605.
37. Diaz Miqueli A, Roloff J, Lemm M, Fichtner I, Perez R, Montero E. Radiosensitisation of U87MG brain tumours by anti-epidermal growth factor receptor monoclonal antibodies. *Br J Cancer.* 2009;100:950–958.
38. Cancer Therapy Evaluation Program. Common Terminology Criteria for Adverse Events v3.0 (CTCAE). Available from : http://ctep.cancer.gov/protocolDevelopment/electronic_applications/docs/ctcae3.pdf. Accessed July 5, 2013.
39. Solomon MT, Selva JC, Figueredo J, et al. Radiotherapy plus the anti-EGFR mAb nimotuzumab or placebo for the treatment of high-grade glioma patients. ASCO Annual Meeting; June 1–5, 2012; Chicago, IL, USA. *J Clin Oncol.* 30(Suppl):Abstr 2515.
40. Hong J, Peng Y, Liao Y, et al. Nimotuzumab prolongs survival in patients with malignant gliomas: A phase I/II clinical study of concomitant radiochemotherapy with or without nimotuzumab. *Exp Ther Med.* 2012;4:151–157.
41. Westphal M, Bach F. Final results of a randomized phase III trial of nimotuzumab for the treatment of newly diagnosed glioblastoma in addition to standard radiation and chemotherapy with temozolomide versus standard radiation and temozolomide. ASCO Annual Meeting; June 1–5, 2012; Chicago, IL, USA. *J Clin Oncol.* 30(Suppl): Abstr 2033.
42. Hegi ME, Diserens AC, Gorlia T, et al. MGMT gene silencing and benefit from temozolomide in glioblastoma. *N Engl J Med.* 2005;352:997–1003.
43. Fleischhack G, Siegler S, Warmuth-Metz M, et al. Final results of a phase III study consisting of nimotuzumab and concomitant standard radiotherapy for the treatment of newly diagnosed diffuse intrinsic pontine gliomas. *Pediatr Blood Cancer.* 2009;Suppl:755.
44. Crombet T, Cabanas R, Alert J, et al. Nimotuzumab and radiotherapy in children and adolescents with brain stem glioma: preliminary results from a phase II study. *Eur J Cancer.* 2009;7(2):497.
45. Akashi Y, Okamoto I, Iwasa T, et al. Enhancement of the antitumor activity of ionising radiation by nimotuzumab, a humanised monoclonal antibody to the epidermal growth factor receptor, in non-small cell lung cancer cell lines of differing epidermal growth factor receptor status. *Br J Cancer.* 2008;98:749–755.
46. Gonzalez JE, Barquero JF, Lee M, Garcia O, Casaco A. Radiosensitization induced by the anti-epidermal growth factor receptor monoclonal antibodies cetuximab and nimotuzumab in A431 cells. *Cancer Biol Ther.* 2012;13:71–76.
47. Perez R, Moreno E, Garrido G, Crombet T. EGFR-Targeting as a Biological Therapy: Understanding Nimotuzumab's Clinical Effects. *Cancers.* 2011;3:2014–2031.
48. Schmidt-Ullrich RK, Contessa JN, Lammering G, Amorino G, Lin PS. ERBB receptor tyrosine kinases and cellular radiation responses. *Oncogene.* 2003;22:5855–5865.
49. Huang SM, Bock JM, Harari PM. Epidermal growth factor receptor blockade with C225 modulates proliferation, apoptosis, and radiosensitivity in squamous cell carcinomas of the head and neck. *Cancer Res.* 1999;59:1935–1940.
50. Dent P, Reardon DB, Park JS, et al. Radiation-induced release of transforming growth factor alpha activates the epidermal growth factor receptor and mitogen-activated protein kinase pathway in carcinoma cells, leading to increased proliferation and protection from radiation-induced cell death. *Mol Biol Cell.* 1999;10:2493–2506.
51. Clarke MF, Dick JE, Dirks PB, et al. Cancer stem cells – perspectives on current status and future directions: AACR Workshop on cancer stem cells. *Cancer Res.* 2006;66:9339–9344.
52. Hemmati HD, Nakano I, Lazareff JA, et al. Cancerous stem cells can arise from pediatric brain tumors. *Proc Natl Acad Sci U S A.* 2003;100:15178–15183.
53. Singh SK, Clarke ID, Terasaki M, et al. Identification of a cancer stem cell in human brain tumors. *Cancer Res.* 2003;63:5821–5828.
54. Singh SK, Clarke ID, Hide T, Dirks PB. Cancer stem cells in nervous system tumors. *Oncogene.* 2004;23:7267–7273.
55. Bao S, Wu Q, Sathornsumetee S, et al. Stem cell-like glioma cells promote tumor angiogenesis through vascular endothelial growth factor. *Cancer Res.* 2006;66:7843–7848.
56. Eramo A, Ricci-Vitiani L, Zeuner A, et al. Chemotherapy resistance of glioblastoma stem cells. *Cell Death Differ.* 2006;13:1238–1241.
57. Liu G, Yuan X, Zeng Z, et al. Analysis of gene expression and chemoresistance of CD133+ cancer stem cells in glioblastoma. *Mol Cancer.* 2006;5:67.
58. Mazzoleni S, Politi LS, Pala M, et al. Epidermal growth factor receptor expression identifies functionally and molecularly distinct tumor-initiating cells in human glioblastoma multiforme and is required for gliomagenesis. *Cancer Res.* 2012;70:7500–7513.
59. Ayuso-Sacido A, Moliterno JA, Kratochvil S, et al. Activated EGFR signaling increases proliferation, survival, and migration and blocks neuronal differentiation in post-natal neural stem cells. *J Neurooncol.* 2010;97:323–337.
60. Sato A, Sunayama J, Matsuda K, et al. Regulation of neural stem/progenitor cell maintenance by PI3K and mTOR. *Neurosci Lett.* 2010;470:115–120.
61. Calabrese C, Poppleton H, Kocak M, et al. A perivascular niche for brain tumor stem cells. *Cancer Cell.* 2007;11:69–82.
62. Shintani S, Li C, Mihara M, et al. Enhancement of tumor radioresponse by combined treatment with gefitinib (Iressa, ZD1875), an epidermal growth factor receptor tyrosine kinase inhibitor, is accompanied by inhibition of DNA damage repair and cell growth in oral cancer. *Int J Cancer.* 2003;107:1030–1037.
63. Iliakis G, Wang Y, Guan J, Wang H. DNA damage checkpoint control in cells exposed to ionizing radiation. *Oncogene.* 2003;22:5834–5847.
64. Harari PM, Huang SM. Head and neck cancer as a clinical model for molecular targeting of therapy: combining EGFR blockade with radiation. *Int J Radiat Oncol Biol Phys.* 2001;49:427–433.
65. Nyati MK, Maheshwari D, Hanasoge S, et al. Radiosensitization by pan ErbB inhibitor CI-1033 in vitro and in vivo. *Clin Cancer Res.* 2004;10:691–700.
66. Herbst RS, Johnson DH, Mininberg E, et al. Phase I/II trial evaluating the anti-vascular endothelial growth factor monoclonal antibody bevacizumab in combination with the HER-1/epidermal growth factor receptor tyrosine kinase inhibitor erlotinib for patients with recurrent non-small-cell lung cancer. *J Clin Oncol.* 2005;23:2544–2555.
67. Tabernero J. The role of VEGF and EGFR inhibition: implications for combining anti-VEGF and anti-EGFR agents. *Mol Cancer Res.* 2007;5:203–220.
68. Niu G, Wright KL, Huang M, et al. Constitutive Stat3 activity up-regulates VEGF expression and tumor angiogenesis. *Oncogene.* 2002;21:2000–2008.
69. Milas L, Mason K, Hunter N, et al. In vivo enhancement of tumor radioresponse by C225 anti-epidermal growth factor receptor antibody. *Clin Cancer Res.* 2000;6:701–708.
70. Schmidt-Ullrich RK, Mikkelsen RB, Dent P, et al. Radiation-induced proliferation of the human A431 squamous carcinoma cells is dependent on EGFR tyrosine phosphorylation. *Oncogene.* 1997;15:1191–1197.
71. Schmidt-Ullrich RK, Valerie K, Fogleman PB, Walters J. Radiation-induced autophosphorylation of epidermal growth factor receptor in human malignant mammary and squamous epithelial cells. *Radiat Res.* 1996;145:81–85.
72. Ramakrishnan MS, Eswaraiah A, Crombet T, et al. Nimotuzumab, a promising therapeutic monoclonal antibody for treatment of tumors of epithelial origin. *MAbs.* 2009;1:41–48.
73. Bebb G, Smith C, Rorke S, et al. Phase I clinical trial of the anti-EGFR monoclonal antibody nimotuzumab with concurrent external thoracic radiotherapy in Canadian patients diagnosed with stage IIb, III or IV non-small cell lung cancer unsuitable for radical therapy. *Cancer Chemother Pharmacol.* 2011;67:837–845.

74. Choi HJ, Sohn JH, Lee CG, et al. A phase I study of nimotuzumab in combination with radiotherapy in stages IIB-IV non-small cell lung cancer unsuitable for radical therapy: Korean results. *Lung Cancer*. 2011;71:55–59.
75. Ling Y, Chen J, Tao M, Chu X, Zhang X. A pilot study of nimotuzumab combined with cisplatin and 5-FU in patients with advanced esophageal squamous cell carcinoma. *J Thorac Dis*. 2012;4:58–62.
76. Kim YH, Sasaki Y, Lee KH, et al. Randomized phase II study of nimotuzumab, an anti-EGFR antibody, plus irinotecan in patients with 5-fluorouracil-based regimen-refractory advanced or recurrent gastric cancer in Korea and Japan: Preliminary results. 2011 Gastrointestinal Cancers Symposium; January 20–22, 2011; San Francisco, CA, USA. *J Clin Oncol*. 2011;29(Suppl 4):Abstr 87.
77. Zhao KL, Hu XC, Wu XH, Fu XL, Fan M, Jiang GL. A phase I dose escalation study of Nimotuzumab in combination with concurrent chemoradiation for patients with locally advanced squamous cell carcinoma of esophagus. *Invest New Drugs*. 2012;30:1585–1590.
78. Bebb G, Boland W, Melosky B. Don't jump to rash conclusions. *Cancer Biol Ther*. 2011;11:639–641.
79. Cabanas R, Saurez G, Rios M, et al. Treatment of children with high grade glioma with nimotuzumab: A 5-y institutional experience. *MAbs*. 2013;5(2):202–207.
80. Fortin D. The blood-brain barrier: its influence in the treatment of brain tumors metastases. *Curr Cancer Drug Targets*. 2012;12:247–259.
81. Rojo F, Gracias E, Villena N, et al. Pharmacodynamic trial of nimotuzumab in unresectable squamous cell carcinoma of the head and neck: a SENDO Foundation study. *Clin Cancer Res*. 2010;16:2474–2482.
82. Garrido G, Tikhomirov IA, Rabasa A, et al. Bivalent binding by intermediate affinity of nimotuzumab: a contribution to explain antibody clinical profile. *Cancer Biol Ther*. 2011;11:373–382.
83. Zarghooni M, Bartels U, Lee E, et al. Whole-genome profiling of pediatric diffuse intrinsic pontine gliomas highlights platelet-derived growth factor receptor alpha and poly (ADP-ribose) polymerase as potential therapeutic targets. *J Clin Oncol*. 2010;28:1337–1344.
84. Verhaak RG, Hoadley KA, Purdom E, et al; Cancer Genome Atlas Research Network. Integrated genomic analysis identifies clinically relevant subtypes of glioblastoma characterized by abnormalities in PDGFRA, IDH1, EGFR, and NF1. *Cancer Cell*. 2010;17:98–110.
85. Basavaraj C, Sierra P, Shivu J, Melarkode R, Montero E, Nair P. Nimotuzumab with chemoradiation confers survival advantage in treatment naive head and neck tumors overexpressing EGFR. *Cancer Biol Ther*. 2010;10(7):673–681.
86. Bode U, Massimino M, Bach F, et al. Nimotuzumab treatment of malignant gliomas. *Expert Opin Biol Ther*. 2012;12(12):1649–1659.

OncoTargets and Therapy

Publish your work in this journal

OncoTargets and Therapy is an international, peer-reviewed, open access journal focusing on the pathological basis of all cancers, potential targets for therapy and treatment protocols employed to improve the management of cancer patients. The journal also focuses on the impact of management programs and new therapeutic agents and protocols on

Submit your manuscript here: <http://www.dovepress.com/oncotargets-and-therapy-journal>

patient perspectives such as quality of life, adherence and satisfaction. The manuscript management system is completely online and includes a very quick and fair peer-review system, which is all easy to use. Visit <http://www.dovepress.com/testimonials.php> to read real quotes from published authors.

Dovepress