

Shear wave elastography imaging for assessing the chronic pathologic changes in advanced diabetic kidney disease

Kamal Hassan^{1,2}
 Norman Loberant³
 Nur Abbas⁴
 Hassan Fadi⁵
 Hassan Shadia⁵
 Khaled Khazim²

¹Faculty of Medicine in the Galilee, Bar-Ilan University, Safed,

²Department of Nephrology and Hypertension, Peritoneal Dialysis Unit – Galilee Medical Center,

³Department of Radiology, Galilee Medical Center, Nahariya, ⁴The Ruth and Bruce Rappaport Faculty of Medicine, Technion-Israel Institute of Technology, Haifa, ⁵Sackler Faculty of Medicine, Tel Aviv University, Tel Aviv, Israel

Objective: The assessment of the grade of renal fibrosis in diabetic kidney disease (DKD) requires renal biopsy, which may be associated with certain risks. To assess the severity of chronic pathologic changes in DKD, we performed a quantitative analysis of renal parenchymal stiffness in advanced DKD, using shear wave elastography (SWE) imaging.

Patients and methods: Twenty-nine diabetic patients with chronic kidney disease (CKD) grades 3–4 due to DKD, and 23 healthy subjects were enrolled. Combined conventional ultrasound and SWE imaging were performed on all participants. The length, width, and cortical thickness and stiffness were recorded for each kidney.

Results: Cortical thickness was lower in patients with DKD than in healthy subjects (13.8 ± 2.2 vs 14.8 ± 1.6 mm; $P=0.002$) and in DKD patients with CKD grade 4 than in those with grade 3 (13.0 ± 3.5 vs 14.7 ± 2.1 mm; $P<0.001$). Cortical stiffness was greater in patients with DKD than in healthy subjects (23.72 ± 14.33 vs 9.02 ± 2.42 kPa; $P<0.001$), in DKD patients with CKD grade 4 than in those with grade 3 (30.4 ± 16.2 vs 14.6 ± 8.1 kPa; $P<0.001$), and in DKD patients with CKD grade 3b, than in those with CKD grade 3a (15.7 ± 6.7 vs 11.0 ± 4.2 kPa; $P=0.03$). Daily proteinuria was higher in DKD patients with CKD grade 4 than in those with grade 3 (5.52 ± 0.96 vs 1.13 ± 0.72 ; $P=0.001$), and in DKD patients with CKD grade 3b, than in those with CKD grade 3a (1.59 ± 0.59 vs 0.77 ± 0.48 ; $P<0.001$). Cortical stiffness was inversely correlated with the estimated glomerular filtration rate ($r=-0.65$, $P<0.001$) and with cortical thickness ($r=-0.43$, $P<0.001$) in patients with DKD.

Conclusions: In patients with advanced DKD, SWE imaging may be utilized as a simple and practical method for quantitative evaluation of the chronic morphological changes and for the differentiation between CKD grades.

Keywords: diabetic kidney disease, shear wave, elastography, cortical stiffness

Introduction

Diabetes mellitus is the leading cause of end-stage renal disease (ESRD) worldwide. Clinically, diabetic kidney disease (DKD) is characterized by a progressive increase in proteinuria, a decline in glomerular filtration rate (GFR), elevated blood pressure, and a high risk of kidney failure. In addition, advanced DKD is characterized by morphologic renal changes that include varying degrees of fibrosis.^{1,2}

For a number of decades, the evaluation of renal disorders has been based on a variety of conventional methods, including ultrasound, computerized tomography, magnetic fields, and biochemical analysis. Although the progression of DKD can be assessed from routine biochemical tests, such as the amount of urinary protein and serum creatinine levels, assessment of the grade of renal fibrosis requires renal biopsy.

Correspondence: Kamal Hassan
 Department of Nephrology and Hypertension, Peritoneal Dialysis Unit – Galilee Medical Center,
 PO Box 21, Nahariya 22100, Israel
 Tel +972 5 0788 7913
 Fax +972 4 910 7482
 Email drkamalh@hotmail.com

This is an invasive and costly procedure that may be associated with certain risks and is not routinely performed.³⁻⁵

While kidney biopsy is required for the definitive diagnosis of diabetic nephropathy, in most cases, careful screening of diabetic patients can identify people with DKD without the need for kidney biopsy. Thus, renal biopsy is usually considered when the course of DKD is not typical, as when other diseases, such as membranous nephropathy, are suspected. Although most complications of renal biopsies are mild and resolve spontaneously, major complications have been reported in up to 7.3% of biopsies.³ Renal insufficiency is considered a main risk factor for the development of complications after renal biopsies. The risk of bleeding has been shown to increase with worsening of the degree of renal insufficiency.⁴ Compared to patients with normal renal function, patients with CKD grades 3 and 4 have a six-fold increased risk of severe bleeding.⁴ Despite the identification of predisposing risk factors, there is no definitive way to predict which patients will develop serious bleeding. Therefore, a noninvasive method may be preferred for assessing the severity and progression of chronic renal changes, particularly in cases in which it is advisable to avoid performing a kidney biopsy, such as in DKD patients with a single kidney or in those who are receiving anticoagulant therapy. Thus, shear wave elastography (SWE) imaging may be applied as a simple tool for assessing the severity of chronic morphologic changes and for establishing categories of severity based on cortical stiffness measurements, at least in cases in which renal biopsy should be avoided or is contraindicated. Certainly, other studies are needed to establish the correlations between cortical stiffness, morphologic changes, and renal function.

Conventional renal ultrasound may reveal reduced renal length and cortical thickness, as well as increased cortical echogenicity, which may suggest the presence of chronic atrophic morphological changes in a variety of renal diseases. However, these measurements are not quantitative. Moreover, in diabetic patients, kidneys frequently do not show atrophic change by conventional renal ultrasound, even in advanced DKD with CKD grades 3 and 4. Therefore, conventional renal ultrasound is, generally, not informative for the evaluation of the progression of DKD and not useful for the differentiation between the CKD grades.^{1,2,6}

SWE imaging, based on acoustic radiation force impulse (ARFI) technology, is a noninvasive and cost effective ultrasound diagnostic method that has been developed for the evaluation of tissue elasticity.⁷⁻¹⁰ Essentially, SWE technology measures the velocity of the shear wave (in m/s)

that passes through the examined tissue, and then converts this measurement into a tissue stiffness measurement that is expressed in kPa.⁷⁻¹¹ Combined conventional and SWE imaging can provide qualitative and quantitative assessments of tissue elasticity. A number of recent applications of SWE have focused on the evaluation of the mechanical properties of renal tissue.⁷⁻¹¹

Mechanical properties of the kidney depend on its histology, particularly the amount of fibrosis in the renal parenchyma. A simple, practical, and noninvasive measure is needed for quantitative assessment of renal fibrosis. Yet, the ARFI technique is difficult to apply to native kidneys because of the limited detection depth, which is a maximum of 8 cm from the probe surface. Only a few studies examined renal elastographic parameters in native kidneys of patients with DKD. Goya et al¹⁰ and Yu et al¹¹ showed that ARFI can be used to assess renal morphologic changes in patients with DKD. Goya et al¹⁰ evaluated the changes in the elasticity of the renal parenchyma in healthy volunteers and patients with diabetic nephropathy using ARFI imaging. The shear wave velocities (m/s) for the kidneys were higher in patients with stage 1–5 diabetic nephropathy than healthy volunteers, and it was concluded that ARFI imaging was able to distinguish between different diabetic nephropathy stages (except for stage 5). Also, Yu et al¹¹ evaluated the changes in the elasticity of the renal parenchyma in healthy volunteers and three groups of patients with diabetic nephropathy, according to their urinary albumin-to-creatinine ratio (ACR): normoalbuminuria (ACR <30 mg/g), microalbuminuria (ACR 30–300 mg/g), and macroalbuminuria (ACR ≥300 mg/g and estimated glomerular filtration rate [eGFR] ≥30 mL/min/1.73 m²), to determine and to compare the shear wave velocity of the renal cortex between these groups.⁶ The results showed that there was no significant difference between the normoalbuminuria and healthy subjects, but there was a significant difference between the microalbuminuria and macroalbuminuria groups and the healthy subjects. It was concluded that it is feasible to use ARFI imaging to determine the renal cortical shear wave velocity for judging renal injury in type 2 diabetes mellitus.

In the current study, we investigated whether renal SWE imaging expressed in kPa can serve as a practical and non-invasive tool for quantitative assessment of renal fibrosis in DKD patients with CKD grades 3a, 3b, and 4, where conventional renal ultrasound is not informative for the evaluation of the progression of DKD and not useful for the differentiation between CKD grades.

Materials and methods

The study protocol was approved by the Institutional Helsinki Committee of Galilee Medical Center, Naharyia, Israel (no 0096-14-NHR) and written informed consent was obtained from all participants.

Twenty-nine patients with type 2 diabetes mellitus and CKD grade 3–4 due to DKD, and 23 healthy subjects were enrolled in the study. All patients with DKD were receiving diabetic treatment, seven (24.1%) were receiving oral antidiabetic treatment, and 22 (75.9%) were receiving insulin therapy. The eGFR was calculated by using the CKD epidemiology collaboration (CKD-EPI) equation:

$$\text{GFR} = 141 * \min(\text{Scr}/\kappa, 1)^\alpha * \max(\text{Scr}/\kappa, 1) - 1.209 * \\ 0.993 \text{ Age} * 1.018 [\text{if female}] * \\ 1.159 [\text{if African ethnicity}].$$

where Scr is serum creatinine (mg/dL); κ is 0.7 for females, and 0.9 for males; α is -0.329 for females and -0.411 for males; min indicates the minimum of Scr/κ or 1; and max indicates the maximum of Scr/κ or 1.¹² Daily urinary protein excretion was determined by 24-hour urine collection. Diabetic nephropathy was defined on the basis of a urinary albumin excretion of more than 300 mg in a 24-hour urine collection and reduced eGFR.²

Combined conventional ultrasound imaging for routine kidney scan with SWE imaging, using the Philips iU22 xMATRIX ultrasound system with ARFI-based technology, including a 5–1 MHz convex probe (Philips Medical Systems, Bothell, WA, USA), was performed on all participants. Immediately after image acquisition, the screen displays the image and measurement results, including the mean and median values and the deviations expressed in kPa or m/s. If measurement reliability is low, 0.00 kPa will be displayed as the result. Elastic value (E) expressed in kPa is calculated using the equation:

$$E = 3\rho V_s^2$$

where V_s (m/s) is defined as the shear wave propagation velocity and ρ as tissue density (with an approximated value in the human body of 1 g/cm³). The ρ of blood is 1.0428 g/cm³, fat 0.9094 g/cm³, and muscle 1.0599 g/cm³.

The region of interest (ROI) can be placed anywhere, but always at a depth of <8 cm. All the measurements were performed in the supine and the right or left lateral decubitus positions while the patients were holding their breath. The probe was placed steadily with minimal compression. The mean

values from ten measurements were used. The most appropriate ROI used was the center of the image, immediately below the probe, and <8 cm from the probe surface. The radiologic evaluations, including the conventional ultrasound and elastographic examinations, were performed by a single experienced radiologist. The usual examination time was 20–30 minutes. Symptoms or a history of abnormal imaging data (including cysts, stones, or hydronephrosis on conventional ultrasound) were considered exclusion criteria. Before renal SWE imaging was performed, kidneys were checked by conventional ultrasound to detect stones, cysts, hydronephrosis, or masses. Obese subjects with a renal depth of more than 8 cm from the skin surface were excluded from the study. The length and width were recorded for each right and left kidney. Cortical thickness was measured at ten locations between kidney poles of both kidneys. The cortical thickness for each kidney was calculated as the mean of ten measurements expressed in mm. The elastographic measurements of the cortical stiffness were taken at ten locations between kidney poles of both kidneys. The cortical stiffness for each kidney was calculated as the mean of ten measurements expressed in kPa.

Statistical methods

Statistical analysis was carried out using Statistical Package for the Social Sciences (SPSS) (IBM SPSS Statistics Version 21, Armonk, NY, USA) software; $P < 0.05$ was considered to be significant. Continuous variables were reported as mean values and standard deviations, and categorical variables as frequencies and percentages. The unpaired *t*-test was used to compare the differences between the study groups, according to age, BMI, HbA1c, eGFR, proteinuria level, kidney length, kidney width, cortical thickness, and cortical stiffness. The Chi square test was used to compare the gender distribution between the study groups. Pearson's correlation coefficient test was used to describe associations between cortical stiffness, age, eGFR, and cortical thickness.

Results

The study group comprised 29 patients with DKD: 14 with CKD grade 3 and 15 with CKD grade 4. Their mean eGFR was 32.0 ± 11.6 mL/min/1.73 m² and mean daily proteinuria level was 1.61 ± 1.09 g/day. Characteristics of the study population are summarized in Table 1.

Cortical thickness was significantly lower in patients with DKD than in healthy subjects (13.8 ± 2.2 vs 14.8 ± 1.6 mm; $P = 0.002$) (Table 2) and in DKD patients with CKD grade 4 than in those with grade 3 (13.0 ± 3.5 vs 14.7 ± 2.1 mm; $P < 0.001$) (Table 3). Stratifying by gender, cortical thickness

Table 1 Demographic and laboratory characteristics of the study population

Variables	DKD patients with CKD grades 3 and 4	Healthy subjects	P-value
n	29	23	
Males, n (%)	17 (58.6)	13 (56.5)	0.525
Females, n (%)	12 (41.4)	10 (43.5)	0.997
Age (years)	61.12±10.85	58.50±9.420	0.099
BMI (kg/m ²)	28.46±2.85	26.86±2.00	0.044
HbA1c (%)	7.32±0.43	5.48±0.32	<0.001
eGFR (mL/min/1.73 m ²)	32.0±11.6	≥90	
Proteinuria (g/day)	1.61±1.09	<0.15	
Diabetes mellitus, n	29	0	
Oral antidiabetic therapy, n (%)	7 (24.1)	0	
Insulin therapy, n (%)	22 (75.9)	0	
ACEIs or ARBs	18 (62.1)	0	
DKD and CKD grade 3, n	14	0	
DKD and CKD grade 4, n	15	0	

Notes: Values of age, BMI, HbA1c, eGFR, and daily proteinuria are represented as mean ± standard deviation.

Abbreviations: CKD, chronic kidney disease; DKD, diabetic kidney disease; BMI, body mass index; eGFR, estimated glomerular filtration rate; ACEIs, angiotensin converting enzyme inhibitors; ARBs, angiotensin II blockers.

Table 2 Conventional and shear wave elastography imaging parameters

Variables	Patients with CKD grade 3–4 due to DKD	Healthy subjects	P-value
Number of participants	29	23	
Number of evaluated kidneys	58	46	
Kidney length (cm)	10.60±1.14	10.49±0.91	0.289
Kidney width (cm)	4.79±0.66	4.67±0.53	0.138
Cortical thickness (mm) (all patients)	13.8±2.2	14.8±1.6	0.002
Cortical thickness (mm) (males)	14.0±1.32 [§]	14.9±1.7 [#]	0.002
Cortical thickness (mm) (females)	13.3±1.2 [§]	14.7±1.2 [#]	0.002
Cortical stiffness (kPa) (all patients)	23.72±14.33	9.02±2.42	<0.001
Cortical stiffness (kPa) (males)	24.34±17.21 [*]	9.63±2.49 ^{**}	<0.001
Cortical stiffness (kPa) (females)	22.89±9.58 [*]	8.73±2.46 ^{**}	<0.001

Notes: Values are presented as mean ± standard deviation. [§]P=0.078; [#]P=0.405; ^{*}P=0.353; ^{**}P=0.117.

Abbreviations: CKD, chronic kidney disease; DKD, diabetic kidney disease.

Table 3 Shear wave elastography imaging parameters in CKD grade 3 and grade 4 due to DKD

Variables	Patients with CKD grade 3a due to DKD	Patients with CKD grade 3b due to DKD	P-value*	Patients with CKD grade 3 due to DKD	Patients with CKD grade 4 due to DKD	P-value [#]
Number of participants	7	7		14	15	
Number of evaluated kidneys	14	14		28	30	
eGFR (mL/min/1.73 m ²)	49.1±4.4	34.9±3.7	<0.001	42.0±8.3	21.7±4.8	<0.001
Cortical thickness (mm)	14.9±2.1	14.3±2.5	0.496	14.7±2.1	13.0±3.5	<0.001
Cortical stiffness (kPa)	11.0±4.2	15.7±6.7	0.03	14.6±8.1	30.4±16.2	<0.001
Proteinuria (g/day)	0.77±0.48	1.59±0.59	<0.001	1.13±0.72	5.52±0.96	0.001

Notes: Values are presented as mean ± standard deviation. ^{*}P=, significance between grade 3a and grade 3b variables; [#]P=, significance between grade 3 and grade 4 variables.

Abbreviations: CKD, chronic kidney disease; DKD, diabetic kidney disease; eGFR, estimated glomerular filtration rate.

was lower for individuals with DKD than for healthy subjects (males: 14.0 ± 1.3 vs 14.9 ± 1.7 mm; $P=0.002$; females: 13.3 ± 1.2 vs 14.7 ± 1.2 cm; $P=0.002$). Mean values of cortical thickness were similar in males and females among the diabetic patients, as well as among the healthy subjects (Table 2).

Cortical stiffness was significantly greater in patients with DKD than in healthy subjects (23.72 ± 14.33 vs 9.02 ± 2.42 kPa; $P<0.001$) (Table 2), in DKD patients with CKD grade 4 than in those with grade 3 (30.4 ± 16.2 vs 14.6 ± 8.1 kPa; $P<0.001$) (Table 3), and in DKD patients with CKD grade 3b, than in those with CKD grade 3a (15.7 ± 6.7 vs 11.0 ± 4.2 kPa; $P=0.03$) (Table 3). Stratifying by gender, cortical stiffness was greater for individuals with DKD than for healthy subjects: (males: 24.34 ± 17.21 vs 9.63 ± 2.49 kPa; $P<0.001$; females: 22.89 ± 9.58 vs 8.73 ± 2.46 kPa; $P<0.001$) (Table 2). Mean values of cortical stiffness were similar in males and females among the diabetic patients, as well as among the healthy subjects (Table 2).

Daily proteinuria was higher in DKD patients with CKD grade 4 than in those with grade 3 (5.52 ± 0.96 vs 1.13 ± 0.72 ; $P=0.001$) and in DKD patients with CKD grade 3b, than in those with CKD grade 3a (1.59 ± 0.59 vs 0.77 ± 0.48 ; $P<0.001$) (Table 3).

Cortical stiffness was inversely correlated with the eGFR ($r=-0.65$, $P<0.001$) (Figure 1) and with cortical thickness ($r=-0.43$, $P<0.001$) in patients with DKD (Figure 2). Cortical stiffness was positively correlated with daily proteinuria ($r=0.56$, $P<0.001$) (Figure 3). Daily proteinuria was inversely correlated with the eGFR ($r=-0.53$, $P<0.001$) (Figure 4).

In analysis of the total sample, no correlations were found between cortical stiffness and kidney length, kidney width, and gender. No correlation was found between cortical stiffness and cortical thickness in healthy subjects.

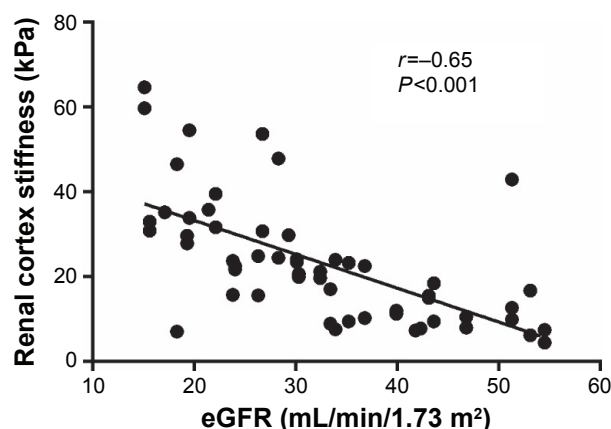


Figure 1 The inverse correlation between renal cortex stiffness and estimated glomerular filtration rate (eGFR).

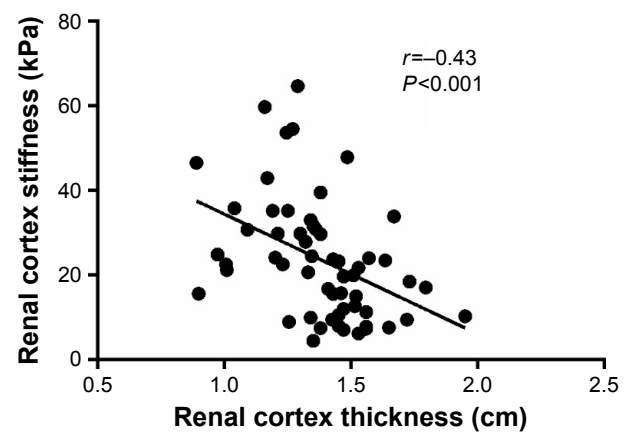


Figure 2 The inverse correlation between renal cortex stiffness and thickness.

Discussion

Compared to healthy individuals, cortical stiffness was significantly higher and inversely correlated with the eGFR in DKD patients with CKD grades 3 and 4. Moreover, cortical stiffness was significantly higher in DKD patients with CKD grade 3b than in those with CKD grade 3a. These data suggest that SWE may be applied as a noninvasive, simple, cost effective, and reliable imaging technique that can quantitatively assess the extent of cortical fibrosis in advanced DKD, and enable differentiation between CKD grades 3a, 3b, and 4. In contrast, conventional ultrasound and other expensive imaging methods, including computerized tomography and magnetic fields, are not quantitative for the assessment of the severity of chronic morphologic changes, and not informative for differentiation between these CKD grades.

According to Kidney Disease Improving Global Outcomes (KDIGO), classification of CKD is based on the degree of decline in GFR and the presence of

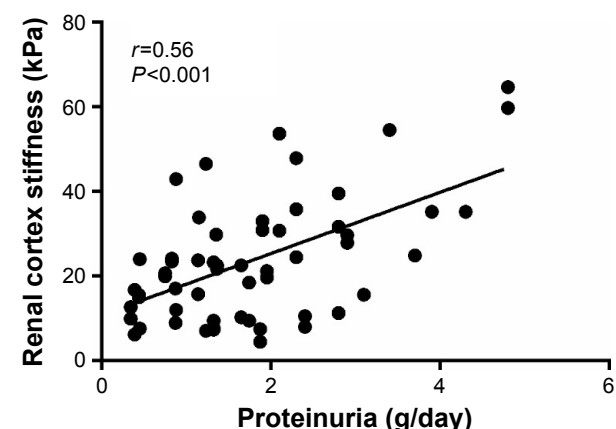


Figure 3 The positive correlation between renal cortex stiffness and daily proteinuria.

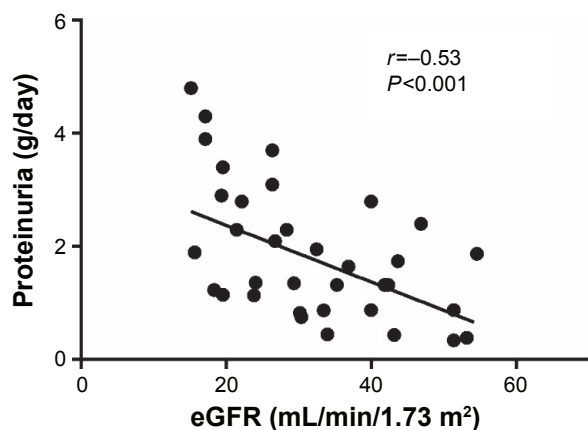


Figure 4 The inverse correlation between daily proteinuria and estimated glomerular filtration rate (eGFR).

kidney damage markers, rather than on direct examination of kidney tissue.² These markers include abnormalities in urinary protein excretion, urine sediment, electrolyte and solutes, pathologic changes in kidney tissue obtained by biopsy, imaging abnormalities, and history of kidney transplantation. The quantitative information obtained by SWE imaging enables more accurate assessment of the chronic morphological changes associated with the progression of DKD.^{5,7–11} Furthermore, SWE imaging may be used as a noninvasive, practical, and quantitative kidney damage marker, and as a tool for assigning CKD grades in DKD patients.

While only few studies have documented the use of SWE imaging in relation to native kidneys, SWE has become a useful and practical method to evaluate other organs. For example, although liver biopsy has long been the gold standard procedure for assessing the degree of chronic morphologic changes in the liver, SWE has been used to stage liver fibrosis.¹³ Moreover, SWE imaging has been used for the evaluation of pathologic processes in several tissues, including breast, prostate, pancreas, testis, thyroid, and transplanted kidneys.^{13–18} Human native kidneys are located at a greater depth than the liver and transplanted kidneys and, therefore, assessment of their renal elasticity is more difficult.^{14–21} Consequently, the earliest studies of renal SWE imaging were performed in animals and transplanted kidneys. Animal studies on rats and rabbits showed a direct correlation between renal cortical stiffness and renal fibrotic changes, and between an increase in cortical stiffness and a decline in renal function.^{19,20} In studies of transplanted kidneys, increased renal stiffness was detected in cases of transplant rejection and in patients who developed acute deterioration in renal function.^{21–37}

Of the few studies that examined the use of SWE to assess renal stiffness, and its relationship to native kidney function, four evaluated renal elasticity in CKD patients.^{8,38–40} Only two studies showed that SWE imaging, using ARFI-based technology, can be used to assess renal morphologic changes in patients with DKD.^{10,11} In both studies, histological samples were lacking because renal biopsies were not performed and the diagnosis of DKD was based on the presence of albuminuria and/or reduced kidney function. One study evaluated the elasticity of renal parenchyma in different grades of DKD. The second study evaluated the elasticity of the renal parenchyma in healthy controls and in patients with DKD and different levels of proteinuria. The results of both studies suggest that SWE imaging, using ARFI-based technology, may distinguish between renal elasticity changes in DKD. The results of the present study revealed that SWE imaging can differentiate not only between CKD grades in DKD (as was shown by Goya et al¹⁰) but also between CKD subgrades 3a, 3b, as was shown for the first time in the present study. Furthermore, the results showed that the cortical stiffness was inversely correlated with the eGFR and positively with the level of proteinuria which, itself, was found to be positively correlated with cortical stiffness. Thus, these data suggest that SWE imaging can be considered as an additional noninvasive and more accurate tool for the evaluation of the severity of chronic morphological changes than other imaging methods, and can contribute to better follow-up regarding the progression of DKD.

Although current treatments that focus on controlling hyperglycemia and hypertension with renin–angiotensin system inhibitors reduce the risk of progressive kidney disease, DKD remains the leading cause of ESRD.^{41–43} Metabolic abnormalities including high levels of glucose and lipids may produce glycated lipids and reactive oxygen species that lead to the production of inflammatory cytokines and profibrotic factors.^{41–43} These may incur mesangial, endothelial, and epithelial damage that ultimately results in the development of glomerulosclerosis and tubulointerstitial fibrosis that are characteristic of DKD.^{41–43} Based on these advances, novel therapeutic agents, targeting different mechanisms of DKD, are under evaluation. Renal biopsies are not practical for following the response to such agents. In contrast, renal SWE imaging may be considered a reliable and alternative method for providing additional information concerning the severity and progression of the chronic changes of DKD and the therapeutic response to the investigational therapies.

In summary, while kidney biopsy remains the gold standard for diagnosing renal chronic morphological changes, this method is an invasive and expensive procedure that requires hospitalization, and may be associated with various risks.^{3–5} Renal insufficiency predisposes to dangerous complications after renal biopsies, particularly severe bleeding.⁴ Additionally, sometimes biopsies should be repeated periodically to monitor disease progression. Although the idea of a noninvasive method to detect the progression of CKD in the diabetic patient is tempting, the actual need for renal biopsy in diabetics is restricted to certain medical situations, such as the presence of hematuria, active sediments, heavy proteinuria, or an atypical course of DKD.⁴⁴ However, due to the rising number of patients with DKD worldwide, and based on the findings in the present study, SWE appears to be a simple, practical, and “virtual” method for evaluating the native kidney in patients with advanced DKD. Additionally, the findings in the present study suggest that SWE may be applied for evaluation of chronic morphological changes in DKD patients with a single kidney and those on anticoagulant therapy. However, this technology is a new tool for renal tissue characterization and further studies are needed to provide additional confirmation and validation in clinical practice.

Limitations

The present study was performed in one center and included a relatively small number of patients. The study was also limited because of the absence of real-time renal histopathologic samples of the studied population, which were not obtained due to ethical considerations. The maximum detection depth of only 8 cm limits the use of the SWE method, and the accuracy of measurements depends on the skill of the examiner.

Conclusion

In patients with advanced DKD, SWE imaging may be utilized as a simple and practical method for quantitative evaluation of the chronic morphological changes and for the differentiation between different CKD grades. Multicenter studies are needed to provide additional confirmation and validation in clinical practice.

Disclosure

The authors report no conflicts of interest in this work.

References

- Gross JL, de Azevedo MJ, Silveiro SP, Canani LH, Caramori ML, Zelmanovitz T. Diabetic nephropathy: diagnosis, prevention, and treatment. *Diabetes Care*. 2005;28:164–176.
- KDOQI Clinical Practice Guidelines and Clinical Practice Recommendations for Diabetes and Chronic Kidney Disease. *Am J Kidney Dis*. 2007; 49(2 Suppl 2):S12–S154.
- Korbet SM. Percutaneous renal biopsy. *Semin Nephrol*. 2002;22(3): 254–267.
- Christensen J, Lindequist S, Knudsen DU, Pedersen RS. Ultrasound-guided renal biopsy with biopsy gun technique—efficacy and complications. *Acta Radiol*. 1995;36(3):276–279.
- Chesney DS, Brouhard BH, Cunningham RJ. Safety and cost effectiveness of pediatric percutaneous renal biopsy. *Pediatr Nephrol*. 1996;10(4): 493–495.
- Sicari R, Gargani L, Wiecek A, et al. The use of echocardiography in observational clinical trials: the EURECA-m registry. *Nephrol Dial Transplant*. 2013;28(1):19–23.
- Zaffanello M, Piacentini G, Bruno C, Brugnara M, Fanos V. Renal elasticity quantification by acoustic radiation force impulse applied to the evaluation of kidney diseases: a review. *J Investig Med*. 2015;63(4): 605–612.
- Samir AE, Allegretti AS, Zhu Q, et al. Shear wave elastography in chronic kidney disease: a pilot experience in native kidneys. *BMC Nephrol*. 2015;116:119.
- Sarvazyan AP, Rudenko OV, Swanson SD, Fowlkes JB, Emelianov SY. Shear wave elasticity imaging: a new ultrasonic technology of medical diagnostics. *Ultrasound Med Biol*. 1998;24(9):1419–1435.
- Goya C, Kilinc F, Hamidi C, et al. Acoustic radiation force impulse imaging for evaluation of renal parenchyma elasticity in diabetic nephropathy. *AJR Am J Roentgenol*. 2015;204(2):324–329.
- Yu N, Zhang Y, Xu Y. Value of virtual touch tissue quantification in stages of diabetic kidney disease. *J Ultrasound Med*. 2014;33(5): 787–792.
- Levey AS, Stevens LA, Schmid CH, et al. A new equation to estimate glomerular filtration rate. *Ann of Intern Med*. 2009;150(9):604–612.
- Afdhal NH. Fibroscan (transient elastography) for the measurement of liver fibrosis. *Gastroenterol Hepatol (N Y)*. 2012;8(9):605–607.
- Zheng XZ, Ji P, Mao HW, et al. A novel approach to assessing changes in prostate stiffness with age using virtual touch tissue quantification. *J Ultrasound Med*. 2011;30(3):387–390.
- D’Anastasi M, Schneevogt BS, Trottmann M, et al. Acoustic radiation force impulse imaging of the testes: a preliminary experience. *Clin Hemorheol Microcirc*. 2011;49(1–4):105–114.
- Bai M, Du L, Gu J, Li F, Jia X. Virtual touch tissue quantification using acoustic radiation force impulse technology: initial clinical experience with solid breast masses. *J Ultrasound Med*. 2012;31(2): 289–294.
- Zhang YF, Xu HX, He Y, et al. Virtual touch tissue quantification of acoustic radiation force impulse: a new ultrasound elastic imaging in the diagnosis of thyroid nodules. *PLoS One*. 2012;7(11):e49094.
- Sporea I, Gilja OH, Bota S, Şirli R, Popescu A. Liver elastography – an update. *Med Ultrason*. 2013;15(4):304–314.
- Derieppe M, Delmas Y, Gennisson JL, et al. Detection of intrarenal microstructural changes with supersonic shear wave elastography in rats. *Eur Radiol*. 2012;22(1):243–250.
- Moon SK, Kim SY, Cho JY, Kim SH. Quantification of kidney fibrosis using ultrasonic shear wave elastography: experimental study with a rabbit model. *J Ultrasound Med*. 2015;34(5):869–877.
- Sommerer C, Scharf M, Seitz C, et al. Assessment of renal allograft fibrosis by transient elastography. *Transpl Int*. 2013;26(5):545–551.
- Arndt R, Schmidt S, Loddenkemper C, et al. Noninvasive evaluation of renal allograft fibrosis by transient elastography – a pilot study. *Transpl Int*. 2010;23(9):871–877.
- Lee J, Oh YT, Joo DJ, et al. Acoustic Radiation Force Impulse Measurement in Renal Transplantation: A Prospective, Longitudinal Study With Protocol Biopsies. *Medicine (Baltimore)*. 2015;94(39):e1590.
- Nakao T, Ushigome H, Nakamura T, et al. Evaluation of renal allograft fibrosis by transient elastography (Fibro Scan). *Transplant Proc*. 2015; 47(3):640–643.

25. Orlacchio A, Chegai F, Del Giudice C, et al. Kidney transplant: usefulness of real-time elastography (RTE) in the diagnosis of graft interstitial fibrosis. *Ultrasound Med Biol*. 2014;40(11):2564–2572.
26. Gao J, Rubin JM. Ultrasound strain zero-crossing elasticity measurement in assessment of renal allograft cortical hardness: a preliminary observation. *Ultrasound Med Biol*. 2014;40(9):2048–2057.
27. Lukenda V, Mikolasevic I, Racki S, Jelic I, Stimac D, Orlic L. Transient elastography: a new noninvasive diagnostic tool for assessment of chronic allograft nephropathy. *Int Urol Nephrol*. 2014;46(7):1435–1440.
28. He WY, Jin YJ, Wang WP, Li CL, Ji ZB, Yang C. Tissue elasticity quantification by acoustic radiation force impulse for the assessment of renal allograft function. *Ultrasound Med Biol*. 2014;40(2):322–329.
29. Gao J, Min R, Hamilton J, et al. Corticomedullary strain ratio: a quantitative marker for assessment of renal allograft cortical fibrosis. *J Ultrasound Med*. 2013;32(10):1769–1775.
30. Kahn J, Slowinski T, Thomas A, Filimonow S, Fischer T. TSI ultrasound elastography for the diagnosis of chronic allograft nephropathy in kidney transplanted patients. *J Ultrason*. 2013;13(54):253–262.
31. Gao J, Weitzel W, Rubin JM, et al. Renal transplant elasticity ultrasound imaging: correlation between normalized strain and renal cortical fibrosis. *Ultrasound Med Biol*. 2013;39(9):1536–1542.
32. Syversveen T, Midtvedt K, Berstad AE, Brabrand K, Strom EH, Abildgaard A. Tissue elasticity estimated by acoustic radiation force impulse quantification depends on the applied transducer force: an experimental study in kidney transplant patients. *Eur Radiol*. 2012;22(10):2130–2137.
33. Grenier N, Poulain S, Lepreux S, et al. Quantitative elastography of renal transplants using supersonic shear imaging: a pilot study. *Eur Radiol*. 2012;22(10):2138–2146.
34. Lee CU, Glockner JF, Glaser KJ, et al. MR elastography in renal transplant patients and correlation with renal allograft biopsy: a feasibility study. *Acad Radiol*. 2012;19(7):834–841.
35. Stock KF, Klein BS, Cong MT, et al. ARFI-based tissue elasticity quantification and kidney graft dysfunction: first clinical experiences. *Clin Hemorheol Microcirc*. 2011;49(1–4):527–535.
36. Stock KF, Klein BS, Vo Cong MT, et al. ARFI-based tissue elasticity quantification in comparison to histology for the diagnosis of renal transplant fibrosis. *Clin Hemorheol Microcirc*. 2010;46(2–3):139–148.
37. Syversveen T, Brabrand K, Midtvedt K, et al. Assessment of renal allograft fibrosis by acoustic radiation force impulse quantification—a pilot study. *Transpl Int*. 2011;24(1):100–105.
38. Hu Q, Wang XY, He HG, Wei HM, Kang LK, Qin GC. Acoustic radiation force impulse imaging for non-invasive assessment of renal histopathology in chronic kidney disease. *PLoS One*. 2014;9(12):e115051.
39. Grenier N, Gennisson JL, Cornelis F, Le Bras Y, Couzi L. Renal ultrasound elastography. *Diagn Interv Imaging*. 2013;94(5):545–550.
40. Menzilcioglu MS, Duymus M, Citil S, et al. Strain wave elastography for evaluation of renal parenchyma in chronic kidney disease. *Br J Radiol*. 2015;88(1050):20140714.
41. Arora MK, Singh UK. Molecular mechanisms in the pathogenesis of diabetic nephropathy: an update. *Vascul Pharmacol*. 2013;58(4):259–271.
42. Vinod PB. Pathophysiology of diabetic nephropathy. *Clin Queries: Nephrology*. 2012;1(2):121–126.
43. Sun YM, Su Y, Li J, Wang LF. Recent advances in understanding the biochemical and molecular mechanism of diabetic nephropathy. *Biochem Biophys Res Commun*. 2013;433(4):359–361.
44. Ritz E. Clinical manifestations and natural history of diabetic kidney disease. *Med Clin N Am*. 2013;97(1):19–29.

Therapeutics and Clinical Risk Management

Publish your work in this journal

Therapeutics and Clinical Risk Management is an international, peer-reviewed journal of clinical therapeutics and risk management, focusing on concise rapid reporting of clinical studies in all therapeutic areas, outcomes, safety, and programs for the effective, safe, and sustained use of medicines. This journal is indexed on PubMed Central, CAS,

Submit your manuscript here: <http://www.dovepress.com/therapeutics-and-clinical-risk-management-journal>

Dovepress

EMBASE, Scopus and the Elsevier Bibliographic databases. The manuscript management system is completely online and includes a very quick and fair peer-review system, which is all easy to use. Visit <http://www.dovepress.com/testimonials.php> to read real quotes from published authors.