

# Radiofrequency ablation using Barrx<sup>®</sup> for the endoscopic treatment of gastric antral vascular ectasia: a series of three cases and a review of the literature on treatment options

Anish Patel  
 Sunil Patel  
 Prasanna C Wickremesinghe  
 Deepak Vadada

Department of Gastrointestinal  
 Medicine, Richmond University  
 Medical Center, Staten Island,  
 NY, USA

**Abstract:** Gastric antral vascular ectasia (GAVE), also known as “watermelon stomach”, is an uncommon condition, which can cause gastrointestinal bleeding due to rupture of blood vessels that line the stomach. The pathogenesis of GAVE remains unclear; however it is thought that hemodynamic changes, mechanical stress, and autoimmune factors all have a part to play. A range of conditions are also commonly associated with the syndrome, such as portal hypertensive gastropathy, liver cirrhosis, and autoimmune disorders. Less commonly, chronic renal failure, cardiac diseases, and bone marrow transplantation have coexisted with GAVE. The diagnosis is usually based on visualization of the tissue upon endoscopy; however, histology plays a role in uncertain cases. The typical “watermelon” appearance relates to the tissue having a striped appearance radiating out from the pylorus. Medical treatment has failed to show satisfactory results and surgery is usually considered as a last resort, due to its increased risk for complications and mortality. Lasers and argon plasma coagulation have been used recently, and been shown to be as effective as surgery and a safer option. We present three cases of gastric antral vascular ectasia treated at our institution with radiofrequency ablation and review the literature on treatment modalities for GAVE.

**Keywords:** gastric antral vascular ectasia, radiofrequency ablation, Barrx, endoscopic treatment

## Introduction

Gastric antral vascular ectasia (GAVE), also known as “watermelon stomach”, is an uncommon cause of upper gastrointestinal bleeding and chronic iron deficiency anemia, often requiring long-term blood transfusion.<sup>1</sup> The pathogenesis of GAVE remains unclear, but it is thought that hemodynamic changes, mechanical stress, and autoimmune factors all have a part to play. A range of conditions are also commonly associated with the syndrome, including portal hypertensive gastropathy, liver cirrhosis, and autoimmune disorders. Less commonly, chronic renal failure, cardiac diseases, and bone marrow transplantation have coexisted with GAVE. The diagnosis is usually based on visualization of the tissue upon endoscopy; however, histology plays a role in uncertain cases. The typical “watermelon” appearance relates to the tissue having a striped appearance radiating out from the pylorus. Systemic interventions such as corticosteroids, hormonal therapy, and octreotide have failed to demonstrate changes in the abnormal mucosa, and patients continue to remain dependent on blood transfusions. Surgery, such as antrectomy, is a definitive treatment

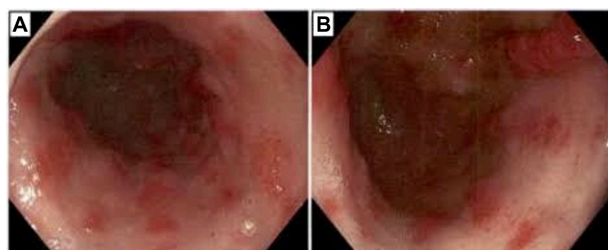
Correspondence: Anish Patel  
 Department of Internal Medicine,  
 Richmond University Medical Center,  
 355 Bard Avenue, Staten Island,  
 NY 10310, USA  
 Tel +1 718 818 2419  
 Email anishpatelanishp255@gmail.com



option, but is associated with high morbidity and mortality.<sup>1</sup> Endoscopic options for therapy include Nd:YAG laser ablation, cryotherapy, heater probe, and argon plasma coagulation (APC). Recently, APC has become one of the preferred modalities in the treatment of chronic radiation proctitis, and many centers have reported success with this treatment. Radiofrequency ablation (RFA) is a newer endoscopic technique that uses a catheter to deliver radiofrequency energy to ablate tissue, and in many centers has become the treatment of choice for early Barrett's esophagus.<sup>1</sup> The HALO® RFA system uses two different types of probes with a closely spaced arrangement of electrodes that thermally ablate tissue. The depth (0.5–1 mm) is dependent on the power, density, and duration of contact. A generator connects to either a 360 degree HALO catheter or to a HALO-90 catheter to provide a circumferential or more focused ablation.<sup>2</sup> There have been some reports of this treatment being used for patients with GAVE who have failed other treatments like argon laser coagulation. We present three cases of GAVE treated with RFA and review the literature on its management. Institutional Review Board approval was not obtained as the Richmond University Medical Center review board does not require approval for case studies with three patients or less. Written informed consent for patient data and images was deemed not required for this study by the Richmond University Medical Center review board due to de-identified patient data and images.

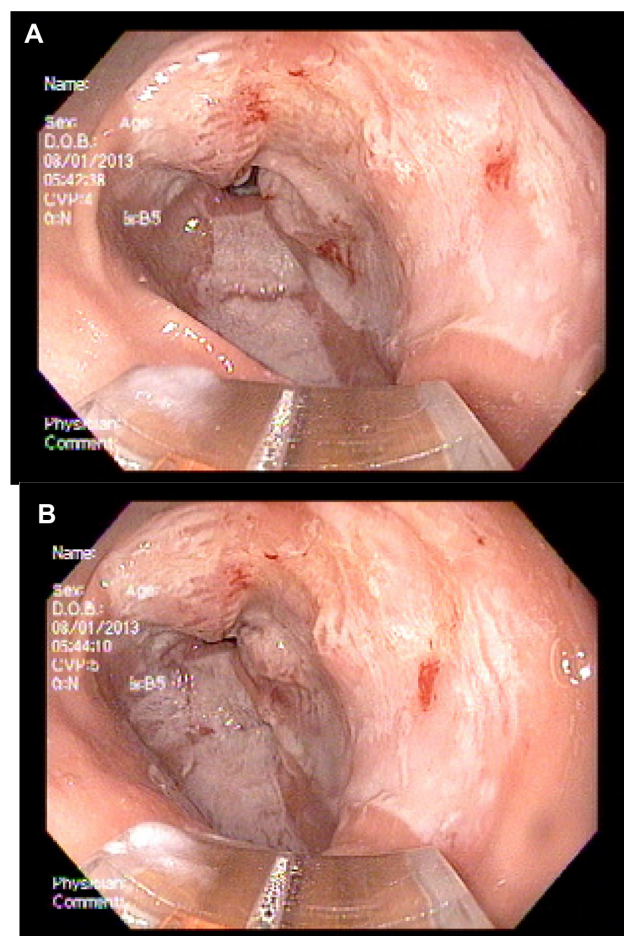
## Case report I

A 51-year-old female patient with a history of gastroesophageal reflux disease, dysphagia, and iron deficiency anemia underwent an upper and lower endoscopy. The patient was found to have findings consistent with gastric antral vascular ectasia (Figure 1). At that time, no definitive therapy was performed, the patient was continued on supplemental iron, and her hemoglobin/hematocrit levels were checked periodically. Her hemoglobin progressively decreased over the next 2 months, and prior to her repeat

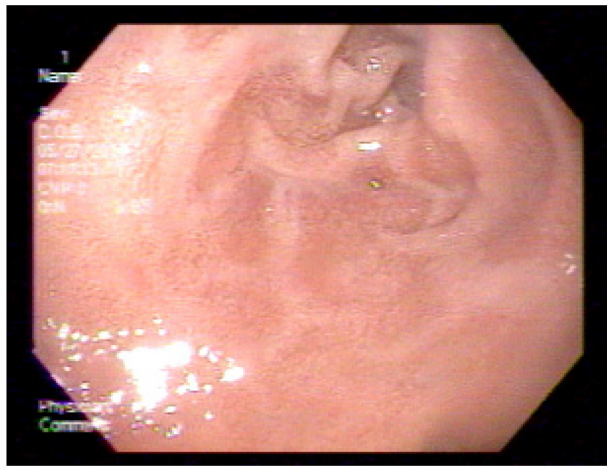


**Figure 1** Gastric antral vascular ectasia on initial upper endoscopy.  
**Notes:** (A, B) Different views demonstrating the same findings.

endoscopy her hemoglobin level was at 9 g/dL. Six months after the initial endoscopy was performed, the patient underwent a repeat upper endoscopy with RFA to the GAVE (Figure 2). The antrum showed early GAVE, which was more prominent than previously seen. The HALO-90 ultra ablator was attached, and the GAVE lesions were cauterized using the 4 cm paddle starting at the “12 o’clock position” going circumferentially in both directions. This technique was performed for half of the area. The instrument was withdrawn and the paddle was attached at the “6 o’clock” position, and the remaining posterior vascular ectatic lesions were cauterized. Over the course of the next year, the patient’s hemoglobin started to increase and on follow-up her hemoglobin was 11.4 g/dL. The patient has done well since the initial therapeutic intervention, and has not required any further sessions of RFA. Three years after the therapeutic intervention was performed, her repeat upper endoscopy shows almost complete healing of the mucosa (Figure 3).



**Figure 2** Immediately post radiofrequency ablation.  
**Notes:** (A, B) Different views demonstrating the same findings.



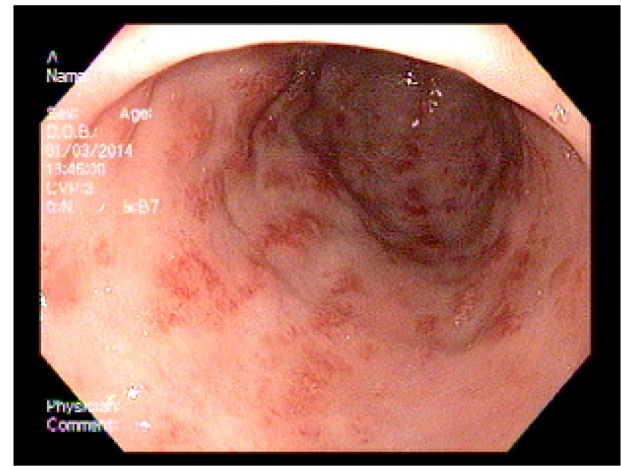
**Figure 3** Upper endoscopy 1 year after radiofrequency ablation.

## Case report 2

A 79-year-old female patient with anemia (hemoglobin 8.4 g/dL) underwent an upper endoscopy and was found to have longitudinal strips of submucosal vascular ectasia leading toward the pylorus, consistent with GAVE. The GAVE lesions were cauterized using cold probe cautery. The patient was monitored over the next few years and did well, with a stable hemoglobin level approximately 8.6–9.8 g/dL. Three years after the initial cauterization, the patient presented with a decrease in her hemoglobin level, and underwent a repeat upper endoscopy. The patient was found to have a lesion in the antrum that was oozing blood, and she again underwent cauterization using the BiCap gold probe until the bleeding had stopped with coaptive coagulation. The patient did well after the procedure, and again maintained a hemoglobin level approximately 8.5–10 g/dL. Over the next few years, the patient required multiple sessions of cauterization (total of six), and her hemoglobin continued to fluctuate. After a total of six sessions, the patient underwent RFA of the GAVE. Her hemoglobin level prior to the therapy was 8.7 g/dL, and during a 1-year follow-up period her hemoglobin levels have been maintained at 10.2–11.5 g/dL. It has been 3 years since the endoscopic intervention with RFA was performed, and the patient has done very well, requiring no additional treatment. Hemoglobin levels have normalized; however, she continues to be followed.

## Case report 3

An 83-year-old female patient with a history of GAVE requiring multiple transfusions in the past presented with symptomatic anemia due to acute blood loss (hemoglobin 8.8 g/dL). On upper endoscopy, the patient was

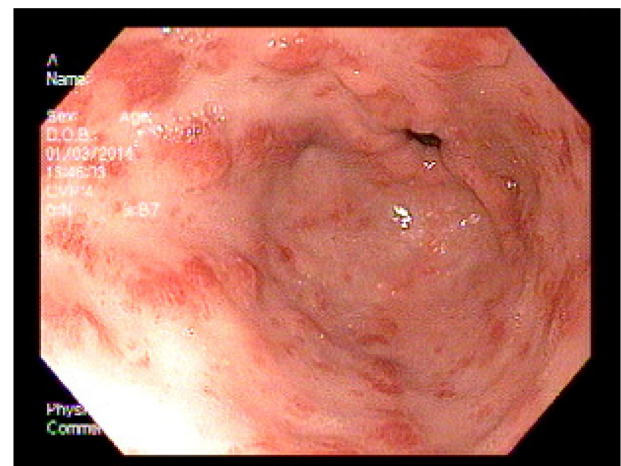


**Figure 4** Upper endoscopy showing the typical longitudinal red stripes in the antrum radiating out from the pylorus, consistent with gastric antral vascular ectasia.

found to have mild gastritis in the fundus and body, and multiple vascular ectasia in the antrum consistent with GAVE (Figures 4 and 5). The patient underwent cauterization with the gold probe electro hemostasis catheter until the bleeding had stopped (Figure 6). The patient did well after the procedure, and maintained a hemoglobin level in the range of 8.7–9.2 g/dL over the next 13 months. However, the patient returned after 14 months with anemia secondary to an upper gastrointestinal bleed. The antrum was noted to have multiple GAVE, and the patient underwent RFA with the HALO-90 catheter (Figure 7). The patient has done very well since the procedure, and at 2-year follow-up her hemoglobin level is 12.3 g/dL.

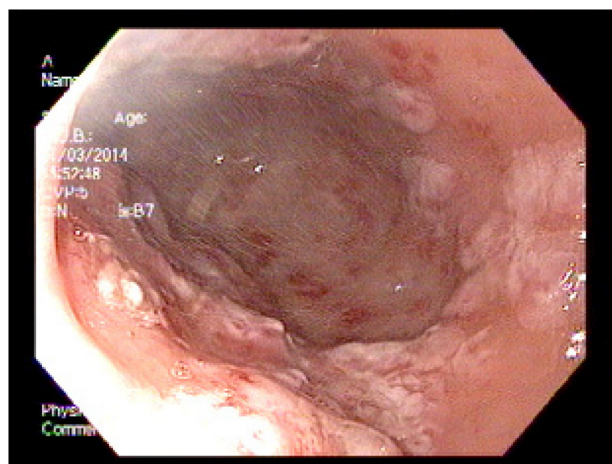
## Discussion

GAVE is an uncommon cause of chronic gastrointestinal bleeding and anemia. On endoscopy, it has a characteristic



**Figure 5** Longitudinal, erythematous stripes can again be seen radiating in a spoke-like fashion from the pylorus to the antrum.

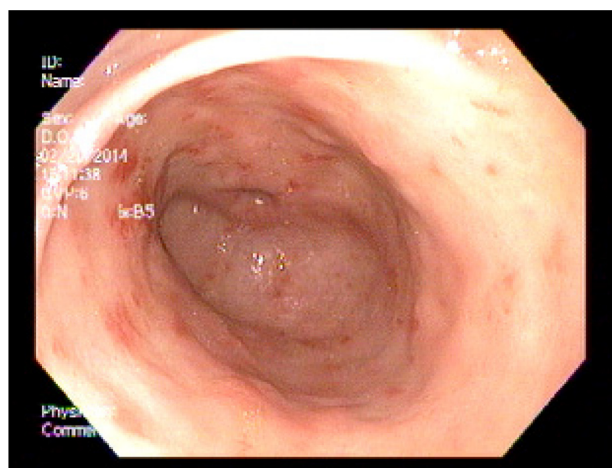




**Figure 6** Upper endoscopy immediately after cauterization with the gold probe hemostasis catheter.

appearance, demonstrating prominent erythematous streaks protruding out from the pylorus to the antrum, often referred to as “watermelon stomach”.<sup>3</sup> The pathogenesis of GAVE remains unclear; however, it is thought that hemodynamic changes, mechanical stress, and autoimmune factors all have a part to play. A range of conditions are commonly associated with the syndrome, including portal hypertensive gastropathy, liver cirrhosis, chronic kidney diseases, and autoimmune and systemic disorders. APC has been the first-line treatment for patients with GAVE and shown promising results; however, approximately two-thirds of patients continue to require blood transfusions.<sup>4</sup>

Results from our case series suggest that RFA is a safe and effective treatment for recurrent bleeding from GAVE. A range of medical and surgical treatments have been used for symptomatic GAVE, with varied results. Examples of



**Figure 7** Upper endoscopy before therapeutic intervention with radiofrequency ablation.

available treatment options can range from less invasive modalities such as corticosteroids, hormonal therapy, and octreotide to more invasive procedures including laser therapy, electrocoagulation, APC, RFA, and even surgery in the most refractory cases. Endoscopic thermal therapy is currently the first-line treatment, with APC being the most favored due to its fair success rate, low complication rate, and low costs.<sup>5</sup>

## Medical treatment

### Hormonal therapy

Randomized controlled trials have demonstrated that use of estrogen alone has no benefit in the resolution of gastrointestinal bleeding.<sup>6</sup> Subsequently, Van Cutsem et al reported a randomized, crossover trial, concluding that estrogen–progesterone used together can achieve resolution of bleeding from gastrointestinal vascular abnormalities.<sup>7</sup> Tran et al reported an open pilot study of six patients with GAVE, demonstrating complete resolution of bleeding in four patients, and a decrease in the need for blood transfusions in all six patients using ethinyl estradiol 30 µg and norethisterone 1.5 mg.<sup>8</sup> Additionally, there have been isolated case reports suggesting that dual therapy with estrogen and progesterone can be effective in the treatment of GAVE.<sup>9–12</sup> Although resolution of bleeding was achieved, no endoscopic changes were noted in any patients,<sup>11,12</sup> suggesting that bleeding would reappear on discontinuing the therapy. Hormonal therapy for a prolonged period should be used with caution. In the open pilot study reported by Tran et al, menorrhagia and gynecomastia was described in three patients.<sup>8</sup> Like other pharmacological agents, hormonal therapy can be used as a substitute in patients (especially post-menopausal women) with dispersed lesions who are not suitable for endoscopic therapy or surgery.

### Corticosteroids

Corticosteroids have been used in patients not suitable for endoscopic treatment or surgery. On review of the literature, eleven patients were found who were treated with oral steroids alone. Over a 3-year period, six of these patients had stopped bleeding and were transfusion-independent. One patient developed hyperglycemia and had to be switched to an alternative agent, and the remaining four patients showed no success with steroid use and required endoscopic intervention or surgery.<sup>9,13–20</sup>

### Octreotide

Octreotide, a somatostatin analog, is another agent that has been used in patients not suitable for endoscopic

treatment or surgery. Unlike published trials on hormones, most of the data regarding octreotide as a treatment option for GAVE have come from isolated case reports or case series only. To date, there are 18 published cases of the use of octreotide.<sup>21–29</sup> The mean follow-up time in these cases was 20.1 (range: 0.1–64) months, and the doses of octreotide ranged from 100 µg subcutaneously twice daily to 500 µg subcutaneously twice daily. In these reports, it was noted that seven of the 18 patients had a significant reduction in transfusion requirements after treatment. A further nine of the 18 patients had a moderate reduction in transfusion requirements. The effect was equivocal in one patient,<sup>28</sup> and treatment completely failed in another.<sup>24</sup> Nardone et al reported a case series of 17 patients with vascular irregularities of the gastrointestinal tract refractory to endoscopic treatment. Three of the 17 patients were cirrhotics with GAVE. Resolution of bleeding was seen in one patient, and the other two patients had a decrease in transfusion requirements over a 2-year period.<sup>28</sup> The success seen in these patients with underlying cirrhosis may be due to the fact that octreotide causes a decrease in portal pressure. In addition, octreotide has a low rate of side effects. However, due to the lack of controlled trials and the small number of case reports/series, further studies are required to evaluate its usefulness in the treatment of GAVE.

### Tranexamic acid

There have been a number of cases reporting on treatment of vascular abnormalities of the gastrointestinal tract with the antifibrinolytic agent tranexamic acid. However, there are only two reports of tranexamic acid being used in the treatment of GAVE. Park et al reported on a patient with alcoholic cirrhosis and GAVE, who demonstrated a reduction in blood loss with the use of tranexamic acid.<sup>30</sup> Since then, McCormick et al have reported on a patient with cirrhosis and GAVE who required 130 units of packed red blood cell products prior to use of tranexamic acid. The bleeding did not respond to portal decompression with transjugular intrahepatic portosystemic shunt or beta-blockers. Following treatment with oral tranexamic acid, the patient did not require further blood transfusion over a follow-up period of 30 months.<sup>30</sup> Despite these promising results, controlled trials are required to establish the value of tranexamic acid in the treatment of GAVE. Further, tranexamic acid has been linked to a number of side effects, including pulmonary embolism and central venous retinopathy.<sup>31</sup>

### Other agents

A number of other agents have been studied in single case reports, including calcitonin,<sup>18</sup> cyproheptadine,<sup>32</sup> alpha-interferon,<sup>33</sup> and thalidomide.<sup>34–36</sup> Among the agents studied, cyproheptadine stood out because it resolved the gastrointestinal bleeding and caused remodeling of the gastric mucosa.<sup>32</sup>

## Endoscopic treatment

### Nd:YAG laser

The Nd:YAG laser penetrates to a depth of 5 mm, is well absorbed by tissue, and is a non-contact method.<sup>37–39</sup> Gostout et al reported a study of 45 patients treated by endoscopic Nd:YAG laser coagulation for the treatment of GAVE. Complete resolution of visible disease was noted after laser therapy (a median of one treatment, range: 1–4) in four patients (13%) and >90% resolution in 24 patients (80%). During a follow-up period of 2 years (range: 1 month to 6 years), hemoglobin levels normalized in 87% of patients, and there were no major complications reported.<sup>40</sup> Liberski et al reported a study of 15 patients who were followed for a period of 2–8 years from the time of initial diagnosis. Both endoscopic and hematological improvement was noted in this study.<sup>14</sup> Bjorkman and Buchi reported a small study comparing the use of the Nd:YAG laser with that of the argon laser. This study demonstrated that use of the Nd:YAG laser resulted in fewer sessions needed to eliminate the lesions and a lower recurrence rate when compared with the argon laser.<sup>41</sup> The Nd:YAG laser is expensive and has a lot of complications, so its use has decreased over time.

### Argon plasma coagulation

APC uses high frequency energy transmitted to tissue by ionized gas. In APC, the laser current is conducted through argon gas to the tissue from the tip of a monopolar electrode. The coagulation depth is variable (from 0.8 mm to 3.0 mm) according to the generator settings, gas flow rate, time applied, and distance from the tissue. It has frequently been used in the treatment of radiation proctopathy due to its superficial penetration. Wahab et al reported a study of 125 patients with vascular ectasias, including six with GAVE. These six patients had complete resolution of their lesions with a mean of 2.8 sessions.<sup>14</sup> There have been a number of other case series and reports supporting the use of APC as the most useful and widespread treatment modality for GAVE. APC is less expensive compared with lasers, and is more widely available.

### Bipolar electrocoagulation and heater probe

These are widely available and relatively inexpensive compared with lasers. They are contact probes and are useful for delivering focal, directed therapy to actively bleeding mucosa. Char formation at the probe tip is a complication that can sometimes be experienced. Binmoeller and Katon reported a patient with GAVE who underwent four sessions of BiCap, resulting in almost complete resolution of visible disease and no recurrence.<sup>4</sup> These treatment modalities are dependent on the energy setting (1, 3, 5, 7, and 9 watts), duration (2, 6, 10, and 14 seconds), and force applied (0, 50, and 100 g).<sup>42</sup>

### Cryotherapy

Cryotherapy is non-contact method of tissue ablation by application of extreme cold temperatures to a targeted area. It has the benefit of uniform treatment of larger surface areas and ease of targeted application. Cho et al reported a study assessing the efficacy and safety of cryotherapy in 12 patients with GAVE. Six of the 12 patients demonstrated a complete response to treatment and six demonstrated a partial response. An increased mean hemoglobin level of 9.9–11.3 g/dL was noted. Of interest, in 32 of the 36 cryotherapy sessions performed (89%), more than 90% of GAVE lesions were treated. No immediate cryotherapy-related complications were noted in this study.<sup>43</sup> One of the risks of cryotherapy is over distention perforation of the bowel.<sup>44</sup> Cryotherapy requires the use of liquid nitrogen or carbon dioxide, which is difficult to perform in smaller practices. The unit is less mobile compared to RFA, and the depth of ablation is greater, increasing the risk of bowel perforation.

### Radiofrequency ablation

RFA is a new endoscopic therapy that may be a valuable alternative in the treatment of GAVE. The HALO RFA system uses two different types of probes with a closely spaced arrangement of electrodes, which thermally ablate tissue. The depth (0.5–1 mm) is dependent on the power, density, and duration of contact. A generator connects to either a 360 degree HALO catheter or a HALO-90 catheter to provide a circumferential or more focused ablation.<sup>2</sup> Dray et al reported an open-label, retrospective, case series evaluating the effectiveness and safety of RFA for the treatment of GAVE. Twenty-four patients were enrolled in the study and underwent a mean of  $1.8 \pm 0.8$  RFA sessions. In all 23 transfusion-dependent patients, the number of red blood cell packs decreased from a mean of  $10.6 \pm 12.1$  during the 6 months prior to RFA to a mean of  $2.5 \pm 5.9$  during the 6 months after RFA. Fifteen patients were reported to have been weaned off transfusions completely.<sup>3</sup>

McGorisk et al reported an open-label prospective cohort study of patients with GAVE refractory to APC. Twenty-one patients were enrolled in the study, and underwent endoscopic RFA to the gastric antrum using the HALO-90 ultra ablation catheter until transfusion independence was achieved or a maximum of four sessions were performed. Six months after completion of RFA therapy, 18 of the 21 patients (86%) were transfusion-independent. The mean hemoglobin increased from 7.8 to 10.2 g/dL, and there were two adverse events reported (minor acute bleeding and superficial ulceration), both of which resolved without intervention.<sup>1</sup>

There are multiple advantages of using RFA with the HALO-90 ablation catheter for the treatment of GAVE. RFA covers a broader surface area compared with APC and electrocautery. Applying pressure to the probe results in some coaptive coagulation before the application of power to ablate the tissue, leading to a more superficial burn in less time. This helps shorten the treatment duration even in extensive disease. Squamous re-epithelialization, which occurs after RFA, minimizes bleeding, fibrosis, and stricture formation.<sup>45–47</sup> This is due to the superficial depth of ablation (0.5–1 mm).

These studies show that RFA could prove to be a useful method for refractory GAVE. Our experience indicates that it could even be used as the primary treatment modality for GAVE. However, it is still considered a newer method, and we need more experience and longer follow-up times before recommending it as a primary treatment.

### Surgical treatment

Surgical intervention, most commonly antrectomy, is a definitive therapy for GAVE but its use is associated with significant morbidity and mortality. Earlier reports have shown a 7.4% operative mortality.<sup>44</sup> From review of previous cases, and the newer endoscopic treatment options available, antrectomy should be restricted to those who remain refractory to medical and endoscopic treatment.

### Conclusion

RFA is an emerging technique that has been used in the treatment of Barrett's esophagus for the last few years. Recent reports of its use in GAVE have been promising, and we believe that in the future RFA may become the preferred treatment. RFA is becoming more widely available, and it is easy to perform with minimal risks. However, more reports are needed with longer follow-up before it can be routinely recommended for GAVE. Two of our patients had been treated with other endoscopic thermal therapies prior to undergoing RFA (cases 2 and 3). The third patient had



RFA as a primary treatment (case 1). All three patients have shown good results.

## Disclosure

The authors report no conflicts of interest in this work.

## References

- McGorisk T, Krishnan K, Keefer L, Komanduri S. Radiofrequency ablation for refractory gastric antral vascular ectasia (with video). *Gastrointest Endosc*. 2013;78:584–588.
- Akiyama J, Triadafilopoulos G. Endoscopic ablation therapy of Barrett's esophagus. *Minerva Gastroenterol Dietol*. 2010;56:405–420.
- Dray X, Repici A, Gonzalez P, et al. Radiofrequency ablation for the treatment of gastric antral vascular ectasia. *Endoscopy*. 2014;46:963–969.
- Sebastian S, O'Morain CA, Buckley MJ. Review article: current therapeutic options for gastric antral vascular ectasia. *Aliment Pharmacol Ther*. 2003;18:157–165.
- Shibukawa G, Irisawa A, Sakamoto N, et al. Gastric antral vascular ectasia (GAVE) associated with systemic sclerosis: relapse after endoscopic treatment by argon plasma coagulation. *Intern Med*. 2007;46:279–283.
- Vase P. Estrogen treatment of hereditary hemorrhagic telangiectasia. A double-blind controlled clinical trial. *Acta Med Scand*. 1981;209:393–396.
- Van Cutsem E, Rutgerts P, van Trappen G. Treatment of bleeding gastrointestinal vascular malformations with oestrogen progesterone. *Lancet*. 1990;335:953–955.
- Tran A, Villeneuve JP, Bilodeau M, et al. Treatment of chronic bleeding from gastric antral vascular ectasia (GAVE) with oestrogen-progesterone in cirrhotic patients: an open pilot study. *Am J Gastroenterol*. 1994;94:202–211.
- Moss SF, Ghosh P, Thomas DM, Jackson JE, Calam J. Gastric antral vascular ectasia; maintenance treatment with oestrogen-progesterone. *Gut*. 1992;33:715–717.
- Herman C, Gofin E, Harsman Y, et al. Watermelon stomach. An unusual cause of recurrent upper gastrointestinal tract bleeding in the uremic patient: efficacy of treatment with oestrogen progesterone therapy. *Nephrol Dial Transpl*. 1996;11:871–874.
- Schonbrodt N, Horsmann Y, Hoang P, et al. Vascular gastric lesions, CREST syndrome and primary biliary cirrhosis: efficacy of oestrogen progesterone treatment. *Gastroenterol Clin Biol*. 1994;18:649–651.
- Manning RJ. Oestrogen progesterone treatment of diffuse antral vascular ectasia. *Am J Gastroenterol*. 1995;90:154–156.
- Jabbari M, Cherry R, Lough JO, Daly DS, Kinnear DG, Goresky CA. Gastric antral vascular ectasia: the watermelon stomach. *Gastroenterology*. 1984;87:1165–1170.
- Liberski SM, McGarrity TJ, Hartle RJ, Varano V, Reynolds D. The watermelon stomach: long-term outcome in patients with Nd:YAG laser therapy. *Gastrointest Endosc*. 1990;36:399–402.
- Calam J, Walker RJ. Antral vascular lesion, achlorhydria and chronic gastrointestinal blood loss: response to steroids. *Digest Dis Sci*. 1980;25:236–239.
- Bowmick BK. Watermelon stomach treated with oral corticosteroid. *J R Soc Med*. 1993;86:52.
- Kruger R, Ryan ME, Dickson KB, Nunez JF. Diffuse vascular ectasia of the gastric antrum. *Am J Gastroenterol*. 1987;82:421–426.
- Kishi K, Kinoshita Y, Kitajima N, et al. Two cases of gastric antral vascular ectasia – response to medical treatment. *Gastroenterol Jpn*. 1999;26:757–762.
- Cales P, Voigt JJ, Payen JL, et al. Diffuse vascular ectasia of the antrum, duodenum and jejunum in a patient with nodular regenerative hyperplasia: lack of response to portosystemic shunt or surgery. *Gut*. 1993;34:558–561.
- Rawlinson D, Bare CD, Lin BP. Antral vascular ectasia – the watermelon stomach. *Med J Aust*. 1986;144:709–711.
- Torsoli A, Annibale B, Viscardi A, Delle Fave G. Treatment of bleeding due to diffuse angiodysplasia of the small intestine with somatostatin analogue. *Eur J Gastroenterol Hepatol*. 1991;3:785–787.
- Rossini FP, Arrigoni A, Pennazio M. Octreotide in the treatment of bleeding due to angiodysplasia of the small intestine. *Am J Gastroenterol*. 1993;88:1424–1427.
- Andersen MR, Aaseby J. Somatostatin in the treatment of gastrointestinal bleeding caused by angiodysplasia. *Scand J Gastroenterol*. 1996;31:1037–1039.
- Barbara G, De Giorgio R, Salvioli B, Stanghellini V, Corinaldesi R. Unsuccessful octreotide treatment of the watermelon stomach. *J Clin Gastroenterol*. 1998;26:345–346.
- Bowers M, McNulty O, Mayne E. Octreotide in the treatment of gastrointestinal bleeding caused by angiodysplasia in two patients with von Willebrand's disease. *Br J Haematol*. 2000;108:524–527.
- Orsi P, Guatti-Zuliani C, Okolicsanyi L. Long-acting octreotide is effective in controlling rebleeding angiodysplasia of the gastrointestinal tract. *Dig Liver Dis*. 2001;33:330–334.
- Nordquist LT, Wallach PM. Octreotide for gastrointestinal bleeding of obscure origin in an anticoagulated patient. *Dig Dis Sci*. 2002;47:1514–1515.
- Coppola A, De Stefano V, Tufano A, et al. Long-lasting intestinal bleeding in an old patient with multiple mucosal vascular abnormalities and Glanzmann's thrombasthenia: 3-year pharmacological management. *J Intern Med*. 2002;252:271–275.
- Blich M, Fruchter O, Edelstein S, Edoute Y. Somatostatin therapy ameliorates chronic and refractory gastrointestinal bleeding caused by diffuse angiodysplasia in a patient on anticoagulation therapy. *Scand J Gastroenterol*. 2003;38:801–803.
- Park RM, Danesh BJZ, Upadhyay R, et al. Gastric antral vascular ectasia (watermelon stomach) therapeutic options. *Postgrad Med J*. 1990;66:720–723.
- Woo KS, Tse LK, Woo JL, et al. Massive pulmonary embolism after tranexamic acid antifibrinolytic therapy. *Br J Clin Pract*. 1989;43:465–466.
- Pina Cabral JE, Pontes JM, Toste M, et al. Watermelon stomach: treatment with a serotonin antagonist. *Am J Gastroenterol*. 1991;86:927–928.
- Disdier P, Schleinitz N, Perreard M, et al. Dramatic improvement of watermelon stomach with alpha-interferon. *Am J Gastroenterol*. 1995;90:1009–1010.
- Perez-Encinas M, Rabunal Martinez MJ, Bello Lopez JL. Is thalidomide effective for the treatment of gastrointestinal bleeding in hereditary hemorrhagic telangiectasia? *Haematologica*. 2002;87:ELT34.
- Shurafa M, Kamboj G. Thalidomide for the treatment of bleeding angiodysplasias. *Am J Gastroenterol*. 2003;98:221–222.
- Bauditz J, Schachschal G, Wedel S, Lochs H. Thalidomide for treatment of severe intestinal bleeding. *Gut*. 2004;53:609–612.
- Swaroop VS, Gostout CJ. Endoscopic treatment of chronic radiation proctopathy. *J Clin Gastroenterol*. 1998;27:36–40.
- Wilson SA, Rex DK. Endoscopic treatment of chronic radiation proctopathy. *Curr Opin Gastroenterol*. 2006;22:536–540.
- Patel A, Pathak R, Deshpande V, Patel SH, Wickremesinghe PC, Vadada D. Radiofrequency ablation using BarRx for the endoscopic treatment of radiation proctopathy: a series of three cases. *Clin Exp Gastroenterol*. 2014;7:453–460.
- Goustout CJ, Viggiano TR, Ahlquist DA, Wang KK, Larson MV, Balm R. The clinical and endoscopic spectrum of the watermelon stomach. *J Clin Gastroenterol*. 1992;15:256–263.
- Bjorkman DJ, Buchi KN. Endoscopic laser therapy of the watermelon stomach. *Laser Surg Med*. 1992;12:478–481.
- Laine L. Determination of the optimal technique for bipolar electrocoagulation treatment. An experimental evaluation of the BICAP and gold probes. *Gastroenterology*. 1991;100:107–112.

43. Cho S, Zanati S, Yong E, et al. Endoscopic cryotherapy for the management of gastric antral vascular ectasia. *Gastrointest Endosc.* 2008;68: 895–902.
44. Hou JK, Abudayyeh S, Shaib Y. Treatment of chronic radiation proctitis with cryoablation. *Gastrointest Endosc.* 2011;73:383–389.
45. Sharma VK, Wang KK, Overholt BF, et al. Balloon-based, circumferential, endoscopic radiofrequency ablation of Barrett's esophagus: 1-year follow-up of 100 patients. *Gastrointest Endosc.* 2007;65:185–195.
46. Ganz RA, Utley DS, Stern RA, Jackson J, Batts KP, Termin P. Complete ablation of esophageal epithelium with a balloon-based bipolar electrode: a phased evaluation in the porcine and in the human esophagus. *Gastrointest Endosc.* 2004;60:1002–1010.
47. Dunkin BJ, Martinez J, Bejarano PA, et al. Thin-layer ablation of human esophageal epithelium using a bipolar radiofrequency balloon device. *Surg Endosc.* 2006;20:125–130.

### Clinical and Experimental Gastroenterology

Dovepress

### Publish your work in this journal

Clinical and Experimental Gastroenterology is an international, peer-reviewed, open access journal, publishing all aspects of gastroenterology in the clinic and laboratory, including: Pathology, pathophysiology of gastrointestinal disease; Investigation and treatment of gastrointestinal disease; Pharmacology of drugs used in the alimentary tract;

Immunology/genetics/genomics related to gastrointestinal disease. This journal is indexed on CAS. The manuscript management system is completely online and includes a very quick and fair peer-review system. Visit <http://www.dovepress.com/testimonials.php> to read real quotes from published authors.

Submit your manuscript here: <http://www.dovepress.com/clinical-and-experimental-gastroenterology-journal>