

Ganglion blocks as a treatment of pain: current perspectives

Osman Hakan Gunduz
Ozge Kenis-Coskun

Department of Physical Medicine and
Rehabilitation, Faculty of Medicine,
Marmara University, Istanbul, Turkey

Abstract: The inputs from sympathetic ganglia have been known to be involved in the pathophysiology of various painful conditions such as complex regional pain syndrome, cancer pain of different origin, and coccygodynia. Sympathetic ganglia blocks are used to relieve patients who suffer from these conditions for over a century. Many numbers of local anesthetics such as bupivacaine or neurolytic agents such as alcohol can be chosen for a successful block. The agent is selected according to its duration of effect and the purpose of the injection. Most commonly used sympathetic blocks are stellate ganglion block, lumbar sympathetic block, celiac plexus block, superior hypogastric block, and ganglion Impar block. In this review, indications, methods, effectiveness, and complications of these blocks are discussed based on the data from the current literature.

Keywords: cancer pain, complex regional pain syndrome, ganglion, pain management, sympathetic nervous system

Introduction

Blocking sympathetic ganglia is a century-old method, which has been performed since World War I for pain relief. The inputs from sympathetic ganglia have been known to be involved in the pathophysiology of various conditions like complex regional pain syndrome (CRPS).¹ One of the suggested mechanisms is the loss of regular inhibitory influence on pain. Adrenergic hypersensitivity is also thought to play a part in symptoms.² The effect of sympathetic blocks in these conditions usually outlasts the original effectiveness duration of the agents that are applied. This suggests that blocking of the sympathetic neurons interrupts the positive feedback circuit and decreases the central hyperexcitability.³ Due to their effectiveness and their capability to alter the inputs from the peripheral nervous system to the central nervous system, sympathetic blocks have been more commonly used in a variety of painful conditions like postherpetic neuralgia and some non-painful ones like posttraumatic stress disorder (PTSD) and hyperhidrosis.

In this review, the most common sympathetic blocks that are currently used in medical practice are described. The current literature at hand is also examined to give a more detailed picture of the effectiveness of sympathetic blocks in pain management. This review aims to familiarize the medical professionals who are new to the field of interventional pain medicine or to these procedures and provide a comprehensive starting point for them.

Stellate ganglion block (SGB)

Stellate ganglion, also known as the cervicothoracic ganglion, is part of the cervical sympathetic chain, formed by the fusion of inferior cervical ganglion with the first

Correspondence: Ozge Kenis-Coskun
Department of Physical Medicine and
Rehabilitation, Faculty of Medicine,
Marmara University, Fevzi Çakmak
Mahallesi, Muhsin Yazıcıoğlu Caddesi,
No:10, Üst Kaynarca, Pendik, 34899
Istanbul, Turkey
Tel +90 50 5829 4947
Email ozgekenis@gmail.com

thoracic sympathetic ganglion. It is located as follows: medial to the scalene muscles; lateral to the longus colli muscle, esophagus, and trachea, along with the recurrent laryngeal nerve in between; anterior to the transverse processes; superior to the subclavian artery and the posterior aspect of the pleura; and posterior to the vertebral vessels at the C7 level.⁴ Stellate ganglion provides sympathetic input to the ipsilateral upper extremity, chest, face, and head.

Traditionally, SGB can be applied without any imaging, by palpating the anterior transverse process of C6, or the Chassaignac tubercle, and injecting the local anesthetic (LA) immediately medially.⁵ As the imaging techniques improved in the last century, SGBs have started to be done with imaging guidance (Figure 1A and B). Since the 1980s, computed tomography (CT) is being used.⁶ In the middle of 1990s, ultrasound (US) guidance has also become widely preferable.⁷ Many numbers of LAs (e.g., bupivacaine) and neurolytic agents (e.g., alcohol) can be chosen for block according to their duration of effect and the purpose of the injection. A block is considered successful by the development of Horner's syndrome, increase in skin temperature, increase in blood flow, and loss of the galvanic skin response.

SGB is the oldest and most common sympathetic block that is applied today. Its indications vary from CRPS types 1 and 2, postherpetic neuralgia (PHN), intractable angina^{8–10} to PTSD, hyperhidrosis, arrhythmias, and hot flushes.^{11–13} The scope of this review is limited to the efficacy of SGB in painful conditions.

The most common indication of SGB is the CRPS of the upper extremity. Even though SGB has been used for CRPS since the 1950s,¹⁴ the literature mostly consisted of case reports of mixed patient groups who did not undergo

the same procedure up until the last two decades. From the beginning of the 2000s, the evidence for the effectiveness of SGB for CRPS has somewhat increased.

One of the first studies that included patients who had undergone only SGBs was by Rodríguez et al in 2005. A total of 82 patients were divided into two groups. One group received physical and pharmacological therapy, while the other group underwent SGB. After a two-month follow-up, 46% of patients in the SGB group had 50% decrease in pain.¹⁵ Other studies in the literature focus on the duration of symptoms as a factor for the effectiveness of SGB. One study done by Ackerman et al in 2006 included 25 patients who had CRPS type 1 which developed after carpal tunnel surgery. All the subjects received three consecutive weekly injections of 5 mL of 0.5% lidocaine under fluoroscopic guidance for SGB. After the injections, 10 of the patients had complete, nine had partial, and six had no pain relief. Patients who had complete pain relief had significantly shorter disease duration, and better depression and neuropathic pain scores after the injections.¹⁶ Another study, done by Yucel et al, also compared the effectiveness of SGB in patients with symptoms shorter and longer than 28 weeks. An injection composed of equal parts of 0.5% bupivacaine (5 mg/mL) and 1% prilocaine hydrochloride (20 mg/mL) was applied weekly for consecutive three weeks. All the patients included had significant pain relief and improvement in range of motion. In addition, patients who had shorter disease periods had a significantly better outcome.¹⁷ Both studies show that a shorter time of symptom onset to treatment increases the success of SGBs.

In 2010, Nascimento et al compared the effectiveness of SGB with the continuous intravenous sympathetic block.

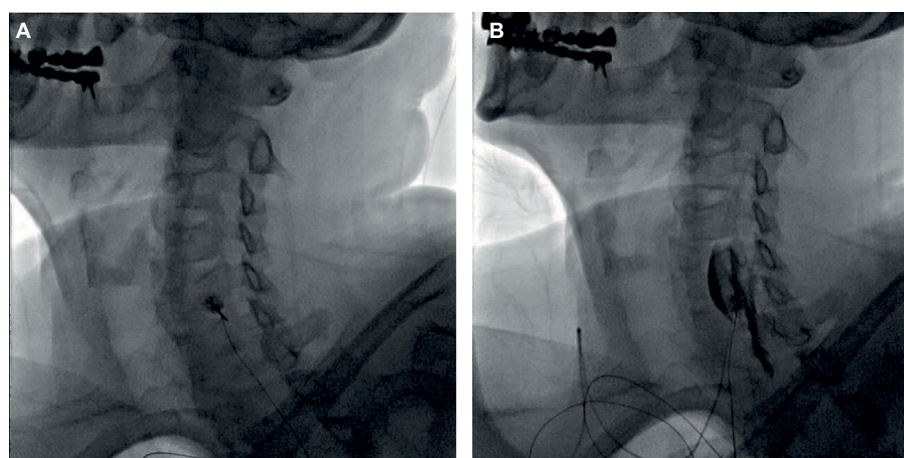


Figure 1 Fluoroscopic view of stellate ganglion block before and after the administration of contrast agent.

Forty-five patients with CRPS type 1 were divided into three groups: the first group underwent SGB with an injection of 7 mL of 70 mg of 1% lidocaine, the second group underwent SGB with an injection of 7 mL of 70 mg of 1% lidocaine combined with 30 µg of clonidine, and the third group received a continuous intravenous block of 7 mL of 70 mg of 1% of lidocaine and 30 µg of clonidine. All three groups received four consecutive weekly injections. All groups had a significant decrease in pain, but there were no significant differences between groups.¹⁸ There are two critical points in this study: first, the amount of lidocaine used in the injections is higher than usual, which has contributed to immediate pain relief in patients who underwent SGB. Second, a fourth injection was applied to the patients, but this additional injection does not seem to improve pain scores.

Yoo et al investigated the effectiveness of US-guided SGB when compared to blind injections in 2012. For this study, 42 patients with poststroke CRPS were recruited. Each group was injected with 5 mL of 0.5% lidocaine weekly for two weeks. Pain decrease was significant in both groups, and it was significantly better in the US-guided group.¹⁹ A retrospective case series reports that US-guided SGB is useful when combined with occupational and pharmacological therapy. However, since this study did not have a control group, it cannot be concluded that SGB is more efficient than other approaches for CRPS.²⁰

SGB can also be used for decreasing the incidence of other painful conditions like PHN. Lipton et al did one of the first studies in patients with herpes zoster in 1987. They included 30 patients within two weeks of the onset of the rash, who were over the age of 60 years. The intervention group underwent SGB with 10 mL of a mixture of equal part of 1% lidocaine and 0.5% bupivacaine, while the control group received oral acyclovir and prednisolone. There were no significant differences in the incidence of PHN during follow-up.²¹ In 1999, Lee et al did a similarly designed study to compare the effects of SGB with 0.8% mepivacaine with a standard therapy of acyclovir and analgesics. They also found no significant difference in the incidence of PHN but a decreased level of pain in the SGB group.²² Makharita et al reported in 2012 that SGB using 6 mL of 0.125% bupivacaine and 8 mg dexamethasone in a total volume of 8 mL significantly decreased pain levels in patients with herpes zoster and showed that significant pain reduction lasts up until six months, reducing the incidence of PHN.⁹ This is the only study that has included steroids in SGB, which may have changed the outcome drastically. However, concurring with a recent review on this subject, there is not enough

evidence to declare the effectiveness of SGB in decreasing the incidence of PHN.²³

To sum it up, SGB is effective in reducing pain in patients with CRPS that involves upper extremity, and it is promising in the treatment of PHN. However, larger, controlled studies are needed to establish its efficacy further. There is a broad range of case studies that report the effectiveness of SGB in many different conditions. The outcomes may look promising, but expanding the indications of SGB needs more randomized, controlled studies.

Lumbar sympathetic block (LSB)

The lumbar sympathetic ganglia are an anatomical structure located anterolateral to the lumbar vertebral bodies. The lumbar sympathetic ganglia can be blocked via neurolytic agents, LAs, or other means like radiofrequency ablation. They are commonly blocked at the lumbar vertebral levels of L2–L4 usually with fluoroscopic guidance (Figure 2), while a single injection of 20–25 mL of injectate has also been shown to be effective in the adequate spread of the medication when applied at the L3 level.²⁴ However, a multilevel approach seems to be more efficient when compared to a single-needle method.²⁵

US, CT, and magnetic resonance (MR) have also been used for guidance in LSBs.^{26–28} Currently, similar to other sympathetic blocks, there is no standard to perform the technique or pharmaceutical guidance of suitable injectate mixtures.²⁹ LSB is indicated for diagnosis, prognosis, and therapy of painful and other conditions associated with sympathetic dysfunctions like CRPS types 1 and 2, herpes zoster, amputation stump pain, and inoperable peripheral vascular vasospastic diseases of the lower limb.³⁰

Most recent studies included patients with lower-extremity CRPS. One of the first studies on LSB was done by Price et al in 1999, which aimed to define the diagnostic and therapeutic value of LA sympathetic blocks. Their study included three lower-extremity CRPS cases. They applied two LSB injections, one of a saline placebo and another that contained 10 mL of 0.25% bupivacaine solution. Every patient was his own control. The main findings of this study were that peak analgesic effects from both saline and LA block of sympathetic ganglia were substantial and not statistically different, whereas the duration of analgesia was much longer in the case of LA. The researchers continued and included 41 other patients with CRPS, but all with upper-extremity involvement.³¹ In 2008, Manjunath et al conducted a pilot study comparing the effect of percutaneous radiofrequency thermal lumbar sympathectomy and lumbar sympathetic

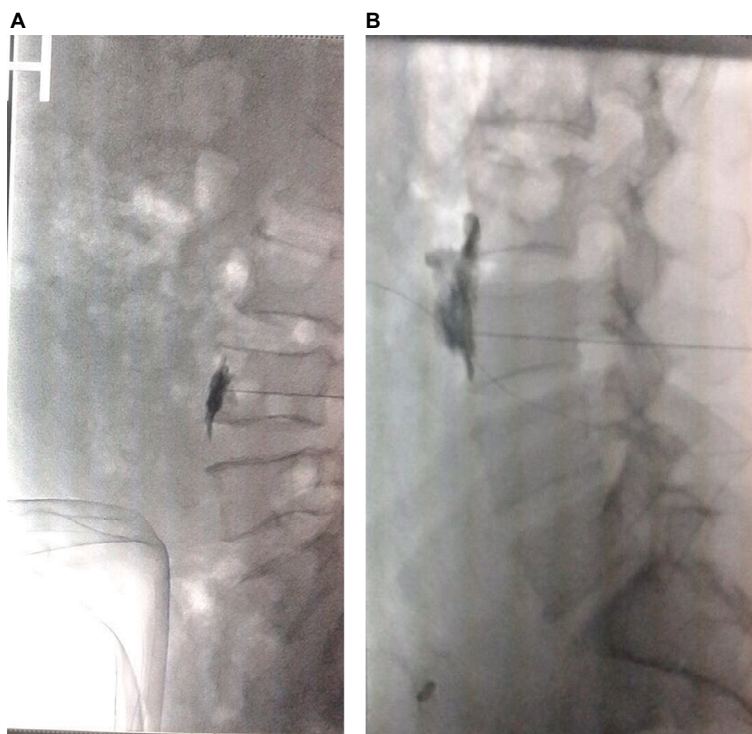


Figure 2 Fluoroscopic view of lumbar sympathetic block right after the injection of the contrast (**A**) and the dissemination of contrast material (**B**).

neurolysis in patients with lower-extremity CRPS type 1. Twenty patients were included. Ten patients underwent percutaneous radiofrequency lumbar sympathectomy, and ten patients underwent lumbar sympathetic neurolysis with phenol 7%. Within each group, there were statistically significant reductions from baseline in various pain scores after the procedure. However, there was no statistically significant difference in mean pain scores between the groups.³² In 2009, Carroll et al conducted another study to find out if using botulinum toxin (BTX) as an injectate would increase the duration of analgesia in lower-extremity CRPS cases who receive LSB. They included ten patients. All the patients received one injection of 10 mL of 0.5% bupivacaine, and another crossover injection of 10 mL of 0.5% bupivacaine with an added 75 units of BTX-A. Median time to analgesic failure was significantly longer in patients who received LSB with BTX. Moreover, BTX was more effective in decreasing pain levels in these patients.³³ Meier et al have investigated the effects of LSB in pediatric patients with CRPS types 1 and 2. They conducted a double-blind, placebo-controlled study including 23 patients between the ages of 10 and 18. Control group received intravenous lidocaine and lumbar sympathetic saline, while treatment group received lumbar sympathetic lidocaine and intravenous saline. Lumbar sympathetic blockade produced a significant decrease in pain intensity compared to pretreatment values of allodynia

and verbal pain scores, while intravenous lidocaine failed to provide a significant reduction.³⁴ Freitas et al have compared the results of pulsed radiofrequency with sympathetic block via the injection of 15 mL of 2% lidocaine plus 100 µg of clonidine. Both interventions significantly decreased pain scores and were not significantly different from each other. Pulsed radiofrequency seemed only superior in reducing burning pain scores when the patients' pain was evaluated.³⁵

Overall, it can be concluded that LSBs are an efficient way to deal with sympathetic pain, especially in patients with CRPS. Even though there are other indications to perform LSBs, the majority of the controlled studies in the literature involve CRPS cases. The literature about other applications of LSB merely consists of case reports. New studies involving other indications would be of value in this regard. However, it is clear that the cases that require LSBs are relatively rare, which may be a limiting factor in conducting major controlled studies.

Celiac plexus block (CPB) and splanchnic plexus block

The celiac plexus lies anterior to the aorta and epigastrium. The plexus extends for several centimeters in front of the aorta and laterally around the aorta. Fibers within the plexus arise from preganglionic splanchnic nerves, parasympathetic preganglionic nerves from the vagus, some sensory nerves

from the phrenic and vagus nerves, and sympathetic post-ganglionic fibers. Afferent fibers concerned with nociception pass diffusely through the celiac plexus and represent the primary target of celiac plexus blockade.³⁶

There are two main approaches to apply the CPB: anterior and posterior approach. In the anterior approach, a needle is inserted through the anterior abdominal wall directly into the region of the celiac plexus and a neurolytic agent is injected into the antecrural space. One of the classic posterior approaches is the fluoroscopy-guided two-needle retrocrural approach. In this approach, the patient is placed in prone position with a pillow under the abdomen to flex the thoracolumbar spine. The T12 vertebral body and the spinous process of the L1 vertebral body are then identified with fluoroscopy. Two 20-G needles are inserted bilaterally, oriented 45° toward the midline and about 20° cephalad. They are advanced under fluoroscopic guidance to ensure contact with the inferolateral portion of the T12 vertebral body. Ultimately, the tips of the needles should be just anterior to the lateral border of the vertebral body and just behind the aorta and vena cava in the retrocrural space. On the fluoroscopic anteroposterior view, contrast should be confined to the midline and concentrated near the T12 vertebral body. The smooth posterior border of psoas fascia should be observed on the lateral view.³⁷ In the posterior transcrural approach, a needle is inserted under C-arm or CT guidance caudal to 12th rib and cephalad to the transverse process of L1 toward the anterolateral surface of L1 corpus on the left side. Continuous aspiration is applied as the needle might penetrate aorta. If blood is aspirated, then the needle must be further moved anteriorly so that the anterior wall of aorta should be passed. Contrast distribution should be on both sides of midline over the anterior surface of the aorta for a successful CPB.³⁸ Although anterior approach necessitates traversing abdominal structures such as intestines and liver, this is ordinarily inconsequential, well tolerated, and quicker.³⁹ The advantages of performing an anterior CPB are the ability to perform the procedure while the patient is supine, only one needle is used decreasing the discomfort, and reduced risk of accidental neurologic injury related to the retrocrural spread of drug to somatic nerve roots or epidural and subarachnoid spaces.³⁶ CT, US, and fluoroscopy can all be used for guidance, while CT is the preferred option when available.⁴⁰ Recently, endoscopic ultrasound (EUS) has become a preferred approach since it defines the plexus and adjacent structures in detail.⁴¹

The primary indication of CPB is intractable abdominal pain, mainly in the cases of chronic pancreatitis or malignancies of abdominal origin, particularly pancreatic cancer.^{42,43}

For a successful block, 30–60 mL of a neurolytic agent, commonly alcohol, is injected into the antecrural space.⁴⁴

Primary indications of CPB are alleviation of visceral pain and decreasing opioid consumption in patients with upper abdominal cancers, mainly pancreatic cancer, and chronic pancreatitis. Ischia et al did one of the first modern studies on the subject in 1992 showing that patients with pancreatic cancer benefit from the procedure, with 29 of the 61 patients experiencing complete pain relief. The remaining 32 patients had partial pain relief.⁴⁵ One of the first studies to show that CPB decreases opioid consumption, albeit for a brief period, in pancreatic cancer patients was done by Mercadante in 1993.⁴⁶ Polati et al have shown this decline in opioid use again in a study involving 24 patients.⁴⁷ However, Lillemo et al did the first randomized controlled study in 1993. A total of 137 patients with unresectable pancreatic adenocarcinoma were included in the study. Chemical splanchnicectomy with 50% alcohol was performed in 65 patients, whereas 72 patients received the placebo with saline injections intraoperatively to each side of the aorta via a 20- or 22-G spinal needle. Mean pain scores were significantly lower in the alcohol group at two-, four-, and six-month follow-up and at the final assessment before their deaths. In addition, only 46% of patients who underwent the CPB required more than 10 mg of morphine which was significantly lower than the control group.⁴⁸ In 2006, Wong et al did the first extensive, prospective, randomized, controlled, double-blind evaluation of the analgesia of CPB in patients with pancreatic cancer. Their study included 101 patients who received systemic analgesic treatment. One group received CPB with 10 mL of absolute alcohol, while the sham group only received intramuscular and subcutaneous injections. The results showed that pain intensity was significantly less in the first week after the injection when compared to the control group, and continued to be less in the treatment group every week during the 24-week follow-up period. However, the consumption and side effects of opioids did not differ between the two groups.⁴⁹ Zhong et al investigated the effectiveness of CT-guided CPB in a controlled study in 56 patients with pancreatic cancer. The patients either received CPB while using oral controlled-release morphine when needed or were under oral controlled-release morphine therapy alone. The visual analog scale (VAS) scores were significantly lower on days 1, 7, and 14 compared to controls, while this difference disappeared on days 30 and 90. However, opioid consumption remained significantly low throughout the study.⁵⁰ In 2013, Amr and Makharita investigated the effectiveness of two different procedures that involve CPB. They designed

a study to include 60 patients divided into two groups. One group underwent CPB early after the first meeting and then received analgesic treatment. The second group of patients received CPB only when they reported a VAS score less than 40. During the one-year research period, all 60 patients underwent CPB. Patients were followed weekly in the first month, monthly for six months, and finally in the ninth and 12th months. There was a significant decrease in VAS scores in the second group when compared with the first group at two months after the procedure. Opioid consumption and frequency of opioid adverse effects were significantly lower in the second group during this period as well. This study has documented that controlling pain with analgesic treatment before performing a CPB is a more useful option.⁵¹

More recent studies are focusing mainly on CPB guided by EUS. The advantages of the EUS approach are the fine orientation of the needle above or lateral to the celiac trunk and the real-time performance of the procedure, under Doppler control of vessel interposition. Besides, the technique can be done in the same session of staging or sampling of an inoperable pancreatic tumor.⁵² In a meta-analysis published in 2008, EUS-guided CPB showed a pain relief of 80.12% in pancreatic cancer patients.⁵³ In 2011, Wyse et al conducted a double-blind, randomized, controlled study to demonstrate early EUS-CPB would reduce pain and morphine consumption in patients with unresectable pancreatic cancer. A total of 96 patients were divided into two groups, one group receiving bilateral injections around the celiac axis with a total of 10 mL of 0.5% bupivacaine and 20 mL of absolute alcohol as previously described with EUS guidance. It has not been made clear what kind of pain treatment the control group was taking. Patients were followed for three months. Pain relief was higher in the EUS-CPB group at one month and significantly higher at three months, while opioid consumption was not significantly different between the groups.⁵⁵

Splanchnic plexus neurolysis (SPN) can also be applied in patients with upper gastrointestinal cancers. Thoracic splanchnic plexus is made up of paired nerves that arise from thoracic sympathetic trunk and pass the diaphragm to join celiac plexus. It can be blocked with fluoroscopy or CT guidance. The patient is placed prone, T12 vertebra is localized, and two 22-G needles are directed bilaterally to the anterolateral portion of T12 to reach the splanchnic plexus. After the confirmation of needle placement, diagnostic block is applied with bupivacaine, and if successful, neurolysis is achieved with the injection of 50% of alcohol. The technique for splanchnic nerve block is quite similar to the classic retrocural approach to CPB except that the needles

are aimed more cephalad so that they are at the anterolateral margin of the T12 vertebral body. Both needles should be placed medially against the vertebral body to ensure avoiding pneumothorax.³⁷ It can especially be chosen when the anatomy of celiac plexus is altered due to the enlargement of the lymph nodes. Recent studies show that in patients with upper abdominal cancers, SPN can be as efficient as CPB. In their study, Shwita et al⁵⁴ have compared the efficacy of SPN versus CPN in 79 patients with inoperable gastrointestinal tumors. Both patient groups had significant improvements in pain, while SPN group had better social and cognitive improvement during the six-month follow-up.

The effectiveness of CPB in chronic pancreatitis is somewhat less established. The number and extent of the studies are inadequate in chronic pancreatitis. In 1999, Gress et al have compared the results of CT-guided and EUS-guided CPB in patients with chronic pancreatitis. They included a total of 18 patients. Persistent pain relief was experienced by 40% of patients at eight weeks and by 30% at 24 weeks in EUS group, while in CT group only 25% of the patients had pain relief.⁵⁶ The same research group also reported their experiences with EUS-guided blocks in 2001. A significant improvement in overall pain scores was reported in 55% of 90 patients. In 26% of patients, there was a persistent benefit beyond 12 weeks, and 10% still had a continuing benefit at 24 weeks of follow-up. They also found out that patients younger than 45 years of age and those who had underwent previous pancreatic surgery for chronic pancreatitis were unlikely to respond to the EUS-guided celiac block.⁵⁷ In 2009, LeBlanc et al compared the effectiveness of one versus two injections of CPB with EUS guidance in patients with chronic pancreatitis. Twenty-three patients received one injection, and 27 received two injections. Thirty-one of the total of 50 patients responded to injections. The duration and the onset of pain relief did not differ in subjects when the same total amount of medication was delivered in one or two injections during a single EUS-CPB procedure. Both methods were shown to be safe.⁵⁸ Santosh et al compared the effectiveness of fluoroscopy-guided CPB with EUS-guided CPB in chronic pancreatitis patients in 2009. They included 50 patients, and improvement in pain scores was seen in 70% of subjects undergoing EUS-CPB while this rate was 30% in the other group, which was significantly different.⁵⁹ In 2015, Sey et al published their results of a prospectively maintained EUS database to identify patients who had undergone more than one EUS-CPB procedure over a 17-year period. Their report included a total of 248 patients who underwent a mean number of 3.1 CPB injections. In 76% of the patients with

chronic pancreatitis, the median duration of the response to the first EUS-CPB procedure was ten weeks. Lack of pain relief after the initial EUS-CPB was associated with failure of the next procedure. Older age at first injection and relief after the first procedure were significantly associated with pain relief after subsequent blocks.⁶⁰

Complications of CPB differ from approach to approach, while it is deemed relatively safer under CT guidance⁴⁴ and EUS guidance⁶¹ when compared to a blind approach. Majority of the reported complications are transient and minor, with back pain being the most common one followed by orthostatic hypotension and transient diarrhea. Other severe complications of CPB include neurologic injuries such as monoplegia and anal and bladder sphincter dysfunction, pneumothorax, arterial injury, local hematoma, pleuritis, transient hematuria, pericarditis, intervertebral disk injury, and retroperitoneal abscess.^{44,61} There are several reports of spinal cord injury after CPB, even with EUS guidance. It is thought to be a result of the spinal cord ischemia due to the embolic occlusion of Adamkiewicz artery or vasospasm in radicular arteries. This is a rare but a severe complication and an important limiting factor of utilizing CPB in patients with benign pathologies.^{62,63} Sympathetic blocks are claimed to be safe, because neurologic complications are unlikely, different from neurolytic somatic blocks. However, no study assessed complications as a primary outcome. Given that severe complications are rare, it is assumed that some hundreds of patients should be recruited to determine the real complication rate and severity.⁶⁴

In summary, CPB can be considered as an effective method for decreasing pain intensity and the need for opioids in patients with upper abdominal cancers. A previous systematic review and meta-analysis by Nagels et al has also confirmed this, while the effect of CPB on quality of life is less established. They also showed that EUS-CPB is effective in reducing pain, while the evidence for EUS approach was not abundant at the time of the review. Both this meta-analysis and our review show that CPB is a relatively safe method for pain reduction in these patients.⁶⁵ However, serious complications can occur which must be kept in mind when applying the procedure.

Superior hypogastric block (SHB)

The superior hypogastric plexus is situated in the retroperitoneum, bilaterally extending from the lower third of the fifth lumbar vertebral body to the upper third of the first sacral vertebral body. It is an extension of the aortic plexus below the aortic bifurcation and contains sympathetic fibers and

visceral afferents. Afferent pain fibers innervating pelvic organs travel with sympathetic nerves that originate from superior hypogastric plexus. Therefore, the sympathetic chain can be interrupted at this level to treat pelvic cancer pain.⁶⁶ This can be applied in treatment of chronic pain that occurs due to diseases like endometriosis, chronic benign pelvic pain, and proctalgia fugax, but the literature about these conditions are mainly on a case report level.⁶⁷

Superior hypogastric plexus can be blocked by the traditional two-needle method, or newer single-needle approaches can also be implemented. Single-needle method can even be performed transdiscally. All these approaches aim to reach the anterior-lateral aspect of the L5 vertebra. In traditional approaches, patients lie prone with a pillow underneath their abdomen to decrease the lumbar lordosis, therefore making L4–L5 interdiscal space parallel. A 15-G needle is then inserted anteromedially, at angles differing from 30 to 45° to avoid transverse processes of L5 vertebra. This process can be done under fluoroscopy or CT guidance.^{67,68} The injectate usually contains pure alcohol to achieve a successful nerve block.

Plancarte et al described this technique in the literature and did the earliest work on its efficacy in 1990.⁶⁸ They defined and implemented a double-needle, fluoroscopy-guided approach in 28 patients with pelvic cancer pain. They used 6–8 mL of phenol to achieve nerve block. They reached a pain reduction of 70% with the injection alone. When combined with oral analgesic, this rate rose to 90%. In 1993, de Leon-Casasola et al reported their results with this traditional method in 26 patients with pelvic cancer pain.⁶⁹ Eighteen patients had satisfactory pain relief, while eight patients had moderate pain relief. In 1997, Plancarte et al documented their results in a more extensive series of 159 patients with pelvic cancer pain. They achieved a satisfactory pain relief in 72% of the patients, while the remaining patients had a moderate pain relief. In all the patients, opioid need had also significantly decreased.⁷⁰ Soon after Plancarte et al, Waldman et al described the single-needle, CT-guided posterior approach.⁶⁷ The safety and efficacy of a CT-guided anterior block were described in a series of ten patients in 2002 by Cariati et al.⁷¹ Ghoneim and Mansour had designed a study to compare the effectiveness of anterior CT-guided approach to the traditional posterior approach. They included 30 patients with pelvic cancer pain randomized into two groups. VAS scores and opioid consumption decreased significantly in both groups after the block with no significant differences between both groups. The duration of the procedure was significantly shorter in CT-guided group.⁷²

In 2005, the transdiscal approach was described by Turker et al. It was shown to be safe and efficient in their series of three patients.⁷³ Gamal et al compared the effectiveness of this transdiscal approach with the classic posterior approach in 30 patients in 2006. They showed that the duration of the procedure was significantly shorter in the transdiscal approach, while pain relief and opioid consumption did not show significant differences between two groups.⁷⁴ Even a US-guided approach had been described in 2008 by Mishra et al.⁷⁵ The same group has compared the effectiveness of this method against oral therapy and showed that US-guided SHB is significantly better than oral therapy alone. They included a total of 50 patients with gynecological malignancies, 25 of which underwent anterior US-guided SHB with 10 mL of solution containing 50% ethanol in 0.25% bupivacaine. This study showed that this technique resulted in a significant decrease in VAS score and morphine consumption when compared to the control group. To this day, this is the only controlled study on the effectiveness of US-guided SHB.⁷⁶ Gofeld and Lee have recently done a cadaveric study to determine the feasibility of a US-guided approach and reported that it could be as effective as the traditional approach in a clinical setting.⁷⁷

In summary, there are many safe and efficient ways to block the superior hypogastric plexus. There have been considerable efforts and steps taken in the last 30 years to expand our data about the effectiveness of the SHB. However, one cannot ignore the need for larger series with prospective, randomized, controlled designs to solidify our knowledge on this subject.

Ganglion Impar block (GIB)

The ganglion Impar (also known as the ganglion of Walther) is found on the ventral surface of the coccyx where it forms the caudal origin of the bilateral sympathetic chain. It can be found anterior to the sacrococcygeal joint, the coccyx,

or to the tip of the coccyx.⁷⁸ The ganglion is said to supply nociceptive and sympathetic fibers to the perineum, distal rectum, perianal region, distal urethra, vulva/scrotum, and the distal third of the vagina. It also supplies sympathetic innervation to the pelvic viscera.⁷⁹

GIB has first been described by Plancarte et al in 1990, initially to treat sympathetic pain of malignant origin.^{79,80} Since then, it has also been used to alleviate other, benign causes of intractable perineal pain and coccygodynia. The nature and extent of the innervation patterns of ganglion Impar are still not defined.

The first described approach to reach ganglion Impar was through anococcygeal ligament until the needle reaches the anterior of the sacrococcygeal joint.⁸⁰ Next, the trans-sacrococcygeal approach was defined, since it required less expertise and provided a shorter needle path and a more direct approach.⁸¹ Other intercoccygeal joint approaches have also been described in the literature.⁸² In some patients, sacrococcygeal joint or intercoccygeal joints can be fused, preventing a direct approach. For those cases, paracoccygeal approaches are defined and can be used to reach the ganglion.⁸³ Fluoroscopy is mainly used for imaging guidance (Figure 3Aa and B), but recently CT and ultrasonographic guidance has also been defined.^{84,85} A feasibility study of MR imaging guidance has also shown it to be accurate and safe.⁸⁶

Especially before the 2000s, the literature about GIBs mainly composed of description of various techniques and case reports. There are several recent patient series that evaluate the effectiveness, and there is a certain lack of randomized controlled trials. Reig et al reported one of the first patient series in 2005. Their study included 13 patients with chronic perineal, non-cancer-related pain who underwent a fluoroscopy-guided, two-needle thermocoagulation of the ganglion Impar. The patients were followed for a maximum of six months. After therapy, the pain scores decreased by an average of 50% in the whole group.⁸⁷ In 2007, Toshniwal et al

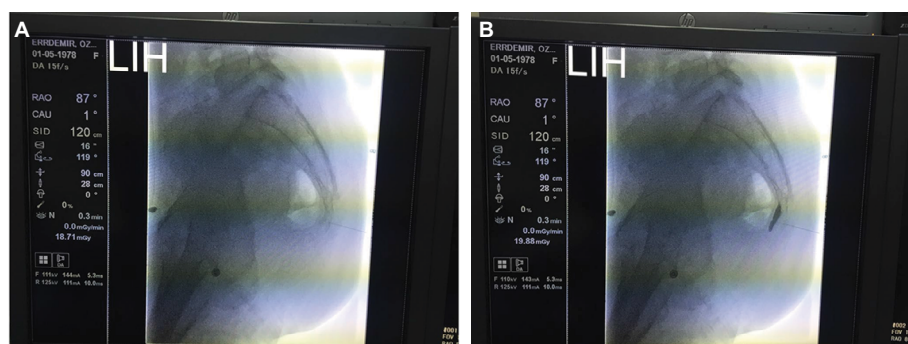


Figure 3 Fluoroscopic view of ganglion impar block before (A) and after (B) the administration of contrast agent.

reported their results of a prospective observational study, which included 16 patients with chronic perineal pain of both malignant and benign origin. They applied the transsacroccygeal approach under fluoroscopic guidance and achieved a significant pain reduction during the two-month follow-up period.⁸⁸ Agarwal-Kozlowski et al have reported their results of CT-guided lateral approach in 43 patients with perineal pain of both malignant and benign origins. They performed a total of 76 blocks, 48 of them being diagnostic blocks and 28 neuroablations. Nineteen patients had sufficient pain relief with LA injection only and did not require neuroablation, while 24 patients required neuroablation. Pain reduction was significant both at the time of discharge and after four months of follow-up period.⁸⁹ Datir and Connell have reported their results of a series of eight patients who underwent CT-guided GIB. Three patients had complete relief of pain during the follow-up intervals up to six months. Three patients had partial relief of symptoms, and a second repeat injection was given at the three-month interval of the follow-up period. At the end of the six-month follow-up period, six out of eight patients experienced symptomatic relief.⁸⁵ Demircay et al have reported the results of their retrospective analysis of 10 patients with coccygodynia, who underwent radiofrequency ablation of the ganglion Impar. Six months after the procedure, nine patients considered having a successful outcome.⁹⁰ A similar retrospective analysis of 20 patients with chronic coccygodynia that does not respond to medical treatment, who received radiofrequency ablation, has shown that the procedure was successful in 75% of the patients in their 12 months of follow-up period.⁹¹ In 2015, Gunduz et al reported their results in a series of 22 patients with coccygodynia, who underwent a total of 34 injections of LAs and corticosteroids to ganglion Impar with a fluoroscopy-guided transsacroccygeal approach. For achieving at least 50% relief of pain, the success rate of a first injection was 82% but accounted for three technical failures. In patients with a successful outcome, relief lasted for a median duration of six months. Relief was reinstated for a median period of 17 months by a second injection in nine patients who presented for repeat treatment. No relief was achieved in two of these patients when they presented for a third injection.⁹² Adas et al have most recently shown the effectiveness of radiofrequency ablation of ganglion Impar in a series of 41 patients with coccygodynia. The examinations carried out in the sixth month of the treatment showed that 37 patients had a successful outcome, whereas treatment failed in four of the patients.⁹³

The complications of GIB are rarely reported but can include motor, sexual, bladder, and bowel dysfunction,

perforation of rectum and sciatic nerve impingement, and to a rarer extent, infection.⁹⁴ Overall, it is considered a safe and effective technique in perineal and coccyx pain.

Overall, GIB seems useful in the treatment of intractable coccyx and perineal pain. However, the lack of controlled trials makes it hard to make a substantial comment on its efficacy.

Sphenopalatine ganglion (SPG) block

The SPG is found in the course of the greater petrosal nerve located in the pterygopalatine fossa. It is a predominantly parasympathetic neural center with multiple connections to trigeminal, facial, and sympathetic systems and consists of somatosensory, sympathetic, and parasympathetic fibers and receives a sensory, motor, and sympathetic root.⁹⁵ Due to its complex nature, sphenopalatine ganglion block (SpGB) had been used for a variety of medical conditions ranging from low back pain to asthma in the past.⁹⁶ Today, it is mainly utilized in treatment of intractable facial pain, migraine, and cluster headache while also used in the treatment of trigeminal neuralgia, local neoplastic compression mechanisms, and myofascial pain of head and neck.⁹⁷ There is also evidence that it is useful in decreasing pain in patients after endoscopic sinus surgery.⁹⁸

SPG can be blocked via a transoral, infrazygomatic, or an intranasal approach. In intranasal approach, a long cotton swab that is saturated with 4% lidocaine is applied to the posterior nasal cavity through the nose when the patient is supine.⁹⁷ A novel device called Tx360 can also be used for this method.⁹⁹

Due to its resistance to medical therapies, SpGB has become an essential aspect of treatment of chronic cluster headaches. In 2009, Narouze et al investigated the effect of SpGB via radiofrequency ablation. They included 15 patients with cluster headaches and followed them for an 18-month period and showed that attack intensity frequency and pain disability were significantly decreased.¹⁰⁰ A recent study has tried BTX injections to the SPG in 10 patients with cluster headaches and showed that attack frequency decreased significantly.¹⁰¹

It is also being used in patients with head and neck cancer. These patients suffer from intractable headaches and facial pains. SpGB has been increasingly used to help these patients in the recent years. A very recent study in the literature by Sanghavi et al showed that in 100 patients with head and neck cancer, home-based SpGB significantly decreased pain levels and opioid use. It has also been shown to be a safe and comfortable procedure.¹⁰²

To conclude, SpGB is a safe and easy method that can be applied in intractable facial pain and headaches of various

etiologies. The literature mostly consists of case reports and currently lacks controlled studies to comment on its effectiveness.

Acknowledgment

The authors would like to thank Dr. Savas Sencan for his contribution of images used in this article. All the patients have given consent to the publication of the images included in this review.

Disclosure

The authors report no conflicts of interest in this work.

References

- Drummond PD, Finch PM, Skipworth S, Blockley P. Pain increases during sympathetic arousal in patients with complex regional pain syndrome. *Neurology*. 2001;57(7):1296–1303.
- Ramer MS, Bisby MA. Adrenergic innervation of rat sensory ganglia following proximal or distal painful sciatic neuropathy: distinct mechanisms revealed by anti-NGF treatment. *Eur J Neurosci*. 1999;11(3):837–846.
- Jänig W, Baron R. Complex regional pain syndrome: mystery explained? *Lancet Neurol*. 2003;2(11):687–697.
- Narouze S. Ultrasound-guided stellate ganglion block: safety and efficacy. *Curr Pain Headache Rep*. 2014;18(6):424.
- Carron H, Litwiller R. Stellate ganglion block. *Anesth Analg*. 1975;54(5):567–570.
- Haaga JR, Kori SH, Eastwood DW, Borkowski GP. Improved technique for CT-guided celiac ganglia block. *AJR Am J Roentgenol*. 1984;142(6):1201–1204.
- Kapral S, Kraft P, Gosch M, Fleischmann D, Weinstabl C. Ultrasound imaging for stellate ganglion block: direct visualization of puncture site and local anesthetic spread. A pilot study. *Reg Anesth*. 1995;20(4):323–328.
- O'Connell NE, Wand BM, Gibson W, Carr DB, Birklein F, Stanton TR. Local anaesthetic sympathetic blockade for complex regional pain syndrome. *Cochrane Database Syst Rev*. 2016;7:CD004598.
- Makharita MY, Amr YM, El-Bayoumy Y. Effect of early stellate ganglion blockade for facial pain from acute herpes zoster and incidence of postherpetic neuralgia. *Pain Physician*. 2012;15(6):467–474.
- Abdi S, Zhou Y, Patel N, Saini B, Nelson J. A new and easy technique to block the stellate ganglion. *Pain Physician*. 2004;7(3):327–331.
- Lipov E, Ritchie EC. A review of the use of stellate ganglion block in the treatment of PTSD. *Curr Psychiatry Rep*. 2015;17(8):599.
- Hayase J, Patel J, Narayan SM, Krummen DE. Percutaneous stellate ganglion block suppressing VT and VF in a patient refractory to VT ablation. *J Cardiovasc Electrophysiol*. 2013;24(8):926–928.
- Guttuso T Jr. Stellate ganglion block for treating hot flashes: a viable treatment option or sham procedure? *Maturitas*. 2013;76(3):221–224.
- Hamelberg W, Jacoby J. Shoulder-hand syndrome: treatment with stellate ganglion block. *J S C Med Assoc*. 1959;55(2):53–55.
- Rodríguez RF, Bravo LE, Tovar MA, Castro F, Ramos GE, Méndez F. Determinación de la eficacia analgésica de los bloqueos del ganglio estrellado en el alivio del dolor mediado por el sistema nervioso simpático, en pacientes con síndrome doloroso regional complejo del miembro superior [Determination of the analgesic efficacy of stellate ganglion blockages in the relief of pain mediated by the sympathetic nervous system, in patients with complex regional pain syndrome of the upper limb]. *Rev Colomb Anestesiología*. 2005;33(3):153–159. Spanish [with English abstract].
- Ackerman WE, Zhang JM. Efficacy of stellate ganglion blockade for the management of type 1 complex regional pain syndrome. *South Med J*. 2006;99(10):1084–1088.
- Yucel I, Demiraran Y, Ozturan K, Degirmenci E. Complex regional pain syndrome type I: efficacy of stellate ganglion blockade. *J Orthop Traumatol*. 2009;10(4):179–183.
- Nascimento MS, Klamt JG, Prado WA. Intravenous regional block is similar to sympathetic ganglion block for pain management in patients with complex regional pain syndrome type I. *Braz J Med Biol Res*. 2010;43(12):1239–1244.
- Yoo SD, Jung SS, Kim HS, et al. Efficacy of ultrasonography guided stellate ganglion blockade in the stroke patients with complex regional pain syndrome. *Ann Rehabil Med*. 2012;36(5):633–639.
- Wei K, Feldmann RE Jr, Brascher AK, Benrath J. Ultrasound-guided stellate ganglion blocks combined with pharmacological and occupational therapy in Complex Regional Pain Syndrome (CRPS): a pilot case series ad interim. *Pain Med*. 2014;15(12):2120–2127.
- Lipton JR, Harding SP, Wells JC. The effect of early stellate ganglion block on postherpetic neuralgia in herpes zoster ophthalmicus. *Pain Clin*. 1987;1:247–251.
- Lee IH, Kim BS, Lee SC, Jo DH. The effect of stellate ganglion block on the pain of acute stage and the prevention of postherpetic neuralgia in the treatment of senile herpes zoster patients. *Korean J Dermatol*. 1999;37(5):571–579.
- Kim HJ, Ahn HS, Lee JY, et al. Effects of applying nerve blocks to prevent postherpetic neuralgia in patients with acute herpes zoster: a systematic review and meta-analysis. *Korean J Pain*. 2017;30(1):3–17.
- Mekhail N, Malak O. Lumbar sympathetic blockade. *Tech Reg Anesth Pain Manag*. 2001;5(3):99–101.
- Hong JH, Oh MJ. Comparison of multilevel with single level injection during lumbar sympathetic ganglion block: efficacy of sympatholysis and incidence of psoas muscle injection. *Korean J Pain*. 2010;23(2):131–136.
- König CW, Schott UG, Pereira PL, et al. MR-guided lumbar sympathicolysis. *Eur Radiol*. 2002;12(6):1388–1393.
- Schmid MR, Kissling RO, Curt A, Jaschko G, Hodler J. Sympathetic skin response: monitoring of CT-guided lumbar sympathetic blocks. *Radiology*. 2006;241(2):595–602.
- Moon JY, Choi JK, Shin JY, Chon SW, Dev S. A brief report on a technical description of ultrasound-guided lumbar sympathetic block. *Korean J Pain*. 2017;30(1):66–70.
- Abramov R. Lumbar sympathetic treatment in the management of lower limb pain. *Curr Pain Headache Rep*. 2014;18(4):403.
- Chaturvedi A, Dash HH. Sympathetic blockade for the relief of chronic pain. *J Indian Med Assoc*. 2001;99(12):698–703.
- Price DD, Long S, Wilsey B, Rafii A. Analysis of peak magnitude and duration of analgesia produced by local anesthetics injected into sympathetic ganglia of complex regional pain syndrome patients. *Clin J Pain*. 1998;14(3):216–226.
- Manjunath PS, Jayalakshmi TS, Dureja GP, Prevost AT. Management of lower limb complex regional pain syndrome type 1: an evaluation of percutaneous radiofrequency thermal lumbar sympathectomy versus phenol lumbar sympathetic neurolysis--a pilot study. *Anesth Analg*. 2008;106(2):647–649, table of contents.
- Carroll I, Clark JD, Mackey S. Sympathetic block with botulinum toxin to treat complex regional pain syndrome. *Ann Neurol*. 2009;65(3):348–351.
- Meier PM, Zurakowski D, Berde CB, Sethna NF. Lumbar sympathetic blockade in children with complex regional pain syndromes: a double blind placebo-controlled crossover trial. *Anesthesiology*. 2009;111(2):372–380.
- Freitas TS, Deusdara R, Kessler I. Pulsed radiofrequency of sympathetic lumbar plexus versus sympathetic block in the management of lower limb complex regional pain syndrome type 1. In: Roberts DW, Lebanon NH, editors. *Stereotactic and Functional Neurosurgery*. Vol. 91. Basel: Karger; 2013:107.
- Erdine S. Celiac ganglion block. *Agri*. 2005;17(1):14–22.

37. Waldman SD. *Atlas of Interventional Pain Management*. Elsevier Health Sciences, Philadelphia; 2009.
38. Rathmell JP. *Atlas of Image-Guided Intervention in Regional Anesthesia and Pain Medicine*. Lippincott Williams & Wilkins, Philadelphia; 2011.
39. Nitschke AM, Ray CE Jr. Percutaneous neurolytic celiac plexus block. *Semin Intervent Radiol*. 2013;30(3):318–321.
40. Wang PJ, Shang MY, Qian Z, Shao CW, Wang JH, Zhao XH. CT-guided percutaneous neurolytic celiac plexus block technique. *Abdom Imaging*. 2006;31(6):710–718.
41. Yasuda I, Wang HP. Endoscopic ultrasound-guided celiac plexus block and neurolysis. *Dig Endosc*. 2017;29(4):455–462.
42. Eisenberg E, Carr DB, Chalmers TC. Neurolytic celiac plexus block for treatment of cancer pain: a meta-analysis. *Anesth Analg*. 1995;80(2):290–295.
43. Rana MV, Candido KD, Raja O, Knezevic NN. Celiac plexus block in the management of chronic abdominal pain. *Curr Pain Headache Rep*. 2014;18(2):394.
44. Kambadakone A, Thabet A, Gervais DA, Mueller PR, Arellano RS. CT-guided celiac plexus neurolysis: a review of anatomy, indications, technique, and tips for successful treatment. *Radiographics*. 2011;31(6):1599–1621.
45. Ischia S, Ischia A, Polati E, Finco G. Three posterior percutaneous celiac plexus block techniques. A prospective, randomized study in 61 patients with pancreatic cancer pain. *Anesthesiology*. 1992;76(4):534–540.
46. Mercadante S. Celiac plexus block versus analgesics in pancreatic cancer pain. *Pain*. 1993;52(2):187–192.
47. Polati E, Finco G, Gottin L, Bassi C, Pederzoli P, Ischia S. Prospective randomized double-blind trial of neurolytic coeliac plexus block in patients with pancreatic cancer. *Br J Surg*. 1998;85(2):199–201.
48. Lillemoe KD, Cameron JL, Kaufman HS, Yeo CJ, Pitt HA, Sauter PK. Chemical splanchnicectomy in patients with unresectable pancreatic cancer: A prospective randomized trial. *Ann Surg*. 1993;217(5):447–455; discussion 456–457.
49. Wong GY, Schroeder DR, Carns PE, et al. Effect of neurolytic celiac plexus block on pain relief, quality of life, and survival in patients with unresectable pancreatic cancer: a randomized controlled trial. *JAMA*. 2004;291(9):1092–1099.
50. Zhong W, Yu Z, Zeng JX, et al. Celiac plexus block for treatment of pain associated with pancreatic cancer: a meta-analysis. *Pain Pract*. 2014;14(1):43–51.
51. Amr YM, Makharita MY. Comparative study between 2 protocols for management of severe pain in patients with unresectable pancreatic cancer: one-year follow-up. *Clin J Pain*. 2013;29(9):807–813.
52. Seicean A. Celiac plexus neurolysis in pancreatic cancer: the endoscopic ultrasound approach. *World J Gastroenterol*. 2014;20(1):110–117.
53. Puli SR, Reddy JB, Bechtold ML, Antillon MR, Brugge WR. EUS-guided celiac plexus neurolysis for pain due to chronic pancreatitis or pancreatic cancer pain: a meta-analysis and systematic review. *Dig Dis Sci*. 2009;54(11):2330–2337.
54. Shwita AH, Amr YM, Okab MI. Comparative Study of the Effects of the Retrocural Celiac Plexus Block Versus Splanchnic Nerve Block, C-arm Guided, for Upper Gastrointestinal Tract Tumors on Pain Relief and the Quality of Life at a Six-month Follow Up. *Korean J Pain*. 28(1):22–31.
55. Wyse JM, Carone M, Paquin SC, Usatii M, Sahai AV. Randomized, double-blind, controlled trial of early endoscopic ultrasound-guided celiac plexus neurolysis to prevent pain progression in patients with newly diagnosed, painful, inoperable pancreatic cancer. *J Clin Oncol*. 2011;29(26):3541–3546.
56. Gress F, Schmitt C, Sherman S, Ikenberry S, Lehman G. A prospective randomized comparison of endoscopic ultrasound- and computed tomography-guided celiac plexus block for managing chronic pancreatitis pain. *Am J Gastroenterol*. 1999;94(4):900–905.
57. Gress F, Schmitt C, Sherman S, Ciaccia D, Ikenberry S, Lehman G. Endoscopic ultrasound-guided celiac plexus block for managing abdominal pain associated with chronic pancreatitis: a prospective single center experience. *Am J Gastroenterol*. 2001;96(2):409–416.
58. LeBlanc JK, DeWitt J, Johnson C, et al. A prospective randomized trial of 1 versus 2 injections during EUS-guided celiac plexus block for chronic pancreatitis pain. *Gastrointest Endosc*. 2009;69(4):835–842.
59. Santosh D, Lakhtakia S, Gupta R, et al. Clinical trial: a randomized trial comparing fluoroscopy guided percutaneous technique vs. endoscopic ultrasound guided technique of coeliac plexus block for treatment of pain in chronic pancreatitis. *Aliment Pharmacol Ther*. 2009;29(9):979–984.
60. Sey MS, Schmaltz L, Al-Haddad MA, et al. Effectiveness and safety of serial endoscopic ultrasound-guided celiac plexus block for chronic pancreatitis. *Endosc Int Open*. 2015;3(1):E56–E59.
61. Kaufman M, Singh G, Das S, et al. Efficacy of endoscopic ultrasound-guided celiac plexus block and celiac plexus neurolysis for managing abdominal pain associated with chronic pancreatitis and pancreatic cancer. *J Clin Gastroenterol*. 2010;44(2):127–134.
62. Minaga K, Kitano M, Imai H, Miyata T, Kudo M. Acute spinal cord infarction after EUS-guided celiac plexus neurolysis. *Gastrointest Endosc*. 2016;83(5):1039–1040; discussion 1040.
63. Köker IH, Aralasmak A, Ünver N, Asil T, Şentürk H. Spinal cord ischemia after endoscopic ultrasound guided celiac plexus neurolysis: case report and review of the literature. *Scand J Gastroenterol*. 2017;52(10):1158–1161.
64. Mercadante S, Klepstad P, Kurita GP, Sjögren P, Giarratano A; European Palliative Care Research Collaborative (EPCRC). Sympathetic blocks for visceral cancer pain management: a systematic review and EAPC recommendations. *Crit Rev Oncol Hematol*. 2015;96(3):577–583.
65. Nagels W, Pease N, Bekkering G, Cools F, Dobbels P. Celiac plexus neurolysis for abdominal cancer pain: a systematic review. *Pain Med*. 2013;14(8):1140–1163.
66. Bosscher H. Blockade of the superior hypogastric plexus block for visceral pelvic pain. *Pain Pract*. 2001;1(2):162–170.
67. Waldman SD, Wilson WL, Kreps RD. Superior hypogastric plexus block using a single needle and computed tomography guidance: description of a modified technique. *Reg Anesth*. 1991;16(5):286–287.
68. Plancarte R, Amescua C, Patt RB, Aldrete JA. Superior hypogastric plexus block for pelvic cancer pain. *Anesthesiology*. 1990;73(2):236–239.
69. de Leon-Casasola OA, Kent E, Lema MJ. Neurolytic superior hypogastric plexus block for chronic pelvic pain associated with cancer. *Pain*. 1993;54(2):145–151.
70. Plancarte R, de Leon-Casasola OA, El-Helaly M, Allende S, Lema MJ. Neurolytic superior hypogastric plexus block for chronic pelvic pain associated with cancer. *Reg Anesth*. 1997;22(6):562–568.
71. Cariati M, De Martini G, Pretolesi F, Roy MT. CT-guided superior hypogastric plexus block. *J Comput Assist Tomogr*. 2002;26(3):428–431.
72. Ghoneim AA, Mansour SM. Comparative study between computed tomography guided superior hypogastric plexus block and the classic posterior approach: a prospective randomized study. *Saudi J Anaesth*. 2014;8(3):378–383.
73. Turker G, Basagan-Mogol E, Gurbet A, Ozturk C, Uckunkaya N, Sahin S. A new technique for superior hypogastric plexus block: the posteromedian transdiscal approach. *Tohoku J Exp Med*. 2005;206(3):277–281.
74. Gamal G, Helaly M, Labib YM. Superior hypogastric block: transdiscal versus classic posterior approach in pelvic cancer pain. *Clin J Pain*. 2006;22(6):544–547.
75. Mishra S, Bhatnagar S, Gupta D, Thulkar S. Anterior ultrasound-guided superior hypogastric plexus neurolysis in pelvic cancer pain. *Anaesth Intensive Care*. 2008;36(5):732–735.
76. Mishra S, Bhatnagar S, Rana SP, Khurana D, Thulkar S. Efficacy of the anterior ultrasound-guided superior hypogastric plexus neurolysis in pelvic cancer pain in advanced gynecological cancer patients. *Pain Med*. 2013;14(6):837–842.

77. Gofeld M, Lee CW. Ultrasound-guided superior hypogastric plexus block: a cadaveric feasibility study with fluoroscopic confirmation. *Pain Pract.* 2017;17(2):192–196.
78. Oh CS, Chung IH, Ji HJ, Yoon DM. Clinical implications of topographic anatomy on the ganglion impar. *Anesthesiology.* 2004;101(1):249–250.
79. Scott-Warren JT, Hill V, Rajasekaran A. Ganglion impar blockade: a review. *Curr Pain Headache Rep.* 2013;17(1):306.
80. Plancarte R, Amescua C, Patt RB, Allende S. Presacral blockade of the ganglion of Walther (ganglion impar). *J Am Soc Anesthesiol.* 1990;73(3A):A751.
81. Wemm K Jr, Saberski L. Modified approach to block the ganglion impar (ganglion of Walther). *Reg Anesth.* 1995;20(6):544–545.
82. Foye PM, Buttaci CJ, Stitik TP, Yonclas PP. Successful injection for coccyx pain. *Am J Phys Med Rehabil.* 2006;85(9):783–784.
83. Huang JJ. Another modified approach to the ganglion of Walther block (ganglion of impar). *J Clin Anesth.* 2003;15(4):282–283.
84. Lin CS, Cheng JK, Hsu YW, et al. Ultrasound-guided ganglion impar block: a technical report. *Pain Med.* 2010;11(3):390–394.
85. Datir A, Connell D. CT-guided injection for ganglion impar blockade: a radiological approach to the management of coccydynia. *Clin Radiol.* 2010;65(1):21–25.
86. Marker DR, U-Thainual P, Ungi T, et al. MR-guided perineural injection of the ganglion impar: technical considerations and feasibility. *Skeletal Radiol.* 2016;45(5):591–597.
87. Reig E, Abejón D, del Pozo C, Insausti J, Contreras R. Thermocoagulation of the ganglion impar or ganglion of Walther: description of a modified approach. Preliminary results in chronic, nononcological pain. *Pain Pract.* 2005;5(2):103–110.
88. Toshniwal GR, Dureja GP, Prashanth SM. Transsacrococcygeal approach to ganglion impar block for management of chronic perineal pain: a prospective observational study. *Pain Physician.* 2007;10(5):661–666.
89. Agarwal-Kozlowski K, Lorke DE, Habermann CR, Am Esch JS, Beck H. CT-guided blocks and neuroablation of the ganglion impar (Walther) in perineal pain: anatomy, technique, safety, and efficacy. *Clin J Pain.* 2009;25(7):570–576.
90. Demircay E, Kabatas S, Cansever T, Yilmaz C, Tuncay C, Altinors N. Radiofrequency thermocoagulation of ganglion impar in the management of coccydynia: preliminary results. *Turk Neurosurg.* 2010;20(3):328–333.
91. Gopal H, Mc Crory C. Coccygodynia treated by pulsed radio frequency treatment to the Ganglion of Impar: a case series. *J Back Musculoskelet Rehabil.* 2014;27(3):349–354.
92. Gunduz OH, Sencan S, Kenis-Coskun O. Pain relief due to transsacrococcygeal ganglion impar block in chronic coccygodynia: a pilot study. *Pain Med.* 2015;16(7):1278–1281.
93. Adas C, Ozdemir U, Toman H, Luleci N, Luleci E, Adas H. Transsacrococcygeal approach to ganglion impar: radiofrequency application for the treatment of chronic intractable coccydynia. *J Pain Res.* 2016;9:1173–1177.
94. Walters A, Muhleman M, Osiro S, et al. One is the loneliest number: a review of the ganglion impar and its relation to pelvic pain syndromes. *Clin Anat.* 2013;26(7):855–861.
95. Robbins MS, Robertson CE, Kaplan E, et al. The sphenopalatine ganglion: anatomy, pathophysiology, and therapeutic targeting in headache. *Headache.* 2016;56(2):240–258.
96. Berger JJ, Pyles ST, Saga-Rumley SA. Does topical anesthesia of the sphenopalatine ganglion with cocaine or lidocaine relieve low back pain? *Anesth Analg.* 1986;65(6):700–702.
97. Levin M. Nerve blocks in the treatment of headache. *Neurotherapeutics.* 2010;7(2):197–203.
98. DeMaria S Jr, Govindaraj S, Chinosorvatana N, Kang S, Levine AI. Bilateral sphenopalatine ganglion blockade improves postoperative analgesia after endoscopic sinus surgery. *Am J Rhinol Allergy.* 2012;26(1):e23–e27.
99. Candido KD, Massey ST, Sauer R, Darabad RR, Knezevic NN. A novel revision to the classical transnasal topical sphenopalatine ganglion block for the treatment of headache and facial pain. *Pain Physician.* 2013;16(6):E769–E778.
100. Narouze S, Kapural L, Casanova J, Mekhail N. Sphenopalatine ganglion radiofrequency ablation for the management of chronic cluster headache. *Headache.* 2009;49(4):571–577.
101. Bratbak DF, Nordgård S, Stovner LJ, et al. Pilot study of sphenopalatine injection of onabotulinumtoxin A for the treatment of intractable chronic cluster headache. *Cephalalgia.* 2016;36(6):503–509.
102. Sanghavi PR, Shah BC, Joshi GM. Home-based application of sphenopalatine ganglion block for head and neck cancer pain management. *Indian J Palliat Care.* 2017;23(3):282–286.

Journal of Pain Research

Publish your work in this journal

The Journal of Pain Research is an international, peer reviewed, open access, online journal that welcomes laboratory and clinical findings in the fields of pain research and the prevention and management of pain. Original research, reviews, symposium reports, hypothesis formation and commentaries are all considered for publication.

Submit your manuscript here: <https://www.dovepress.com/journal-of-pain-research-journal>

Dovepress

The manuscript management system is completely online and includes a very quick and fair peer-review system, which is all easy to use. Visit <http://www.dovepress.com/testimonials.php> to read real quotes from published authors.