

A novel nomogram for the prediction of intrahepatic cholangiocarcinoma in patients with intrahepatic lithiasis complicated by imagiologically diagnosed mass

Gang Chen¹
 Huajun Yu¹
 Yi Wang²
 Chenhao Li²
 Mengtao Zhou¹
 Zhengping Yu¹
 Xiangwu Zheng³
 Xiuling Wu⁴
 Yunfeng Shan¹
 Qiyu Zhang¹
 Qiqiang Zeng¹

¹Department of Hepatobiliary Surgery, The First Affiliated Hospital, Wenzhou Medical University, Wenzhou, Zhejiang, China; ²Division of Preventive Medicine, School of Public Health and Management, Wenzhou Medical University, Wenzhou, Zhejiang, China; ³Radiological Department, The First Affiliated Hospital, Wenzhou Medical University, Wenzhou, Zhejiang, China; ⁴Department of Pathology, The First Affiliated Hospital, Wenzhou Medical University, Wenzhou, Zhejiang, China

Correspondence: Qiqiang Zeng
 Department of Hepatobiliary Surgery,
 The First Affiliated Hospital, Wenzhou
 Medical University, 1 Shangcai Street,
 Wenzhou, Zhejiang 325000, China
 Tel +86 138 5778 8867
 Fax +86 577 5557 8033
 Email zqq@wzhospital.cn

Background: Accurate preoperative diagnosis of intrahepatic cholangiocarcinoma (ICC) among patients with imagiologically intrahepatic lithiasis (IHL) complicated by mass is crucial for timely and effective surgical intervention. The aim of the present study was to develop a nomogram to identify ICC associated with IHL (IHL-ICC).

Patients and methods: Data were obtained from a total of 252 consecutive patients with IHL complicated by mass. Multivariate logistic regression analysis was conducted to identify the clinicopathologic and imagiologic characteristics that were potentially associated with ICC. A nomogram was developed based on the results of the multivariate analysis, and the value for prediction of ICC was assessed.

Results: The study revealed six potential predictors for IHL-ICC, including comprehensive imagiologic diagnosis, biliary tract operation history, fever, ascites, cancer antigen (CA) 19-9, and carcinoembryonic antigen (CEA). The optimal cutoff value was 3.75 µg/L for serum CEA and 143.15 U/mL for serum CA 19-9. The accuracy of the nomogram in predicting ICC was 78.5%. The Youden index provided a value of 0.348, corresponding to a cutoff of 95 points, with an area under the curve of 0.863.

Conclusion: The nomogram holds promise as a novel and accurate tool in identifying IHL-ICC for hepatectomy, and in the differentiation of benign occupying lesions in IHL patients, resulting in the avoidance of unnecessary surgical resection.

Keywords: intrahepatic cholangiocarcinoma, intrahepatic lithiasis, benign occupying lesions, nomogram, CEA, CA 19-9

Introduction

Intrahepatic cholangiocarcinoma (ICC) is the second most common primary cancer of the liver after hepatocellular carcinoma, which arises from the endothelial cells of segmental or proximal branches of the bile duct. The incidence of ICC has been increasing over the last several decades,¹⁻⁴ and the disease is more prevalent in Far Eastern countries, such as China, Japan, South Korea, and Thailand,⁵ than in Western countries. Until now, the reason underlying this higher incidence has remained unclear; however, a contributing factor to this difference appears to be intrahepatic lithiasis (IHL), which has been reported to be more frequently observed in Southeast Asia than in Western countries.^{6,7} The incidence of IHL in Western countries has also increased with the continuous influx of Asian immigrants to these countries. In fact, IHL has been well documented as a high-risk state for ICC.^{6,7} Studies have

reported that a proportion ranging from 2.3% to 13.0% of hepatolithiasis patients eventually develop cholangiocarcinoma.^{8–13} In Taiwan, it has been estimated that 65%–70% of patients that undergo resection for cholangiocarcinoma have concomitant hepatolithiasis.^{14,15} A high incidence of IHL is one of the major causes of the high incidence of ICC in China,⁵ similar to the prevalence of hepatobiliary flukes that leads to the high incidence of ICC in the northeast of Thailand.

Although the progression from IHL to ICC is not fully understood, chronic proliferative cholangitis may play a role in biliary carcinogenesis.¹⁶ Indeed, long-term intrahepatic bile duct stones and chronic bile duct inflammation can lead to the formation of an intrahepatic mass. However, it has been very difficult for clinical surgeons to distinguish between an inflammatory mass (IM) and a malignant lesion, and thus the effective and timely surgical intervention is largely limited by the accuracy of the preoperative diagnosis, mainly due to its nonspecific clinical presentation or the absence of specific symptoms. Currently, detection of ICC among patients with IHL mainly relies on imaging examination, including B-scan ultrasound (US), computed tomography (CT), and magnetic resonance imaging (MRI). However, it has proven difficult to accurately differentiate ICCs from IMs in IHL as well as to identify strictures, infiltrating types of ICC, massforming ICCs, and inflammatory pseudotumors, mainly because lesions with fibrotic, scarring, and inflammatory necrosis often appear in prolonged affected liver segments.^{17–19} The accuracy of preoperative imaging diagnosis for IHL-ICC is <70%.^{20,21} Although tissue biopsies can confirm a histologic diagnosis, it is not routinely recommended or necessary in ICC,²² especially in IHL-ICC because a “negative” biopsy does not exclude ICC given the potential for sampling error. In fact, the probability of a “negative” biopsy is higher in IHL-ICC due to concurrent chronic inflammation and necrosis caused by calculi. The preoperative diagnostic accuracy of IHL-ICC is low, generally ranging from 20% to 50% diagnosed by combining imaging with biopsy, serum carcinoembryonic antigen (CEA), and cancer antigen (CA) 19-9 levels.^{8,9,20} Therefore, there is an urgent need to develop a better noninvasive method to improve the diagnostic accuracy of ICC in patients with IHL complicated by mass.

The aim of the present study was to analyze data collected from consecutive patients with IHL complicated by mass, detected through imaging examination, and to develop a nomogram for preoperative identification of ICC among these patients.

Patients and methods

Patients and study design

Study subjects were drawn from a total of 5,279 patients with IHL who underwent hepatectomy at The First Affiliated Hospital of Wenzhou Medical University between January 2000 and July 2016. Of these patients, 283 showed complications due to the presence of a mass as displayed by imaging. However, 31 patients were found ineligible, of which 26 individuals underwent surgical resection for the lesions rather than those originally revealed by imaging, two cases were pathologically indicative of hepatocellular carcinoma, and three patients were histologically diagnosed as having atypical hyperplasia. In all, 252 patients who fulfilled the following four inclusion criteria were eventually selected for the current retrospective study: 1) IHL, which is referred to as intrahepatic bile duct stones confirmed by clinical and imagiological examinations; 2) undergoing hepatectomy (irregular hepatectomy, heplobectomy, or hepatic segmentectomy); 3) mass or other occupying lesions revealed by at least one of the following imaging assessments: US, CT, or MRI; and 4) ICC or cholangitis confirmed through pathology after hepatectomy.

Details of the recruitment and selection of the patients in this study are displayed in Figure 1. Preoperative comprehensive imagiological diagnosis following imaging (US, CT, or MRI) was performed by two senior board-certified radiologists, who were not given any information about the histopathological diagnosis or other clinical data. Diagnosis was categorized as follows: 1) IM was diagnosed when imaging exhibited a) typical echogenic debris, septations, or gas on sonography or b) observation of hypodense hepatic mass with regular margin compared with normal liver tissue through the arterial phase to delayed phase on CT; 2) suspicious cancer or suspicious lesion was diagnosed when imaging lacked the typical features of abscess and ICC; and 3) cancer was diagnosed when imaging demonstrated heterogeneous minor peripheral enhancement with gradual enhancement centrally and irregular margins.

This retrospective study was reviewed and approved by the Institutional Review Board (IRB) of the First Affiliated Hospital of Wenzhou Medical University, and a waiver of written informed consent was granted by the IRB due to the retrospective nature of this study, in which de-identified data were used and analyzed. All study procedures were performed in accordance with the 1964 Helsinki Declaration and its later amendments or comparable ethical standards.

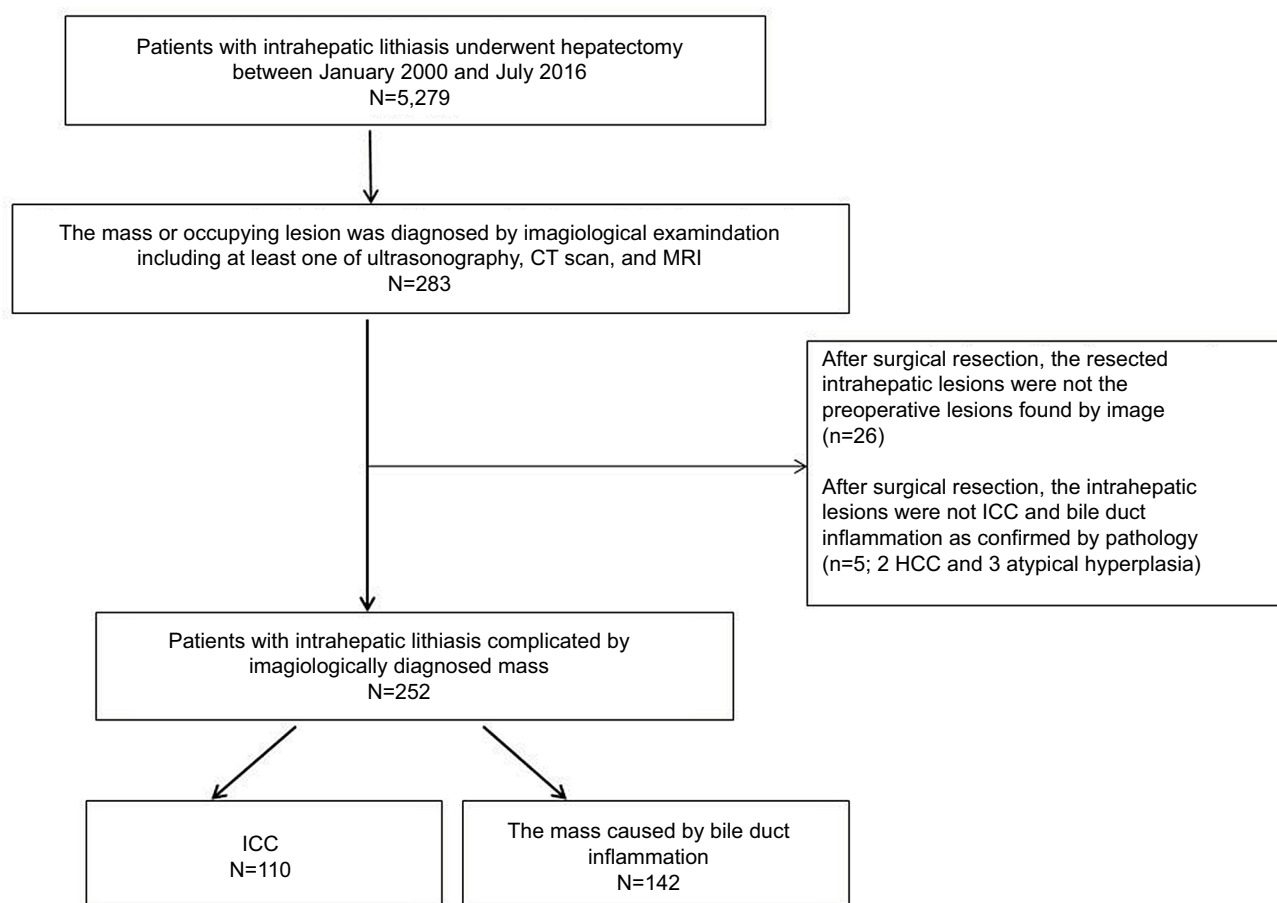


Figure 1 Flow diagram of the study design.

Notes: The study patients were selected from a large sample of patients with intrahepatic lithiasis (N=5,279) who underwent hepatectomy in our hospital. Of these patients, 283 had masses, as revealed by the imaging examination, 31 patients did not meet the inclusion criteria, and a total of 252 patients were included in this retrospective study. **Abbreviations:** CT, computed tomography; MRI, magnetic resonance imaging; HCC, hepatocellular carcinoma; ICC, intrahepatic cholangiocarcinoma.

Development of nomogram

A nomogram was constructed based on the results of the multivariate analysis to predict the probability of ICC. The discriminative power of the model was quantified in terms of discrimination and calibration. The Hosmer–Lemeshow test was used to assess the fitness of the nomogram ($P > 0.05$ indicating good fit).²³ Discrimination was quantified by the area under the curve (AUC) of the receiver-operating characteristic (ROC) and 95% CIs were estimated. In all, 1,000 bootstrap resamples were used for the internal validation of the accuracy estimates to reduce overfit bias. Sensitivity, specificity, positive predictive values (PPV), negative predictive values (NPV), and their 95% CIs were calculated for various cutoff points of the calculated risk score.

Statistical analysis

Continuous variables are presented as mean±SD or median (range). Data were compared using standard parametric

and nonparametric methods, where appropriate. Frequency data are presented as numbers and percentages and were compared using the chi-squared test or Fisher's exact test, where appropriate. The performance of the tumor marker and imaging were assessed using ROC curve analysis. The factors predictive of ICC at diagnosis were identified through univariate and multivariate logistic regression analyses. OR and 95% CI were calculated to estimate the strength of the association between individual risk factors and ICC. Factors found to be significantly associated with ICC in the univariate analysis ($P < 0.05$) were included in the multivariate analysis. All statistical analyses were two-sided and carried out using SPSS (version 18.0; SPSS Company Inc, Chicago, IL, USA) and R software version 3.22 (<http://www.r-project.org>). The R package with rms, pROC, Hmisc, and ggplot2 (available at <http://cran.r-project.org/web/packages/>) was used.

Results

Demographic and clinicopathologic characteristics

Data were obtained from 252 patients in this study cohort, of which 110 cases were confirmed to have ICC and 142 were confirmed to have IM. Demographic characteristics as well as laboratory and clinical data from the IHL-ICC and IHL-IM groups are summarized in Table 1. Univariate analysis demonstrated that the potential risk factors for the development of ICC in IHL were age, comprehensive imagiological

diagnosis, biliary tract operation history, fever, weight loss, ascites, alkaline phosphatase, and the serum levels of CA 19-9, CEA, and CA125 (all $P<0.001$; Table 1).

ROC curve analysis of cross-sectional liver imaging and laboratory diagnostic tests

Cross-sectional liver imaging

Preoperative imaging with at least one of the cross-sectional liver imaging techniques was performed for each patient.

Table 1 Demographic and clinical characteristics of 252 patients

	IHL-IM (n=142)	IHL-ICC (n=110)	P-value
Age (years)	59.58±10.44	62.99±9.83	0.008
Sex (F/M)	87/55	70/40	0.7
Time (months)	3 (0.002–40)	5 (0.02–50)	0.016
Smoking	23 (16%)	23 (21%)	0.34
Alcohol	19 (13%)	17 (15%)	0.64
Comprehensive imagiological diagnosis			0.001
Inflammatory mass	44	21	
Suspicious of cancer	88	55	
Cancer	10	34	
Location of mass			0.696
Left lobe	99	77	
Right lobe	35	30	
Left and right lobes	5	2	
Lobus caudatus	3	1	
Lesion size (cm)	5.5±1.27	5.7±1.32	0.92
Complication			
HBV	15 (11%)	14 (13%)	0.59
Diabetes	16 (11%)	10 (9%)	0.57
Cirrhosis	16 (11%)	13 (12%)	0.89
Fat liver	8 (6%)	6 (5%)	0.96
Cholecystectomy	44 (31%)	34 (31%)	0.99
Biliary tract operation history	36 (25%)	52 (47%)	<0.001
Symptoms			
Abdominal pain	122 (86%)	92 (84%)	0.62
Fever	60 (42%)	29 (26%)	0.009
Jaundice	11 (8%)	9 (8%)	0.90
Weight loss	7 (5%)	23 (21%)	<0.001
Ascites	4 (3%)	14 (13%)	0.003
Other	21 (15%)	17 (15%)	0.88
Laboratory			
Alkaline phosphatase (U/L)	121 (8–1,261)	156.5 (70–1,114)	<0.001
Glutamyl transferase (U/L)	110 (15–1,410)	156 (12–1,200)	0.08
Alanine aminotransferase (U/L)	35 (5–651)	28.5 (8–866)	0.31
Lactic dehydrogenase (U/L)	178 (102–805)	186.5 (131–413)	0.42
Total bilirubin (mg/dL)	12 (0.00–159)	11 (0.5–240)	0.45
Albumin (g/dL)	37 (19–49.9)	36.8 (3.3–78.6)	0.90
Personal cancer history	2 (1%)	3 (3%)	0.65
Family cancer history	7 (5%)	6 (5%)	0.85
CA 19-9 (U/mL)	37.6 (0–12,000)	549.7 (0–35,587)	<0.001
CEA (μg/L)	1.7 (0.3–8.2)	5.9 (0.7–2,149.9)	<0.001
CA 125 (U/mL)	17.3 (2.7–272.7)	47 (4.1–2,149.4)	0.002
AFP (μg/L)	2.65 (0.9–10.49)	2.82 (0.6–24.93)	0.10

Abbreviations: IHL-ICC, intrahepatic cholangiocarcinoma associated with intrahepatic lithiasis; IHL-IM, inflammatory mass associated with intrahepatic lithiasis; AFP, alpha-fetoprotein; HBV, hepatitis B; CEA, carcinoembryonic antigen; CA, cancer antigen.

US was performed on 153 patients, CT was performed on 220 patients, enhanced CT was performed on 64 patients, MRI was performed on 89 patients, and enhanced MRI was performed on 17 patients. As shown in Figure 2A, AUC comparison demonstrated that the highest discriminatory capacity was achieved through enhanced CT, with an AUC (95% CI) of 0.793 (0.647–0.940). The discriminatory capacity of enhanced CT was significantly greater than that of enhanced MRI ($P=0.022$), for which the AUC (95% CI) was 0.700 (0.104–1.000). The results from other imaging techniques are as follows: US showed an AUC (95% CI) of 0.617 (0.590–0.752), comprehensive imagiological diagnosis displayed an AUC (95% CI) of 0.638 (0.575–0.700), nonenhanced MRI exhibited an AUC (95% CI) of 0.595 (0.474–0.717), and nonenhanced CT an AUC (95% CI) of 0.584 (0.521–0.648).

Serum CEA

Preoperative data on the serum CEA levels of 91 patients in the IHL-ICC group and 108 patients in the IHL-IM group were obtained and analyzed. The median level of serum CEA in the IHL-ICC patients was 5.9 $\mu\text{g/L}$, with a range of 0.7–2149.9 $\mu\text{g/L}$, which was significantly higher than the level in the IHL-IM patients (1.7 $\mu\text{g/L}$ with a range of 0.3–8.2 $\mu\text{g/L}$; $P<0.001$). The sensitivity of serum CEA was plotted against 1–specificity for each possible cutoff point, giving an AUC of 0.811. The optimal cutoff value for serum CEA was 3.75 $\mu\text{g/L}$, which yielded a sensitivity of 59% and a specificity of 92% (Figure 2B). To develop a nomogram, the level of serum CEA was converted to a categorical variable,

according to the cutoff value (3.75 and 5 $\mu\text{g/L}$), and univariate analysis was then performed (Table 2). There was a significant difference between the two groups ($P<0.001$).

Serum CA 19-9

The level of serum CA 19-9 was preoperatively examined in 91 patients with IHL-ICC and 108 patients with IHL-IM. The median levels of serum CA 19-9 in the IHL-ICC patients (549.7 U/mL with a range of 0–35,587) were significantly greater than the IHL-IM patients (37.6 U/mL with a range of 0–12,000; $P<0.001$). The AUC was calculated by plotting the sensitivity of serum CA 19-9 against 1–specificity for each possible cutoff point, and the calculated value was 0.704. The optimal cutoff value for serum CA 19-9 was 143.15 U/mL, which yielded a sensitivity of 68% and a specificity of 68% (Figure 2C). To facilitate the development of a nomogram, the level of serum CA 19-9 was converted to a categorical variable according to the cutoff value (37 and 143.15 U/mL), and univariate analysis was then performed (Table 2). The difference of the two groups was marked ($P<0.001$).

Multivariate logistic regression analysis for the selection of independent ICC predictors

Ten candidate predictors, selected from the univariate analysis, were included in the multivariate regression analysis model, and six independent predictors for ICC development were eventually identified (Table 3). Patients with IHL that had a biliary tract operation history carried a 2.954-fold increase in ICC risk (OR=2.954, 95% CI, 1.312–6.648), and

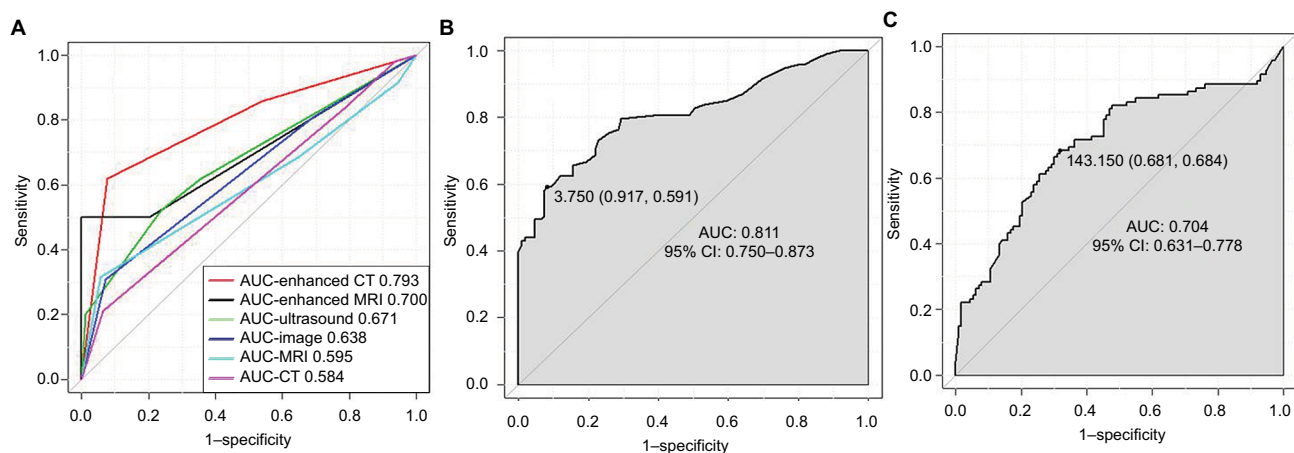


Figure 2 ROC curve analysis of the cross-sectional liver imaging and serum markers for patients with intrahepatic lithiasis complicated by mass.

Notes: (A) Enhanced CT, enhanced MRI, comprehensive imagiological diagnosis, nonenhanced MRI, and nonenhanced CT. (B) CEA: the cutoff and the optimal cutoff values of serum CEA ($\mu\text{g/L}$) were used to determine the sensitivity and specificity of the ICC diagnosis. (C) CA 19-9: the cutoff and the optimal cutoff values of serum CA 19-9 (U/mL) were used to determine the sensitivity and specificity of the ICC diagnosis.

Abbreviations: ROC, receiver operating characteristic; CT, computed tomography; MRI, magnetic resonance imaging; ICC, intrahepatic cholangiocarcinoma; CEA, serum carcinoembryonic antigen; CA, cancer antigen; AUC, area under the curve.

Table 2 Univariate analysis of CA 19-9 and CEA as a categorical variable

	IHL-IM	IHL-ICC	P
CA 19-9			<0.001
≤37	54	16	
~143.15	19	12	
>143.15	35	63	
CEA			<0.001
<3.75	99	38	
~5	2	8	
>5	7	45	

Abbreviations: IHL-ICC, intrahepatic cholangiocarcinoma associated with intrahepatic lithiasis; IHL-IM, inflammatory mass associated with intrahepatic lithiasis; CEA, carcinoembryonic antigen; CA, cancer antigen.

Table 3 Multivariate logistic regression analysis of the risk factor for patients with IHL complicated by mass

	P-value	OR	95% CI
Ascites	0.092	4.213	0.790–22.477
Biliary tract operation history	0.009	2.954	1.312–6.648
Fever	0.045	0.436	0.193–0.983
Comprehensive imagiological diagnosis	0.088	1.725	0.921–3.230
CA 19-9			
≤37 U/mL			
~143.15 U/mL	0.302	1.804	0.588–5.531
>143.15 U/mL	0.001	4.124	1.740–9.775
CEA			
<3.75 µg/L			
3.75–5.00 µg/L	0.022	7.185	1.326–38.927
>5.00 µg/L	<0.001	9.176	3.210–26.231

Abbreviations: IHL, intrahepatic cholangiocarcinoma; CEA, carcinoembryonic antigen; CA, cancer antigen.

patients with ascites carried a 4.213-fold increase in ICC risk (OR=4.213, 95% CI, 0.790–22.477). The comprehensive imagiological diagnosis of ICC was associated with a high risk of ICC (OR=1.725, 95% CI, 0.921–3.230). IHL patients with fever were associated with a low risk of developing ICC (OR=0.436, 95% CI, 0.193–0.983). IHL patients with a serum CEA level higher than 5.0 µg/L carried a 9.176-fold increase in ICC risk (OR=9.176, 95% CI, 3.210–26.231), and patients with a serum CA 19-9 level higher than 143.15 U/mL carried a 4.124-fold increase in ICC risk (OR=4.124, 95% CI, 1.740–9.775).

The nomogram and its performance

The nomogram was constructed based upon the six independent predictors described above (Figure 3). In the nomogram model, each predictor was ascribed a total point value or a weighted point total (top scale), which implied the probability of ICC (bottom scale). The *P*-value for the Hosmer–Lemeshow test was 0.989, indicating good fit of the model.

The calibration plot of the nomogram was subsequently developed. As illustrated in Figure 4, the nomogram was well calibrated.

As shown in Figure 5, the AUC of the nomogram was 0.863 (95% CI, 0.810–0.916), with a sensitivity, specificity, NPV, and PPV of 81.3%, 76.4%, 84.5%, and 72.3%, respectively. The Youden-derived cutoff value for the nomogram was 0.348, corresponding to a total point value of 95. At this threshold, the nomogram had a sensitivity of 82.4%, specificity of 75.0%, NPV of 75.0%, PPV of 81.3%, and accuracy of 78.5%. If the specificity of 90% was set as the cutoff value, the corresponding probability, total points, and sensitivity were 0.613, 143, and 59.3%, respectively. At the cutoff value for the specificity of 95%, the corresponding probability, total points, and sensitivity were 0.762, 174, and 49.5%, respectively.

Furthermore, the AUC comparison revealed the highest discriminatory capacity of the nomogram among any combination of two predictors, which was significantly higher than comprehensive imagiological diagnosis combined with CEA (*P*=0.002) with an AUC of 0.784, comprehensive imagiological diagnosis in conjunction with CA 19-9 with an AUC of 0.754, CEA in combination with an AUC of 0.751, CA 19-9 combined with an AUC of 0.711, or comprehensive imagiological diagnosis in conjunction with an AUC of 0.637 (Figure 5).

Discussion

The present study on IHL patients with ICC or benign occupying lesions had the following main novel findings: 1) potential predictors for IHL-ICC included mass revealed by imaging, biliary tract operation history, fever, ascites, serum CA 19-9, and serum CEA; 2) the optimal cutoff values of serum CEA and CA 19-9 for preoperative diagnosis of ICC among the IHL patients complicated by an imagiologically diagnosed mass were determined as 3.75 µg/L and 143.15 U/mL, respectively; 3) for patients with IHL complicated by an imagiologically diagnosed mass, the Youden-derived cutoff value for the prediction of ICC has a probability of 0.349, corresponding to the total point value of 95 in the present nomogram; and 4) the discriminatory ability of the nomogram model was much improved and significantly greater than image examination in combination with one of the other predictors.

Globally, ICC is rare and the pathological mechanisms that underlie the development and progression of the disease remain largely unknown. Lines of evidence have shown that patients with intrahepatic bile duct stones and chronic bile

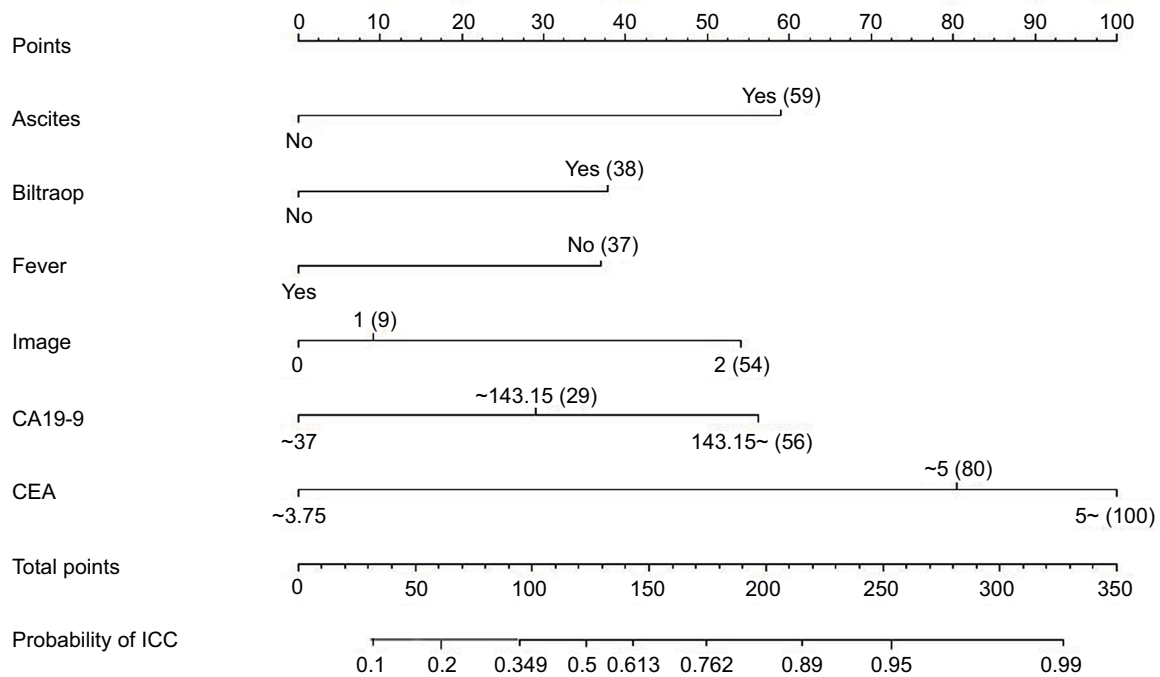


Figure 3 Construction of preoperative nomogram to predict intrahepatic cholangiocarcinoma in patients with intrahepatic lithiasis complicated by mass.

Notes: A preoperative nomogram was created based upon six potential independent predictors, as identified by the multivariate logistic regression analysis, including comprehensive imagiological diagnosis, biliary tract operation history, fever, ascites, and serum levels of CA 19-9 and CEA. Category "0" signifies the presence of an IM, the category "1" signifies the presence of suspicious cancer, and the category "2" signifies the presence of cancer according to preoperative comprehensive imagiological diagnosis upon US, CT, or MRI.

Abbreviations: IM, inflammatory mass; CT, computed tomography; MRI, magnetic resonance imaging; US, ultrasound; CEA, serum carcinoembryonic antigen; CA, cancer antigen; ICC, intrahepatic cholangiocarcinoma.

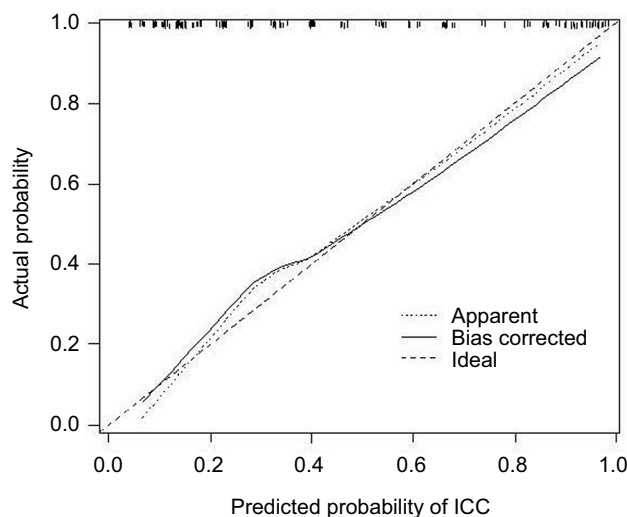


Figure 4 Calibration plot of the nomogram for the probability of intrahepatic cholangiocarcinoma in patients with intrahepatic lithiasis complicated by mass.

Abbreviation: ICC, intrahepatic cholangiocarcinoma.

duct inflammation are at high risk of an intrahepatic mass, including ICC. Based on our data, ICC and intrahepatic bile duct stone were more often located in the left lobe (176/252). Additionally, both lesions were found to share the same location in all of the studied cases. This observation, along with previous reports from other researchers, supports the

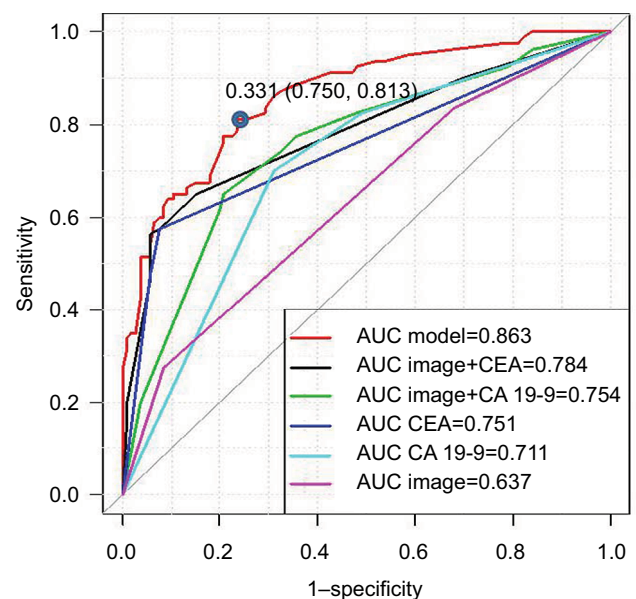


Figure 5 ROC analysis of the nomogram model, in combination with comprehensive imagiological diagnosis and CEA, comprehensive imagiological diagnosis and cancer antigen (CA) 19-9, CEA, CA 19-9, and comprehensive imagiological diagnosis in patients with intrahepatic lithiasis.

Abbreviations: ROC, receiver-operating characteristic; CEA, carcinoembryonic antigen; CA, cancer antigen; AUC, area under the curve.

finding that IHL is strongly associated with ICC, and that it is likely an independent, mainly etiological factor in ICC.²⁴

Logistic regression analysis demonstrated that comprehensive imagiological diagnosis, ascites, a history of biliary surgery, fever, and serum levels of CA 19-9 and CEA are significantly associated with IHL-ICC. Although chronic hepatitis B and C have been reported to be independent risk factors for ICC,^{25–29} we did not find significant differences between the IHL-ICC group and IHC group in the study, similar to the findings of Liu et al.³⁰

Regarding imagiological evaluation, our results demonstrated that enhanced CT was the best method through which to diagnose IHL-ICC, followed by enhanced MRI, US, unenhanced MRI, and unenhanced CT. Through ultrasonography, ICC typically appears as a hypoechoic mass and may be associated with peripheral ductal dilatation, although these features are not specific. Through CT imaging, typical ICC appears as a hypodense hepatic mass with irregular margins in the unenhanced phase, peripheral rim enhancement in the arterial phase, and progressive hyperattenuation in the venous and delayed phases.³¹ Through MRI imaging, ICC typically appears to be hypointense on T1-weighted and hyperintense on T2-weighted images; T2-weighted images may also show central hypointensity corresponding to areas of fibrosis.³² However, after long-term chronic inflammation, liver segments often become fibrotic and scarred.¹⁸ Therefore, it is difficult to differentiate strictures, infiltrating types of ICC, and benign biliary inflammatory stricture, as well as massforming ICCs and inflammatory pseudotumors. In the present study, the comprehensive imagiological diagnosis for each patient was made by two senior board-certified radiologists according to imaging examinations that had been undertaken previously. Because enhanced CT and enhanced MRI examinations were not performed on all of the studied patients, data on enhanced CT and enhanced MRI examination were missing for some patients, and thus overall, the accuracy of the comprehensive imagiological diagnosis for all selected cases was still less than through enhanced CT or enhanced MRI alone, as demonstrated in Figure 2A.

Because imagiological examination alone was limited for the accurate diagnosis of cholangiocarcinoma, as also demonstrated in the present study, tumor markers can be of help in the detection of IHL-ICC. Previously, serum levels of CEA and CA 19-9 have been reported to be useful for the diagnosis of cholangiocarcinoma. To discriminate between IHL-ICC and IHL-IM, the present study showed that the optimal cutoff value for serum CEA was 3.75 µg/L with a sensitivity of 59% and a specificity of 92%. The cutoff value of CEA was lower than the recommended value in the overall population (5.0 µg/L)³³ and that reported by Kim et al

(4.2 µg/L).²¹ The results suggest that we should be alert to concurrent cholangiocarcinomas when serum CEA is higher than 3.75 µg/L in IHL patients. The optimal cutoff value for serum CA 19-9 was 143.15 U/mL with a sensitivity of 68% and a specificity of 68%, which is higher than the value reported to distinguish ICC from benign bile duct lesions by Leelawat et al (100 U/mL).³⁴ However, it is noteworthy that in the study of Leelawat et al the sample size for ICC was only 12 patients, which is much smaller than the sample size of the present study. Additionally, in the previous study no potentially causative factors for ICC were analyzed.³⁴ Elevated concentrations of serum CA 19-9 have been reported in cholangiocarcinoma, with a cutoff value of 37 U/mL.³⁵ However, values of serum CA 19-9 >37 U/mL were obtained from ICC patients³⁵ but not the IHL-ICC cases in our study. It has been reported that the serum CA 19-9 level can be elevated when the bile duct is obstructed or inflamed and free from carcinoma.³⁶ Therefore, a cutoff value of serum CA 19-9 of 37 U/mL is unable to confidently predict IHL-ICC. An additional complication is that ~7% of the population is Lewis negative and unable to express CA 19-9.³⁷ Along with the low sensitivity and specificity observed, there are limitations in the use of serum CEA and CA 19-9 measurements in the prediction of IHL-ICC.

To our knowledge, this is the first study to create a diagnostic nomogram for predicting IHL-ICC using a large sample size. By analyzing the clinical, laboratory, and imaging data from 252 patients with IHL complicated by mass formation, we developed a nomogram that performed well in the prediction of IHL-ICC. The concise and well-fitted nomogram contains variables of biliary tract operation history, fever, ascites, serum levels of CA 19-9 and CEA, and comprehensive imagiological diagnosis. This would provide a convenient application for clinicians. Using the method of calibration plot with bootstrap sampling for internal validation by AUC and ROC, the nomogram was shown to produce good fit. Using the nomogram, the AUC for all variables in predicting IHL-ICC was 0.863 (95% CI, 0.810–0.916). This is significantly higher than the AUC for the comprehensive imagiological diagnosis alone, the serum level of CA 19-9 alone, the serum level of CEA alone, comprehensive imagiological diagnosis combined with the serum level of CA 19-9, and comprehensive imagiological diagnosis combined with the serum level of CEA, or the serum level of CA 19-9 combined with the serum level of CEA (all $P < 0.05$). Liu et al³⁰ reported that smoking, family history of cancer, and duration of symptoms may be risk factors for ICC in patients with IHL. Kim et al²¹ reported that the risk factors

for ICC in patients with IHL include age, weight loss, and serum alkaline phosphatase. However, in the present study, the above-mentioned factors were not found to be potential predictors using our multivariate logistic regression analysis. The reason for this difference may be due to the fact that the previous study enrolled only patients with IHL without complications, whereas in our study, patients with IHL complicated by imagiologically diagnosed mass were enrolled.

Balachandran et al³⁸ have proposed that nomograms could be an important component of decision-making in modern medicine, especially in oncology. Our study supports the diagnostic value of nomograms for patients with IHL complicated by imagiologically diagnosed mass. In the present nomogram, the sum of the sensitivity and specificity for ICC diagnosis reaches the maximum at the probability of ICC of 0.349, corresponding to a total point value of 95 using the Youden-derived cutoff value. Therefore, diagnosis of ICC can be considered for patients with a total point value >95, and surgical intervention is highly recommended. However, for patients with a total point value <95, close observation and follow-up should be performed, during which the serum levels of CA 19-9 and CEA, CT images, and the nomogram total point value should be checked with care. Furthermore, if patients have a biliary tract infection or liver abscess, physicians should examine any changes in the imaging results following an antibiotic treatment. If a specificity of 75% is not satisfactory, a specificity of 90% or 95% can be used as cutoff value, corresponding to a total point value of 143 and sensitivity of 59.3%, or a total point value of 174 and sensitivity of 49.5%. It is worthwhile to note that this carefully constructed nomogram could meet physicians' need for more accurate and simple models to diagnose IHL complicated by imagiologically diagnosed mass. In addition, it has been observed in clinical practice that at least 40% of patients are scheduled for surgery without preoperative definite diagnosis. Of these cases, ~90% are seen and confirmed as cancer in the resected tissues. Therefore, under the condition that the mass is enduring, surgical procedure is recommended even in cases where the nomogram may show relatively low risk for cancer.

The current study had some limitations. First, the study was performed in a single center, which may limit its applicability to a broader sample of patients. An external validation of the nomogram, with a more large-scale sample size, is currently underway in a multicenter study. Second, the design of the study was retrospective and, thus, there were missing data regarding demographic and clinical factors. Third, the preoperative nomogram may not apply to patients with IHL without imagiologically diagnosed masses. Indeed, from

January 2000, we diagnosed six cases of IHL-ICC, in which preoperative imagiological examinations did not reveal any mass, but early stages of ICC were proven by postoperative pathology. Therefore, attention should also be paid to patients with IHL in the absence of imagiologically diagnosed masses.

In conclusion, imagiological diagnosis, biliary tract operation history, fever, ascites, and the serum level of CA 19-9 and CEA are potential independent factors for IHL-ICC. The optimal cutoff values of serum levels of CEA and CA 19-9 are 3.75 µg/L and 143.15 U/mL, respectively. The nomogram holds promise as a novel and accurate tool for the identification of IHL-ICC, for hepatectomy, and in the differentiation of benign occupying lesions, to avoid unnecessary surgical resection.

Acknowledgment

This study was funded by the foundation of Zhejiang Provincial Top Key Discipline of Surgery, Wenzhou Medical University (2008-255).

Disclosure

The authors report no conflicts of interest in this work.

References

1. Charbel H, Al-Kawas FH. Cholangiocarcinoma: epidemiology, risk factors, pathogenesis, and diagnosis. *Curr Gastroenterol Rep*. 2011;13(2):182–187.
2. Patel T. Increasing incidence and mortality of primary intrahepatic cholangiocarcinoma in the United States. *Hepatology*. 2001;33(6):1353–1357.
3. Wood R, Brewster DH, Fraser LA, Brown H, Hayes PC, Garden OJ. Do increases in mortality from intrahepatic cholangiocarcinoma reflect a genuine increase in risk? Insights from cancer registry data in Scotland. *Eur J Cancer*. 2003;39(14):2087–2092.
4. Patel T. Worldwide trends in mortality from biliary tract malignancies. *BMC Cancer*. 2002;2:10.
5. Bridgewater J, Galle PR, Khan SA, et al. Guidelines for the diagnosis and management of intrahepatic cholangiocarcinoma. *J Hepatol*. 2014;60(6):1268–1289.
6. Kuroki T, Tajima Y, Kanematsu T. Hepatolithiasis and intrahepatic cholangiocarcinoma: carcinogenesis based on molecular mechanisms. *J Hepatobiliary Pancreat Surg*. 2005;12(6):463–466.
7. Cai H, Kong WT, Chen CB, et al. Cholelithiasis and the risk of intrahepatic cholangiocarcinoma: a meta-analysis of observational studies. *BMC Cancer*. 2015;15:831.
8. Kubo S, Kinoshita H, Hirohashi K, Hamba H. Hepatolithiasis associated with cholangiocarcinoma. *World J Surg*. 1995;19(4):637–641.
9. Uenishi T, Hamba H, Takemura S, et al. Outcomes of hepatic resection for hepatolithiasis. *Am J Surg*. 2009;198(2):199–202.
10. Lin CC, Lin PY, Chen YL. Comparison of concomitant and subsequent cholangiocarcinomas associated with hepatolithiasis: clinical implications. *World J Gastroenterol*. 2013;19(3):375–380.
11. Kim HJ, Kim JS, Suh SJ, et al. Cholangiocarcinoma risk as long-term outcome after hepatic resection in the hepatolithiasis patients. *World J Surg*. 2015;39(6):1537–1542.
12. Suzuki Y, Mori T, Yokoyama M, et al. Hepatolithiasis: analysis of Japanese nationwide surveys over a period of 40 years. *J Hepatobiliary Pancreat Sci*. 2014;21(9):617–622.

13. Chen MF, Jan YY, Wang CS, Jeng LB, Hwang TL, Chen SC. Intrahepatic stones associated with cholangiocarcinoma. *Am J Gastroenterol*. 1989;84(4):391–395.
14. Chen MF. Peripheral cholangiocarcinoma (cholangiocellular carcinoma): clinical features, diagnosis and treatment. *J Gastroenterol Hepatol*. 1999;14(12):1144–1149.
15. Chen MF, Jan YY, Jeng LB, et al. Intrahepatic cholangiocarcinoma in Taiwan. *J Hepatobiliary Pancreat Surg*. 1999;6(2):136–141.
16. Nakanuma Y, Terada T, Tanaka Y, Ohta G. Are hepatolithiasis and cholangiocarcinoma aetiologically related? A morphological study of 12 cases of hepatolithiasis associated with cholangiocarcinoma. *Virchows Arch A Pathol Anat Histopathol*. 1985;406(1):45–58.
17. Mori T, Sugiyama M, Atomi Y. Gallstone disease: management of intrahepatic stones. *Best Pract Res Clin Gastroenterol*. 2006;20(6):1117–1137.
18. Menias CO, Surabhi VR, Prasad SR, Wang HL, Narra VR, Chintapalli KN. Mimics of cholangiocarcinoma: spectrum of disease. *Radiographics*. 2008;28(4):1115–1129.
19. Lesurtel M, Regimbeau JM, Farges O, Colombat M, Sauvanet A, Belghiti J. Intrahepatic cholangiocarcinoma and hepatolithiasis: an unusual association in Western countries. *Eur J Gastroenterol Hepatol*. 2002;14(9):1025–1027.
20. Guglielmi A, Ruzzenente A, Valdegamberi A, et al. Hepatolithiasis-associated cholangiocarcinoma: results from a multi-institutional national database on a case series of 23 patients. *Eur J Surg Oncol*. 2014;40(5):567–575.
21. Kim YT, Byun JS, Kim J, et al. Factors predicting concurrent cholangiocarcinomas associated with hepatolithiasis. *Hepatogastroenterology*. 2003;50(49):8–12.
22. Weber SM, Ribero D, O'Reilly EM, Kokudo N, Miyazaki M, Pawlik TM. Intrahepatic cholangiocarcinoma: expert consensus statement. *HPB (Oxford)*. 2015;17(8):669–680.
23. Hosmer DW, Lemeshow S. Assessing the fit of the model. *Applied Logistic Regression*. 2nd ed. New York: Wiley; 2005:143–202.
24. Su CH, Shyr YM, Lui WY, P'Eng FK. Hepatolithiasis associated with cholangiocarcinoma. *Br J Surg*. 1997;84(7):969–973.
25. Tao LY, He XD, Qu Q, et al. Risk factors for intrahepatic and extrahepatic cholangiocarcinoma: a case-control study in China. *Liver Int*. 2010;30(2):215–221.
26. Welzel TM, Graubard BI, El-Serag HB, et al. Risk factors for intrahepatic and extrahepatic cholangiocarcinoma in the United States: a population-based case-control study. *Clin Gastroenterol Hepatol*. 2007;5(10):1221–1228.
27. Shaib YH, El-Serag HB, Nooka AK, et al. Risk factors for intrahepatic and extrahepatic cholangiocarcinoma: a hospital-based case-control study. *Am J Gastroenterol*. 2007;102(5):1016–1021.
28. Donato F, Gelatti U, Tagger A, et al. Intrahepatic cholangiocarcinoma and hepatitis C and B virus infection, alcohol intake, and hepatolithiasis: a case-control study in Italy. *Cancer Causes Control*. 2001;12(10):959–964.
29. Lee TY, Lee SS, Jung SW, et al. Hepatitis B virus infection and intrahepatic cholangiocarcinoma in Korea: a case-control study. *Am J Gastroenterol*. 2008;103(7):1716–1720.
30. Liu ZY, Zhou YM, Shi LH, Yin ZF. Risk factors of intrahepatic cholangiocarcinoma in patients with hepatolithiasis: a case-control study. *Hepatobiliary Pancreat Dis Int*. 2011;10(6):626–631.
31. Valls C, Gumà A, Puig I, et al. Intrahepatic peripheral cholangiocarcinoma: CT evaluation. *Abdom Imaging*. 2000;25(5):490–496.
32. Hamrick-Turner J, Abbitt PL, Ros PR. Intrahepatic cholangiocarcinoma: MR appearance. *AJR Am J Roentgenol*. 1992;158(1):77–79.
33. Burtis CA, Bruns DE. *Tietz Fundamentals of Clinical Chemistry and Molecular Diagnostics*. St Louis, USA: Elsevier Saunders; 2014:351.
34. Leelawat K, Sakchinabut S, Narong S, Wannaprasert J. Detection of serum MMP-7 and MMP-9 in cholangiocarcinoma patients: evaluation of diagnostic accuracy. *BMC Gastroenterol*. 2009;9:30.
35. Liang B, Zhong L, He Q, et al. Diagnostic accuracy of serum CA19-9 in patients with cholangiocarcinoma: a systematic review and meta-analysis. *Med Sci Monit*. 2015;21:3555–3563.
36. Albert MB, Steinberg WM, Henry JP. Elevated serum levels of tumor marker CA19-9 in acute cholangitis. *Dig Dis Sci*. 1988;33(10):1223–1225.
37. Alvaro D. Serum and bile biomarkers for cholangiocarcinoma. *Curr Opin Gastroenterol*. 2009;25(3):279–284.
38. Balachandran VP, Gonen M, Smith JJ, DeMatteo RP. Nomograms in oncology: more than meets the eye. *Lancet Oncol*. 2015;16(4):e173–e180.

Cancer Management and Research

Publish your work in this journal

Cancer Management and Research is an international, peer-reviewed open access journal focusing on cancer research and the optimal use of preventative and integrated treatment interventions to achieve improved outcomes, enhanced survival and quality of life for the cancer patient. The manuscript management system is completely online and includes

Submit your manuscript here: <https://www.dovepress.com/cancer-management-and-research-journal>

Dovepress

a very quick and fair peer-review system, which is all easy to use. Visit <http://www.dovepress.com/testimonials.php> to read real quotes from published authors.