

# Local triamcinolone acetonide injection for treatment of nasal tip cysts

Zhi Li<sup>1</sup>  
Meng Wang<sup>2</sup>  
Lina Zhang<sup>1</sup>  
Na Zhang<sup>1</sup>  
Ning Xiang<sup>3</sup>  
Zhi Qiang Fu<sup>1</sup>

<sup>1</sup>ENT Department, First Hospital of QinHuangDao City, QinHuangDao, China; <sup>2</sup>Laboratory Department, First Hospital of QinHuangDao City, QinHuangDao, China; <sup>3</sup>Neurology Department, First Hospital of QinHuangDao City, QinHuangDao, China

**Background:** Cysts of the nasal tip are rare and have only been described in case reports. In most cases, such cysts were surgically excised. We treated a cyst of the nasal tip by local injection of triamcinolone acetonide.

**Objective:** We herein describe a patient with a nasal tip cyst that was treated by local injection of triamcinolone acetonide.

**Methods:** This is a case report with a relevant literature review. The cyst of the nasal tip was suctioned using a syringe, and triamcinolone acetonide was injected into the cyst and peripheral tissue once weekly.

**Results:** The patient was treated regularly, and the cyst disappeared after 3 weeks.

**Conclusion:** To our knowledge, the only previously reported treatment for cysts of the nasal tip is surgical excision. Injection of triamcinolone acetonide may be the preferred treatment for small cysts.

**Keywords:** nasal tip, cyst, triamcinolone acetonide injection, local injection

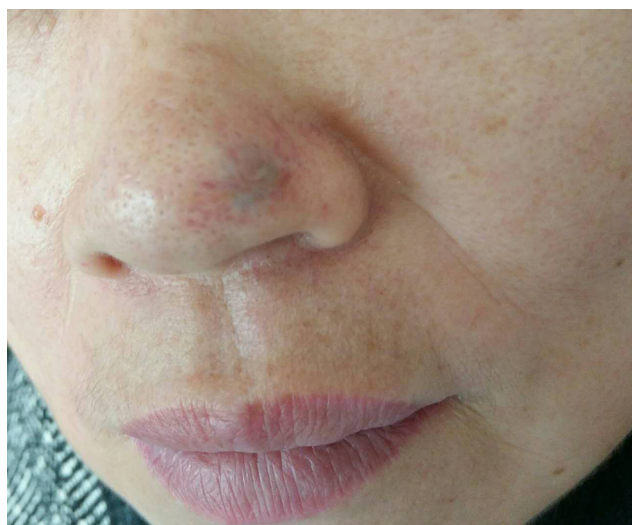
## Introduction

Cysts of the nasal tip are rare. Most are dermoid cysts that represent embryologic remnants of ectodermal tissue. Such cysts can cause compression deformities of the surrounding tissue or recurrent infections. Nasal tip cysts often present in childhood as a solitary enlarging mass on the tip of the nose. The cyst can create a mass effect, sometimes distorting the lower lateral cartilage. The skin on the nasal tip overlying the cyst is frequently attenuated or pigmented. These cysts are generally excised, and several surgical methods have been described. However, a postoperative lesion remains at the location of the cyst, resulting in unsatisfactory cosmesis. We herein present our experience with 1 patient whose nasal tip cyst was treated by local injection of triamcinolone acetonide along with a review of the relevant literature to examine different treatment techniques.

## Case description

A 52-year-old healthy woman was referred to the otolaryngology clinic because of a 2-year history of a swollen mass on the left nasal tip. During physical examination, a smooth round mass (about 1×1 cm) was found on the left side of the nasal tip, and the overlying skin was slightly pigmented (Figure 1). The mass was soft and fluctuant on palpation to the touch. The rest of the physical examination findings were normal. The patient had no other complaints and no specific family history. A cranial computed

Correspondence: Zhi Li  
ENT Department, First Hospital of  
QinHuangDao City, 258, WenHua  
Road, QinHuangDao, HaiGang District,  
066000, China  
Tel +13303352472  
Email lizhi307525@126.com

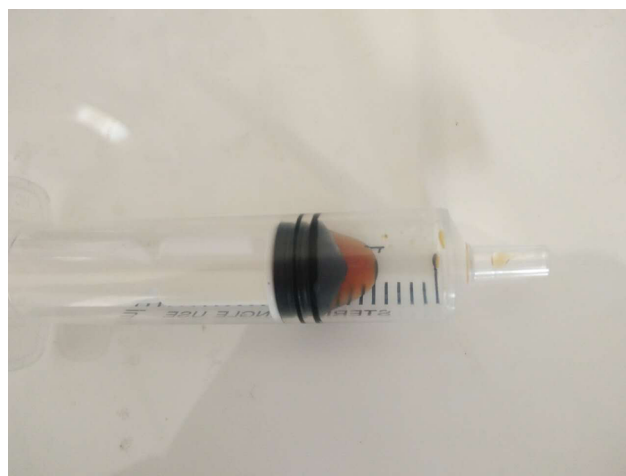

**Figure 1** The swollen mass on the left side of the nasal tip measuring about 1×1 cm.

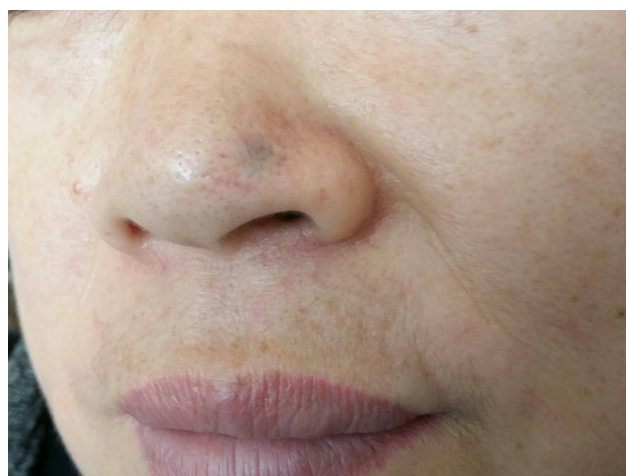
tomography scan showed no abnormalities. The otolaryngologist in charge decided to perform conservative treatment for the patient. About 0.8 mL of a brown secretion was aspirated from the cyst with a syringe, and pathologic examination revealed a small number of scattered squamous epithelial cells. The cells were large in size and contained a small, solid nucleus. Small numbers of lymphocytes and red blood cells were also present. Gram staining revealed no structural substance (keratin), and no tumor cells were found (Figure 2). About 0.5 mL of triamcinolone acetonide was then injected into the cyst and peripheral tissue, and finally the medicine that was left in the cyst was drawn out; this procedure was repeated 2 or 3 times once per week. After 3 weeks, the cyst had disappeared (Figure 3). No problems occurred after the treatment period. The patient had no complaints during the 1-year follow-up, and the aesthetic result was satisfactory.

## Discussion

Nasal dermoid cysts are the most frequent congenital lesions<sup>1</sup> and originate from the ectoderm and mesoderm.<sup>2</sup> These cysts are usually diagnosed in the first 3 years after birth. In some patients, however, the diagnosis can be prolonged until a later age. The oldest patient diagnosed with a nasal dermoid cyst in the literature was 56 years old.<sup>3</sup> Some reports have also indicated a male predominance.<sup>4</sup> Nasal cysts are commonly located between the glabella and columella. Intracranial extension may be incidentally found, but cranial computed tomography and/or magnetic resonance imaging are essential to identify the connection between the cyst and the extension. Cranial computed tomography clearly shows bone alterations and thus helps to achieve a diagnosis. Cysts with intracranial extension may require a more complex surgical approach or



**Figure 2** About 0.8 mL of a brown secretion was aspirated from the cyst of the nasal tip using a syringe.



**Figure 3** After 3 treatments, the mass disappeared.

neurosurgical consultation.<sup>5</sup> Our literature review indicated that the most common treatment of nasal dermoid cysts is surgical excision.<sup>6</sup> Morgan and Evans<sup>7</sup> suggested that excision of nasal dermoid cysts should be performed earlier than the age of 2 years to decrease the morbidity associated with the operation and optimize the aesthetic outcome. The resection of the cyst and reconstruction of the cartilaginous framework must be performed simultaneously, especially in pediatric patients whose cartilage is still soft and immature.<sup>8</sup> In the present case, the patient was conservatively treated because the cyst was small and showed no intracranial extension; it resembled a pseudocyst of the auricle.<sup>9</sup> We previously treated a pseudocyst of the auricle successfully with a combination of aspiration and triamcinolone acetonide injection. After three treatments, the swollen mass on the nasal tip disappeared. To the best of our knowledge, the present report is the first to describe treatment of a nasal tip cyst by local injection of triamcinolone acetonide. Based on our experience, conservative

treatment of nasal dermoid cysts is easy to perform and does not impair the cosmetic outcome.

## Conclusion

We have described our experience with a patient who underwent successful treatment of a nasal tip cyst by local injection of triamcinolone acetonide. Although such cysts are extremely rare, this treatment helps to avoid the risk of an operation and excision-related scar formation on the nasal tip. Therefore, it may be a useful treatment option for small cysts.

## Acknowledgments

The patient provided written informed consent for the publication of their data and accompanying images. We thank Angela Morben, DVM, ELS, from Liwen Bianji, Edanz Editing China ([www.liwenbianji.cn/ac](http://www.liwenbianji.cn/ac)), for editing the English text of a draft of this manuscript.

## Disclosure

The authors report no conflicts of interest in this work.

## References

1. Rahbar R, Shah P, Mulliken JB, et al. The presentation and management of nasal dermoid: a 30-year experience. *Arch Otolaryngol Head Neck Surg.* 2003;129(4):464–471.
2. Post G, McMains KC, Kountakis SE. Adult nasal dermoid sinus cyst. *Am J Otolaryngol.* 2005;26(6):403–405.
3. Hacker DC, Freeman JL. Intracranial extension of a nasal dermoid sinus cyst in a 56-year-old man. *Head Neck.* 1994;16(4):366–371.
4. Denoyelle F, Ducroz V, Roger G, Garabedian EN. Nasal dermoid sinus cysts in children. *Laryngoscope.* 1997;107(6):795–800.
5. Eloy P, Watelet JB, Hatert AS, Bertrand B. Thornwaldt's cyst and surgery with powered instrumentation. *B-ENT.* 2006;2(3):135–139.
6. Bilkay U, Gundogan H, Ozek C, et al. Nasal dermoid sinus cysts and the role of open rhinoplasty. *Ann Plast Surg.* 2001;47(1):8–14.
7. Morgan DW, Evans JNG. Developmental nasal anomalies. *J Laryngol Otol.* 1990;104:394–403.
8. Romo T 3rd, Kwak ES. Nasal grafts and implants in revision rhinoplasty. *Facial Plast Surg Clin North Am.* 2006;14(4):373–387.
9. Beutler BD, Cohen PR. Pseudocyst of the auricle in patients with movement disorders: report of two patients with ataxia-associated auricular pseudocysts. *Dermatol Pract Concept.* 2015;5(4):59–64.

### Comparative Effectiveness Research

### Publish your work in this journal

Comparative Effectiveness Research is an international, peer reviewed open access journal focusing on comparative effectiveness of health care including preventative health care strategies, diagnostic strategies, diagnostic technology, medical devices, drugs, medical technology, health systems and organization. The manuscript management system

Submit your manuscript here: <https://www.dovepress.com/comparative-effectiveness-research-journal>

Dovepress

is completely online and includes a very quick and fair peer-review system. Visit <http://www.dovepress.com/testimonials.php> to read real quotes from published authors.