

# NCOA1–ALK: a novel ALK rearrangement in one lung adenocarcinoma patient responding to crizotinib treatment

This article was published in the following Dove Medical Press journal:  
OncoTargets and Therapy

Qi Cao<sup>1</sup>  
Zhiguang Liu<sup>1</sup>  
Yanhua Huang<sup>1</sup>  
Chuang Qi<sup>2</sup>  
Xiaowei Yin<sup>1</sup>

<sup>1</sup>Department of Respiratory and Critical Care Medicine, Changzhou Second Affiliated People's Hospital of Nanjing Medical University, Changzhou 213003, China; <sup>2</sup>Medical Department, 3D Medicines, Shanghai 201100, China

**Abstract:** The heterogeneity of ALK tyrosine-kinase inhibitor (TKI) responses poses a puzzling question to clinicians. Different variants of *ALK* rearrangements might be one of the mechanisms explaining this phenomenon. Therefore, identifying specific fusion forms is crucial to clinical practice. This case report assesses the clinical efficacy of an ALK-TKI in a new *ALK*-rearrangement variant. Next-generation sequencing was performed in tumor tissue of one lung adenocarcinoma patient, and one new fusion form of an *ALK* rearrangement (*NCOA1–ALK*) was identified. This patient had progression-free survival >18 months with crizotinib treatment. Our findings provide valuable information about responses to crizotinib in patients with this form of *ALK* rearrangement and better understanding of ALK-TKI applications.

**Keywords:** *NCOA1–ALK*, lung adenocarcinoma, crizotinib

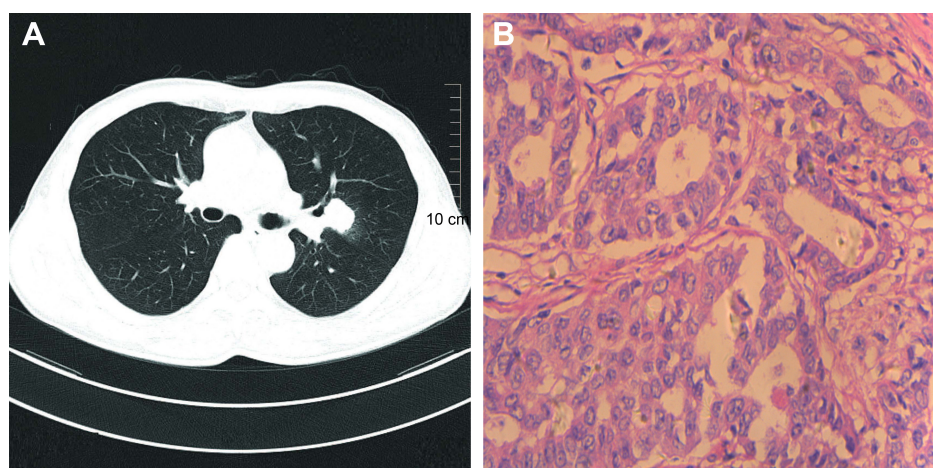
## Introduction

Approximately 5% of patients with non-small-cell lung cancer (NSCLC) have accompanying *ALK* rearrangement.<sup>1</sup> Fortunately, compared with *ALK*-rearrangement-negative NSCLC, ALK-positive patients can achieve impressive clinical outcomes after ALK tyrosine-kinase inhibitor (TKI) therapy.<sup>2</sup> Fusion genes consist of the promoter of a partner gene and the entire ALK domain, leading to continuous activation of downstream signaling pathways. Numerous fusion-partner genes have been discovered, such as *KIF5B*, *TFG*, *HIP1*,<sup>3</sup> among which *MLL4* is the most common. However, in ALK-positive patients, the response to ALK-TKIs is heterogeneous for different individuals. Research has indicated that different fusion variants might be one of the mechanisms explaining this phenomenon.<sup>3</sup> Even though various new types of *ALK* rearrangements have been discovered in clinical practice, the response to ALK-TKIs remains unknown. In the era of precision treatment, it is very important to understand the clinical significance of these unknown variants. Herein, we report one lung adenocarcinoma patient with a new fusion form of *ALK* rearrangement (*NCOA1–ALK*) who presented a long-term response to crizotinib.

## Case presentation

A 59-year-old man with a smoking history was admitted to our hospital for a conventional health checkup with a nodule in his upper-left lung. After pulmonary computed tomography (Figure 1A) and magnetic resonance imaging (MRI) of the head in hospital, the patient was assessed as being acceptable for surgery, without distant metastasis. Left-lung resection and lymph node-dissection were then performed. Postoperative

Correspondence: Xiaowei Yin  
Department of Respiratory and Critical Care Medicine, Changzhou Second Affiliated People's Hospital of Nanjing Medical University, 68 Gehu Road, Wujin, Changzhou, Jiangsu 213003, China  
Tel +86 138 138 6108 9980  
Email xiaoweiyinhuxi@163.com



**Figure 1** Chest computed tomography and histopathological findings of the primary lung tumor.

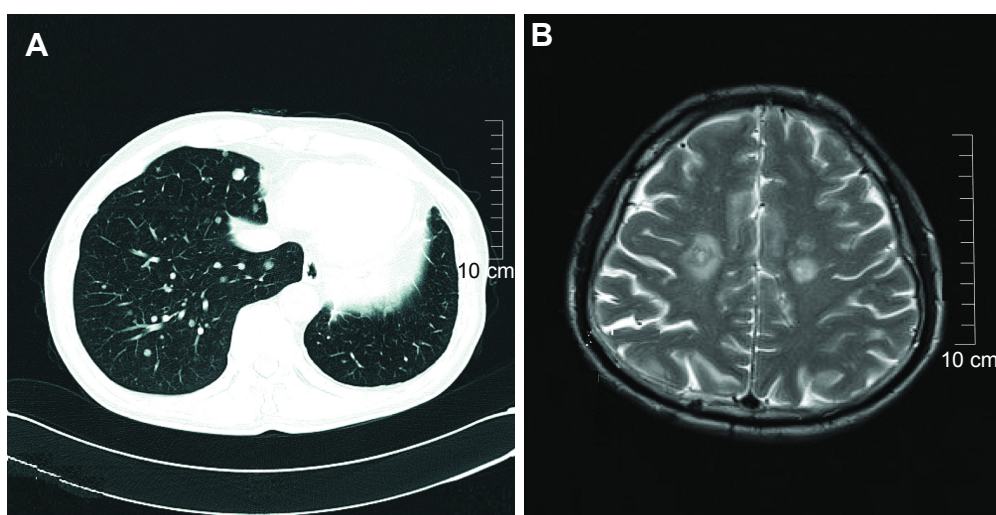
**Note:** (A) Chest computed tomography revealed a nodule in the upper-left lung; (B) a diagnosis of pathological lung adenocarcinoma was considered (H&E stain).

pathology showed a diagnosis of moderately differentiated lung adenocarcinoma in his upper-left lung (Figure 1B).

Genetic testing of common driver genes, such as *EGFR*, *ALK*, *ROS1*, was not performed in hospital. At 3 months after surgery, four cycles of standard chemotherapy (pemetrexed and carboplatin) was administered, and this patient did not come to hospital for regular routine follow-up visits until 28 months later, with a complain of chest congestion. Pulmonary CT and MRI screening showed multiple metastases in both lungs and brain metastasis, respectively (Figure 2A and B).

Second-line chemotherapy with docetaxel (120 mg according to the patient's surface area, 75 mg/m<sup>2</sup>, once every 3 weeks) was performed without any benefit. To explore

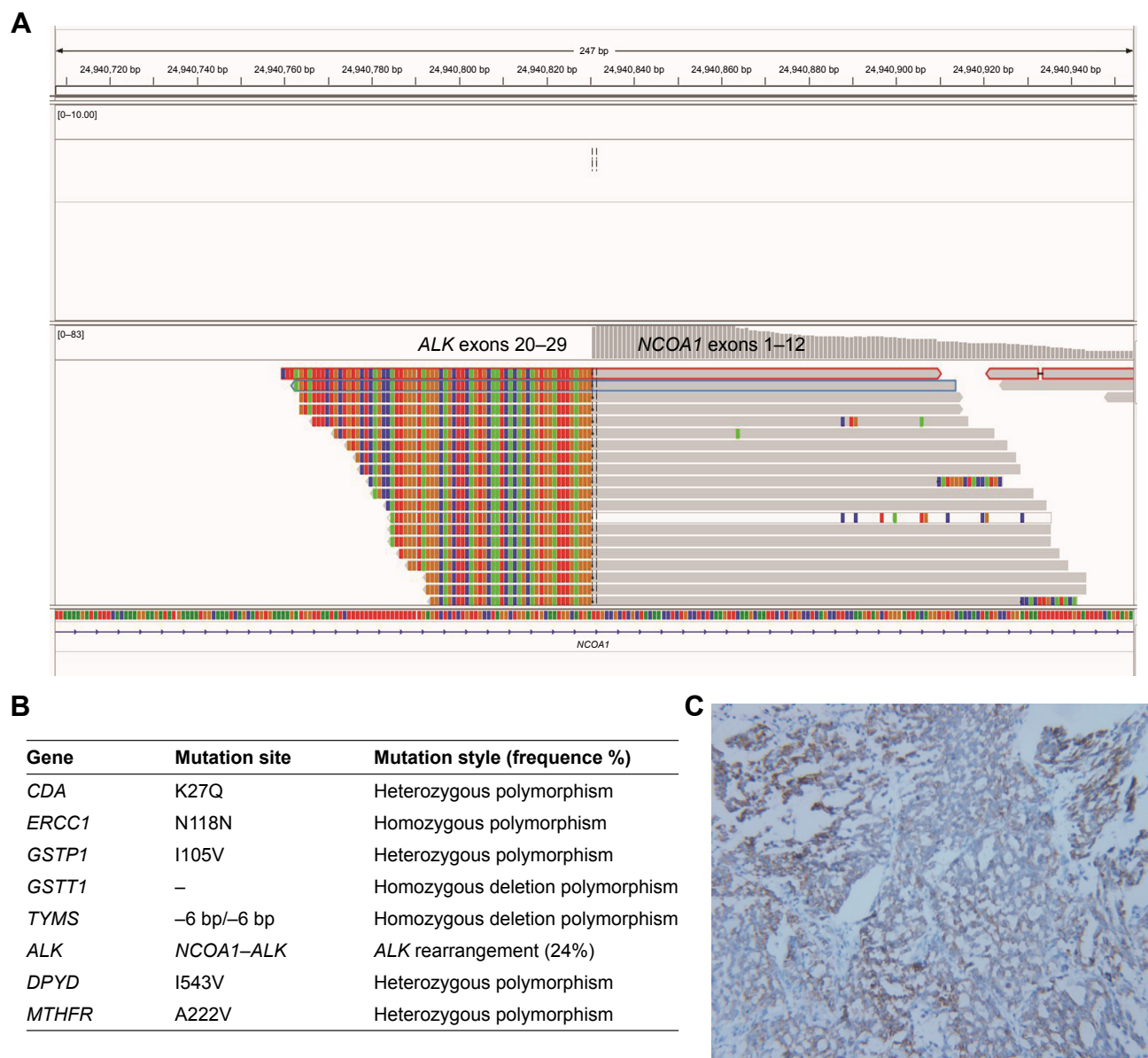
potential targeted therapies, next-generation sequencing was performed in tumor tissue and revealed a new type of *ALK* arrangement (*NCOA1-ALK*, Figure 3A). Mutation profiling of this patient is summarized in Figure 3B, and expression of the *ALK* protein was confirmed by immunohistochemistry (Figure 3C). Oral crizotinib (250 mg twice a day) was administered immediately. After 2 months of crizotinib treatment, the multiple metastatic nodules in the right lung had decreased significantly (Figure 4A and B) and the brain-lesion metastases were stable (Figure 4F and G). Several follow-up visits were recorded, and the patient was still alive without disease progression in lung lesions (Figure 4C–E) or brain metastases (Figure 4H–J). The progression-free survival of this patient had exceeded 18 months.



**Figure 2** Pulmonary CT and MRI screening findings of the lung tumor and brain metastasis (A and B).

**Note:** (A) Pulmonary CT indicated multiple metastases in lung; (B) MRI screening showed multiple metastases in brain metastasis.

**Abbreviations:** CT, computed tomography; MRI, magnetic resonance imaging.



**Figure 3** Next-generation sequencing and ALK immunohistochemistry findings of the primary lung-tumor-tissue samples.

**Notes:** (A) A new fusion form of *ALK* rearrangement involving inversion of the *NCOA1* gene (exons 1–12) and the *ALK* gene (exons 20–29) was identified. (B) Heterozygous genetic polymorphisms were discovered: *CDA*<sup>K27Q</sup>, *ERCC1*<sup>N118N</sup>, *DPYD*<sup>I543V</sup>, *MTHFR*<sup>A222V</sup>, and *GSTP1*<sup>I105V</sup>. A homozygous deletion polymorphism was discovered in the *GSTT1* and *TYMS* genes (–6 bp/–6 bp). (C) Immunohistochemistry results indicated *ALK* rearrangement was positive. Magnification ×200.

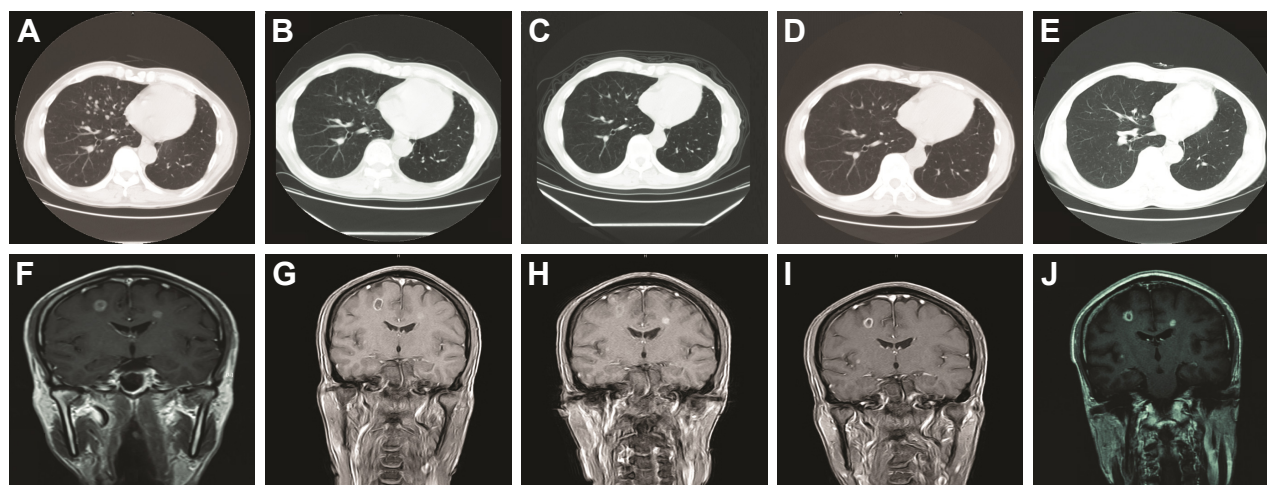
## Discussion

In this case report, a new fusion form of *ALK* rearrangement (*NCOA1-ALK*) was identified, which included inversion of *NCOA1* exons 1–12 and *ALK* exons 20–29. This fusion gene retained the TK domain of *ALK*, a critical region for *ALK* activity. The patient was still alive, with progression-free survival >18 months after crizotinib therapy. None of the other genetic mutations displayed a potential response to *ALK*-TKI.

*ALK*-TKIs are widely used in clinical practice, and the heterogeneity of response posed a puzzling question. Numerous researchers have explored the mechanisms of the primary resistance or heterogeneous response of *EGFR*-TKIs

for *EGFR*-mutation positive NSCLC patients.<sup>4</sup> However, similar studies for *ALK*-TKIs have been rare. Two explanations for the heterogeneity of *ALK*-TKI responses have been suggested. One interpretation was that different variants of *ALK* rearrangement resulted in different protein stability and expression levels, and the other interpretation was that concomitant *ALK* rearrangement with other genetic alterations led to different amplitudes in *ALK*-TKI response.<sup>5</sup>

The golden evaluation criterion for *ALK* state is fluorescent in situ hybridization or immunohistochemistry, neither of which can identify specific fusion forms. With the notion that different variants may exert different responses



**Figure 4** Evolution at follow-up of the patient's lung tumor (A–E) and brain metastasis (F–J) during crizotinib treatment.

**Notes:** (A) Baseline chest CT (October 2016) showed multiple metastatic nodules in the right lung before crizotinib treatment; (B–D) multiple metastatic nodules in the right lung decreased significantly and the brain-lesion metastases were stable in several follow-up visits on chest CT; (E) chest CT examination indicated multiple metastatic nodules having almost disappeared (April 2018); (F) intracranial metastasis before crizotinib treatment on MRI (September 2016); (G–I) lesions of intracranial metastasis had remained stable in several follow-up visits during crizotinib treatment; (J) MRI indicated lesions of intracranial metastasis had remained stable (May 2018).

**Abbreviations:** CT, computed tomography; MRI, magnetic resonance imaging.

to ALK-TKIs, it is crucial to identify the specific variant in different individuals, in order to achieve precise medication in the future. To a certain extent, next-generation-sequencing testing for *ALK* rearrangement may be an excellent method of supplementation.

To our knowledge, this is the first case to present a lung adenocarcinoma patient harboring a new fusion form of *ALK* rearrangements (*NCOA1-ALK*) showing a long-term response to crizotinib. Our findings provide valuable information on response to crizotinib in patients with this form of *ALK* rearrangement and better understanding of ALK-TKIs applications in future.

## Informed consent

Written informed consent had been provided by the patient to have the case details and any accompanying images published. This was an observational case report and institutional approval was not required, because all treatment

received by this patient is standard therapy, including the ALK-TKI (crizotinib).

## Disclosure

The authors report no conflicts of interest in this work.

## References

1. Solomon B, Varela-Garcia M, Camidge DR. ALK gene rearrangements: a new therapeutic target in a molecularly defined subset of non-small cell lung cancer. *J Thorac Oncol*. 2009;4(12):1450–1454.
2. Yoshida T, Oya Y, Tanaka K, et al. Differential crizotinib response duration among ALK fusion variants in ALK-positive non-small-cell lung cancer. *J Clin Oncol*. 2016;34(28):3383–3389.
3. Camidge DR, Bang YJ, Kwak EL, et al. Activity and safety of crizotinib in patients with ALK-positive non-small-cell lung cancer: updated results from a phase 1 study. *Lancet Oncol*. 2012;13(10):1011–1019.
4. Zhong J, Li L, Wang Z, et al. Potential resistance mechanisms revealed by targeted sequencing from lung adenocarcinoma patients with primary resistance to epidermal growth factor receptor (EGFR) tyrosine kinase inhibitors (TKIs). *J Thorac Oncol*. 2017;12(12):1766–1778.
5. Lin JJ, Shaw AT. Differential sensitivity to crizotinib: does EML4-ALK fusion variant matter? *J Clin Oncol*. 2016;34(28):3363–3365.

### OncoTargets and Therapy

### Publish your work in this journal

OncoTargets and Therapy is an international, peer-reviewed, open access journal focusing on the pathological basis of all cancers, potential targets for therapy and treatment protocols employed to improve the management of cancer patients. The journal also focuses on the impact of management programs and new therapeutic agents and protocols on

Submit your manuscript here: <http://www.dovepress.com/oncotargets-and-therapy-journal>

### Dovepress

patient perspectives such as quality of life, adherence and satisfaction. The manuscript management system is completely online and includes a very quick and fair peer-review system, which is all easy to use. Visit <http://www.dovepress.com/testimonials.php> to read real quotes from published authors.