

# Sacral (S1) herpes zoster

This article was published in the following Dove Press journal:  
*Journal of Pain Research*

Anca Chiriac<sup>1–3</sup>  
Anca E Chiriac<sup>4</sup>  
Adrian Naznean<sup>5</sup>  
Cosmin Moldovan<sup>6</sup>  
Cristian Podoleanu<sup>7</sup>  
Simona Stolnicu<sup>8</sup>

<sup>1</sup>The Department of Dermato-Physiology, Apollonia University, Iași, Romania; <sup>2</sup>Department of Dermatology, Nicolina Medical Center, Iași, Romania; <sup>3</sup>"P. Poni" Institute of Macromolecular Chemistry, Iași, Romania; <sup>4</sup>Department of Epidemiology, University of Medicine and Pharmacy "Grigore T Popa", Iași, Romania; <sup>5</sup>The Department of Foreign Languages, The University of Medicine and Pharmacy of Tîrgu Mureș, Tîrgu Mureș, Romania; <sup>6</sup>The Department of Applied Simulation in Medicine, The University of Medicine and Pharmacy of Tîrgu Mureș, Tîrgu Mureș, Romania; <sup>7</sup>The Department of Cardiology, The University of Medicine and Pharmacy of Tîrgu Mureș, Tîrgu Mureș, Romania; <sup>8</sup>The Department of Pathology, The University of Medicine and Pharmacy of Tîrgu Mureș, Tîrgu Mureș, Romania

**Abstract:** Herpes zoster usually affects the thoracic and lumbar vertebra (T3–L3), while sacral herpes zoster has been very rarely reported. We present a very rare case of herpes zoster involving S1 dermatome in a 35-year-old healthy man who presented aching pain and typical herpes zoster eruption on the lateral aspect of the calcaneus, lateral plantar area and dorsal aspect of digits III and IV.

**Keywords:** herpes zoster, S1, pain, sacral zoster

## Introduction

Herpes zoster affects the thoracic and lumbar nerves and dermatomes (T3–L3) in the majority of cases;<sup>1</sup> sacral herpes is very rare and it has been reported in only 4–8% of cases.<sup>2</sup> When herpes zoster virus affects sacral nerves S2–S3 (motor and sensory nerves of the bladder), urinary dysfunction is reported,<sup>2,3</sup> as well as constipation or bowel incontinence.<sup>4</sup> Sacral herpes zoster has been described in elderly or in patients with impaired immune system.<sup>2</sup>

We present a typical case of herpes zoster S1 type with zosteriform eruption within S1 dermatome, intense pain and we review the literature related to S1 herpes zoster.

## Case report

A 35-year-old previously healthy man was referred to the Dermatology Clinic for aching pain and clusters of vesicles located on the lateral aspect of the calcaneus, lateral plantar area and dorsal surface of digits III and IV (Figure 1). Pain and skin lesions had started 5 days and 1 day, respectively, before admission to hospital.

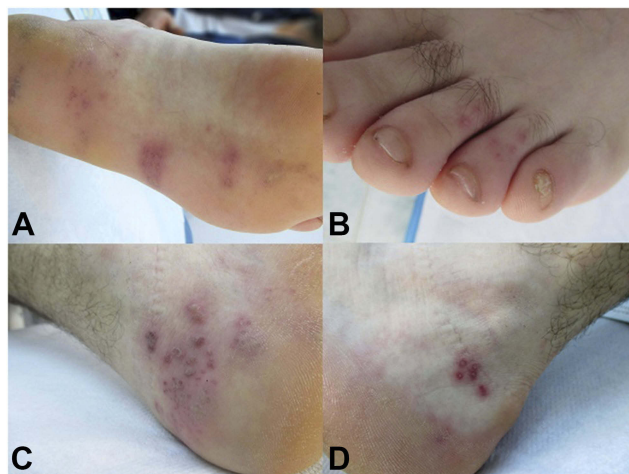Dermatological examination revealed painful erythematous grouped vesicles within S1 dermatome and clinical diagnosis of herpes zoster was made. Laboratory tests, including HIV and hepatitis serology, proved to be within normal limits. Anti-VZV IgM was negative, but anti-VZV IgG was positive. Ballooning multinucleated giant cells were cytological findings of Tzanck smear done from the lesion and confirmed herpes infection.

Systemic administration of acyclovir 3 g/day orally for 10 days and NSAIDs were recommended, with favorable evolution and no complications for short or long term.

## Discussion

Similar to other previous studies, a recent study confirms segmental involvement in herpes zoster related to epidemiology of herpes zoster: thoracic zoster 65.4%, cervical zoster 11.5%, lumbar zoster 8.3%, and sacral type only 3.5%.<sup>5</sup>

Correspondence: Adrian Naznean  
The Department of Foreign Languages,  
The University of Medicine and Pharmacy  
of Tîrgu Mureș, 38 Gheorghe Marinescu  
Street, Tîrgu Mureș, 540139, Romania  
Tel +40 2652 1551  
Email adinaznean@yahoo.com

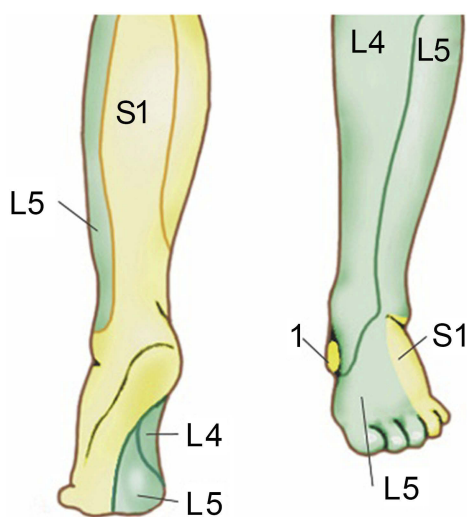


**Figure 1** Clusters of vesicles located on the lateral plantar area (A), dorsal surface of digits III and IV (B), lateral aspect of the calcaneus (C and D).

The person's immune status is a key factor in determining the risk of developing herpes zoster; this can be induced by contact with a person with varicella or by reactivation of the virus in latently infected individuals. The reactivation rate of herpes zoster virus correlates with the decrease of immunity and with age.<sup>6</sup>

Subclinical reactivation of the virus has been described in some patients in response to stress,<sup>7</sup> although, during lifetime, the immune system of the host contributes to the maintenance of immunity against herpes zoster virus.<sup>8</sup>

Sacral herpes zoster is rare and is usually located in S2–4 dermatome affecting the lower urinary tract,<sup>2–4</sup> penis and scrotum,<sup>9</sup> and rectum associated with constipation.<sup>10</sup>



**Figure 2** S1 dermatome area, anatomically delineated by the lateral aspect of the foot, the heel, and most of the sole; L4–5: lumbar dermatoma.

A case of restless legs syndrome was reported in association with herpes zoster affecting S1 and S2 dermatomes, with zosteriform lesions located on the left buttock and the posterior aspect of left lower limb in the presence of high titer of varicella zoster virus-specific IgM in the blood, but no strict correlation was accomplished.<sup>10,11</sup>

S1 dermatome is anatomically delineated by the lateral aspect of the foot, the heel, and most of the sole (Figure 2).

## Conclusion

The present case is a rare type of S1 herpes zoster.

## Ethical Approval

Ethical Approval was obtained from the Ethics Committee of Nicolina Medical Center, Iași.

Written informed consent has been provided by the patient to have the case details and any accompanying images published.

## Disclosure

The authors report no conflicts of interest in this work.

## References

- Whitley RJ. Varicella-Zoster virus infection. In: Longo DL, Fauci AS, Kasper DL, editors. *Harrison's Principles of Internal Medicine*, 18th ed. New York: McGraw-Hill; 2012:1462–1466.
- Hur J. Sacral herpes zoster associated with voiding dysfunction in a young patient with scrub typhus. *Infect Chemother*. 2015;47(2):133–136.
- Brossetta E, Osca JM, Morera J, Martinez-Agullo E, Jimenez-Cruz JF. Urological manifestations of herpes zoster. *Eur Urol*. 1993;24(2):244–247.
- Richmond W. The genito-urinary manifestations of herpes zoster. Three case reports and a review of the literature. *Br J Urol*. 1974;46(2):193–200.
- Aggarwal SK, Radhakrishnan S. A clinico-epidemiological study of herpes zoster. *Med J Armed Forces India*. 2016;72(2):175–177. doi:10.1016/j.mjafi.2015.05.003
- Cohrs RJ, Mehta SK, Schmid DS, Gilden DH, Pierson DL. Asymptomatic reactivation and shed of infectious varicella zoster virus in astronauts. *J Med Virol*. 2008;80(6):1116–1122. doi:10.1002/(ISSN)1096-9071
- Ogunjimi B, Smits E, Heynderickx S, et al. Influence of frequent infectious exposures on general and varicella-zoster virus-specific immune responses in pediatricians. *Clin Vaccine Immunol*. 2014;21(3):417–426. doi:10.1128/CVI.00818-13
- Marinelli I, van Lier A, de Melker H, Pugliese A, van Boven M. Estimation of age-specific rates of reactivation and immune boosting of the varicella zoster virus. *Epidemics*. 2017;19:1–12.
- Arshad AR, Alvi KY, Chaudhary AA. Herpes zoster involving penis and scrotum: an unusual occurrence. *J Coll Physicians Surg Pak*. 2015;25(3):218–219. doi:10.2014/JCPSP.218219
- Matsumoto H, Shimizu T, Tokushige S, Mizuno H, Igeta Y, Hashida H. Rectal ulcer in a patient with VZV sacral meningo-radicularitis (Elsberg syndrome). *Intern Med*. 2012;51(6):651–654.
- Ipekdağ H, Karadas O, Oz O, Ulas UH. Restless legs syndrome secondary to sacral zona zoster. *J Pain Symptom Manage*. 2011;41(4):e8–e11. doi:10.1016/j.jpainsymman.2010.11.007

**Journal of Pain Research****Dovepress****Publish your work in this journal**

The Journal of Pain Research is an international, peer reviewed, open access, online journal that welcomes laboratory and clinical findings in the fields of pain research and the prevention and management of pain. Original research, reviews, symposium reports, hypothesis formation and commentaries are all considered for publication. The manuscript

management system is completely online and includes a very quick and fair peer-review system, which is all easy to use. Visit <http://www.dovepress.com/testimonials.php> to read real quotes from published authors.

Submit your manuscript here: <https://www.dovepress.com/journal-of-pain-research-journal>