

Significant benefit of nivolumab combining radiotherapy in metastatic gallbladder cancer patient with strong PD-L1 expression: a case report

This article was published in the following Dove Press journal:
OncoTargets and Therapy

Weiwei Kong,^{1,2} Jia Wei,¹
Juan Liu,¹ Yudong Qiu,³
Jiong Shi,⁴ Jian He,⁵ Mu Su,⁶
Mingzhe Xiao,⁷ Baorui Liu¹

¹The Comprehensive Cancer Centre of Drum Tower Hospital, Medical School of Nanjing University & Clinical Cancer Institute of Nanjing University, Nanjing 210008, People's Republic of China;

²Department of Oncology of Yizheng Hospital, Nanjing Drum Tower Hospital Group, Yizheng 211400, People's Republic of China; ³Department of General Surgery, Drum Tower Hospital, Medical School of Nanjing University, Nanjing 210008, People's Republic of China; ⁴Department of Pathology, Drum Tower Hospital, Medical School of Nanjing University, Nanjing 210008, People's Republic of China; ⁵Department of Radiology, Drum Tower Hospital, Medical School of Nanjing University, Nanjing 210008, People's Republic of China; ⁶Department of Oncology, Nanjing Second People's Hospital, Nanjing 210003, People's Republic of China; ⁷The Medical Department, 3D Medicines Inc, Shanghai 201114, People's Republic of China

Background: Gallbladder cancer (GBC) is the main pathological type of biliary tract cancers. Due to its aggressive nature, GBC is usually diagnosed at advanced stages with limited therapeutic options and poor outcome, especially after failure of chemotherapy.

Case presentation: Herein, we report a recurrent metastatic GBC patient with strong programmed death-ligand 1 (PD-L1) expression ($\geq 50\%$) who obtained a significant response to radiotherapy combining nivolumab treatment.

Conclusions: To our knowledge this is the first case presenting significant nivolumab response in a Chinese GBC patient. This remarkable response was most likely associated with the strong PD-L1 expression, and indicated that PD-L1 expression could be considered as a biomarker for nivolumab treatment in metastatic gallbladder cancer. However, more studies are needed for validation.

Keywords: immunotherapy, radiotherapy, PD-L1, biomarker, gall bladder cancer (GBC)

Introduction

GBC is the main pathological type of biliary tract cancers (BTC), accounting for 1.23% new cases and 1.45% mortalities of all cancers in the People's Republic of China.¹ Detection of early-stage GBC remains difficult. GBC is usually discovered incidentally at surgery or pathologic examination at advanced stage. Therapeutic options for advanced GBC are limited and the outcome is poor. The 5-year survival rate was only 5% for stage III patients and 1% for stage IV patients.² According to the latest National Comprehensive Cancer Network (NCCN) guidelines for hepatobiliary cancer, first-line therapies for metastatic GBC included chemotherapy regimens and pembrolizumab treatment for microsatellite instability high (MSI-H) patients. No standard therapeutic options were available as second or beyond lines of therapies for advanced GBC patients.

Immunotherapy such as programmed cell death 1 (PD-1)/programmed death-ligand 1 (PD-L1) inhibitors treatment, had emerged as prospective therapeutics in multiple solid tumors. Several clinical trials were conveyed in BTC as well and obtained promising results in second-line therapy, such as the KEYNOTE 028 trial, KEYNOTE 158 trial and one phase II trial of Nivolumab.³⁻⁵ Objective response rate (ORR) of immunotherapy was only around 20% in unselected patients with malignant solid tumors.⁶ Population with immunotherapy-favoring biomarkers such as PD-L1

Correspondence: Baorui Liu
The Comprehensive Cancer Centre of Drum Tower Hospital, The Affiliated Drum Tower Clinical College of Nanjing Medical University, Nanjing 210008, People's Republic of China
Tel +1 385 145 7357
Email baoruiliu_xmz@163.com

expression positive, tumor mutation burden (TMB) high and microsatellite instability-high/mismatch repair-deficient (MSI-H/dMMR) may obtain better clinical response compared with biomarker-negative subpopulations.⁷ Nowadays, data of clinical trials of immunotherapies in Chinese GBC patients are insufficient. Potential predictors of drug efficacy are also in urgent need of further exploration. Herein, we report a recurrent metastatic GBC patient with strong PD-L1 expression ($\geq 50\%$) who obtained significant response to Nivolumab treatment.

Case presentation

In November, 2015, a 69-year-old female patient was admitted to Nanjing Second Hospital and received radical resection of gallbladder cancer. Postoperative pathology indicated a T3N0M0 adenocarcinoma with moderate differentiation (Figure 1A). The patient recovered well after surgery and received no anticancer regimens. Regular follow-up visits were performed. In May 2017, positron emission tomography/computed tomography (PET/CT) results revealed tumor recurrence with the right adrenal metastasis and local intrahepatic metastasis (Figure 1B). The patient was then admitted to our hospital, and the treatment plan, the curative effect and adverse reactions were evaluated through a multiple disciplinary team (MDT).

From June 2017, this patient received radiotherapy (DT 60Gy/12f in tumor area and DT 30Gy/12f in prevention area) followed up by concurrent gemcitabine + capecitabine chemotherapy as first-line therapy. After six cycles of chemotherapy, the patient reached a best response of stable disease (SD). Progressive disease (PD) was observed in left kidney and lymph node in April 2018. Two cycles of GEMOX (gemcitabine combined with oxaliplatin) regimen chemotherapy was taken as second-line therapy since April 2018. Unfortunately, the disease progressed quickly with a new left hip metastasis. Third line palliative radiotherapy (total dose 30Gy/10f) was used for left hip lesions and disease progression was observed again with new occupancies in liver and lung in July, 2018.

To seek other potential therapeutic opportunities, the patient received next generation sequencing (NGS) analysis using a 381-gene panel (provide by 3D Medicines Inc.) and immunohistochemistry (IHC) detection of PD-L1 expression. NGS results indicated that the tumor mutation burden (TMB) was 4.03 Mutants/Mb (Table 1) and the microsatellite state was stable (Table 1). IHC results indicated that the PD-L1 expression was 50% (Figure 2). TMB was defined as the number of somatic mutations per million bases in

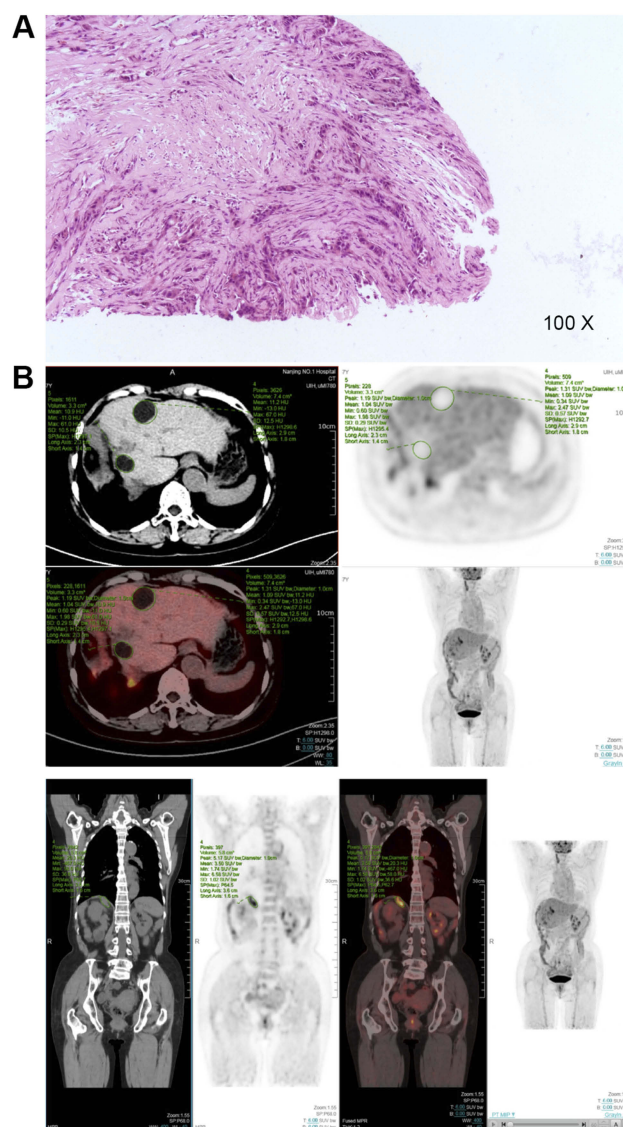


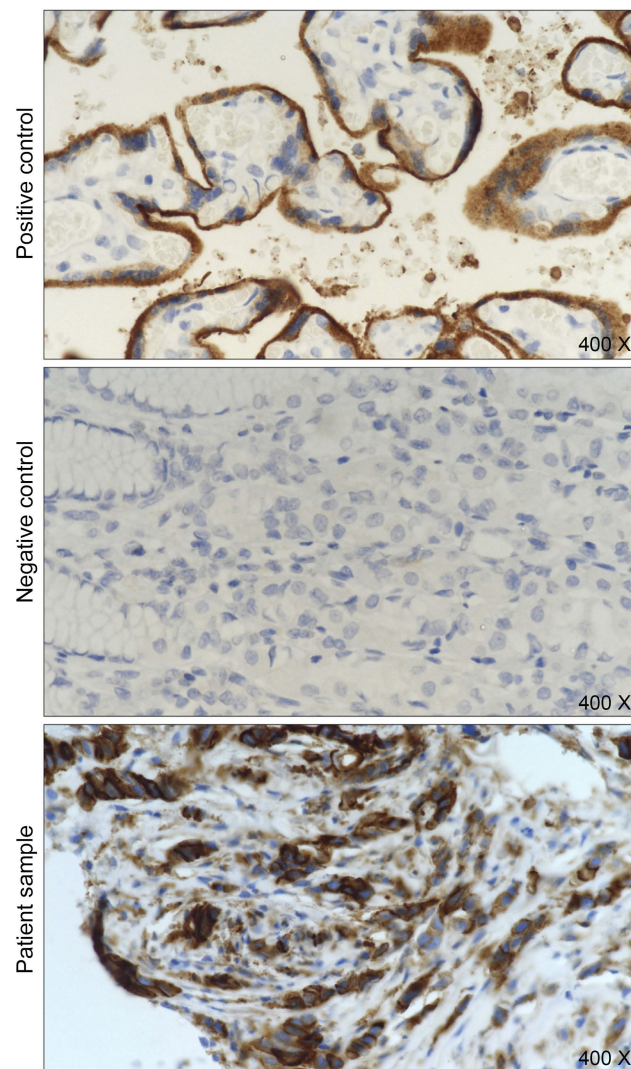
Figure 1 Pathology or PET/CT images of primary and recurrent tumor tissues. (A) Pathology of postoperative samples, indicating moderately differentiated adenocarcinoma. (B) PET/CT results indicating oligo metastasis within the liver and in the right adrenal gland.

sequenced coding region. No other immunotherapy-related biomarkers were identified (Table 2).

Combination of radiotherapy and immunotherapy was then considered. Hypofractionated helical tomotherapy (total dose 60Gy/12f) was administrated to new metastases in the left lobe of the liver, and the patient has received four times of nivolumab therapy (120 mg, every 2 weeks) since September 2018. Metastases in retroperitoneal lymph nodes, left hip and lung all disappeared. Lesions in liver and left kidney received significant response to the treatment (Figure 3). The patient was still alive with a progression free survival (PFS) exceeding 6 months, and no adverse events were observed.

Table 1 Tumor mutation burden and microsatellite instability state

Item	Result
TMB (mutants/Mb)	4.03
Microsatellite	Stable

**Figure 2** The patient with PD-L1 strong expression. Immunohistochemical staining of PD-L1 expression. The PD-L1 expression of the patient sample was 50%. PD-L1 was stained by VENTANA PD-L1 (SP263) Assay kit following the manufacturer's instructions. Positive control and negative control were provided by the kit, indicating PD-L1-expressing and non-PD-L1-expressing tissues, respectively. The "patient sample" was paraffin section of FFPE-embedded tumor sample.

Discussion and conclusion

In this case, the patient with strong PD-L1 expression ($\geq 50\%$) responded deeply to nivolumab immunotherapy after failure of multiple lines of therapies. To our knowledge, this is the first case presenting significant nivolumab response in an advanced GBC patient in the People's Republic of China.

Table 2 Gene mutation list

Gene name	Mutation
ATM	p.H1384Rfs*3 Exon28
ARID1A	p.A360Efs*37 Exon1
EPHA2	p.M689Ifs*2
UGT1A1	p.G71R c.211G>A rs4148323 *6
CYP2C19	p.P227P c.681G>A rs4244285 *2

PD-L1 expression has been considered as an immunotherapy biomarker in NSCLC, melanoma and many other solid tumors, and the expression level was associated with efficacy.^{6,8} In KEYNOTE 028 trial, PD-L1+ ($\geq 1\%$) BTC patients reached an ORR of 17.4%.³ In KEYNOTE 158 trial, the ORR was 6.6% vs 2.9% in PD-L1+ ($\geq 1\%$) vs PD-L1- ($< 1\%$) BTC patients, respectively. In one phase II trial, nivolumab reached an ORR of 18.5%, irrespective of PD-L1 expression, however, subgroup analysis of different PD-L1 expression stratifications were not performed.⁴ Based on the three clinical trials mentioned above, whether PD-L1 expression is a biomarker for BTC immunotherapy is still uncertain, especially for nivolumab. In our case, the patient bore strong PD-L1 expression ($\geq 50\%$) and obtained significant benefit from nivolumab treatment, which might indicate that PD-L1 expression could be a potential biomarker in GBC immunotherapy.

According to a secondary analysis of KEYNOTE 001 trial and other clinical evidences, previous radiotherapy (RT) may enhance PFS and overall survival (OS) in patients receiving immunotherapy.^{9,10} This is presumably because tumor cells damaged by RT could release antigens that could serve as adaptive immune response targets and enhance immune response. In this case, we applied hypofractionated radiotherapy on liver lesions, which indeed lead to enhanced immunogenicity and better immunotherapy response. This synergetic effect between RT and immunotherapy might also contribute to the significant response to nivolumab in this patient.

In clinical trial CHECKMATE 026 and CHECKMATE 227, compared with TMB-middle and TMB-low patients, TMB-high subpopulation received better clinical outcomes.^{11,12} MSI-H/dMMR, another potential biomarker of immunotherapy, showed a significantly higher response vs MSS (microsatellite stable) or pMMR solid tumors.¹³ In our case, the TMB was merely middle and the microsatellites were stable, thus we speculated that strong PD-L1 expression is the main reason for the deep response.

To our knowledge, this is the first case describing a strong PD-L1 positive GBC patient who received

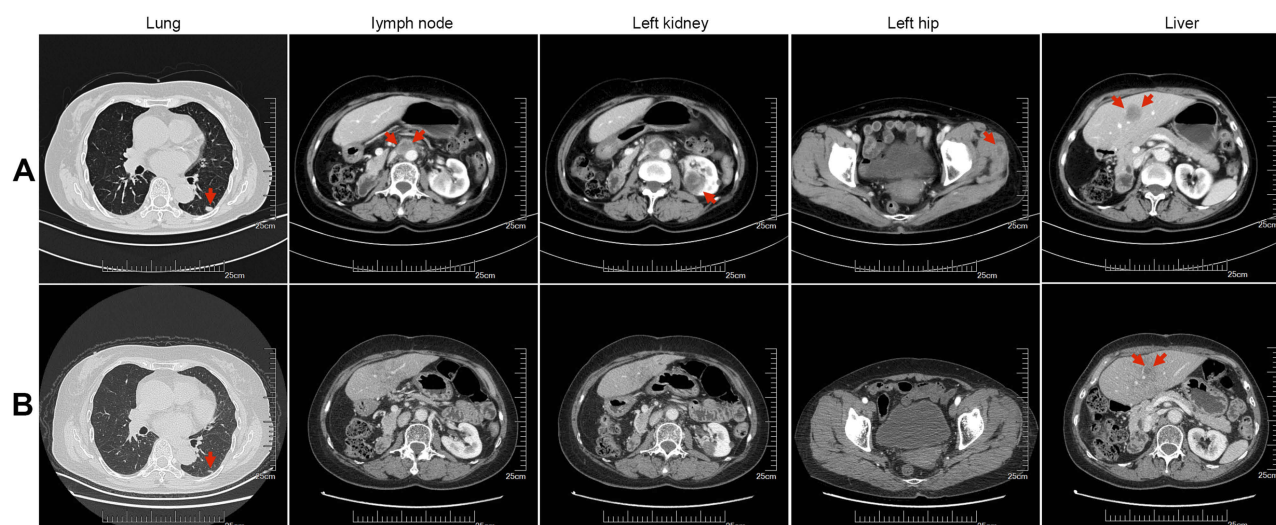


Figure 3 Computed tomography scan shows different lesions in lung, lymph node, left kidney, liver, and left hip during immunotherapy. (A) Lesions before immunotherapy are indicated by arrows. (B) Lesions after immunotherapy are indicated by arrows.

a significant response to nivolumab treatment. This case indicated that PD-L1- or PD-1-based immunotherapies may bring new treatments for recurrent metastatic GBC patients, especially in those with strong PD-L1 expression. Still, more studies are needed to validate this finding.

Ethics approval and consent for publication

This research was approved by the research ethics committee of The Comprehensive Cancer Centre of Drum Tower Hospital, and written informed consent for publication of the clinical details and images was obtained from the patient.

Acknowledgments

This work was supported by the Program of The National Key Research and Development Program of China [grant number 2017YFC1308900]; the Program of Jiangsu Provincial Key Medical Center [grant number YXZXB2016002]. The funding sources had no role in the study design, data collection, data analysis, data interpretation, or writing of the report.

Author contributions

All authors made substantial contributions to conception and design, acquisition of data, or analysis and interpretation of data; took part in drafting the article or revising it critically for important intellectual content; gave final approval of the version to be published; and agree to be accountable for all aspects of the work.

Disclosure

The authors report no conflicts of interest in this work.

References

- Chen W, Zheng R, Baade PD, et al. Cancer statistics in China, 2015. *CA Cancer J Clin*. 2016;66(2):115–132. doi:10.3322/caac.21338
- Donohue JHISA, Menck HR. The National Cancer Data Base report on carcinoma of the gallbladder, 1989–1995. *Cancer*. 1998;83(12):2618–2628.
- Bang YJ, Doi T, Braud FD, et al. 525 safety and efficacy of pembrolizumab (MK-3475) in patients (pts) with advanced biliary tract cancer: interim results of KEYNOTE-028. *Eur J Cancer*. 2015;51:S112. doi:10.1016/S0959-8049(16)30326-4
- Kim R, Kim D, Alese O, et al. O-009A Phase II multi institutional study of nivolumab in patients with advanced refractory biliary tract cancers (BTC). *Ann Oncol*. 2018;29(suppl_5):mdy149.008-mdy149.008.
- Ueno M, Chung HC, Nagrial A, et al. 625PDPembrolizumab for advanced biliary adenocarcinoma: results from the multicohort, phase II KEYNOTE-158 study. *Ann Oncol*. 2018;29(suppl_8):mdy282.009-mdy282.009. doi:10.1093/annonc/mdy282.009
- Teng F, Meng X, Kong L, Yu J. Progress and challenges of predictive biomarkers of anti PD-1/PD-L1 immunotherapy: a systematic review. *Cancer Lett*. 2018;414:166–173. doi:10.1016/j.canlet.2017.11.014
- Yarchoan M, Hopkins A, Jaffee EM. Tumor mutational burden and response rate to PD-1 inhibition. *N Engl J Med*. 2017;377(25):2500–2501. doi:10.1056/NEJMc1713444
- Herbst RSBP, Kim DW, Felip E, et al. Pembrolizumab versus docetaxel for previously treated, PD-L1-positive, advanced non-small-cell lung cancer (KEYNOTE-010): a randomised controlled trial. *Lancet*. 2016;387(10027):P1540–P1550. doi:10.1016/S0140-6736(15)01281-7
- Chajon E, Castelli J, Marsiglia H, De Crevoisier R. The synergistic effect of radiotherapy and immunotherapy: a promising but not simple partnership. *Crit Rev Oncol Hematol*. 2017;111:124–132. doi:10.1016/j.critrevonc.2017.01.017
- Shaverdian N, Lisberg AE, Bormazyan K, et al. Previous radiotherapy and the clinical activity and toxicity of pembrolizumab in the treatment of non-small-cell lung cancer: a secondary analysis of the KEYNOTE-001 phase 1 trial. *Lancet Oncol*. 2017;18(7):895–903. doi:10.1016/S1470-2045(17)30380-7

11. Carbone DP, Reck M, Paz-Ares L, et al. First-line nivolumab in stage IV or recurrent non-small-cell lung cancer. *N Engl J Med*. 2017;376(25):2415–2426. doi:10.1056/NEJMoa1613493
12. Hellmann MD, Ciuleanu TE, Pluzanski A, et al. Nivolumab plus ipilimumab in lung cancer with a high tumor mutational burden. *N Engl J Med*. 2018;378(22):2093–2104. doi:10.1056/NEJMoa1801946
13. Le DT, Durham JN, Smith KN, et al. Mismatch repair deficiency predicts response of solid tumors to PD-1 blockade. *Science*. 2017;357(6349):409–413. doi:10.1126/science.aan6733

OncoTargets and Therapy

Dovepress

Publish your work in this journal

OncoTargets and Therapy is an international, peer-reviewed, open access journal focusing on the pathological basis of all cancers, potential targets for therapy and treatment protocols employed to improve the management of cancer patients. The journal also focuses on the impact of management programs and new therapeutic

agents and protocols on patient perspectives such as quality of life, adherence and satisfaction. The manuscript management system is completely online and includes a very quick and fair peer-review system, which is all easy to use. Visit <http://www.dovepress.com/testimonials.php> to read real quotes from published authors.

Submit your manuscript here: <https://www.dovepress.com/oncotargets-and-therapy-journal>