

Successful treatment with osimertinib and its subsequent resistance mechanism in a patient with non-small-cell lung cancer harboring acquired EGFR T790M mutation after recovery from AC0010-induced interstitial lung disease

This article was published in the following Dove Press journal:
OncoTargets and Therapy

Hanping Wang¹
Li Zhang¹
Xiaohua Shi²
Xiaotong Zhang¹
Xiaoyan Si¹

¹Department of Respiratory Medicine, Peking Union Medical College Hospital, Beijing 100730, People's Republic of China; ²Department of Pathology, Peking Union Medical College Hospital, Beijing 100730, People's Republic of China

Objective: Treatment with epidermal growth factor receptor tyrosine kinase inhibitors (EGFR-TKIs) can occasionally lead to interstitial lung disease (ILD), and the appropriate treatment after recovery from ILD remains controversial. AC0010 is an investigational third-generation TKI used in China to selectively target the T790M mutation. Here, we describe a patient who developed ILD after AC0010 treatment and was then successfully re-challenged with osimertinib.

Methods: The patient was a 67-year-old male with a diagnosis of metastatic pulmonary adenocarcinoma with an L858R mutation on exon 21. Acquired T790M mutation was confirmed by re-biopsy after progression on erlotinib treatment. The patient was treated with AC0010, and developed ILD 54 days after treatment initiation. Following his recovery from ILD, osimertinib (80 mg/day) was administered with no adverse effects. After progression on osimertinib 11 months later, a histological transformation from adenocarcinoma to large-cell neuroendocrine carcinoma was confirmed by re-biopsy, with a marked increase in serum neuron-specific enolase.

Conclusions: This is the first report of interstitial pneumonitis caused by AC0010. Osimertinib re-challenge after recovery from ILD was a safe and effective treatment option. Our report further highlights that pathological transformation of large-cell neuroendocrine carcinoma represents one of the resistance mechanisms of osimertinib, and may be accompanied by an increase in serum neuron-specific enolase.

Keywords: osimertinib, AC0010, interstitial lung disease, resistance mechanism, transformation, large-cell neuroendocrine carcinoma

Introduction

Epidermal growth factor receptor tyrosine kinase inhibitors (EGFR TKIs) have survival benefits and a favorable safety profile in patients with metastatic non-small-cell lung cancer with EGFR sensitive mutations (mainly 19del or 21L858R mutation). However, severe adverse effects including interstitial lung disease (ILD) can occasionally result from the use of these inhibitors.¹ Following recovery from ILD, the appropriate treatment option remains unclear. Among first-generation TKIs, given the variety of drugs available, patients typically switch to another

Correspondence: Li Zhang
Department of Respiratory Medicine,
Peking Union Medical College Hospital,
1 Shuai Fu Yuan, Dong Cheng District,
Beijing 100730, People's Republic of China
Tel +86 106 915 8760
Fax +86 106 915 5039
Email zhanglipumch1026@sina.com

TKI, although some patients are re-challenged with the previously used TKI.² AC0010 is a novel third-generation TKI that selectively targets the T790M mutated EGFR and is currently under clinical investigation in China.³ Here, we report the case of a patient who developed ILD after AC0010 treatment and was subsequently successfully re-challenged with osimertinib (Figure 1A). The patient later developed resistance to osimertinib via a unique resistance mechanism.

Case description

A 67-year-old male patient with EGFR 21 exon L858R-positive metastatic lung adenocarcinoma showed disease progression after erlotinib treatment (progression-free survival [PFS] 8.0 months). Amplification-refractory mutation system PCR in re-biopsied tumor tissue confirmed the T790M-positive mutation, so the patient was enrolled to a phase I

trial of AC0010 (NCT02330367). The evaluated response after 1 month showed stable disease. On day 54 of AC0010 treatment, the patient began to experience dyspnea, cough, and fever. Chest computerized tomography scanning showed diffuse ground-glass opacification in the lung (Figure 1B), while the cancer lesion and malignant pleural effusion remained stable. Etiological examination in sputum and plasma returned negative results. The patient was diagnosed with AC0010-induced acute ILD and was treated with methylprednisolone (80 mg per day initially; gradually decreased thereafter) and empirical antibiotics.

Following recovery from ILD, pemetrexed was administered, resulting in severe myelosuppression. Osimertinib (80 mg per day) was subsequently administered under close monitoring and resulted in partial remission (Figure 1B) without any adverse effects. PFS was 11 months.

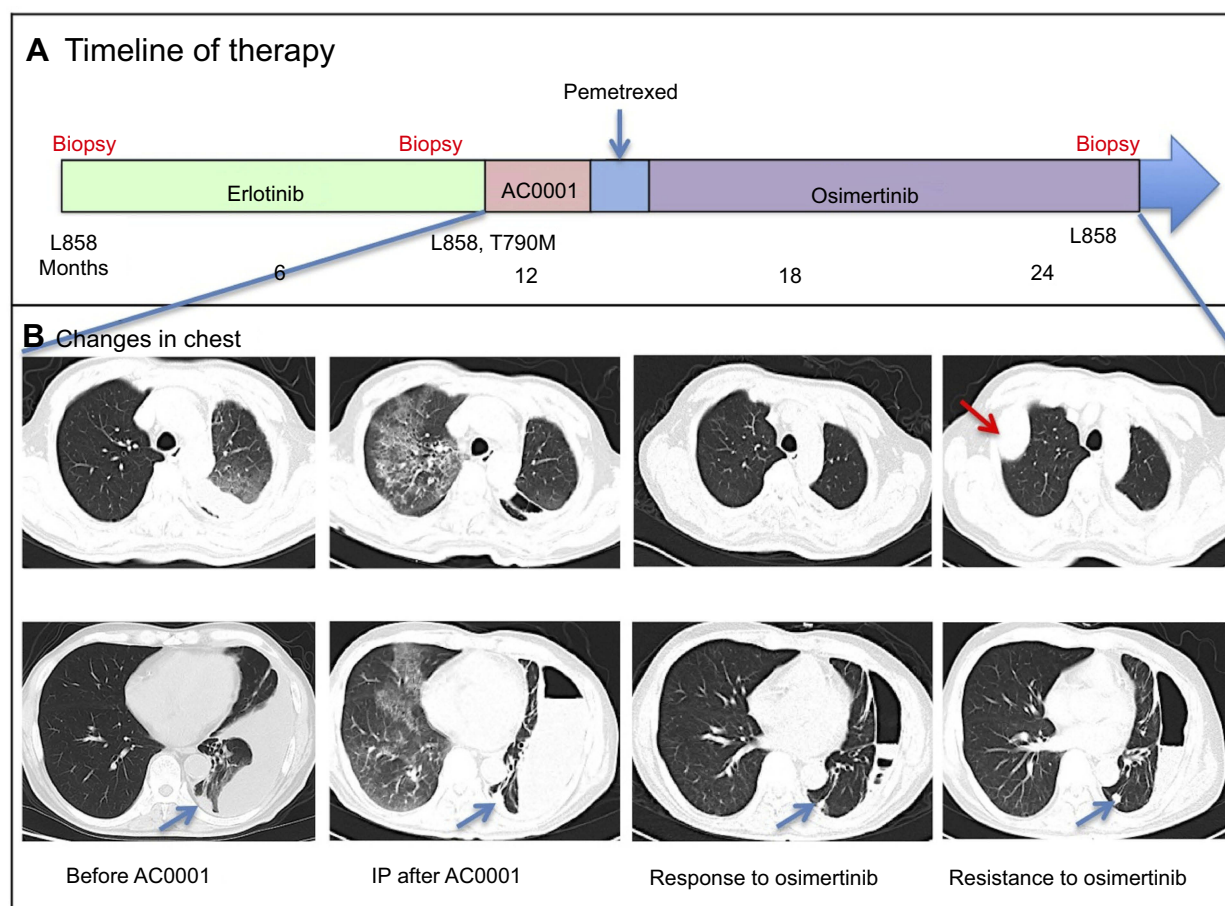


Figure 1 Interstitial pneumonitis induced by AC0010 and successful treatment with osimertinib after recovery. **(A)** Treatments received by the patient and the duration of each treatment. **(B)** Chest computerized tomography (CT) images prior to administration of AC0010, during interstitial pneumonitis induced by AC0010, during the response to subsequent treatment with osimertinib, and following subsequent disease relapse at 11 months. The patient's interstitial pneumonitis presented as diffuse ground-glass opacity in the lung. His left pleural effusion remained stable during treatment with AC0010, but markedly decreased during treatment with osimertinib, the nodules in the lower left lung (blue arrows) also shrank. A soft mass (red arrow) was identified following progression with osimertinib after 11 months.

Following re-biopsy after progression on osimertinib, pathological examination showed a histological transformation from adenocarcinoma to large-cell neuroendocrine carcinoma (Figure 2). Meanwhile, the level of neuron-specific enolase (NSE) in serum was markedly increased

(Figure 3), indicating neuroendocrine neoplasia,⁴ while next-generation sequencing (NGS) -based liquid biopsy showed EGFR 21L858R mutation (the allelic frequency was 7.9%) without T790M mutation. No other gene variation with clear clinical significance was identified.

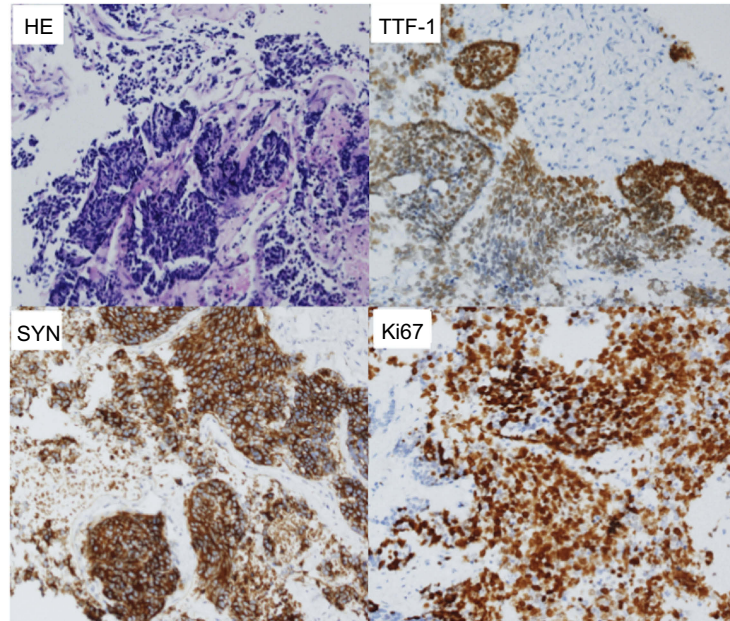


Figure 2 Histopathological and immunophenotypic evolution of re-biopsied tissue after progression with osimertinib. Hematoxylin-eosin (HE) staining revealed undifferentiated large cell carcinoma. Immunohistochemical staining for synaptophysin (SYN) revealed strong positivity. Staining for thyroid transcription factor I (TTFI) was also positive, and staining for Ki-67 showed 80% positivity.

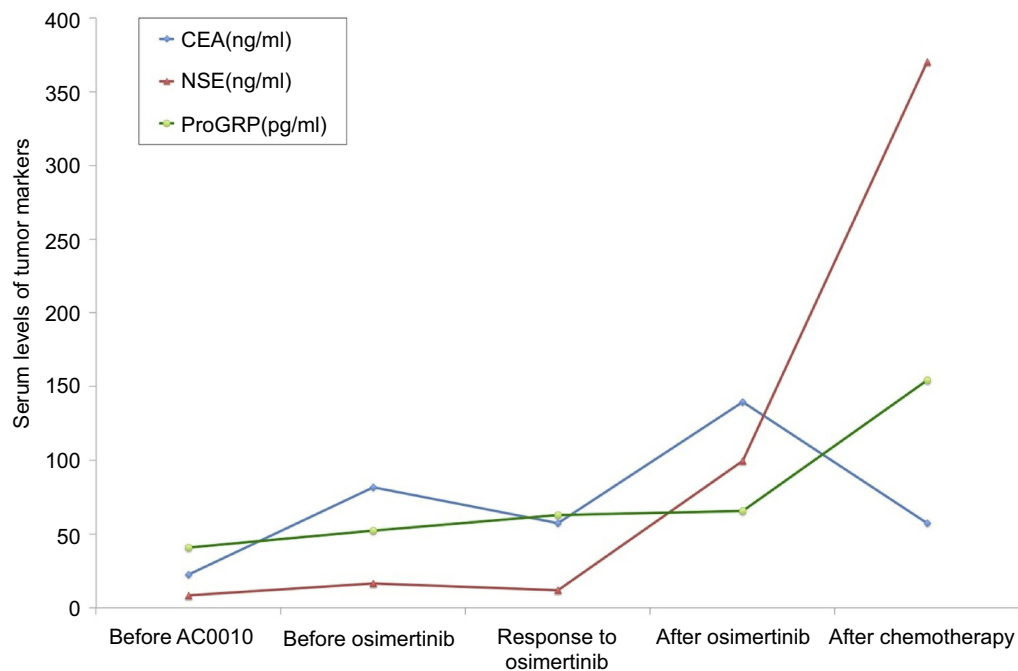


Figure 3 Changes in serum tumor markers. Serial monitoring of the levels of carcinoembryonic antigen (CEA), neuronal specific enolase (NSE), and pro-gastrin-releasing peptide (ProGRP) showed that the level of NSE was markedly increased during progression on osimertinib.

Discussion

The incidence of ILD associated with first- and third-generation EGFR TKI treatment has been reported as 1–5%.² In the AURA3 trial, 10 cases of pneumonia (4%) were reported, of which one was fatal.⁵ The diagnosis of TKI related ILD is dependent on the history of medication, new interstitial disease in chest imaging, and exclusion of infection and tumor progression, and most patients recover with timely glucocorticoid therapy.¹

Subsequent antitumor treatment options are limited; however, successful switching from one first-generation EGFR TKI to another because of severe adverse effects has been reported.² Osimertinib is the only globally approved third-generation EGFR T790M inhibitor. Successful re-challenge with osimertinib after recovery from ILD related to osimertinib has been reported in several cases in non-small-cell lung cancer.⁶ However, re-challenge with the previously used drug may lead to recurrence of ILD.² AC0010 is used in China as a novel third-generation EGFR TKI target of the T790M mutation, and has demonstrated initial efficacy in a phase I trial.³ As shown in our patient, however, it can also induce severe ILD, and subsequent osimertinib therapy achieved better efficacy and prolonged PFS without the recurrence of ILD. This observation indicates that these two third-generation TKIs do not share common toxicities, with osimertinib appearing to be more effective.

Although the mechanisms of resistance to osimertinib appear to be highly heterogeneous, no dominant mechanism has been identified to date. Transformation of cell types can be found in resistance to both first- and third-generation TKIs, and mostly involves transformation from adenocarcinoma to small-cell lung cancer.⁷ Transformation from adenocarcinoma to large-cell neuroendocrine carcinoma is extremely rare, and cases reported to date as an acquired resistance mechanism to EGFR TKIs are summarized in Table 1. In the majority of these cases, the transformation occurred following treatment with a first-generation TKI, while only two cases (included the present case) have shown transformation after osimertinib.

We noted that one case with pathological type transformation accompanied by T790M mutation loss. Similarly, our patients also have T790M loss. We hypothesized that the loss of T790M mutation was an accompanying resistance mechanism during cell type transformation. Subsequent treatment is challenging for these patients, and histopathological biopsy is instrumental in diagnosing the transformation. We found that the NSE level was markedly

Table 1 Reported cases of large-cell neuroendocrine carcinoma transformation as an acquired resistance mechanism to EGFR TKI in patients with non-small-cell lung cancer with initial EGFR sensitive mutation (19del or 21L858R mutation)

Study	Patient (Age/Sex)	1st Biopsy	Prior EGFR TKI	2nd Biopsy		Subsequent therapy	3rd Biopsy		Subsequent therapy
		Pathology/ EGFR	TKIs/PFS (M)	Pathology/EGFR			Pathology/EGFR		
Yanagisawa et al ⁸	46/M	Adeno./19del	Gefitinib/24Ms	LCNEC/19del	LCNEC/19del	Unknown			
Lim et al ⁹	33/M	Adeno./19del	Erlotinib/10Ms	LCNEC+Adeno/NA	LCNEC+Adeno/NA	Etoposide-Cisplatin			
Kogo et al ¹⁰	68/M	Adeno./L858	Gefitinib/11Ms	LCNEC/L858	LCNEC/L858	Irinotecan			
Moriya et al ¹¹	58/F	Adeno./19del	Gefitinib/96Ms	LCNEC+Adeno./19del	LCNEC+Adeno./19del	None			
Baglivo et al ¹²	57/M	Adeno./19del	Erlotinib/48Ms	Adeno./19del+T790M	Adeno./19del+T790M	Osimertinib (1M)*	LCNEC+Adeno./19del	None	None
Ricordel et al ¹³	57/M	Adeno./19del	Gefitinib/11Ms	Adeno./19del+T790M	Adeno./19del+T790M	Osimertinib (10M)	LCNEC/19del+T790M	Radiation therapy + Osimertinib	Radiation therapy + Osimertinib
Present case	67/M	Adeno./L858	Erlotinib/8M	Adeno./L858+T790M	Adeno./L858+T790M	Osimertinib(11M)	LCNEC/L858	Radiofrequency ablation + Etoposide-Carboplatin	Radiofrequency ablation + Etoposide-Carboplatin

Notes: *The patient was diagnosed with large-cell neuroendocrine carcinoma transformation after 1 month of osimertinib treatment, indicating that the transformation was a resistance mechanism of erlotinib rather than of osimertinib.

Abbreviations: Adeno., adenocarcinoma; LCNEC, large-cell neuroendocrine carcinoma; EGFR TKI, epidermal growth factor receptor tyrosine kinase inhibitors; PFS, progression-free survival.

increased during progression on osimertinib, indicating that NSE detection may represent cell-type transformation.⁴ However, NGS-based liquid biopsy in plasma did not identify any characteristics or specific targets, except for retention of the initial EGFR mutation.

Conclusions

This is the first report of interstitial pneumonitis caused by AC0010, a novel third-generation EGFR TKI that selectively targets the T790M mutated EGFR. Re-challenge with osimertinib after recovery from ILD was successful, and represents a safe and effective treatment option for this patient population. Our case also shows that pathological transformation of large-cell neuroendocrine carcinoma is one of the resistance mechanisms of osimertinib. In addition to pathological detection, increased serum NSE may indicate pathological transformation.

Acknowledgments

We thank Clare Cox, PhD, from Edanz Group for editing a draft of this manuscript. As the patient is now deceased, written informed consent for publication of the case details was provided by his son. An institutional approval was not required for a case report. This research did not receive any specific grant from funding agencies in the public, commercial, or not-for-profit sectors.

Disclosure

The authors report no conflicts of interest in this work.

References

- Schwaiblmair M, Behr W, Haeckel T, et al. Drug induced interstitial lung disease. *Open Respir Med J*. 2012;6:63–74. doi:10.2174/1874306401206010063

- Kashiwabara K, Semba H, Fujii S, et al. Outcome in advanced non-small cell lung cancer patients with successful rechallenge after recovery from epidermal growth factor receptor tyrosine kinase inhibitor-induced interstitial lung disease. *Cancer Chemother Pharmacol*. 2017;79:705–710. doi:10.1007/s00280-017-3261-5
- Ma Y, Zheng X, Zhao H, et al. First-in-Human Phase I Study of AC0010, a mutant-selective EGFR inhibitor in non-small cell lung cancer: safety, efficacy, and potential mechanism of resistance. *J Thorac Oncol*. 2018;13:968–977. doi:10.1016/j.jtho.2018.03.025
- Isgrò MA, Bottoni P, Scatena R. Neuron-specific enolase as a biomarker: biochemical and clinical aspects. *Adv Exp Med Biol*. 2015;867:125–143.
- Mok TS, Wu YL, Ahn MJ, et al. Osimertinib or platinum-pemetrexed in EGFR T790M-positive lung cancer. *N Engl J Med*. 2017;376:629–640. doi:10.1056/NEJMoa1612674
- Satoh S, Shiroyama T, Tamiya M, et al. Successful osimertinib rechallenge after osimertinib-induced pneumonitis in a patient with lung adenocarcinoma. *Respir Med Case Rep*. 2018;23:68–70. doi:10.1016/j.rmcr.2017.12.005
- Marcoux N, Gettinger SN, O’Kane G, et al. EGFR-mutant adenocarcinomas that transform to small-cell lung cancer and other neuroendocrine carcinomas: clinical outcomes. *J Clin Oncol*. 2019;37(4):278–285. doi:10.1200/JCO.18.01585
- Yanagisawa S, Morikawa N, Kimura Y, et al. Large-cell neuroendocrine carcinoma with epidermal growth factor receptor mutation: possible transformation of lung adenocarcinoma. *Respirology*. 2012;17(8):1275–1277. doi:10.1111/j.1440-1843.2012.02258.x
- Lim JU, Woo IS, Jung YH, et al. Transformation into large-cell neuroendocrine carcinoma associated with acquired resistance to erlotinib in nonsmall cell lung cancer. *Korean J Intern Med*. 2014;29(6):830–833. doi:10.3904/kjim.2014.29.6.830
- Kogo M, Shimizu R, Uehara K, et al. Transformation to large cell neuroendocrine carcinoma as acquired resistance mechanism of EGFR tyrosine kinase inhibitor. *Lung Cancer*. 2015;90(2):364–368. doi:10.1016/j.lungcan.2015.09.002
- Moriya R, Hokari S, Shibata S, et al. Histological transformation to large cell neuroendocrine carcinoma from lung adenocarcinoma harboring an EGFR mutation: an autopsy case report. *Intern Med*. 2017;56(15):2013–2017. doi:10.2169/internalmedicine.56.7802
- Baglivo S, Ludovini V, Sidoni A, et al. Large cell neuroendocrine carcinoma transformation and EGFR-T790M mutation as coexisting mechanisms of acquired resistance to EGFR-TKIs in lung cancer. *Mayo Clin Proc*. 2017;92(8):1304–1311. doi:10.1016/j.mayocp.2017.03.022
- Ricordel C, Llamas-Gutierrez F, Chiforeanu D, et al. Large cell neuroendocrine lung carcinoma transformation as an acquired resistance mechanism to osimertinib. *J Thorac Oncol*. 2017;12(11):e184–e186.

OncoTargets and Therapy

Publish your work in this journal

OncoTargets and Therapy is an international, peer-reviewed, open access journal focusing on the pathological basis of all cancers, potential targets for therapy and treatment protocols employed to improve the management of cancer patients. The journal also focuses on the impact of management programs and new therapeutic

agents and protocols on patient perspectives such as quality of life, adherence and satisfaction. The manuscript management system is completely online and includes a very quick and fair peer-review system, which is all easy to use. Visit <http://www.dovepress.com/testimonials.php> to read real quotes from published authors.

Submit your manuscript here: <https://www.dovepress.com/oncotargets-and-therapy-journal>

Dovepress