

The role of herpesviruses in ocular infections

Asim V Farooq¹
Arpeet Shah¹
Deepak Shukla²

¹Department of Ophthalmology and Visual Sciences, ²Department of Microbiology and Immunology, College of Medicine, University of Illinois at Chicago, Chicago, IL, USA

Abstract: Ocular infections caused by herpesviruses are an important cause of morbidity. The majority of cases are believed to be associated with herpes simplex virus type-1 (HSV-1), although HSV-2, varicella zoster virus (VZV), cytomegalovirus (CMV) and Epstein–Barr virus (EBV) are also associated with various ocular diseases. The ability of some herpes viruses to infect various anatomic regions of the eye may be facilitated by entry processes that are cell-type specific, and in many cases may occur more frequently in the immunocompromised. The elimination of the role of herpesviruses in ocular disease remains elusive, as they often develop life-long latency in a large proportion of humans. Experimental vaccines for ocular HSV have shown some benefit in animal models, a result that has not been adequately demonstrated in clinical trials. Meanwhile, ocular involvement in VZV remains unpredictable, and CMV retinitis continues to be an important cause of blindness in those infected by HIV.

Keywords: ocular herpes, viral entry, antivirals, epidemiology, seroprevalence, ocular lymphomas, viral vaccine

Introduction

The *Herpesviridae* are a family of double-stranded DNA viruses containing at least twenty-five members, eight of which are known to infect humans (summarized in Table 1).^{1–9} Their basic structure includes an icosahedral capsid surrounded by a layer of proteins and mRNAs known as the tegument, which is encased by a lipid bilayer envelope containing several proteins and glycoproteins (Figure 1). These viruses exist in either a lytic or latent state in infected hosts. The lytic state is characterized by active viral replication in which the virus uses host machinery for propagation. Latency develops when the virus becomes dormant within certain host cell types that may differ for each member of the herpesvirus family. During the latent state, viral gene transcription is severely restricted although latency associated transcripts (LATs) may be expressed in high amounts and are likely modulated by regulatory sequences such as the LAT promoter binding factor.¹⁰ All human herpesviruses can cause morbidity in part due to the development of life-long latency, followed by recurrent episodes brought on by a variety of factors such as stress or immunosuppression.

Many of the human herpesviruses are associated with ocular disease as a rare sequel of infection. Herpes simplex virus (HSV) type-1 and -2 are capable of infecting virtually all of the same ocular cell types, although HSV-1 is the more common cause of ocular disease. This includes blepharitis, keratitis and anterior uveitis. Varicella zoster virus (VZV) can cause a similar range of ocular infections, although with unique

Correspondence: Deepak Shukla
Department of Ophthalmology and Visual Sciences (M/C 648), University of Illinois at Chicago, 1855 W. Taylor Street, Chicago, IL 60612, USA
Tel +1 312 355 0908
Fax +1 312 996 7770
Email dshukla@uic.edu

Table 1 Human herpesviruses


Label	Herpesvirus subfamily	Sites of latency
HHV-1/HSV-1	Alphaherpesvirinae	Neurons, cornea ¹
HHV-2/HSV-2	Alphaherpesvirinae	Neurons ²
HHV-3/VZV	Alphaherpesvirinae	Neurons ²
HHV-4/EBV	Gammaherpesvirinae	B-lymphocytes ³
HHV-5/CMV	Betaherpesvirinae	Various ⁴
HHV-6	Betaherpesvirinae	T-lymphocytes (CD4 ⁺), monocytes/macrophages ^{5,6}
HHV-7	Betaherpesvirinae	T lymphocytes (CD4 ⁺) and salivary gland cells ^{6,7}
HHV-8/KSHV	Gammaherpesvirinae	B-lymphocytes, endothelial cells ^{8,9}

Abbreviations: HHV, human herpes virus; HSV, herpes simplex virus; VZV, varicella zoster virus; EBV, Epstein-Barr virus; CMV, cytomegalovirus; KSHV, Kaposi's sarcoma-related virus.

molecular and clinical characteristics. Both HSV and VZV are known to develop latency in sensory ganglia, with latency in trigeminal ganglia often linked to recurrent ocular infection. HSV may also develop latency in the cornea, although this remains controversial.¹ Cytomegalovirus (CMV) infection of the eye is strongly associated with immunodeficiency, and retinal involvement is an important cause of visual morbidity in patients with HIV/AIDS. Epstein-Barr virus (EBV) can rarely cause a variety of ocular infections and is also associated with ocular tumors, as are the remaining human herpesviruses.

Epidemiology of human herpesviruses

The human herpesviruses are generally highly prevalent globally, and for the majority of people may not be a cause of clinically significant disease. Symptomatic disease, when present, can lead to a substantial impact on health. HSV-1 seroprevalence studies demonstrate that the majority of humans are infected. Recent data suggests a decreased seropositivity in developed nations with one study indicating a drop from 62% in 1988–1994 to 57.7% in 1999–2004.¹¹ Improved hygiene and living conditions may be contributors to this trend. Polymerase chain reaction (PCR) data from trigeminal ganglia have indicated that nearly all adult humans have been exposed to the virus and some studies implicate saliva and tears as major modes of transmission.^{12,13} While historically HSV-2 has been less common than HSV-1, HSV-2 seroprevalence approaches that of HSV-1 in certain populations, and genital infection caused by the virus remains a worldwide epidemic.^{14,15} Some studies indicate that the prevalence of HSV-2 infection has also recently decreased.¹¹ The seroprevalence of HSV-2 in developing nations is believed to be higher than

**Figure 1** Basic structure of a herpesvirus virion.

Notes: The herpesviruses contain a double-stranded DNA genome (a), located inside of a nucleocapsid (b). This is surrounded by the tegument (c), which is made up of many mRNAs and proteins and is encased by a lipid bilayer envelope. Several proteins and glycoproteins (d), are embedded in the envelope, which play important roles in signaling and contribute to pathogenesis.

that in developed nations, and genital infection may be more common in women than men with new infections frequent in younger populations.¹⁴ HSV-2 also appears to have synergy with HIV through the development of mucosal ulcerations leading to increased transmissibility.¹⁶

The changing seroprevalence of the herpes simplex viruses have important implications for clinical disease patterns. While previously HSV-1 and HSV-2 have been associated with infections above and below the waist, respectively, HSV-1 is increasing as a cause of genital infection and HSV-2 may be causing more ocular disease. It is presumed that both viral subtypes are transmitted via asymptomatic shedding in mucous secretions, the mechanism of which is not well understood.¹⁷ The increasing proportion of genital disease caused by HSV-1 has been attributed to a decrease in early seropositivity as well as an increase in oral-genital contact.^{15,17,18} These issues may have increasing clinical significance and should be considered in future measures to manage disease.¹⁴

VZV is believed to infect virtually all humans, and like HSV-1 and -2 is a neurotropic virus. Before the varicella vaccine was introduced, the incidence of infection was roughly equal to that of the birth rate; currently over 95% of the population has serological evidence of past infection.¹⁹ VZV is associated with the development of chickenpox after initial viral exposure, which often occurs in childhood. Reactivation later in life causes shingles, which is a painful condition that develops in a dermatomal distribution and is often self-limited,

although some may continue to experience pain after the disappearance of vesicles (ie, post herpetic neuralgia).^{19,20} Latent VZV infection is maintained by cell-mediated immunity and is associated with periodic re-exposure to the virus.²⁰ Current incidence of VZV infection appears to be lower than before, which is attributed to the successful implementation of widespread vaccination before virus exposure. As some adults who were never infected may be exposed to wild-type virus or children who have been vaccinated, some groups recommend vaccination in older age groups to prevent a rise in incidence of VZV as the population ages.^{21,22}

CMV develops latency in multiple cell types and can be transmitted by body fluids and organ transplantation (eg, kidney). Seroprevalence studies of CMV indicate that socioeconomic status and race are predictive factors, although the majority of people are infected.²³ CMV currently remains the leading cause of infection-mediated mental retardation and deafness in developed countries.^{23,24} It is a major cause of birth defects affecting 0.2%–2% of newborns in the United States. While only 10%–15% of those infected at birth demonstrate symptoms, all infections carry a risk of neurodevelopmental sequelae.²⁴ EBV has a tropism for B-lymphocytes, as well as salivary gland duct cells and oropharyngeal cells. It has a significantly higher seroprevalence in developing nations and among lower socioeconomic status individuals. In young children it may cause a subclinical or mild initial infection, while older children and adults may develop infectious mononucleosis, of which it is the most common cause.²⁵ It is also associated with nasopharyngeal carcinoma and several lymphomas including Burkitt's. The cellular tropisms for the remaining human herpesviruses are summarized in the table above. HHV-6 and HHV-7 are causes of exanthema subitum, a common pediatric infection, while HHV-8 is associated with cancers including Kaposi's sarcoma.

Pathological processes caused by viral ocular infection

HSV-1 and HSV-2

The *Alphaherpesvirinae* subfamily includes HSV-1 and HSV-2. It is believed that HSV-1 keratitis is the leading cause of infectious blindness in developed nations. The development of ocular HSV-1 can occur in the form of primary or recurrent infection. Primary ocular exposure to the virus may result in local entry and spread often resulting in mild disease.¹ Although the host immune response clears the epithelial surface of virus, HSV-1 is able to travel retrograde along sensory nerve branches to the ipsilateral trigeminal ganglion to develop life-long latency. HSV-1 may

more frequently reach the trigeminal ganglia after initial extra-ocular infection (eg, oral mucosa) with subsequent neuronal or non-neuronal spread. The development and modulation of HSV-1 neuronal latency appears to involve both cytotoxic and noncytotoxic factors associated with CD8⁺ T-cells, as well as an inefficiency of the DNA repair mechanism in neurons.^{26–28} Latency associated transcripts are involved in regulation of the intermediate-early gene ICP0 in reactivation leading to recurrent ocular disease, which may occur repeatedly throughout the life of the host.

The ability of HSV-1 to enter and spread in ocular tissue, as well as participate in retrograde and anterograde neuronal transport, are essential in its pathophysiology. The main mechanism of spread relies on direct contact – the virus entering through the mucous membrane of the host followed by entry into cells. Entry may first occur at the outermost layers of the conjunctival or corneal epithelium using conserved invasion methods.^{29–31} HSV-1 cellular entry occurs through multiple pathways and relies on both virus and host factors. After the initial interaction of viral glycoproteins gB and/or gC with cell surface heparan sulfate proteoglycans, viral gD interacts with specific cellular receptors, causing a conformational change resulting in a glycoprotein complex facilitating invasion through a fusion pore. The gD receptors include nectin-1, herpes virus entry mediator (HVEM) and 3-O sulfated heparan sulfate (3-OS HS), each of which plays a differential role in entry based on cell-type.^{29,30,32,33} In some ocular cell types, the virus may preferably enter by a pH-dependent endocytic pathway.²⁹

HSV-1 may also use filopodia, which are actin-rich extensions of the cellular membrane, in unilateral movement to the cell body followed by receptor-mediated entry.³¹ The ability of HSV-1 to spread in tissue is not well understood, although the mechanisms of entry into cells may be preserved in its methods of spread, including a form of viral surfing along filopodia from infected to uninfected cells. The movement of the virus along peripheral nerves has also been the focus of much research. Retrograde transport of HSV-1 appears to be facilitated by viral proteins and is a conserved mechanism shared by other viruses. Anterograde transport similarly relies on viral proteins that facilitate recurrent infection.

Initial exposure to HSV-1 may result in blepharitis, which is an inflammation of the eyelids and leads to irritation and itching. It may be chronic in nature, although it is often a mild and self-limiting disease that may recur periodically. HSV-1 is also an important cause of viral conjunctivitis which may be a manifestation of initial ocular exposure.^{1,29} Epithelial keratitis due to HSV-1 develops if the virus enters

into the outermost layers of the cornea, a process that is likely facilitated by nectin-1 (unpublished data). It initially causes a punctate lesion, followed by a stellate erosion and subsequently a dendritic ulcer, recognized clinically by a characteristic branching pattern with terminal bulbs using one of several stains (Figure 2).

Stromal keratitis, which involves infection of the deeper layers of the cornea, is more frequently a result of recurrent HSV-1 rather than initial ocular exposure. It is associated with neovascularization and scarring, leading to opacification of the stroma and potentially severe vision loss or blindness if the visual axis is involved. It is believed that stromal disease, particularly scarring, results from virus-mediated damage as well as inflammatory effects associated with CD4⁺ T-cells as part of the host immune response. The issue of HSV-1 corneal latency has been debated for at least two decades, with some evidence for neuron-like characteristics of stromal cells. HSV-1 may also be transmitted by corneal transplant, which has been rarely reported. Many reactivations of HSV infection that lead to corneal infection may be premediated by alterations in host immune-virus interaction.^{1,28,34}

HSV-1 is a cause of anterior uveitis, which is associated with elevated intraocular pressure likely due to inflammation of the trabecular meshwork. HSV-1 and -2 are among the causes of acute retinal necrosis, in which there is vasculitis

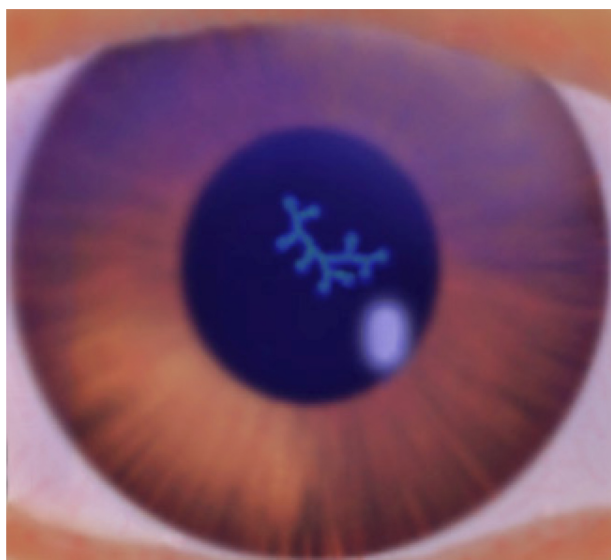


Figure 2 Illustration of a dendritic ulcer caused by HSV.

Notes: The dendritic pattern of epithelial ulceration associated with the virus is characterized by a branching morphology with terminal bulbs and “heaped-up” borders. This can be seen in the eye with slit-lamp examination using stains such as fluorescein (as in this figure), lissamine green or rose bengal. Geographic ulcers are larger and irregularly shaped. Stromal infection may eventually lead to an opacity, and usually results from recurrent ocular HSV with potential vision loss if the visual axis is involved. The pupillary dilation depicted in this figure is for illustrative purposes only.

and widespread necrosis of the retina with a high rate of visual morbidity. This may further be characterized by inflammatory orbitopathy, proptosis and optic nerve involvement, and may occur as a result of initial viral invasion or during a recurrent episode of retinitis or keratitis and can lead to severe complications such as retinal detachment.^{35–38} HSV-2 induced retinitis and acute retinal necrosis are seen in both immunocompetent and immunosuppressed patients. HSV-2 may be increasing as a cause of acute retinal necrosis due to an epidemic of genital infection among pregnant women followed by vertical transmission to neonates, although this remains to be effectively demonstrated. Congenital and neonatal HSV-2 infections may also progress to retinitis later in life due to neuronal transport of the virus following anterior chamber infection.³⁷ While HSV-2 is not classically associated with other ocular diseases we have discussed, some cases have been reported. The ability of HSV-2 to infect various ocular cell types, a changing HSV seroprevalence and more specific diagnostic tests suggest that it may be increasingly recognized as a cause of ocular disease.^{30,35,39,40}

VZV

VZV is also a member of the *Alphaherpesvirinae* subfamily and is a known cause of ocular infection referred to as herpes zoster ophthalmicus (HZO). HZO affects approximately 10%–20% of those infected with VZV.²⁰ This is most often a result of reactivation from latency in the ipsilateral trigeminal ganglion. The ability of VZV to enter cells, spread through tissue and participate in retrograde and anterograde neuronal transport are therefore vital in its pathophysiology. VZV successfully enters neurons within the dorsal root ganglion and promotes cell–cell fusion allowing spread of virus. Satellite cell infection by VZV helps the spread of virus into further neuronal bodies.⁴¹ VZV glycoprotein E (gE) is known to be important for entry, replication and cell–cell spread.⁴²

Ocular involvement in VZV is usually preceded by a prodrome of influenza-like symptoms followed by a painful maculopapular rash that erupts in a dermatomal distribution. The upper eyelid and forehead are commonly affected, with potential ectropion (turning out of the eyelid) and scarring. Conjunctival involvement may have one of several presentations along with redness and vesicle formation. VZV infection of the corneal epithelium leads to a dendrite-like morphology of epithelial cell swelling that may be seen on slit-lamp examination (Figure 3). Microdendritic keratitis, nummular keratitis, disciform keratitis, mucous plaque keratitis, sclerokeratitis or iritis may occur. In children, ocular involvement is usually a self-limiting process that may

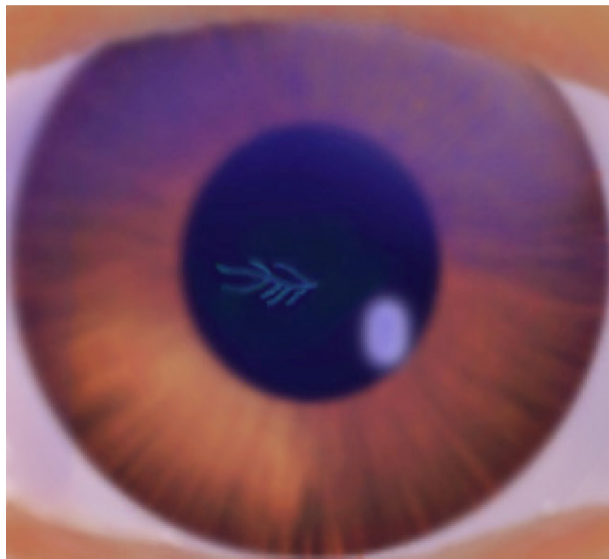


Figure 3 Illustration of a pseudodendrite caused by VZV.

Notes: The morphology of pseudodendrites associated with VZV differs from the dendritic ulcers of HSV by a lack of terminal bulbs as well as elevation and less branching. Unlike HSV which causes sloughing of epithelial cell layers leading to ulceration, VZV is characterized by swollen epithelial cells that may or may not stain with fluorescein. Repeated infection with VZV may also lead to a neurotrophic cornea, in which there is lack of sensation due to corneal nerve damage leading to an increased risk of corneal ulcer (ie, neurotrophic ulcer). The pupillary dilation depicted in the figure is for illustrative purposes only.

not require extensive treatment. However, in neonates and immunosuppressed patients ocular involvement can quickly progress into severe pneumonitis and/or encephalitis.²⁰

Repeated painful episodes of ocular VZV may be followed by corneal anesthesia due to corneal nerve damage (ie, neurotrophic cornea). This is associated with an increased risk of sterile corneal ulceration as well as secondary bacterial infection. Patients with a history of HZO may also develop late epithelial lesions, including dendriform lesions and mucous plaque keratitis, the latter of which is considered non-infectious.⁴³ In addition to corneal epithelial lesions, VZV may cause a number of stromal infection patterns including granular anterior stromal infiltrates, disc-shaped or diffuse edema in deeper areas of the stroma and limbal vascular invasion. Studies in animal models have demonstrated the neurotropism of VZV after primary ocular infection. Corneal inoculation in guinea pigs resulted in punctate keratitis and microdendrite formation, with viral spread to the trigeminal and superior cervical ganglia as well as the cerebellum and midbrain.⁴⁴

VZV is also associated with anterior uveitis that may be granulomatous or non granulomatous and often leads to elevated intraocular pressure secondary to trabecular meshwork damage or other processes. This may coincide with iris atrophy as well as keratitis and/or posterior pole

complications. VZV is believed to be a common cause of acute retinal necrosis. A study of retinal pigment epithelial cells revealed that they were susceptible to infection by VZV and served as antigen presenting cells. It has also been demonstrated that infection of these cells most likely occurs after transaxonal spread to nearby neurons.⁴⁵

Several case series that describe HZO include those with a history of immunosuppression. In particular, multiple investigations have described corneal epithelial lesions in patients with HIV. Recently, Hu et al reported on late dendriform keratitis in immunocompetent patients with a history of HZO, in which 15 of 16 cases were positive for VZV DNA.⁴³ It was noted that these lesions were pleomorphic and sometimes associated with a subadjacent haze in the corneal stroma. Anterior uveitis has also been described in both immunocompromised and immunocompetent patients. Patients with concurrent HIV and other etiologies of immunosuppression may have an increased recurrence rate as seen in ocular HSV.^{19–21,46,47}

EBV

The ability of EBV to infect various ocular cell types has been described by clinical reports of conjunctivitis, keratitis, iritis, retinitis and neuritis attributed to the virus. It should be noted that many of these reports came prior to the use of more specific diagnostic tests that are now available. In some cases ocular sequelae were noted soon after or concurrently with infectious mononucleosis, including cases of Sjogren's syndrome with dendritic keratitis. A study of EBV DNA in tear film did not reveal a higher rate of shedding in Sjogren's syndrome versus controls, although secondary Sjogren's was associated with a higher rate of EBV type 1.⁴⁸

Increased EBV shedding was also observed in patients with HIV.⁴⁹ Other studies have found varying presentations of corneal epithelial and stromal infection associated with the virus, although a distinct granular form of stromal keratitis has been described.

Posterior segment disease due to EBV has been rarely reported. There are also reports of ocular lymphomas associated with EBV, including B-cell and T-cell lymphomas. Lymphomas linked to EBV are known to involve mucosa-associated lymphoid tissue (MALT), but the virus has also been implicated in various types of ocular lymphoid malignancies. Although ocular lymphomas are rare, further investigation is required to improve the understanding of EBV-related tumorigenesis.

CMV

The *Betaherpesvirinae* subfamily includes CMV, which is an important ocular pathogen recognized for its ability to

cause disease in the immunocompromised. It has declined as a cause of retinitis and other ocular diseases since the advent of highly active antiretroviral treatment (HAART), although all cases have not been eliminated.^{50–53} CMV retinitis is understood to be an AIDS-defining illness in patients with HIV, since it usually presents in those with a severely low CD4⁺ T cell count. Prior to the availability of HAART, a substantial number of CMV retinitis cases were seen in AIDS patients. The disease has also been observed in other forms of immunosuppression, including those undergoing solid organ transplantation. As evidence of viral activity may be difficult to obtain, diagnosis of CMV retinitis often relies on a history of immunosuppression and characteristic retinal changes on examination (Figure 4). The issue of ocular latency of CMV has been debated in the literature and is evidenced by reports of CMV reactivation in immunocompetent patients who underwent ocular immunosuppression.

CMV is also a rare cause of other ocular diseases, with some reports describing keratitis or optic neuritis without a diffuse retinitis. An imaging study in a murine model using green fluorescent-tagged CMV followed ocular infection using a scanning laser ophthalmoscope.⁵⁴ It was revealed that immunocompetent mice were susceptible to infection in retinal pigment epithelial cells and the outer segments of photoreceptors after intraocular injection, with no virus present in the optic nerve or brain. Virus was also detected in the

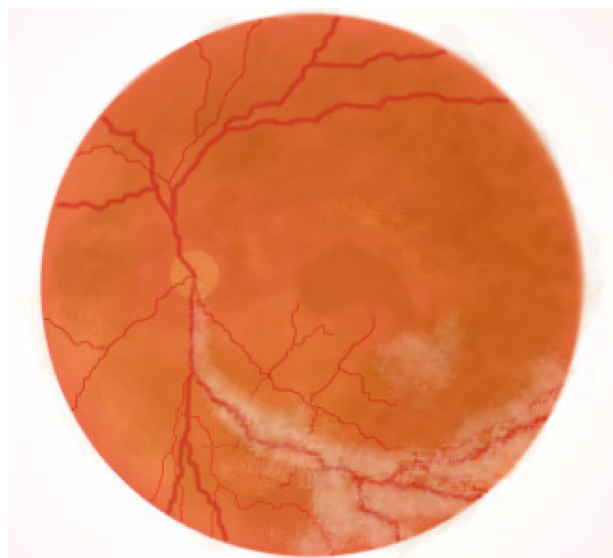


Figure 4 Illustration of CMV retinitis.

Notes: The majority of human beings have been infected by CMV and it usually does not cause clinical symptoms. In the immunocompromised it can cause a number of clinically significant diseases, including CMV retinitis. This is a progressive viral inflammatory condition of the retina that may lead to decreased visual acuity and an increased risk for retinal detachment. It is an AIDS-defining illness in those infected by HIV as it usually coincides with a low CD4⁺ T cell count. The illustration in the figure depicts areas of retinal changes and exudates.

anterior lens capsule, and in the iris as early as 4 days after injection and lasting until 25 days. CMV DNA has also been detected in cases of anterior uveitis in immunocompetent and immunocompromised patients.⁵⁵

HHV-6, HHV-7 and HHV-8

The remaining human herpes viruses are associated with primary ocular lymphomas as demonstrated in selected case series. HHV-6 is a rare cause of optic neuritis and possibly dry eye and papillary conjunctivitis.^{56,57} HHV-8, also known as Kaposi's sarcoma-associated herpes virus (KSHV), can cause conjunctival Kaposi's sarcoma and possibly uveitis. The link of these herpes viruses to ocular lymphomas has been established by the use of PCR to detect viral DNA in biopsied samples, including from mucosa-associated lymphoid tissue (MALT) lymphomas.⁵⁸

Prevention and management strategies

The management of herpesvirus ocular infections depends upon virus type and disease severity, among other factors. However, most available antiviral treatments are targeted at inhibiting virus replication. The detection of herpesvirus DNA may be increasingly used as a diagnostic tool as more specific tests are made available and due to overlapping disease patterns. Epithelial keratitis due to HSV-1 or -2 is usually treated with topical 0.3% acyclovir, 1% trifluridine or oral acyclovir. Stromal keratitis may additionally be treated with corticosteroids, which should not be used without antivirals due to the possibility of increased viral activity. Prophylactic oral acyclovir may be used in patients with a history of recurrent disease or immunosuppression.⁵⁹ Herpes zoster ophthalmicus may be treated with oral antivirals such as acyclovir or valacyclovir, with topical steroids added for stromal or uveal involvement. Analgesics are used for what are often severely painful cutaneous lesions. Acute retinal necrosis due to HSV or VZV may be treated with oral antivirals (eg, famciclovir, valacyclovir), intravenous acyclovir or intravitreal antiviral injection. Retinal detachment may occur requiring surgical treatment including vitrectomy or endolaser.

Ocular EBV may also be treated with antivirals in the form of nucleoside analogs, and it is likely an under-diagnosed etiology of some ocular diseases.⁶⁰ This may be due to the ability of herpesviruses to cause a variety of presentations with EBV believed to be uncommon in ocular infections. The treatment of CMV retinitis involves the use of oral valganciclovir, and possibly ganciclovir delivered

as an intravitreal injection or implant. The use of HAART is beneficial in these patients by facilitating an increase in CD4⁺ T cell count. However, there is also a risk for immune reconstitution disease manifesting as CMV uveitis, which can cause severe ocular morbidity.⁶¹ Retinal detachment may occur in CMV as well requiring surgical treatment. The treatments for ocular lymphomas associated with several human herpesviruses include radiation, cryotherapy and chemotherapy.

Prevention of ocular herpesvirus infections in humans can be a challenging immunological and epidemiologic issue due to their high seroprevalence and transmissibility. Vaccines against HSV-1 and HSV-2 have shown promise in animal models, but adequate protection remains to be seen in human clinical trials. The development of life-long latency in sensory ganglia early in the life of humans may therefore have unique virological and immunological features that make vaccine development for HSV a difficult task. By contrast, a live attenuated VZV vaccine was developed in the 1970s, and a commercial form is now used widely in the United States and Japan. While this vaccine has a high disease prevention rate, protection against ocular involvement has not been specifically demonstrated.

Some progress has been made in vaccine development efforts for other human herpes viruses, although further investigation is required. Prevention and management of EBV may require different formulations for infectious mononucleosis-related symptoms versus tumors, the latter of which may involve exploitation of viral antigen presence in abnormal tissue.⁶² Central nervous system involvement of CMV has created much interest in prevention of disease and optimization of management.⁶³ A candidate CMV glycoprotein B subunit vaccine used in seronegative women has shown some benefit in a phase 2 clinical trial, with protection in newborns as a potential endpoint.⁶⁴

Conclusion

The human herpesviruses comprise an enigmatic category of pathogens. Although several of them infect a large proportion of humans, they are able to develop latency in various cell types and thereby most individuals may remain asymptomatic for long periods of time. Ocular disease is usually a rare manifestation of infection, and treatments are often focused on inhibiting virus replication. A comprehensive discussion of the many epidemiologic, molecular and clinical issues related to herpesvirus ocular infections is beyond the scope of this review. This is instead a brief summary of the role of herpes viruses in ocular disease while addressing some of

the salient issues in understanding their pathophysiology, clinical patterns and treatment modalities.

While some of the “classic” disease presentations are discussed, it should be noted that ocular herpesvirus infections may not produce these characteristic lesions and instead may mimic each other clinically. The complex virus-host interactions that facilitate the development of latency may make the development of effective vaccines particularly challenging.

Knowledge of the important similarities and differences between the ways in which these herpesviruses cause ocular disease will provide insight into pathogenic mechanisms that may be targeted for improved treatments in the future.

Acknowledgments

Deepak Shukla is supported in part by NIH grants AI057860, AI081869, Core Grant EY01792 and a Lew Wasserman Merit Award from Research to Prevent Blindness, Inc, New York, New York.

Asim Farooq is supported by a Research to Prevent Blindness Medical Student Eye Research Fellowship.

Disclosure

The authors report no conflicts of interest in this work.

References

1. Kaye S, Choudhary A. Herpes simplex keratitis. *Prog Retin Eye Res.* 2006;25(4):355–380.
2. Steiner I. Human herpes viruses latent infection in the nervous system. *Immunol Rev.* 1996;152:157–173.
3. Niller HH, Wolf H, Minarovits J. Regulation and dysregulation of Epstein-Barr virus latency: implications for the development of autoimmune diseases. *Autoimmunity.* 2008;41(4):298–328.
4. Ho M. The history of cytomegalovirus and its diseases. *Med Microbiol Immunol.* 2008;197(2):65–73.
5. Caserta MT, Mock DJ, Dewhurst S. Human herpes virus 6. *Clin Infect Dis.* 2001;33(6):829–833.
6. De Araujo T, Berman B, Weinstein A. Human herpes viruses 6 and 7. *Dermatol Clin.* 2002;20(2):301–306.
7. Black JB, Pellet PE. Human herpes virus 7. *Rev Med Virol.* 1999;9(4):245–262.
8. Verma SC, Robertson ES. Molecular biology and pathogenesis of Kaposi sarcoma-associated herpes virus. *FEMS Microbiol Lett.* 2003;222(2):155–163.
9. Pantry SN, Medveczky PG. Epigenetic regulation of Kaposi's sarcoma-associated herpes virus replication. *Semin Cancer Biol.* 2009;19(3):153–157.
10. Zwaagstra JC, Ghiasi H, Nesburn AB, Wechsler SL. Identification of a major regulatory sequence in the latency associated transcript (LAT) promoter of herpes simplex virus type 1 (HSV-1). *Virology.* 1991;182(1):287–297.
11. Xu F, Sternberg MR, Kottiri BJ, et al. Trends in herpes simplex virus type 1 and type 2 seroprevalence in the United States. *JAMA.* 2006;296(8):964–973.
12. Hill JM, Ball MJ, Neumann DM, et al. The high prevalence of herpes simplex virus type 1 DNA in human trigeminal ganglia is not a function of age or gender. *J Virology.* 2008;82(16):8230–8234.

13. Kaufman HE, Azcuy AM, Varnell ED, et al. HSV-1 DNA in tears and saliva of normal adults. *Invest Ophthalmol Vis Sci*. 2005;46(1):241–247.
14. Weiss H. Epidemiology of herpes simplex virus type 2 infection in the developing world. *Herpes*. 2004;11(1):24A–35A.
15. Malkin J. Epidemiology of genital herpes simplex virus infection in developed countries. *Herpes*. 2004;11 Suppl 1:2a–23a.
16. Gupta R, Warren T, Wald A. Genital herpes. *Lancet*. 2007;370(9605):2127–2137.
17. Langenberg AG, Correy L, Ashley RL, et al. A prospective study of new infections with herpes simplex virus type 1 and type 2. *NEJM*. 1999;341(19):1432–1438.
18. Roberts CM, Pfister JR, Spear SJ. Increasing proportion of herpes simplex virus type 1 as a cause of genital herpes infection in college students. *Sex Transm Dis*. 2003;30(10):797–800.
19. Arvin AM. Varicella-zoster virus. *Clin Microbiol Rev*. 1996;9(3):361–381.
20. Liesegang TJ. Herpes Zoster Ophthalmicus: Natural History, Risk Factors, Clinical Presentation, and Morbidity. *Ophthalmology*. 2008;115(2):S3–S12.
21. Sanford M, Keating GM. Zoster vaccine (Zostavax): a review of its use in preventing herpes zoster and postherpetic neuralgia in older adults. *Drugs Aging*. 2010;27(2):159–176.
22. Reynolds MA, Chaves SS, Harpaz R, et al. The impact of the varicella vaccination program on herpes zoster epidemiology in the United States: a review. *J Infect Dis*. 2008;197 Suppl 2:S224–S227.
23. Cannon MJ. Congenital Cytomegalovirus Epidemiology and Awareness. *J Clin Virol*. 2009;46 Suppl 4:S6–S10.
24. Boppana SB, Fowler KB, Pass RF, et al. Congenital cytomegalovirus infection: association between virus burden in infancy and hearing loss. *J Pediatr*. 2005;146(6):817–823.
25. Slobod KS, Sandlund JT, Spiegel PH, et al. Molecular Evidence of Ocular Epstein-Barr Virus Infection. *Clin Infect Dis*. 2000;31(1):184–188.
26. Knickelbein JE, Khanna KM, Yee MB, et al. Noncytotoxic lytic granule-mediated CD8⁺ T cell inhibition of HSV-1 reactivation from neuronal latency. *Science*. 2008;322(5899):268–271.
27. Ghiasi H, Cai S, Perng GC, et al. Both CD4⁺ and CD8⁺ T-cells are involved in protection against HSV-1 induced corneal scarring. *Br J Ophthalmol*. 2000;84(4):408–412.
28. Lilley CE, Carson CT, Muotri AR, et al. DNA repair proteins affect the lifecycle of herpes simplex virus 1. *Proc Natl Acad Sci*. 2005;102(16):5844–5849.
29. Akhtar J, Tiwari V, Oh M-J, et al. HVEM and nectin-1 are the major mediators of herpes simplex virus 1 (HSV-1) entry into human conjunctival epithelium. *Invest Ophthalmol Vis Sci*. 2008;49(9):4026–4035.
30. Tiwari V, Shukla SY, Yue BY, Shukla D. Herpes simplex virus type 2 entry into cultured human corneal fibroblasts is mediated by herpes virus entry mediator. *J Gen Virol*. 2007;88(8):2106–2110.
31. Tiwari V, Oh MJ, Kovacs M, et al. Role for nectin-1 in herpes simplex virus 1 entry and spread in human retinal pigment epithelial cells. *FEBS J*. 2008;275(21):5272–5285.
32. Shukla SY, Singh YK, Shukla D. Role of nectin-1, HVEM, and PILR-alpha in HSV-2 entry into human retinal pigment epithelial cells. *Invest Ophthalmol Vis Sci*. 2009;50(6):2878–2887.
33. Akhtar J, Shukla D. Viral entry mechanisms: cellular and viral mediators of herpes simplex virus entry. *FEBS J*. 2009;276(24):7228–7236.
34. Valyi-Nagy T, Sheth V, Clement C, et al. Herpes simplex virus entry receptor nectin-1 is widely expressed in the murine eye. *Curr Eye Res*. 2004;29(4–5):303–309.
35. Liesegang TJ. Herpes simplex virus epidemiology and ocular importance. *Cornea*. 2001;20:1–13.
36. Duker JS, Nielsen JC, Eagle RC, et al. Rapidly progressive acute retinal necrosis secondary to herpes simplex virus, type 1. *Ophthalmology*. 1990;97:1638–1643.
37. Smith LK, Kurz PA, Wilson DJ, et al. Two patients with the von Szily reaction: herpetic keratitis and contralateral retinal necrosis. *Am J Ophthalmol*. 2007;143:536–538.
38. Nussenblatt RB, Palestine AG. Acute retinal necrosis. In: *Uveitis: Fundamentals and Clinical Practice*. Year Book Medical Publishers. Chicago 1989;407–414.
39. Duker JS, Blumenkranz MS. Diagnosis and management of the acute retinal necrosis (ARN) syndrome. *Surv Ophthalmol*. 1991;35:327–343.
40. Inoda S, Wakakura M, Hirata J, et al. Stromal keratitis and anterior uveitis due to herpes simplex virus type-2 in a young child. *Jpn J Ophthalmol*. 2001;45(6):618–621.
41. Reichelt M, Zerboni L, Arvin AM. Mechanisms of varicella-zoster virus neuropathogenesis in human dorsal root ganglia. *J Virol*. 2008;82(8):3971–3983.
42. Berarducci B, Sommer M, Zerboni L, Rajamani J, Arvin AM. Cellular and viral factors regulate the varicella-zoster virus gE promoter during viral replication. *J Virol*. 2007;81(19):10258–10267.
43. Hu AY, Strauss EC, Holland GN, et al. Late varicella-zoster virus dendritic keratitis in patients with histories of herpes zoster ophthalmicus. *Am J Ophthalmol*. 2010;149(2):214–220.
44. Pavan-Langston D, Dunkel EC. Ocular varicella-zoster virus infection in the guinea pig. A new in vivo model. *Arch Ophthalmol*. 1989;107(7):1068–1072.
45. Milikan JC, Baarsma GS, Kuijpers RW, et al. Human ocular-derived virus-specific CD4⁺ T-cells control varicella zoster virus replication in human retinal pigment epithelial cells. *Invest Ophthalmol Vis Sci*. 2009;50(2):743–751.
46. Hodge WG, Margolis TP. Herpes simplex virus keratitis among patients who are positive or negative for human immunodeficiency virus: an epidemiologic study. *Ophthalmology*. 1997;104(1):120–124.
47. Young TL, Robin JB, Holland GN, et al. Herpes simplex keratitis in patients with acquired immune deficiency syndrome. *Ophthalmology*. 1989;96(10):1476–1479.
48. Willoughby CE, Baker K, Kaye SB, et al. Epstein-Barr virus (types 1 and 2) in the tear film in Sjogren's syndrome and HIV infection. *J Med Virol*. 2002;68(3):378–383.
49. Saito I, Servenius B, Compton T. Detection of Epstein-Barr virus DNA by polymerase chain reaction in blood and tissue biopsies from patients with Sjogren's syndrome. *J Exp Med*. 1989;169:2191–2198.
50. Holland GN. AIDS and ophthalmology: the first quarter century. *Am J Ophthalmol*. 2008;145(3):397–408.
51. Holland GN, Vaudaux JD, Jeng SM, et al; UCLA CMV Retinitis Study Group. Characteristics of untreated AIDS-related cytomegalovirus retinitis. I. Findings before the era of highly active antiretroviral therapy (1988 to 1994). *Am J Ophthalmol*. 2008;145(1):5–11.
52. Holland GN, Vaudaux JD, Shiramizu KM, et al; Southern California HIV/Eye Consortium. Characteristics of untreated AIDS-related cytomegalovirus retinitis. II. Findings in the era of highly active antiretroviral therapy (1997 to 2000). *Am J Ophthalmol*. 2008;145(1):12–22.
53. Thorne JE, Holbrook JT, Jabs DA, et al; Studies of Ocular Complications of AIDS Research Group. Effect of cytomegalovirus retinitis on the risk of visual acuity loss among patients with AIDS. *Ophthalmology*. 2007;114(3):591–598.
54. Zinkernagel MS, Petjean C, Fleming P, et al. In vivo imaging of ocular MCMV infection. *Invest Ophthalmol Vis Sci*. 2010;51:369–374.
55. Yamauchi Y, Suzuki J, Sakai J, et al. A case of hypertensive keratouveitis with endotheliitis associated with cytomegalovirus. *Ocul Immunol Inflamm*. 2007;15(5):399–401.
56. Méchai F, Boutolleau D, Manceron V, et al. Human herpes virus 6- associated retrobulbar optic neuritis in an HIV-infected patient: response to anti-herpes virus therapy and long-term outcome. *J Med Virol*. 2007;79(7):931–934.
57. Moschetti D, Franceschini R, Vaccaro NM, et al. Human herpes virus-6B active infection associated with relapsing bilateral anterior optic neuritis. *J Clin Virol*. 2006 Dec;37(4):244–247.
58. Chan CC. Molecular pathology of primary intraocular lymphoma. *Trans Am Ophthalmol Soc*. 2003;101:275–292.

59. International Herpes Management Forum. The management of HSV-1 and ocular HSV diseases. Recommendations from the IHMF Management Strategies Workshop. IHMF 2002.
60. Matoba AY. Ocular disease associated with Epstein-Barr virus infection. *Surv Ophthalmol*. 1990;35(2):145–50.
61. Schrier RD, Song MK, Smith IL, et al. Intraocular viral and immune pathogenesis of immune recovery uveitis in patients with healed cytomegalovirus retinitis. *Retina*. 2006;26(2):165–169.
62. Moss DJ, Suhrbier A, Elliott SL. Candidate vaccines for Epstein-Barr virus. *BMJ*. 1998;317(7156):423–424.
63. Griffith JF. Nervous system manifestations of cytomegalovirus (CMV) infection. *Dev Med Child Neurol*. 1971 Aug;13(4):520–522.
64. Dekker CL, Arvin AM. One step closer to a CMV vaccine. *N Engl J Med*. 2009;360(12):1250–1252.

Virus Adaptation and Treatment

Publish your work in this journal

Virus Adaptation and Treatment is an international, peer-reviewed open access journal focusing on the study of virology, viral adaptation and the development and use of antiviral drugs and vaccines to achieve improved outcomes in infection control and treatment. The journal welcomes original research, basic science, clinical & epidemiological

Submit your manuscript here: <http://www.dovepress.com/virus-adaptation-and-treatment-journal>

studies, reviews & evaluations, expert opinion and commentary, case reports and extended reports. The manuscript management system is completely online and includes a very quick and fair peer-review system, which is all easy to use. Visit <http://www.dovepress.com/testimonials.php> to read real quotes from published authors.

Dovepress