

# Systematic Review of the Management of Retro-Hepatic Inferior Vena Cava Injuries

This article was published in the following Dove Press journal:  
*Open Access Emergency Medicine*

David Zargaran<sup>1</sup>  
Alexander Zargaran<sup>2</sup>  
Mansoor Khan<sup>3</sup>

<sup>1</sup>Department of Medicine, Imperial College London, London, UK;

<sup>2</sup>Department of Medicine, King's College London, London, UK; <sup>3</sup>Brighton and Sussex University Hospitals, Brighton, UK

**Background:** Retro-hepatic inferior vena cava (RHIVC) injuries resulting from blunt or penetrating abdominal trauma are rare but devastating events that remain a considerable challenge to even the most experienced doctors, which continue to carry a considerable mortality.

**Aim:** To establish a better understanding of the management of RHIVC injuries and to identify any adjuncts or operative methods that were associated with an increased survival.

**Methods:** A systematic review of the MEDLINE database was conducted using Medical Search Headings and exploded keywords and phrases. Studies were screened and subjected to inclusion/exclusion criteria. Data were extracted in a methodical manner collecting population demographics, morbidity, mortality and operative intervention, where provided. Operative strategies were compared and discussed.

**Results:** An initial search identified 483 articles. Following duplicate removal and abstract screening, 85 full-text articles were assessed with 25 meeting the desired criteria and were, therefore, included in the systematic review. Key operative strategies and complications were identified and discussed.

**Conclusion:** The wide variety of operative interventions in the management of RHIVC liver injuries described attest to the increased efforts to improve outcomes. The overall improvement in mortality can be noted since the earlier descriptions reported mortality approaching 100% compared to the 52% reported in this review. An algorithm has been proposed based on these findings and our experiences for the management of RHIVC injuries.

**Keywords:** trauma, liver, hepatic

## Background

Retro-hepatic inferior vena cava (RHIVC) injuries resulting from blunt or penetrating abdominal trauma are rare but devastating events that remain a considerable challenge to even the most experienced trauma surgeons. Although increasing experience in the management of liver injuries has decreased mortality in the lower grades of liver injury, high grade, especially RHIVC injury still carries a considerable mortality.<sup>1-4</sup>

The American Association of Surgery for Trauma (AAST) devised a classification mechanism<sup>5</sup> with RHIVC injuries correlating with Grade V.

Although these injuries only account for 10% of all liver injuries, they have the highest mortality, with most deaths resulting from intra-operative haemorrhage.<sup>6</sup> Over the past few years, a number of adjuncts have been proposed to aid survival. Initial increases in the survival of high-grade liver injuries have been due to the advancement of pre-hospital care. Patients who would previously have died in the field are now surviving to receive surgical intervention at hospitals.<sup>7</sup>

Correspondence: David Zargaran  
Email david.zargaran@imperial.ac.uk

The retro-hepatic vena cava is approximately 10 cm long, with 3 large tributaries; the right, middle and left hepatic veins. The right hepatic vein in the majority of cases terminates within 1 cm of the diaphragm.<sup>8</sup> These anatomical factors contribute towards technically demanding mobilization, which consumes time, allows continuing haemorrhage, increasing coagulopathy and consequently lead to worsening haemorrhage.

In an effort to establish a better understanding of the management of RHIVC injuries, we undertook a retrospective systematic review to identify any adjuncts or operative methods that were associated with an increased survival.

## Methods

### Search Strategy

A combination of free text and medical subject headings (MeSH) terms were employed to search the PubMed (Medline Database): “Abdominal Injuries/surgery”[MESH] AND “Liver/injuries”[MESH] AND “Liver/surgery”[MESH], “high-grade liver injury”. We searched the Medline (PubMed) database from the date of inception to 29 March 2018, to capture all literature on treatment of liver lacerations. The initial set of records identified were subsequently screened by title and abstract. All eligible articles for full-text review were then identified and analysed. Duplicate publications were identified and removed.

### Data Collection

- Studies eligible for inclusion:
- Referenced the AAST classification of hepatic injuries
- Included data on grade V and RHIVC injuries
- Original research articles
- Described in English
- Published and indexed on PubMed

Data were extracted in a methodical manner collecting population demographics, morbidity, mortality and operative intervention, where provided. Studies were reviewed and critically appraised by two authors (DZ and AZ).

### Study Quality and Risk of Bias

The QUALSYST tool for evaluating primary data was used, to appraise the quality and assess for risk of bias.

## Review Results

A total of 483 publications were identified using free text and MeSH search strategies. The titles and abstracts of these publications were assessed in a systematic manner with decisions regarding inclusion and exclusion made in accordance with the criteria explained above. Eighty-five full-text articles were analysed following the initial screening and exclusion. A subsequent review of the 85 publications, 25 articles<sup>9–33</sup> met the desired criteria and were therefore included in the systematic review (Figure 1). The interrater reliability kappa score was 1.0. There was no major risk of bias found using the QUALSYST tool.

The 25 studies analysed included a total of 319 patients who were deemed to have met the criteria for an RHIVC injury. Post intervention, a total of 154 survived yielding a mortality rate of 52%. Table 1 illustrates the studies appraised and mortality observed.

Complications reported from the studies include: abscess formation, haemorrhage, bilioma, hepatic failure, fistula formation, bile leak, pneumonia, temporary hepatic ischaemia, necrosis, gallbladder infarction and abdominal compartment syndrome.<sup>11,14,16,18,21,22,27,29–33</sup> Table 2 outlines the range of operative interventions used in the literature.

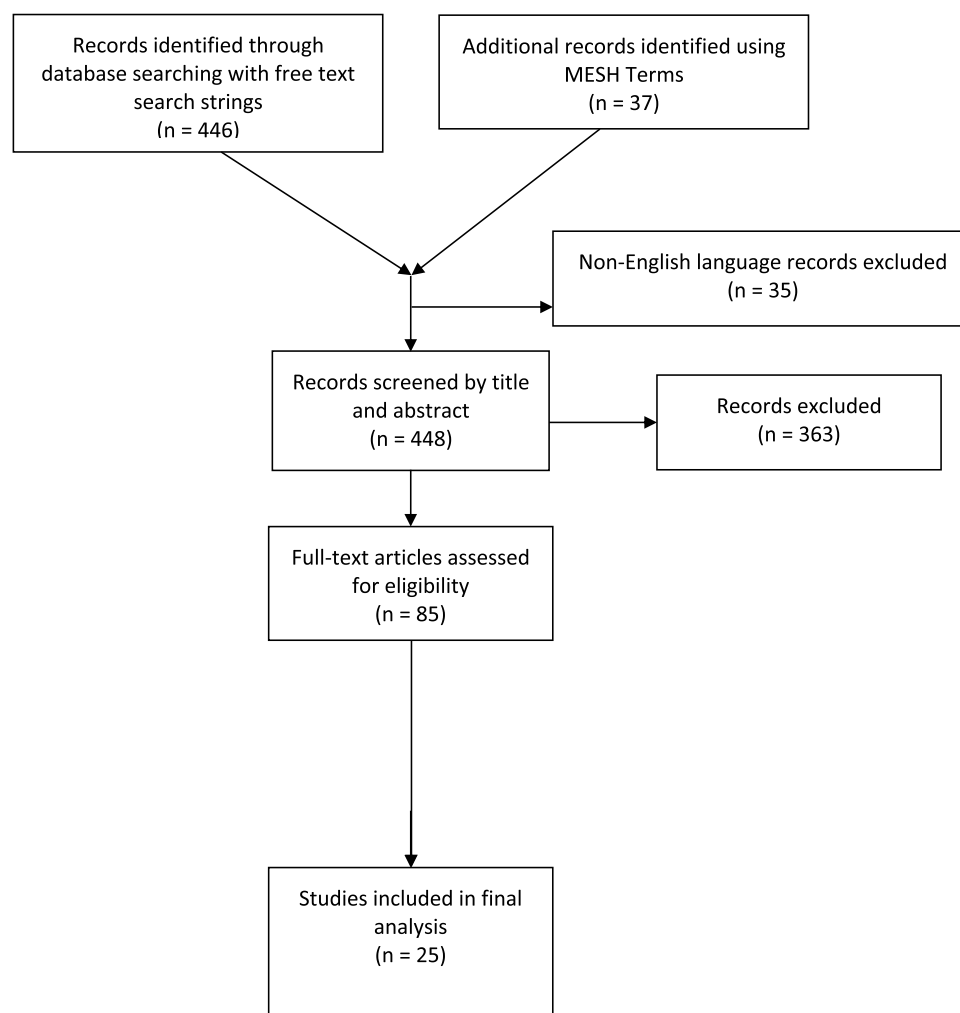
## Discussion

Major hepatic vein and RHIVC injuries are often fatal because of massive uncontrollable haemorrhage, with mortality rates previously reported as approaching 100%.<sup>34–36</sup>

It has been demonstrated that Revised Trauma Score, hemodynamic instability, blood pH and Base Excess are important prognostic factors influencing morbidity and mortality in polytrauma patients with high-grade liver injury.<sup>37</sup> Our series concurred with the fact that the Revised Trauma Score and serum lactate levels may be useful predictors of mortality. Furthermore, Di Saverio et al demonstrated that fast and effective surgical damage control procedure with perihepatic packing, followed by early ICU admission is associated with lower complication rate and shorter ICU stays in patients with severe liver injuries.<sup>37</sup>

### Non-Operative Management

Non-operative management is advocated in blunt liver trauma patients who remain haemodynamically stable. In the context of penetrating injuries, provided other injuries have been excluded which mandate laparotomy, non-operative management, Demetriades et al advocate



**Figure 1** Prisma Diagram outlining research process.

non-operative management for the management of isolated grades I and II gunshot wounds.<sup>38</sup>

There are several operative techniques that can be attempted to treat RHIVC injuries and we will aim to describe each in sequence and current evidence.

## Operative Management

A number of operative skin incisions for optimum access are described in the literature; upper midline extending to a sternotomy, bilateral subcostal with a sternotomy extension (so-called Mercedes-Benz incision) and a right-sided thoraco-abdominal approach. These are thought to aid rapid vascular control and improve the efficiency of hepatic exclusion.<sup>39</sup> However, rarely does major liver trauma occur in isolation and the authors recommend a full mid-line laparotomy to allow access to the liver and determine if other injuries are present.

At operation, if applying the Pringle manoeuvre (digital compression of the porta hepatis) does not control bleeding then RHIVC or major hepatic venous injury should be suspected. Numerous vascular isolation methods are described, ranging from total vascular isolation to venous shunting.

There was an initial hope that shunting techniques would decrease the mortality from RHIVC injuries. Atriocaval shunts are placed in the patient by extending the midline laparotomy to a sternotomy. The infra-diaphragmatic aorta is cross-clamped and the liver is mobilized by transecting the falciform ligament and the left and right triangular ligaments. A purse-string suture is tied around the right atrial appendage and ties placed around the supra-renal and infra-cardiac IVC. A 36G chest tube is then inserted with additional holes 20 cm from the proximal hole through a hole created in the right atrial appendage and secured with the three ties, resulting in

**Table 1** Studies Included in Critical Appraisal and Literature Review

Reference Number	Name	Year	Country	n	Mortality
9	Current approach to liver traumas.	2017	Turkey	14	100%
10	Severe Blunt Hepatic Trauma in Polytrauma Patient - Management and Outcome.	2015	Serbia	10	90%
11	Management of severe blunt liver injuries by applying the damage control strategies with packing-oriented surgery: experiences at a single institution in Korea.	2015	Korea	23	39%
12	Evaluation of liver injury in a tertiary hospital: a retrospective study.	2014	Turkey	1	100%
13	Management and treatment of liver injury in children.	2014	Turkey	1	100%
14	Complications of high grade liver injuries: management and outcome with focus on bile leaks.	2012	Israel	16	69%
15	Management of liver injuries: predictors for the need of operation and damage control surgery.	2013	Thailand	13	62%
16	Non-operative management of isolated liver trauma.	2014	China	6	Indeterminate (estimated 33%)
17	Management of liver trauma in Kuwait.	2013	Kuwait	11	18%
18	Retrospective Evaluation of Magnitude, Severity and Outcome of Traumatic Hepatobiliary Injury at a Level-I Trauma Center in India.	2015	India	14	50%
19	Surgical management and outcome of blunt major liver injuries: experience of damage control laparotomy with perihepatic packing in one trauma centre.	2013	Taiwan	14	79%
20	Early right hepatectomy for severe liver trauma: a case report.	2015	Italy	1	0%
21	Improved outcomes in the non-operative management of liver injuries.	2011	Netherlands	4	Indeterminate (estimated 50%)
22	Complications of nonoperative management of high-grade blunt hepatic injuries.	2005	USA	8	13%
23	Selective management of blunt hepatic injuries including nonoperative management is a safe and effective strategy.	2005	USA	19	63%
24	Major hepatic necrosis: a common complication after angioembolization for treatment of high-grade liver injuries.	2009	USA	80	53%
25	Blunt liver injury: from non-operative management to liver transplantation.	2000	Italy	6	17%
26	Changes in the management of liver trauma leading to reduced mortality: 15-year experience in a major trauma centre.	2013	Australia	31	42%
27	Angiographic embolization for liver injuries: low mortality, high morbidity.	2003	USA	3	67%
28	Severe blunt hepatic trauma in children.	1998	USA	25	36%
29	Hepatic trauma: analysis of the treatment with intrahepatic balloon in a university hospital of Curitiba.	2009	Brazil	2	50%
30	Operative and nonoperative management of blunt hepatic trauma in adults: a single-center report.	2004	Greece	3	100%
31	Place of arterial embolization in severe blunt hepatic trauma: a multidisciplinary approach.	2007	France	3	33%
32	Approach to the management of complex hepatic injuries.	1997	USA	9	22%
33	Outcome of children with blunt liver or spleen injuries: Experience from a single institution in Korea.	2016	Korea	2	50%

bypassing of the liver. The largest survival utilizing this procedure has been reported by Khaneja and colleagues,<sup>40</sup> who report 7 survivors out of 10 patients in whom this was attempted; however, the remainder of reported literature demonstrates a poor outcome in the patients who required this procedure to be undertaken, reflecting the high burden of injury and the relative limited use. More recently, a similar concept has gained traction in the form of the venovenous bypass as an adjunct, allowing decompression of the retro-hepatic IVC.<sup>41</sup>

## Hepatic Packing

Packing should be undertaken by initially fully mobilizing the liver, then returning the liver to its original anatomical shape (in the absence of major retro-hepatic IVC injury as mobilisation, if this is present without vascular control, will derooft the haematoma and exsanguination will occur). Antero-posterior compression should be avoided as this does not adequately tamponade the bleeding and can in effect compromise venous return and increase the size of any lacerations that are present.<sup>42–45</sup>

**Table 2** Operative Interventions Identified in the Literature

Operative Intervention	Number of Studies Reporting Technique
Packing	13(9)(10)(11)(12)(15)(16)(18)(19) (25)(26) (31)(32) (33)
Direct suture/hepatorraphy	7(10)(11)(19)(21)(25)(32)(33)
Selective hepatic artery ligation	2(11),(19)
Fibrin sealants	1(11)
Resection	8(9)(10)(13)(15)(25)(26) (31) (33)
Non-operative management	7(14)(16)(17)(22)(23)(25)(26)
Damage control surgery	2(10)(18)
Hepatectomy	6(9)(19)(20)(25)(30)(32)
Angioembolization	5 (21)(24)(27)(31)(32)
Intrahepatic balloon	1(29)

In bilobar hepatic injuries, it is sometimes extremely difficult to regain anatomical normality. It has been described that in such injuries the liver can be wrapped in an absorbable mesh to regain its correct anatomical shape, and then liver packing can proceed.<sup>46</sup> Packing can also be used as a stabilizing tool to allow the patient time to reach definitive care<sup>44,47</sup> or to correct any evidence of coagulopathy.<sup>48</sup>

The timing of removal of packs and re-look laparotomy still remains debated. It has been proven that the total duration of liver packing does not result in an increase in septic complications or bile leaks. The first re-look laparotomy should only be performed after 48 h. An early re-look at 24 h is associated with re-bleeding and does not lead to early removal of liver packs.<sup>49</sup>

## Partial Hepatic Resection

Overall, right hemi-hepatectomies are more common than left-sided resections in cases of blunt abdominal trauma, the main reason being a large size and dominant lay of the right lobe. Resection of the right lobe of the liver can be aided by dividing the right hepatic vein prior to attempted resection.<sup>50,51</sup>

## Total Hepatectomy

In cases where the liver and associated RHIVC damage is too extensive, there are case reports and small series that advocate total liver resection and transplantation as a two-stage

procedure. When packing fails to stem the bleeding from an RHIVC injury, Chiumello et al have described a successful case of total hepatectomy and a portocaval shunt followed by liver transplantation 36 hours later.<sup>52</sup>

Dominguez-Fernandez et al describe a series of eight emergency total hepatectomies, of which six patients survived to receive a transplant, with only one survivor. Ringe et al, who transplanted eight patients, noted a similar finding. There were two survivors, with the major cause of death being Multi-Organ Dysfunction Syndrome.<sup>53</sup>

## Angiographic Intervention

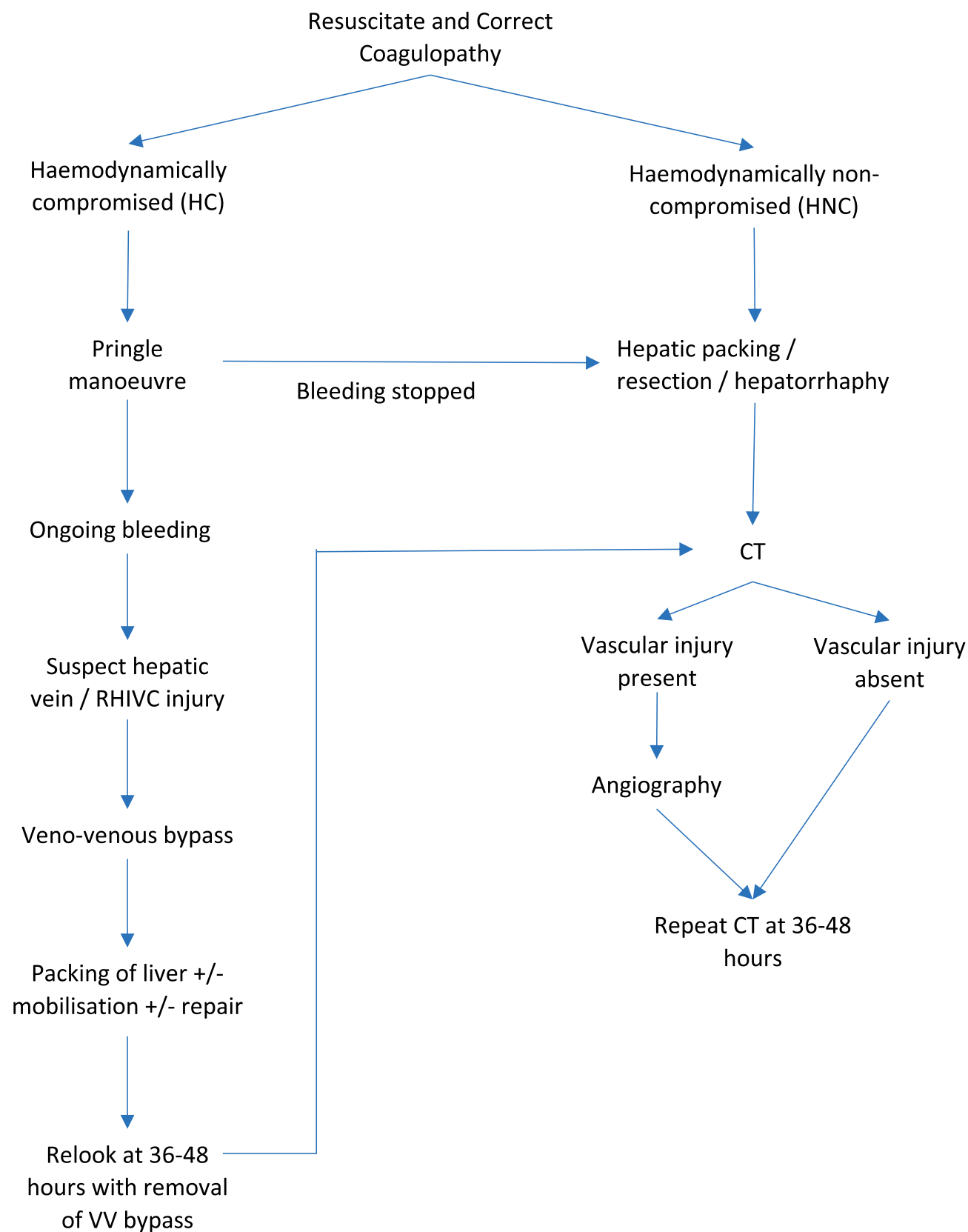
Angioembolization has been advocated in a number of case reports and case series for the management of bleeding in liver trauma<sup>54–56</sup> due to the association of hepatic intra-parenchymal arterial injury in the presence of high-grade liver injuries.<sup>57</sup>

Letoublon et al<sup>58</sup> report a series in which patients were embolized and the complication rates were acceptable given the high-grade liver injury. The patients were categorized as clinically unstable with active hepatic bleeding post liver trauma, and clinically stable with CT evidence of bleeding. Some advocate early or even prophylactic usage of angioembolization, if there is evidence of high-grade liver injury.<sup>31,59,60</sup> Non-operative management of high-grade liver injuries can be safely accomplished. A large multi-centre study<sup>22</sup> has demonstrated that the mortality is low. However, complications in grade 4 and 5 injuries should be anticipated, and may require a combination of operative and non-operative management strategies.

Angioembolization is not without risks. One of the largest series involving angioembolization<sup>61</sup> for major hepatic injury explored the incidence of complications associated with this intervention. A total of 116 patients with high-grade liver injury underwent angiography with 71 undergoing angioembolization. The overall complication risk for this group was 60%, with 30 patients (42.2%) suffering from major hepatic necrosis. Another study by the same institution<sup>24</sup> followed up on the above results and data collected led them to the conclusion that major hepatic necrosis can be managed by serial debridement, or if possible, early lobectomy may be the preferred treatment modality as it decreases re-operative and complication rates.

## Intrahepatic Balloon

The use of balloon tamponade was described by Smaniotto et al, whereby 110 mL of 0.9% saline was used to insufflate a balloon.<sup>29</sup> This group reported a 50% survival rate



**Figure 2** Proposed algorithm for RHIVC Injuries.



(n=2) advocating the reduction in surgical trauma achieving good haemostasis through a tamponading effect.

## Fibrin Sealants

Jung et al<sup>11</sup> describe the use of a fibrin sealant as a haemostatic device and animal studies have demonstrated preferential results over primary suture due to fewer intra-abdominal adhesions whilst allowing shorter haemostasis time in experimental data.<sup>62</sup>

## Proposed Algorithm

In view of the above-discussed strategies, we propose a treatment algorithm for RHIVC injuries (Figure 2). Initial management would be as per the Advanced Life Support Trauma guidelines of resuscitating the patient and then correcting coagulopathies to optimise planned surgical intervention. Furthermore, this approach would fit within established management strategies of such trauma patients within the Emergency Department setting. These include active warming, prompt fluid resuscitation with balanced electrolyte solutions, consideration of transfusion, permissive hypotension and early operative interventions, all dictated by the specific clinical context.<sup>63</sup> A decision can be made depending on whether the patient is haemodynamically compromised (HC) or not (HNC). If HC, the Pringle manoeuvre can be attempted to control bleeding. If bleeding is controlled, hepatic packing, resection or hepatorrhaphy can be performed in the same manner as if the patient were HNC. A CT can then be performed to identify if a vascular injury is present, which if positive should prompt angiography with repeat CT at 36–48 hours. If no vascular injury is identified, a repeat CT is also recommended at 36–48 hours post initial packing, resection or hepatorrhaphy.

However, if bleeding is not controlled with the Pringle manoeuvre, a surgeon should suspect a hepatic vein or RHIVC injury and undertake venovenous bypass with subsequent packing, mobilisation or repair of the liver. After 36–48 hours, relook should be performed with removal of the venovenous bypass. Following this, a repeat CT to assess for vascular injury as per the HNC pathway would be advocated.

## Limitations

This is the first systematic approach seeking to delineate the different operative strategies employed in the management of retro-hepatic inferior vena cava injuries. Given the heterogeneity of the data, further work is required to establish outcomes for specific interventions. Furthermore, studies

do not differentiate between the subdivisions of grade V liver injuries. Improved reporting of outcomes and patient comorbidities can help guide interventional management.

## Conclusion

The wide variety of operative interventions in the management of RHIVC injuries described above attest to the increased efforts to improve outcomes. The overall improvement in mortality can be noted since the earlier descriptions reported mortality approaching 100% compared to the 52% reported in this review. However, the aggregate mortality rate of 52% should be taken in context of the limitations of the heterogeneity of data available, but provides value to the existing body of literature by identifying that there are effective strategies in the management of retro-hepatic inferior vena cava injuries that can reduce mortality. These strategies have informed the proposed algorithm for management of retro-hepatic inferior vena cava injuries in this review. However, despite an overall average improvement in mortality significant variance in geographic location exists. Whilst this may reflect variance in the premorbid state it may indicate the impact of differences in practice and skill. The increased options available demand further study to identify the optimal strategy in managing high-grade hepatic injuries.

## Abbreviations

AAST, Americal Association of Surgery for Trauma; MeSH, Medical Subject Heading; RHIVC, Retro-Hepatic Inferior Vena Cava.

## Author Contributions

All authors contributed to data analysis, drafting or revising the article, gave final approval of the version to be published, and agree to be accountable for all aspects of the work.

## Disclosure

The authors declare that they have no competing interests.

## References

1. Cogbill TH, Moore EE, Jurkovich GJ, Feliciano DV, Morris JA, Mucha P. Severe hepatic trauma: a multi-center experience with 1,335 liver injuries. *J Trauma*. 1988;28:1433–1438. doi:10.1097/00005373-198810000-00004
2. Cox EF, Flancbaum L, Dauterive AH, Paulson RL. Blunt trauma to the liver. Analysis of management and mortality in 323 consecutive patients. *Ann Surg*. 1988;207:126–134. doi:10.1097/00000658-198802000-00003

3. Schrock T, Blaisdell FW, Mathewson C. Management of blunt trauma to the liver and hepatic veins. *Arch Surg*. 1968;96(5):698–704. doi:10.1001/archsurg.1968.01330230006002
4. Misra B, Wagner R, Boneval H. Injuries of hepatic veins and retro-hepatic vena cava. *Am Surg*. 1983;49:55–60.
5. Moore EE, Cogbill TH, Jurkovich GJ, Shackford SR, Malangoni MA, Champion HR. Organ injury scaling: spleen and liver (1994 revision). *J Trauma*. 1995;38(3):323–324. doi:10.1097/00005373-199503000-00001
6. Buechter KJ, Sereda D, Gomez G, Zeppa R. Retrohepatic vein injuries: experience with 20 cases. *J Trauma*. 1989;29:1698–1704. doi:10.1097/00005373-198912000-00020
7. Pons PT, Honigman B, Moore EE, Rosen P, Antuna B, Dernocoeur J. Prehospital advanced trauma life support for critical penetrating wounds to the thorax and abdomen. *J Trauma*. 1985;25(9):828–832. doi:10.1097/00005373-198509000-00003
8. Feliciano DV, Pachter HL. Hepatic trauma revisited. *Curr Probl Surg*. 1989;26(7):453–524. doi:10.1016/0011-3840(89)90014-2
9. Kaptanoglu L, Kurt N, Sikar HE. Current approach to liver traumas. *Int J Surg*. 2017;39:255–259. doi:10.1016/j.ijsu.2017.02.015
10. Doklestić K, Djukić V, Ivančević N, et al. Severe blunt hepatic trauma in polytrauma patient - management and outcome. *Srp Arh Celok Lek*. 2015;143:416–422. doi:10.2298/SARH1508416D
11. Jung K, Kim Y, Heo Y, et al. Management of severe blunt liver injuries by applying the damage control strategies with packing-oriented surgery: experiences at a single institution in Korea. *Hepatogastroenterology*. 2015;62:410–416.
12. Bilgiç İ, Gelecek S, Akgün AE, Özmen MM. Evaluation of liver injury in a tertiary hospital: a retrospective study. *Ulus Travma Acil Cerrahi Derg*. 2014;20:359–365. doi:10.5505/tjtes.2014.22074
13. Arslan S, Güzel M, Turan C, Doğanay S, Doğan AB, Aslan A. Management and treatment of liver injury in children. *Ulus Travma Acil Cerrahi Derg*. 2014;20:45–50. doi:10.5505/tjtes.2014.58295
14. Bala M, Gazalla SA, Faroja M, et al. Complications of high grade liver injuries: management and outcome with focus on bile leaks. *Scand J Trauma Resusc Emerg Med*. 2012;20:20. doi:10.1186/1757-7241-20-20
15. Prichayudh S, Sirinawin C, Sriussadaporn S, et al. Management of liver injuries: predictors for the need of operation and damage control surgery. *Injury*. 2014;45:1373–1377. doi:10.1016/j.injury.2014.02.013
16. Li M, Yu W-K, Wang X-B, Ji W, Li J-S LN. Non-operative management of isolated liver trauma. *Hepatobiliary Pancreat Dis Int*. 2014;13:545–550. doi:10.1016/s1499-3872(14)60049-7
17. Asfar S, Khourshed M, Al-Saleh M, et al. Management of liver trauma in Kuwait. *Med Princ Pract*. 2014;23:160–166. doi:10.1159/000358126
18. Yadav SK, Kumar S, Misra MC, Sagar S, Bansal VK. Retrospective evaluation of magnitude, severity and outcome of traumatic hepatobiliary injury at a Level-I trauma center in India. *Indian J Surg*. 2016;78:281–287. doi:10.1007/s12262-015-1356-y
19. Lin B-C, Fang J-F, Chen R-J, Wong Y-C, Hsu Y-P. Surgical management and outcome of blunt major liver injuries: experience of damage control laparotomy with perihepatic packing in one trauma centre. *Injury*. 2014;45:122–127. doi:10.1016/j.injury.2013.08.022
20. Guglielmo N, Melandro F, Improta L, et al. Early right hepatectomy for severe liver trauma: a case report. *Clin Ter*. 2015;166:e108–10. doi:10.7417/CT.2015.1830
21. Saltzherr TP, van der Vlies CH, van Lienden KP, et al. Improved outcomes in the non-operative management of liver injuries. *HPB (Oxford)*. 2011;13:350–355. doi:10.1111/j.1477-2574.2011.00293.x
22. Kozar RA, Moore JB, Niles SE, et al. Complications of nonoperative management of high-grade blunt hepatic injuries. *J Trauma*. 2005;59:1066–1071. doi:10.1097/01.ta.0000188937.75879.ab
23. Christmas AB, Wilson AK, Manning B, et al. Selective management of blunt hepatic injuries including nonoperative management is a safe and effective strategy. *Surgery*. 2005;138:606–10; discussion 610. doi:10.1016/j.surg.2005.07.018
24. Dabbs DN, Stein DM, Scalea TM. Major hepatic necrosis: a common complication after angioembolization for treatment of high-grade liver injuries. *J Trauma*. 2009;66:621–7; discussion 627. doi:10.1097/TA.0b013e31819919f2
25. Veroux M, Cillo U, Brolese A, et al. Blunt liver injury: from non-operative management to liver transplantation. *Injury*. 2003;34:181–186. doi:10.1016/S0020-1383(02)00283-8
26. Suen K, Skandarajah AR, Knowles B, Judson R, Thomson BN. Changes in the management of liver trauma leading to reduced mortality: 15-year experience in a major trauma centre. *ANZ J Surg*. 2016;86:894–899. doi:10.1111/ans.13248
27. Mohr AM, Lavery RF, Barone A, et al. Angiographic embolization for liver injuries: low mortality, high morbidity. *J Trauma*. 2003;55:1077–81; discussion 1081. doi:10.1097/01.TA.0000100219.02085.AB
28. Pryor JP, Stafford PW, Nance ML. Severe blunt hepatic trauma in children. *J Pediatr Surg*. 2001;36:974–979. doi:10.1053/jpsu.2001.24720
29. Smaniotto B, Bahten LCV, Nogueira Filho DC, Tano AL, Thomaz Junior L, Fayad O. Hepatic trauma: analysis of the treatment with intrahepatic balloon in a university hospital of Curitiba. *Rev Col Bras Cir*. 2009;36:217–222. doi:10.1590/S0100-69912009000300007
30. Gourgoutis S, Vougas V, Germanos S, et al. Operative and nonoperative management of blunt hepatic trauma in adults: a single-center report. *J Hepatobiliary Pancreat Surg*. 2007;14(4):387–391. doi:10.1007/s00534-006-1177-2
31. Monnin V, Sengel C, Thony F, et al. Place of arterial embolization in severe blunt hepatic trauma: a multidisciplinary approach. *Cardiovasc Intervent Radiol*. 2008;31:875–882. doi:10.1007/s00270-007-9277-1
32. Asensio JA, Demetriades D, Chahwan S, et al. Approach to the management of complex hepatic injuries. *J Trauma*. 2000;48:66–69. doi:10.1097/00005373-200001000-00011
33. Kim KH, Kim JS, Kim -W-W. Outcome of children with blunt liver or spleen injuries: experience from a single institution in Korea. *Int J Surg*. 2017;38:105–108. doi:10.1016/j.ijsu.2016.12.119
34. Ciresi KF, Lim RC. Hepatic vein and retrohepatic vena cava injury. *World J Surg*. 1990;14:472–477. doi:10.1007/BF01658670
35. Rivkind AI, Siegel JH, Dunham CM. Patterns of organ injury in blunt hepatic trauma and their significance for management and outcome. *J Trauma*. 1989;29:1398–1415. doi:10.1097/00005373-198910000-00019
36. Watson DI, Williams JA. Management of the traumatized liver: an appraisal of 63 cases. *Aust N Z J Surg*. 1989;59:137–142. doi:10.1111/j.1445-2197.1989.tb01484.x
37. Di Saverio S, Catena F, Filicori F, et al. Predictive factors of morbidity and mortality in grade IV and V liver trauma undergoing perihepatic packing: single institution 14 years experience at European trauma centre. *Injury*. 2012;43:1347–1354. doi:10.1016/j.injury.2012.01.003
38. Demetriades D, Gomez H, Chahwan S, et al. Gunshot injuries to the liver: the role of selective nonoperative management. *J Am Coll Surg*. 1999;188:343–348. doi:10.1016/S1072-7515(98)00315-9
39. Moulton SL, Lynch FP, Canty TG, Collins DL, Hoyt DB. Hepatic vein and retrohepatic vena cava injuries in children: Sternotomy First? *Arch Surg*. 1991;126(10):1262–1266. doi:10.1001/archsurg.1991.01410340104014
40. Khaneja SC, Pizzi WF, Barie PS, Ahmed N. Management of penetrating juxtahepatic inferior vena cava injuries under total vascular occlusion. *J Am Coll Surg*. 1997;184:469–474.
41. Baumgartner F, Scudamore C, Nair C, Karusseit O, Hemming A. Venovenous bypass for major hepatic and caval trauma. *J Trauma*. 1995;39:671–673. doi:10.1097/00005373-199510000-00009
42. Erdek MA, Brotman S. Liver packing for uncontrolled hepatic haemorrhage after trauma. *Eur J Emerg Med*. 1994;1:88–91. doi:10.1097/00063110-199406000-00009
43. Krige JE, Bornman PC, Terblanche J. Therapeutic perihepatic packing in complex liver trauma. *Br J Surg*. 1992;79:43–46. doi:10.1002/bjs.1800790114



44. Hollands MJ, Little JM. Perihepatic packing: its role in the management of liver trauma. *Aust N Z J Surg.* 1989;59:21–24. doi:10.1111/j.1445-2197.1989.tb01459.x
45. Ferguson CM. Hepatic packing in major hepatic trauma. *Arch Surg.* 1989;124(4):508–509. doi:10.1001/archsurg.1989.01410040118030
46. Cirocchi R, Contine A, Mazieri M, et al. [Perihepatic packing combined with wrapping in the treatment of major bi-lober hepatic trauma]. *Chir Ital.* 1999;51(3):259–264. Italian.
47. Calne RY, McMaster P, Pentlow BD. The treatment of major liver trauma by primary packing with transfer of the patient for definitive treatment. *Br J Surg.* 1979;66(5):338–339. doi:10.1002/bjs.1800660512
48. Myrthøj T, Møller P. Liver packing and planned reoperation in the management of severe hepatic trauma. *Ann Chir Gynaecol.* 1987;76:215–217.
49. Nicol AJ, Hommes M, Primrose R, Navsaria PH, Krige JEJ. Packing for control of hemorrhage in major liver trauma. *World J Surg.* 2007;31(3):569–574. doi:10.1007/s00268-006-0070-0
50. Chen X, Qiu F, Wu Z, Zhang Z, Chen Y, Zhang B. [Massive hemorrhage in hepatectomy: causes and management]. *Zhonghua Wai Ke Za Zhi.* 2003;41:172–174. English.
51. Chen Y-L, Kuo S-J, Yang L-H, Chen S-T, Tsai J-H, Chang H-C. Extrahepatic division of the right hepatic vein in right hepatectomy for blunt liver trauma. *Int Surg.* 2003;88:15–20.
52. Chiumello D, Gatti S, Caspani L, Savioli M, Fassati R, Gattinoni L. A blunt complex abdominal trauma: total hepatectomy and liver transplantation. *Intensive Care Med.* 2002;28:89–91. doi:10.1007/s00134-001-1162-9
53. Ringe B, Pichlmayr R. Total hepatectomy and liver transplantation: a life-saving procedure in patients with severe hepatic trauma. *Br J Surg.* 1995;82(6):837–839. doi:10.1002/bjs.1800820637
54. Fandrich BL, Gnanadev DA, Jaecks R, Boyle W. Selective hepatic artery embolization as an adjunct to liver packing in severe hepatic trauma: case report. *J Trauma.* 1989;29:1716–1718. doi:10.1097/00005373-198912000-00024
55. Ong CCP, Toh L, Lo RHG, Yap T-L, Narasimhan K. Primary hepatic artery embolization in pediatric blunt hepatic trauma. *J Pediatr Surg.* 2012;47:2316–2320. doi:10.1016/j.jpedsurg.2012.09.050
56. Kanakis MA, Thomas T, Martinakis VG, Brountzos E, Varsamidakis N. Successful management of severe blunt hepatic trauma by angiographic embolization. *Updates Surg.* 2012;64:303–306. doi:10.1007/s13304-011-0122-3
57. Sugimoto K, Horiike S, Hirata M, Ohwada T, Maekawa K. The role of angiography in the assessment of blunt liver injury. *Injury.* 1994;25:283–287. doi:10.1016/0020-1383(94)90236-4
58. Letoublon C, Morra I, Chen Y, Monnin V, Voirin D, Arvieux C. Hepatic arterial embolization in the management of blunt hepatic trauma: indications and complications. *J Trauma.* 2011;70:1032–6; discussion 1036. doi:10.1097/TA.0b013e31820e7ca1
59. Yi IK, Miao FLP, Wong J, et al. Prophylactic embolization of hepatic artery pseudoaneurysm after blunt abdominal trauma in a child. *J Pediatr Surg.* 2010;45:837–839. doi:10.1016/j.jpedsurg.2010.01.021
60. Greco L, Francioso G, Praticchizzo A, Testini M, Impedovo G, Ettorre GC. Arterial embolization in the treatment of severe blunt hepatic trauma. *Hepatogastroenterology.* 2003;50:746–749.
61. Dabbs DN, Stein DM, Philosophie B, Scalea TM. Treatment of major hepatic necrosis: lobectomy versus serial debridement. *J Trauma.* 2010;69:562–567. doi:10.1097/TA.0b013e3181ebf591
62. Demirel AH, Basar OT, Ongoren AU, Bayram E, Kisakurek M. Effects of primary suture and fibrin sealant on hemostasis and liver regeneration in an experimental liver injury. *World J Gastroenterol.* 2008;14:81–84. doi:10.3748/wjg.14.81
63. Spahn DR, Bouillon B, Cerny V, et al. The European guideline on management of major bleeding and coagulopathy following trauma: fifth edition. *Crit Care.* 2019;23:98.

## Open Access Emergency Medicine

### Publish your work in this journal

The Open Access Emergency Medicine is an international, peer-reviewed, open access journal publishing original research, reports, editorials, reviews and commentaries on all aspects of emergency medicine. The manuscript management system is completely online

Submit your manuscript here: <https://www.dovepress.com/open-access-emergency-medicine-journal>

and includes a very quick and fair peer-review system, which is all easy to use. Visit <http://www.dovepress.com/testimonials.php> to read real quotes from published authors.

Dovepress