

Response to Afatinib in a Patient with NSCLC Harboring Novel *EGFR* Exon 20 Insertion Mutations

This article was published in the following Dove Press journal:
OncoTargets and Therapy

Ling Lin^{1,*}
Xiaomai Wu^{1,*}
Shuangquan Yan¹
Yefei Zhu¹
Zhengqing Yan²
Dongqing Lv¹
Hongfei Ge³

¹Department of Respiratory Medicine, Taizhou Hospital of Wenzhou Medical University, Taizhou, People's Republic of China; ²The Medical Department, 3D Medicines Inc., Shanghai, People's Republic of China; ³Department of Thoracic Surgery, Taizhou Hospital of Wenzhou Medical University, Taizhou, People's Republic of China

*These authors contributed equally to this work

Purpose: Most epidermal growth factor receptor (*EGFR*) exon 20 insertion (*ex20ins*) mutations are resistant to tyrosine kinase inhibitors (TKIs). While some non-small cell lung cancer (NSCLC) patients harboring special subtypes of *EGFR* *ex20ins* still achieved clinical response after TKIs treatment, identifying special subtypes of *EGFR* *ex20ins* is helpful to find out NSCLC patients who can respond to TKIs.

Case Presentation: A 71-year-old non-smoker Chinese female was diagnosed with advanced lung adenocarcinoma harboring *EGFR* *ex20ins* (N771delinsKG). The patient received first-line afatinib (40 mg/day) therapy and a significant and substantial reduction in tumor size was observed subsequently. According to RESIST 1.1, a radiological partial response was achieved. The final progression-free survival was 10 months.

Conclusion: This is the first published case report of *EGFR* N771delinsKG lung adenocarcinoma, which highlighted the heterogeneity of clinical response to TKIs for *EGFR* *ex20ins*-mutant NSCLC. Such results need to be further investigated in prospective studies.

Keywords: afatinib, lung adenocarcinoma, *EGFR* exon 20 insertions, next generation sequencing

Introduction

Epidermal growth factor receptor (*EGFR*) tyrosine kinase inhibitors (TKIs) have improved the pharmacological management of lung cancer significantly and become the standard first-line treatment for *EGFR*-mutant non-small cell lung cancer (NSCLC).¹ The percentage of lung adenocarcinoma with *EGFR* mutations are about 10% and 50% in Western countries and East Asians, respectively. The classic *EGFR* mutations, including *EGFR* del in exon 19 and the L858R in exon 21, account for approximately 90% of all *EGFR* mutation-positive cases. The lung adenocarcinoma harboring such classic *EGFR* mutations is usually sensitive to TKIs. The remaining 10% of *EGFR* mutations are uncommon *EGFR* alterations within exons 18–21. Among these uncommon mutations, about 50% are *EGFR* exon 20 insertions (*ex20ins*).² Until now, some preclinical and clinical studies have explored the clinical response to TKIs in NSCLC with *EGFR* *ex20ins* mutations. Since *EGFR* *ex20ins* mutations produced steric hindrance and activated *EGFR* without markedly decreasing affinity for ATP or enhancing affinity for TKIs, NSCLC harboring *EGFR* *ex20ins* mutations were usually resistant to the first and second generation TKIs. A combined post hoc analysis of LUX-Lung 2, LUX-Lung 3, and LUX-Lung 6 trials revealed that 23 NSCLC patients with *EGFR* *ex20ins* treated with afatinib had an objective response (ORR) of 8.7% and a median

Correspondence: Dongqing Lv; Hongfei Ge
Email Lvdq@enzemed.com;
geh@enzemed.com

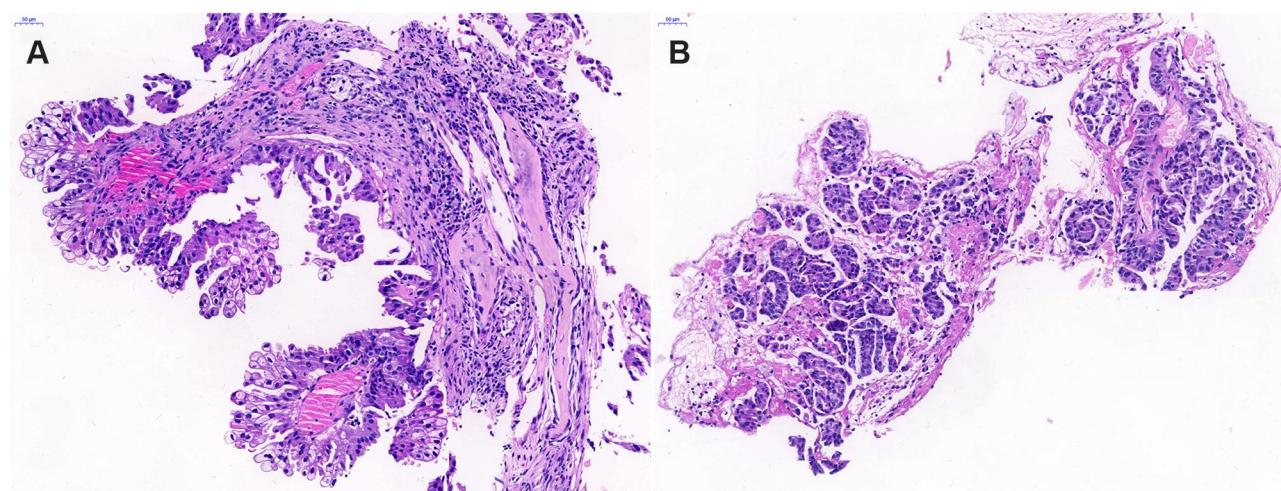


Figure 1 Hematoxylin-eosin (HE) staining for pathological diagnosis in (A) right and (B) left pulmonary lesions showing lung adenocarcinoma.

progression-free survival (PFS) of 2.7 months.³ In another Chinese real world study, 165 advanced *EGFR* ex20ins NSCLC patients were included to compare the clinical outcomes of chemotherapy and all generation TKIs. The median PFS was 6.4 for chemotherapy and 2.9 months for all generation TKIs.⁴ Considering the aforementioned unsatisfactory results, TKIs seems not to be a good choice for patients harboring *EGFR* ex20ins. Until now, there are still no established molecular targeted drugs for NSCLC patients with *EGFR* ex20ins.

However, to the best of our knowledge, a few reported cases also suggested that some subtypes of *EGFR* ex20ins could benefit from TKIs. For example, Yasuda et al⁵, and Voon et al⁶ reported the NSCLC patients harboring *EGFR* A763_764insFQEA demonstrated tumor regression and stable disease (SD) following erlotinib treatment, respectively. Chan et al⁷ reported a patient with *EGFR* A767_S768insSVA exhibited SD for 25 months with afatinib treatment. A patient with *EGFR* A767delinsASVD achieved partial response (PR) with afatinib treatment and PFS of 7.4 months.⁸ Jänne et al⁹ reported one patient harboring *EGFR* D770delinsGY, who achieved PR after dacomitinib treatment. Another patient harboring *EGFR* S768_D770dup could respond to osimertinib with PFS of over 5 months.¹⁰ In a retrospective study, six patients harboring *EGFR* ex20ins received osimertinib with median PFS for 6.2 months. Among them, four patients (*EGFR* A767_V769dup, S768_D770dup, D770_N771insG, and A763_Y764insFQEA&T790M) achieved PR, and two cases (S768_D770dup and D770_N771insG) received SD.¹¹ These cases suggested that some special subtypes of *EGFR* ex20ins mutations might respond to TKIs. Identifying and

distinguishing subtypes of *EGFR* ex20ins, which respond to TKIs, is an important issue for NSCLC patients. Herein, we presented a novel *EGFR* ex20ins (N771delinsKG) patient who could benefit from afatinib treatment.

Case Presentation

A 71-year-old non-smoker Chinese female was diagnosed with lung adenocarcinoma with multiple metastases in bilateral lung and mass in the right chest with osteolytic bone destruction in the sixth rib in May 2019 (Figure 1). The tumor node metastasis (TNM) classification of this patient was T4N3M1. Before treatment, her tumor DNA extracted from tissue was subjected to DNA sequencing analysis by next-generation sequencing (NGS). The sequencing results in Figure 2 suggested that the patient had a novel *EGFR* ex20ins (N771delinsKG) mutation. Based on the NGS results, the patient started to receive first-line treatment with afatinib (40 mg/day) in July 2019. Before the treatment, the computed tomography (CT) scans indicated that the size of tumor lesions located in the left lower lung and right chest were 62.6 mm×60.9 mm and 58.3 mm×46.7 mm, respectively (Figure 3A). In addition, multiple small nodules appeared in bilateral lungs. After one month of afatinib treatment, the size of the lesion in the left lower lung reduced markedly and that of the tumor lesion in the right lung was stable (Figure 3B). After four months of treatment (November 2019), the size of these lesions further decreased. As shown in Figure 3C, one lesion in the left lower lung became obscure and unmeasurable, and the size of another lesion in the right chest was decreased to 43.7 mm×37.2 mm. Notably, the size of multiple small nodules in bilateral lungs




Figure 2 Molecular analysis of gene detection. The integrative genomics viewer snapshot of *EGFR* N771delinsKG (c.2312_2313insGGG) by next-generation sequencing (NGS).

also significantly reduced after treatment. According to the response evaluation criteria in solid tumors (RESIST 1.1), she achieved a radiological PR. No grade three or higher adverse events (AEs) occurred. The treatment-related AEs associated with afatinib were grade 1 or 2 diarrhea, skin rash, paronychia, and stomatitis without treatment interruption. These AEs occurred during the first month of afatinib treatment and relieved with corresponding symptomatic treatments. Until May 2020, progressive disease was observed due to the enlarged tumor lesions. The final PFS was 10 months.

Ethics Statement

This case was approved by the Medical Ethics Committee of the Taizhou Hospital of Wenzhou Medical University. Written informed consent was obtained from the patient for publishing the case details and accompanying images.

Discussion

In this case, the Chinese female with advanced lung adenocarcinoma harboring a novel *EGFR* N771delinsKG achieved PR and the PFS exceeded 8 months. Such exciting results highlighted the heterogeneity of clinical response to TKIs for *EGFR* ex20ins.^{12,13} More than 90% of *EGFR* ex20ins are located behind the C-helix of the *EGFR* kinase domain (S768 to V774). Especially, V769_D770insASV and *EGFR* D770_N771insSVD are common *EGFR* ex20ins mutations. Less than 10% of all *EGFR* ex20ins mutations occurred within the C-helix (E762 to M766).^{4,14,15}

It was reported that *EGFR* A763_Y764insFQEA, which occurred within the C-helix of *EGFR*, was associated with sensitivity to available TKIs.^{5,6} Besides, most *EGFR* ex20ins mutations were resistant to available TKIs. In 2013, Yasuda et al⁴ reported the first crystal structure of a representative *EGFR* D770_N771insNPG, which provided valuable insights into understanding the relationship between *EGFR* ex20ins and *EGFR* activation or TKIs resistance. It revealed *EGFR* D770_N771insNPG located towards the C-terminal end of the C-helix, which was a key regulatory factor that activated *EGFR* via rotating it to form active conformation. Moreover, it pointed out that *EGFR* D770_N771insNPG was able to activate *EGFR* without decreasing ATP affinity or enhancing the affinity of the TKIs markedly. Another research involving 3D modeling of *EGFR* D770_N771insNPG suggested that such an alteration could result in a prominent shift of the C-helix and phosphate-binding loop (p-loop) and subsequently restrict the size of the drug-binding pocket.¹⁶ Considering that, *EGFR* ex20ins located in the p-loop of *EGFR* seems to be associated with insensitivity to TKIs. However, there are still some cases of *EGFR* ex20ins, which, located within p-loop, achieved clinical response to TKIs. For example, Jänne et al⁹ reported that one patient harboring *EGFR* D770delinsGY achieved PR after dacomitinib therapy. Three patients (*EGFR* A767_V769dup, S768_D770dup, and D770_N771insG) achieved PR and two cases (S768_D770dup and D770_N771insG) received SD during osimertinib treatment.¹¹ In this case *EGFR* N771delinsKG also

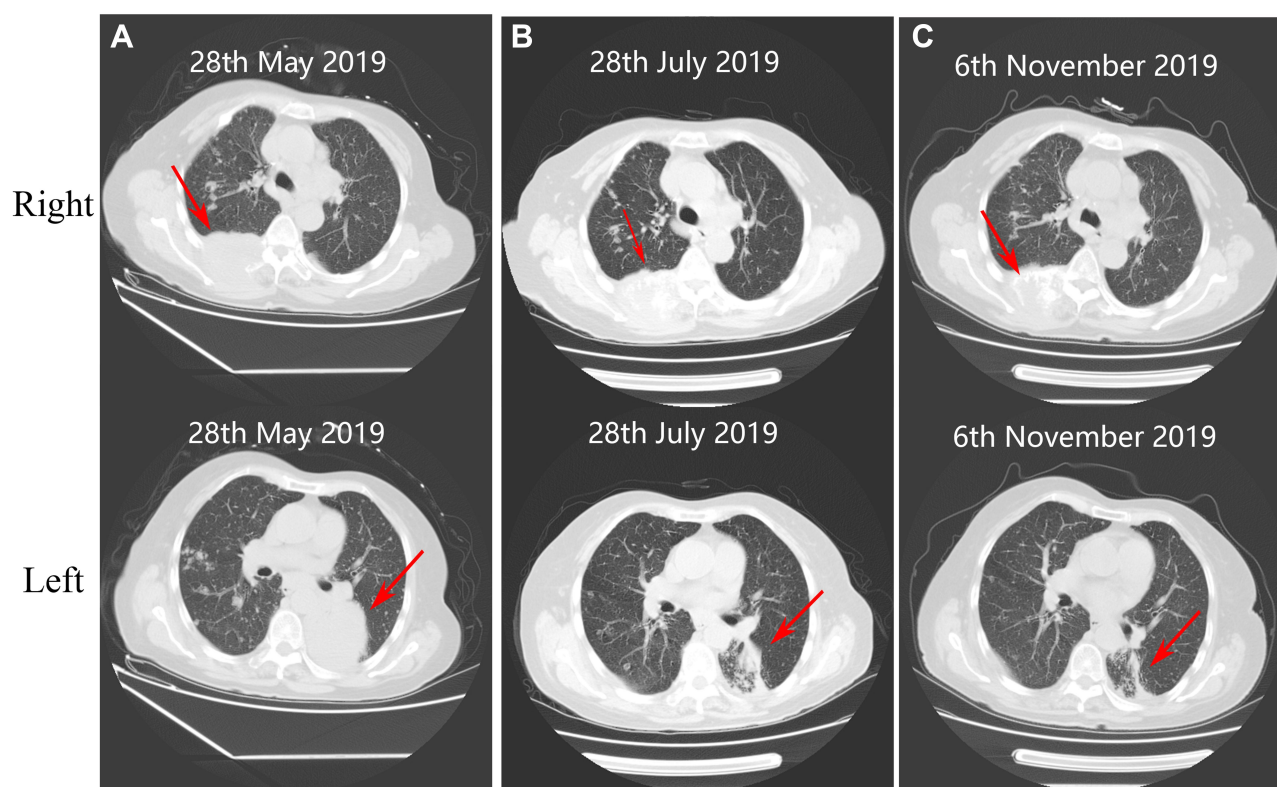


Figure 3 Computed tomography (CT) scans at different time. (A) Baseline imaging (before treatment) of right and left pulmonary lesions, respectively. After (B) 1 month (July 28, 2019) and (C) 4 months (November 6, 2019) of treatment, the mass in the left pulmonary lesion reduced significantly and the right pulmonary lesion decreased slightly, compared with that of baseline imaging.

occurred in the p-loop region and demonstrated exciting clinical response to second generation TKI afatinib. By the way, the rare *EGFR* ex20ins N771delinsKG in the present case was not described previously. Considering such exciting results, *EGFR* N771delinsKG might be attributed to a special subtype of *EGFR* ex20ins that was sensitive to afatinib. Additional in vitro and structural studies are needed to explain why some subtypes but not all respond to TKIs.

Given the significant molecular heterogeneity of *EGFR* ex20ins, it would be important to identify the *EGFR* subtypes who respond to TKIs. The position, the size, and subtype of inserted amino acids in *EGFR* ex20ins might confer the clinical heterogeneity to TKIs. With the development of NGS technology, more special mutation types of *EGFR* ex20ins would be identified due to its high accuracy, high throughput, and rich information content. In this case, the identification of *EGFR* ex20ins N771delinsKG benefited from the usage of NGS.

Considering the nature of the case report, some important issues still need to be studied. It is necessary to explore the potential mechanism for *EGFR* ex20ins-

mutant NSCLC patients, who respond to TKIs. In addition, the long-term clinical durability of TKIs towards lung carcinoma harboring *EGFR* ex20ins remain unclear. To our best knowledge, several clinical trials have been carried out to study TKIs on NSCLC with *EGFR* ex20ins, and some of them demonstrated preliminary promising activity.^{10,17,18} With the development of various TKIs, identifying and distinguishing novel subtypes of *EGFR* ex20ins might be more crucial for *EGFR* mutant NSCLC to choose suitable agents.

Conclusion

Overall, we first reported a lung adenocarcinoma patient harboring a novel *EGFR* ex20ins mutation (N771delinsKG) benefited from afatinib treatment. Our findings highlighted the heterogeneity of clinical response to TKIs in *EGFR* ex20ins-mutant NSCLC. Further investigations need to be carried out to confirm these results.

Funding

The authors thank the patient for his participation and his agreement to the publication of the report. This work was

supported by the Medical Science and Technology Project Foundation of Zhejiang Province of China (2015KYB439) and Scientific Research Fund of Taizhou Science and Technology Agency (1601KY05 and 1801KY19).

Disclosure

Zhengqing Yan is an employee of 3D Medicines Inc. The author reports no other potential conflicts of interest in this work.

References

- Loong HH, Kwan SS, Mok TS, Lau YM. Therapeutic strategies in EGFR mutant non-small cell lung cancer. *Curr Treat Options Oncol*. 2018;19(11):58. doi:10.1007/s11864-018-0570-9
- Sharma SV, Bell DW, Settleman J, Haber DA. Epidermal growth factor receptor mutations in lung cancer. *Nat Rev Cancer*. 2007;7(3):169–181.
- Yang JCH, Sequist LV, Geater SL, et al. Clinical activity of afatinib in patients with advanced non-small-cell lung cancer harbouring uncommon EGFR mutations: a combined post-hoc analysis of LUX-lung 2, LUX-lung 3, and LUX-lung 6. *Lancet Oncol*. 2015;16(7):830–838. doi:10.1016/S1470-2045(15)00026-1
- Yang G, Li J, Xu H, et al. EGFR exon 20 insertion mutations in Chinese advanced non-small cell lung cancer patients: molecular heterogeneity and treatment outcome from nationwide real-world study. *Lung Cancer*. 2020.
- Yasuda H, Park E, Yun CH, et al. Structural, biochemical, and clinical characterization of epidermal growth factor receptor (EGFR) exon 20 insertion mutations in lung cancer. *Sci Transl Med*. 2013;5(216):216ra177. doi:10.1126/scitranslmed.3007205
- Voon PJ, Tsui DW, Rosenfeld N, Chin TM. EGFR exon 20 insertion A763-Y764insFQEA and response to erlotinib—Letter. *Mol Cancer Ther*. 2013;12(11):2614–2615. doi:10.1158/1535-7163.MCT-13-0192
- Chan RT. Afatinib for an EGFR exon 20 insertion mutation: a case report of progressive stage IV metastatic lung adenocarcinoma with 54 months' survival. *Asia Pac J Clin Oncol*. 2018;14(Suppl 1):7–9. doi:10.1111/ajco.12853
- Cai Y, Wang X, Guo Y, et al. Successful treatment of a lung adenocarcinoma patient with a novel EGFR exon 20-ins mutation with afatinib: a case report. *Medicine*. 2019;98(1):e13890. doi:10.1097/MD.00000000000013890
- Janne PA, Boss DS, Camidge DR, et al. Phase I dose-escalation study of the pan-HER inhibitor, PF299804, in patients with advanced malignant solid tumors. *Clin Cancer Res*. 2011;17(5):1131–1139. doi:10.1158/1078-0432.CCR-10-1220
- Piotrowska Z, Fintelmann FJ, Sequist LV, Jahagirdar B. Response to osimertinib in an EGFR exon 20 insertion-positive lung adenocarcinoma. *J Thorac Oncol*. 2018;13(10):e204–e6. doi:10.1016/j.jtho.2018.05.017
- Fang W, Huang Y, Hong S, et al. EGFR exon 20 insertion mutations and response to osimertinib in non-small-cell lung cancer. *BMC Cancer*. 2019;19(1):595. doi:10.1186/s12885-019-5820-0
- Kobayashi Y, Mitsudomi T. Not all epidermal growth factor receptor mutations in lung cancer are created equal: perspectives for individualized treatment strategy. *Cancer Sci*. 2016;107(9):1179–1186.
- Arcila ME, Nafa K, Chaffa JE, et al. EGFR exon 20 insertion mutations in lung adenocarcinomas: prevalence, molecular heterogeneity, and clinicopathologic characteristics. *Mol Cancer Ther*. 2013;12(2):220–229. doi:10.1158/1535-7163.MCT-12-0620
- Vyse S, Huang PH. Targeting EGFR exon 20 insertion mutations in non-small cell lung cancer. *Signal Transduct Target Ther*. 2019;4(1):5. doi:10.1038/s41392-019-0038-9
- Yasuda H, Kobayashi S, Costa DB. EGFR exon 20 insertion mutations in non-small-cell lung cancer: preclinical data and clinical implications. *Lancet Oncol*. 2012;13(1):e23–e31. doi:10.1016/S1470-2045(11)70129-2
- Robichaux JP, Elamin YY, Tan Z, et al. Mechanisms and clinical activity of an EGFR and HER2 exon 20-selective kinase inhibitor in non-small cell lung cancer. *Nat Med*. 2018;24(5):638–646. doi:10.1038/s41591-018-0007-9
- Fang W, Huang Y, Gan J, Shao YW, Zhang L. Durable response of low-dose afatinib plus cetuximab in an adenocarcinoma patient with a novel EGFR exon 20 insertion mutation. *J Thorac Oncol*. 2019;14(10):e220–e1. doi:10.1016/j.jtho.2019.05.023
- Hasegawa H, Yasuda H, Hamamoto J, et al. Efficacy of afatinib or osimertinib plus cetuximab combination therapy for non-small-cell lung cancer with EGFR exon 20 insertion mutations. *Lung Cancer*. 2019;127:146–152. doi:10.1016/j.lungcan.2018.11.039

OncoTargets and Therapy

Publish your work in this journal

OncoTargets and Therapy is an international, peer-reviewed, open access journal focusing on the pathological basis of all cancers, potential targets for therapy and treatment protocols employed to improve the management of cancer patients. The journal also focuses on the impact of management programs and new therapeutic

agents and protocols on patient perspectives such as quality of life, adherence and satisfaction. The manuscript management system is completely online and includes a very quick and fair peer-review system, which is all easy to use. Visit <http://www.dovepress.com/testimonials.php> to read real quotes from published authors.

Submit your manuscript here: <https://www.dovepress.com/oncotargets-and-therapy-journal>

Dovepress