

Misplaced intrauterine contraceptive device: an enigma

Aruna Nigam
Ratna Biswas
Archana Mishra

Department of Obstetrics and
Gynaecology, Lady Hardinge Medical
College, New Delhi, India

Abstract: Intrauterine contraceptive device (IUCD) migration subsequent to uterine wall perforation is an uncommon but serious complication. Three cases of misplaced IUCD at three different sites, ie, posterior fornix, rectal wall, and mesoappendix, are reported. An IUCD thread coming through the posterior fornix is reported in the literature for the first time.

Keywords: intrauterine device, contraception, migration, laparoscopy

Introduction

The intrauterine contraceptive device (IUCD) is one of the most effective and popular methods of contraception worldwide, especially in developing countries like India. IUCD migration subsequent to uterine perforation is an uncommon but serious complication.¹ Three cases of misplaced IUCD at three different sites, ie, the posterior fornix, rectal wall, and mesoappendix, are reported.

Case 1

A 28-year-old female (G3P2L2; gravida 3, parity 2, and live issue 2) with two months of amenorrhea presented to a family planning clinic. She had had an IUCD insertion two years earlier. Per speculum examination showed an IUCD thread coming through the posterior fornix (Figure 1). Per vaginal examination revealed an eight-week sized uterus. Ultrasonography revealed an echogenic linear structure suggestive of an IUCD in the cervix and lower uterine body, and embedded in the outer myometrium. The patient was taken up for medical termination of pregnancy and laparoscopic ligation, along with IUCD removal. On laparoscopy, the left tube and ovary were adherent to the posterior surface of the uterus at the level of the uterosacral ligaments. The rectum was also densely adherent to the posterior surface of the uterus, and the IUCD could not be located. Colpotomy was performed at the site of the IUCD thread in the posterior fornix and the space created between the posterior vaginal wall and cervix. The thread, along with the IUCD, was gently freed from the subserosal area of the posterior uterine wall.

Case 2

A 32-year-old female (P3L3A1; parity 3, live issue 3, abortion 1) presented to us with dull aching pain in the lower abdomen for one month and inability to perceive an IUCD thread for the previous 20 days. IUCD insertion was done eight months earlier during the lactational period, ie, three months after delivery. The IUCD could not be located on per speculum examination. Per vaginal examination revealed cervical

Correspondence: Aruna Nigam
Small Registrar Flat No 2, Lady Hardinge
Medical College Campus, New Delhi
110001, India
Tel +91 986 865 6051
Email prakasharuna@hotmail.com



Figure 1 Arrow showing intrauterine contraceptive device thread coming through posterior fornix.

motion tenderness, nodularity, and tenderness in the pouch of Douglas. Her abdominal radiograph revealed an IUCD misplaced in the pelvis (inset, Figure 2), and transvaginal ultrasonography revealed the IUCD in the pouch of Douglas. The patient was planned for laparoscopic removal of IUCD but due to dense adhesions between the posterior surface of the uterus and rectosigmoid junction, the procedure was converted to a laparotomy (Figure 2). After careful dissection, the vertical limb of the IUCD was visualized under the serosa of the rectum. The IUCD was removed and the serosal tear at the rectosigmoid junction repaired. Postoperative recovery was uneventful.

Case 3

A 28-year-old female (G3P2L2) presented in the family planning outpatient clinic with a four-month history of

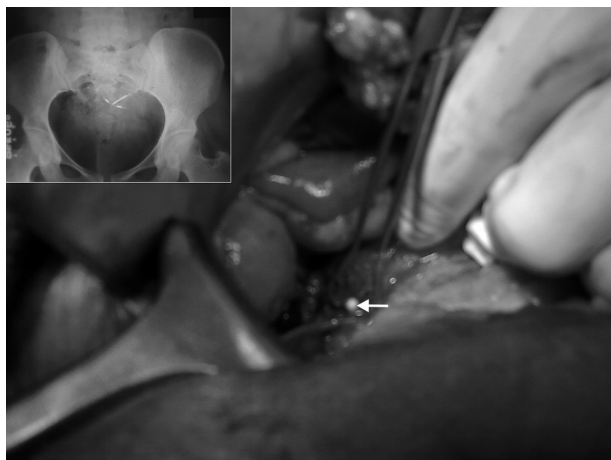


Figure 2 Arrow showing intrauterine contraceptive device tip embedded in rectal wall; abdominal radiograph showing misplaced intrauterine contraceptive device (inset).

amenorrhea. IUCD insertion had been done for the patient 18 months earlier. Examination revealed an 18-week sized uterus. Sonographically, the IUCD could not be localized in the uterus. A single live fetus of 17 weeks and 6 days gestation was found in the uterus. Plain X-ray revealed the IUCD in the pelvis. Misoprostol was used to induce abortion, following which the patient was taken up for laparoscopic ligation. The IUCD could not be located during laparoscopy, so laparotomy was performed. The IUCD was seen in the mesoappendix which was inflamed, along with adhesions between the peritoneum and cecum. The IUCD was removed and an appendectomy performed.

Discussion

Uterine perforation by an IUCD is reported as a complication in 0.87 per 1000 cases, varying from 0.05 to 13 per 1000 insertions.² The risk of perforation is maximum at the time of IUCD insertion. The IUCD usually gets embedded in the uterine wall and is later forced through the uterine wall by uterine contractions into the abdominal cavity and other organs.³ Two types of uterine perforation can occur, ie, complete and partial. If the IUCD perforates through all uterine layers (endometrium, myometrium, and serosa), as in the second and third cases described here, it is called a complete perforation. Less commonly, the IUCD penetrates the myometrium but still remains in the uterus, which is known as partial perforation, as observed in the first case.

The IUCD thread may not be felt due to thread retraction, expulsion, or perforation. Uterine perforation by an IUCD is asymptomatic and does not affect the adjacent organs in 85% of cases, but in the remaining cases, it can invade the adnexa, broad ligament, pouch of Douglas, urinary bladder, rectum, sigmoid colon, and intestine.⁴ An IUCD present in the peritoneal cavity can cause bowel obstruction, perforation, abscess, and fistula formation. Bowel injury usually presents as a triad of abdominal pain, fever, and intermittent diarrhea. Perforation of the rectum or sigmoid colon by an IUCD can lead to complications like peritonitis and stricture. The duration between insertion and appearance of symptoms of perforation has been reported to vary from six months⁵ to 16 years.⁷ Perforation by a copper-containing device is associated with increased risk. This is because a severe inflammatory reaction ensues, due to release of cytokines, and degradation of the extracellular matrix, caused by matrix metalloproteinase.⁶ Risk of uterine perforation by an IUCD has been attributed to various causes, including operator inexperience, an extremely retroverted or retroflexed uterus, and insertion during the

puerperium and lactation. Thinning of the uterine wall due to a hypoestrogenic state during lactation could have been the cause of perforation in the second case.

Cases of a missing IUCD should be thoroughly investigated, and an intraperitoneal copper-containing IUCD should be removed, even in asymptomatic cases. A misplaced IUCD may be diagnosed by noninvasive methods, such as X-ray and ultrasound of the abdomen and pelvis. Invasive diagnostic methods are uterine sounding and hysteroscopy. A computed tomography scan is recommended if bowel perforation is suspected.⁷

The etiology of the misplaced IUCD in the first case could have been faulty insertion of the IUCD, whereby it might have been forced through the posterior fornix because the IUCD thread was visualized in the posterior fornix. However, in the absence of any scarring in that area, it could be a partial perforation whereby the IUCD became implanted in the myometrium while the thread of the IUCD cut through the posterior lip of cervix and came to lie in the posterior fornix. Although laparoscopy is the preferred method of removing an intra-abdominal IUCD, conversion is occasionally required in view of dense adhesions preventing safe laparoscopic surgery, as in this patient.

There are only a few reports of IUCDs dislocating into the rectum. Sepulveda⁸ reported a case of a Copper-T perforating into the rectum in 1990, whereby the Copper-T came out via the anus and the patient was managed conservatively. Our second patient presented with lower abdominal pain and an inability to perceive the Copper-T thread, and the IUCD was found embedded in the rectal serosa.

In the third case, the IUCD could have perforated the appendix and caused acute appendicitis, but early detection and intervention averted serious complications.

It is very important for health professionals to use the right technique of insertion, ie, assessing the size and direction of

the uterus by vaginal examination before inserting the IUCD and confirming the same by using uterine sounding, never using undue force during insertion, and using a withdrawal technique for inserting a device. It is imperative to stress to the woman the importance of feeling the IUCD thread intermittently after periods and attending for a routine follow-up after IUCD insertion at one month, three months, and yearly thereafter. Patient education and postinsertion counseling to detect a missing thread, and reporting of any adverse symptoms should be routine. Early detection of a dislocated IUCD can prevent serious injury to adjacent organs.

Disclosure

The authors report no conflicts of interest in this work.

References

1. Cumming GP, Bramwell SP, Lees DA. An unusual case of cystolithiasis: A urological lesson for gynecologists. *Br J Obstet Gynaecol*. 1997;104:117–118.
2. Grimaldi L, de Giorgio F, Andreotta P, D'Alessio MC, Piscicelli C, Pascali VL. Medicolegal aspects of an unusual uterine perforation with multiload-Cu 375R. *Am J Forensic Med Pathol*. 2005;26:365–366.
3. Carson SA, Gatlin A, Mazur M. Appendiceal perforation by Copper-7 intrauterine contraceptive device. *Am J Obstet Gynecol*. 1981;141:586–587.
4. Phupong V, Sueblinvong T, Pruksanaonda K, Taneepanichskul S, Tiratanachai S. Uterine perforation with Lippes loop intrauterine device-associated actinomycosis: A case report and review of the literature. *Contraception*. 2000;61:347–350.
5. Nceboz US, Ozçakir HT, Uyar Y, Çağlar H. Migration of an intrauterine contraceptive device to the sigmoid colon: A case report. *Eur J Contracept Reprod Health Care*. 2003;8:229–232.
6. Shobokshi A, Shaarawy M. Cervical mucus granulocyte macrophage colony stimulating factor and interleukin-2 soluble receptor in women using copper intrauterine contraceptive devices. *Contraception*. 2002;66:129–132.
7. Istanbuloglu MO, Ozcimen EE, Ozturk B, Uckuyu A, Cicek T, Gonen M. Bladder perforation related to intrauterine device. *J Chin Med Assoc*. 2008;71:207–209.
8. Sepulveda WH. Perforation of the rectum by a Copper-T intra-uterine contraceptive device; a case report. *Eur J Obstet Gynecol Reprod Biol*. 1990;35:275–278.

Open Access Journal of Contraception

Publish your work in this journal

Open Access Journal of Contraception is an international, peer-reviewed, open access, online journal, publishing original research, reports, reviews and commentaries on all areas of contraception. In addition to clinical research, demographics and health-related aspects, the journal welcomes new findings in animal and preclinical studies

Submit your manuscript here: <http://www.dovepress.com/open-access-journal-of-contraception-journal>

Dovepress

relating to understanding the biological mechanisms and practical development of new contraceptive agents. The manuscript management system is completely online and includes a very quick and fair peer-review system. Visit <http://www.dovepress.com/testimonials.php> to read real quotes from published authors.