

Value of Partial Sensory Rhizotomy in the Microsurgical Treatment of Trigeminal Neuralgia Through Retrosigmoid Approach

This article was published in the following Dove Press journal:
Journal of Pain Research

Yin Liu^{1,2}
Yanbing Yu²
Zheng Wang^{1,2}
Zhu Deng^{2,3}
Ruiquan Liu^{2,3}
Na Luo^{1,2}
Li Zhang²

¹Graduate School of Peking University Health Science Center, Beijing, People's Republic of China; ²Department of Neurosurgery, China-Japan Friendship Hospital, Beijing, People's Republic of China; ³Graduate School of Peking Union Medical College, Chinese Academy of Medical Sciences, Beijing, People's Republic of China

Purpose: Microvascular decompression (MVD) is the most effective surgical procedure for the treatment of refractory primary trigeminal neuralgia (TN), but due to the presence of non-neurovascular compression (NVC), the application of MVD is limited. In some cases, partial sensory rhizotomy (PSR) is required. The purpose of this study was to compare the outcome of MVD and MVD+PSR in the treatment of primary TN and to evaluate the application value of PSR in the treatment of TN.

Patients and Methods: We retrospectively analyzed the postoperative outcomes of patients who received MVD or MVD+PSR for the first time from the same surgeon in the neurosurgery department of China-Japan Friendship Hospital from March 2009 to December 2017. A total of 105 patients were included in the data analysis, including 40 in the MVD group and 65 in the MVD+PSR group.

Results: The MVD group had an effectiveness rate of 60% and a recurrence rate of 31.4% after an average follow-up of 49.4 months. The MVD+PSR group had an average effectiveness rate of 69.2% and a recurrence rate of 28.6% after an average follow-up of 71.4 months. There was no statistically significant intergroup difference in long-term effectiveness ($p=0.333$) or recurrence rates ($p=0.819$). The incidence of facial numbness was significantly higher in the MVD+PSR group than in the MVD group (83.1% vs 7.5%; $p<0.001$). However, facial numbness had no significant effect on the patients' daily life.

Conclusion: MVD+PSR and MVD have the same effectiveness in the treatment of primary TN. MVD+PSR is associated with a higher incidence of facial numbness than MVD, but the difference does not affect the patients' daily life. PSR should have a place in the treatment of TN by posterior fossa microsurgery.

Keywords: trigeminal neuralgia, microvascular decompression, partial sensory rhizotomy, posterior fossa microsurgery

Introduction

Trigeminal neuralgia (TN) is a transient, paroxysmal, "electric shock"-like pain that starts and stops suddenly and is limited to one or more branches of the trigeminal nerve; the most common trigger for TN is innocuous stimulation. In addition, persistent pain of moderate intensity may be associated with the distribution of affected branches.¹ According to its etiology, TN can be divided into three categories: idiopathic TN (no clear cause), typical TN (caused by vascular compression of the trigeminal nerve root), and secondary TN (secondary to other neurological diseases, such as multiple sclerosis or cerebellopontine angle tumors).^{2,3} Common surgical

Correspondence: Li Zhang
Department of Neurosurgery, China-Japan Friendship Hospital, No. 2 Yinghua Dongjie, Hepingli, Chaoyang District, Beijing, People's Republic of China
Tel +86 18910586699
Fax +86-10-64217749
Email allan18910586699@163.com

techniques for TN include radiofrequency ablation (RFA), stereotactic radiosurgery (SRS), percutaneous balloon compression (PBC), microvascular decompression (MVD) and partial sensory rhizotomy (PSR). MVD is the most effective surgical method for treating TN, with a recurrence rate between 6% and 47%.^{10–15} As a destructive operation, PSR has rarely been reported in recent years due to its high complications. In the existing literature, the recurrence rate of TN after the first simple PSR is reported to be between 30% and 50%.^{3,6–8,18} There are almost no published reports on the treatment of TN with MVD+PSR.

Due to the presence of neurovascular compression (NVC) in patients with TN, simple MVD is not applicable to all patients with TN, and PSR is often required in clinical practice. To evaluate the medium- and long-term efficacy and safety of MVD+PSR in the treatment of TN, this study retrospectively analyzed 105 nonsecondary TN patients treated with MVD or MVD+PSR by the same surgeon from March 2009 to December 2017 and compared the postoperative outcomes and complications of the two groups. The aims of this study were to provide a reference for the clinical selection of surgical methods and to evaluate the application value of PSR.

Patients and Methods

We retrospectively analyzed 181 TN patients who received MVD or MVD+PSR treatment from the same surgeon in the neurosurgery department of China-Japan Friendship Hospital from March 2009 to December 2017. After the exclusion of cases involving secondary TN (such as cases secondary to intracranial tumors or multiple sclerosis), secondary MVD, loss to follow-up, follow-up time <1 year, incomplete clinical data, and additional comorbid cranial nerve diseases (such as facial spasm and glossopharyngeal neuralgia), 105 patients with nonsecondary TN were included in the statistical analysis, including 40 patients with MVD and 60 patients with MVD+PSR. Five patients were treated with PSR alone because no responsible vessel was found during surgery; those patients were assigned to the MVD+PSR group (five samples are not enough for statistical analysis, to better analyze postoperative complications of PSR, we assigned the five persons into the MVD+PSR group).

The demographic and clinical characteristics of the patients were collected and recorded, including gender, age, duration of TN symptoms, laterality of pain, involvement of the nerve branches, and previous surgical history (surgical destruction of the trigeminal sensory root, such as

PBC or radiofrequency thermocoagulation). The specific intraoperative conditions of the patients were recorded, including surgical method (simple MVD, MVD+PSR, or simple PSR), posterior fossa volume, arachnoid thickening and adhesion, type of responsible vessel formation, and success or failure in providing adequate vascular decompression. We assessed the size of the posterior fossa volume (the posterior fossa volume was defined as the region bordered by the tentorium of the cerebellum, the occipital bone, the clivus, and the pyramidal bones¹⁹) based on previously reported MRI assessment methods or intraoperative conditions. If the posterior fossa volume measured by linear measurement was less than 500 cm³ or if the platybasia or basilar invagination was found during surgery, we considered that the posterior fossa was small.^{20,21} All patients were followed up by independent observers via telephone or outpatient services. The data collected during follow-up included whether the pain recurred, the severity of the pain, the effect of medication and whether there was facial dysfunction and/or other complications.

The degree of postoperative pain in TN patients was evaluated at 1 week postoperatively and at follow-up visits using the Barrow Neurological Institute (BNI) pain score.⁹ One week after the operation, a BNI score of I was taken to represent a cure, and the pain was considered improved if it was reduced compared with the preoperative value; the procedure was considered ineffective if the pain was unchanged or aggravated. At the time of follow-up, severe pain with a BNI score of III or above was defined as recurrence.

Surgical Treatment

The selection of surgical methods for patients adhered to the following basic principles: (1) If a patient was unable to accept facial numbness after PSR and there was significant compression of the trigeminal nerve root by the responsible blood vessels (the sensory root was displaced or compressed), the patient received MVD alone. (2) MVD+PSR was performed for various reasons: if vascular compression was clearly the cause but sufficient decompression could not be achieved (such as veins that affect the brainstem blood flow, or some perforating vessels, or CPA bleeding with small posterior fossa volume); if the intraoperative blood vessels were only slightly compressed, merely touching the trigeminal nerve root, or near the nerve root without touching it; or if the responsible blood vessel was a simple vein and could not be

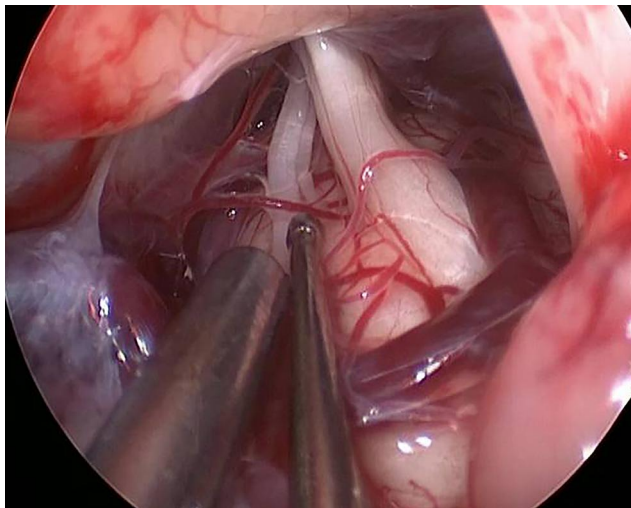


Figure 1 The large branch of inferior petrosal vein oppresses the sensory root of the trigeminal nerve, making it difficult to decompress.

completely decompressed (Figure 1). Additionally, elderly patients (age ≥ 60 years) who were willing to accept facial numbness were treated with MVD+PSR. (3) If no responsible vessel was found in the intraoperative exploration, PSR alone was performed. Preoperatively, each patient was informed of the advantages and disadvantages of the various surgical procedures, and the surgical method was selected according to the patient's wishes and the specific conditions found during the operation.

Surgical Method

All patients underwent surgery on the affected side under general anesthesia. The suboccipital retrosigmoid sinus approach was selected, and the skin, subcutaneous tissue, muscle and fascia were incised layer by layer. The skull was drilled, and the diameter of the bone window was enlarged to approximately 2 cm. The surgeon reached forward to the sigmoid sinus and upward to the transverse sinus. The dura mater was opened and suspended under the skin; next, the surgeon gently pulled the cerebellar hemisphere, aspirated some of the cerebrospinal fluid, and entered the cerebellopontine angle (CPA) area. The arachnoid membrane around the trigeminal nerve root was carefully separated. The position of the patient's head and the angle of the microscope were adjusted, and the surgeon thoroughly explored the trigeminal sensory roots and their environs to clarify which vessel was responsible for the nerve compression. According to the patient's wishes and the specific conditions found on intraoperative exploration, different surgical methods were adopted: for patients who underwent only MVD treatment, the surgeon freed the responsible blood vessels and moved

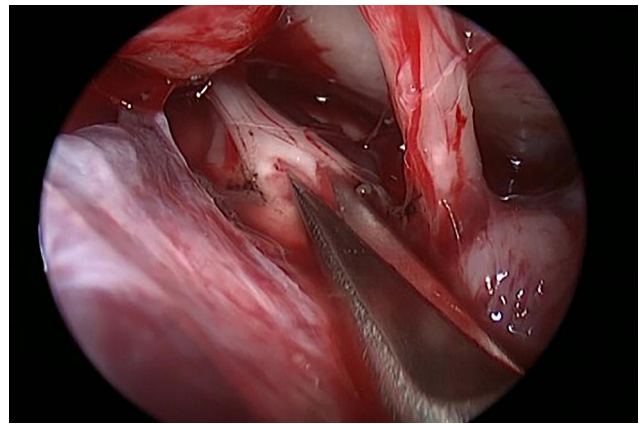


Figure 2 Partially cut off the sensory root of the trigeminal nerve.

them away from the nerve roots, inserting a cotton-polyester pad between the blood vessels and the brainstem; for patients treated with MVD+PSR, the surgeon first completed the MVD according to the above mentioned surgical procedure and then cut the sensory root 1/3-2/3 0.5–1cm from pons according to the distribution of pain (if the pain only affected the V3 division, we cut off 1/3 of the sensory root; if the pain affected the V1 or V2 division, not only the V3 division, we cut off 2/3 of the sensory root). Patients who had no vascular compression evident on repeated exploration were treated with PSR alone (Figure 2).

Statistical Analysis

All statistical analyses were performed using SPSS version 24.0 (IBM, Armonk, New York, USA). All analyses were performed only for the MVD group and the MVD+PSR group. The mean \pm standard deviation was used to represent continuous variables; the count and percentage were used to represent categorical variables. After continuous variables were tested for normality by the Kolmogorov–Smirnov test, Student's *t*-test was used to compare the two groups; comparison of categorical variables was performed using Pearson's χ^2 test or Fisher's exact test. Kaplan-Meier survival analysis was used to compare long-term postoperative outcomes. The differences were considered significant at $p < 0.05$.

Results

This study retrospectively investigated 181 TN patients who underwent MVD or MVD+PSR in the neurosurgery department from March 2009 to December 2017 at China-Japan Friendship Hospital. After the exclusion of secondary TN (eg, secondary to intracranial tumors or multiple

Table 1 Demographic and Clinical Data of Patients in the MVD and MVD+PSR Groups

Variables	MVD	MVD+PSR	P value
Gender, n (%)			0.514
Male	14(35.0%)	18 (27.7%)	
Female	26(65.0%)	47(72.3%)	
Duration(years), mean±SD	7.5±6.3	5.6±4.9	0.086
Age(years), mean±SD	55.5±10.2	59.9±10.0	0.031
Affected side, n (%)			0.543
Left	19(47.5%)	26(40.0%)	
Right	21(52.5%)	39(60.0%)	
Distribution of pain, n (%)			0.737
V1	0(0.0%)	0(0.0%)	
V2	15(37.5%)	20(30.8%)	
V3	4(10.0%)	8(12.3%)	
V1+V2	7(17.5%)	7(10.8%)	
V2+V3	12(30.0%)	25(38.5%)	
V1+V2+V3	2(5.0%)	5(7.7%)	
Previous surgical history, n (%)			1.000
Yes	5(12.5%)	7(10.8%)	
No	35(87.5%)	58(89.2%)	
Follow-up time(month), mean ±SD	49.4±27.2	71.4±30.7	0.000

Abbreviations: MVD, microvascular decompression; PSR, partial sensory rhizotomy; V1, the first division of the trigeminal nerve; V2, the second division of the trigeminal nerve; V3, the third division of the trigeminal nerve.

sclerosis), secondary MVD, loss to follow-up, follow-up time <1year, incomplete clinical data, and additional comorbid neurological diseases (such as facial spasm and glossopharyngeal neuralgia), 105 patients with nonsecondary TN were included in the statistical analysis, comprising 40 patients with MVD and 65 patients with MVD+PSR. Demographic data (Table 1) showed that patients receiving MVD+PSR were older than patients receiving MVD (the mean age of MVD+PSR patients was 60 years, while the mean age of MVD patients was 55 years, $p=0.031$). Additionally, the follow-up time was longer for the former group (average 71.4 months for MVD+PSR patients and 49.4 months for MVD patients, $p=0.000$). There was no difference in gender, side, duration of disease, pain distribution, or previous surgical history.

The intraoperative exploration of the MVD+PSR group and MVD group are presented in Table 2. Intraoperative

Table 2 The Intraoperative Exploration of the MVD+PSR Group and MVD Group

Variable	MVD	MVD+PSR	P value
Posterior fossa volume, n (%)			0.969
Normal	18(45.0%)	29(44.6%)	
Small	22(55.0%)	36(55.4%)	
Arachnoid thickened and adhered, n (%)			0.542
No	8 (20.0%)	10 (15.4%)	
Yes	32 (80.0%)	55 (84.6%)	
Type of offending vessel, n (%)			0.158
Arteries	21 (52.5%)	28(43.1%)	
Veins	1 (2.5%)	6 (9.2%)	
Arteries and veins	18 (45.0%)	26(40.0%)	
No vessel	0 (0.0%)	5 (7.7%)	

Abbreviations: MVD, microvascular decompression; PSR, partial sensory rhizotomy.

exploration revealed that the MVD group contained 21 cases (52.5%) in which the responsible vessels were only arteries, 1 case (2.5%) in which only veins were responsible, and 18 cases (45.0%) in which both arteries and veins were responsible. In the MVD+PSR group, 28 patients (43.1%) had only arteries as the responsible vessels, 6 patients (9.2%) had only veins as the responsible vessels, 26 patients (40.0%) had both, and 5 patients (7.7%) had no vascular compression. There was no significant difference in the composition of the responsible vessels between the two groups ($p=0.158$). There were no differences between the two groups in the volume of the posterior fossa or whether the arachnoid thickened and adhered.

The immediate effect on the patient was recorded within one week after surgery (Table 3). The MVD group achieved an immediate cure in 30 cases (75%), improvement in 4 cases (10%), and no effect in 6 cases (15%), for a total effectiveness rate of 85.0%. The MVD+PSR group achieved a cure in 54 cases (83.1%), improvement in 8 cases (12.3%), and no effect in 3 cases (4.6%) were invalid; the total effectiveness rate was 95.4%. There was no significant difference between the two groups in this respect.

By the last follow-up, 11 patients in the MVD group (31.4%) and 18 patients in the MVD+PSR group (28.6%) had suffered recurrence, excluding the patients for whom surgery had had no immediate effectiveness, and there was no significant difference in the recurrence rate between the two groups ($p=0.819$). The overall effective rates of the

Table 3 Comparison of Outcomes Between MVD Group and MVD+PSR Group

Variables	MVD	MVD +PSR	P value
Immediate effect, n (%)			0.196
Cure	30 (75.0%)	54 (83.1%)	
Improvement	4 (10.0%)	8 (12.3%)	
No effect	6 (15.0%)	3 (4.6%)	
The BNI score at the last follow-up, n (%)			0.970
I	19 (47.5%)	33 (50.8%)	
II	5 (12.5%)	10 (15.4%)	
III	6 (15.0%)	9 (13.8%)	
IV	9 (22.5%)	11 (16.9%)	
V	1 (2.5%)	2 (3.1%)	
Recurrence, n (%)			0.819
Yes	11 (31.4%)	18 (28.6%)	
No	24 (68.6%)	45 (71.4%)	
Effect at the last follow-up, n (%)			0.333
No effect or recurrence	16 (40.0%)	20 (30.8%)	
Effective	24 (60.0%)	45 (69.2%)	
Pain-free survival time(month), mean \pm SD	37.9 \pm 29.4	56.3 \pm 34.6	0.009

Abbreviations: MVD, microvascular decompression; PSR, partial sensory rhizotomy.

MVD and MVD+PSR groups were 60% and 69.2%, respectively, and there was no significant difference between the two groups ($p=0.333$). The pain-free survival time of the MVD group was 37.9 months, and the pain-free survival time of the MVD+PSR group was 56.3 months. The MVD+PSR group had a longer pain-free survival time than the MVD group ($p=0.009$).

To exclude the effects of follow-up, we performed a further Kaplan-Meier survival analysis (Figure 3) and found no statistically significant difference between the long-term outcomes of the MVD group and the MVD+PSR group ($p = 0.329$, Log-rank test).

Postoperative Complications

According to the patients' self-assessment, the degrees of numbness were divided into very slight, mild, moderate, serious, and very serious (Table 4). The incidence of facial numbness was significantly higher in the MVD+PSR group than in the MVD group (83.1% vs 7.5%; $p < 0.001$; Table 5). In the MVD group, 3 cases of postoperative numbness were mild, while in the MVD+PSR group, 2 cases (3.7%) were

very mild, 32 cases (59.3%) were mild, 11 cases (20.4%) were moderate, and 9 cases were severe (16.7%). For the patients with moderate or severe facial numbness, they experienced numbness only when they were brushing their teeth, washing their face, or eating, and in the rest of time they were used to it. In the MVD group, there were 2 cases (5.0%) of hearing loss, 1 case (2.5%) of delayed wound healing, and 4 cases (10.0%) of aseptic meningitis. In the MVD+PSR group, there were 4 cases (6.2%) of hearing loss, 2 cases (3.0%) of delayed wound healing, 1 case (1.5%) of facial nerve paralysis, and 2 cases (3.0%) of aseptic meningitis (Table 5). There were no complications, such as cerebrospinal fluid leakage or intracranial hematoma, in either group.

Discussion

The purpose and advantage of the posterior sigmoid approach for trigeminal nerve root surgery is to relieve pain immediately for TN patients. MVD is considered the preferred surgical procedure. However, destructive surgery such as PSR is considered a safe and effective alternative procedure in the absence of NVC, if pain recurs or does not subside after MVD, or if the patient's intraoperative condition does not allow safe and effective decompression.⁷ Although combing of the trigeminal sensory root is advised in patients without NVC, the incidence of unilateral numbness is as high after nerve combing as after PSR.⁸

Due to differences in technology, research methods, patient selection, efficacy evaluation, and follow-up time, the effectiveness of MVD in treating TN differs in reports from different institutions. However, there are few reports on the long-term efficacy of MVD+PSR in the treatment of TN. Here, we summarize the long-term experience of a single surgeon with MVD+PSR for the treatment of nonsecondary TN, comparing short-term efficacy, long-term efficacy, and complications between the MVD and MVD+PSR groups.

After analyzing the relevant data of 40 patients with MVD and 65 patients with MVD+PSR, we found that the immediate effectiveness rate of the MVD group was 85% (34/40), and the recurrence rate was 31.4% after an average follow-up of 49.4 months. The total immediate effectiveness rate of the MVD+PSR group was 95.4% (62/65), and the recurrence rate was 28.6% after an average follow-up of 71.4 months. For why were there more patients in the MVD+PSR group than in the MVD group, we believe that one important reason is that in the early stage, the surgeon was not very skilled with MVD and therefore

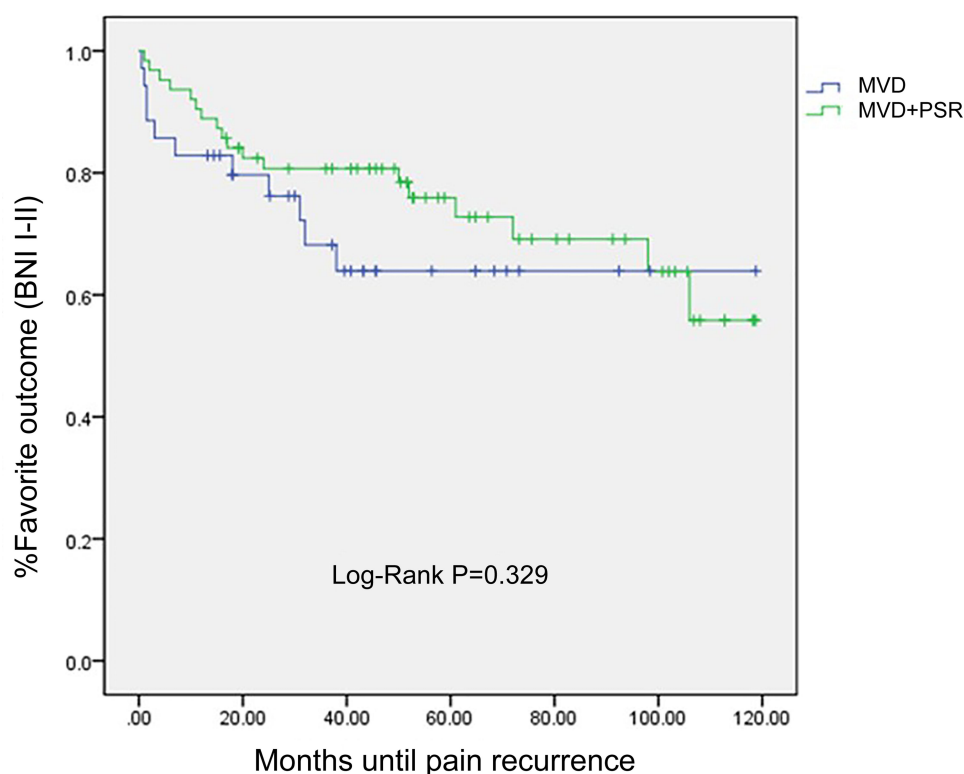


Figure 3 The Kaplan-Meier survival curves for the MVD and MVD+PSR groups are shown.

Abbreviations: MVD, microvascular decompression; PSR, partial sensory rhizotomy.

have difficulty achieving satisfactory decompression, which can also explain why the MVD+PSR group had a longer follow-up time than the MVD group.

Table 4 The Degrees of Postoperative Facial Numbness

	MVD (n=3)	MVD+PSR (n=54)
The degrees of numbness		
Very slight	0 (0.0%)	2 (3.7%)
Mild	3 (100.0%)	32 (59.3%)
Moderate	0 (0.0%)	11 (20.4%)
Serious	0 (0.0%)	9 (16.7%)
Very serious	0 (0.0%)	0 (0.0%)

Abbreviations: MVD, microvascular decompression; PSR, partial sensory rhizotomy.

Table 5 Postoperative Complications Between MVD Group and MVD+PSR Group

Variable	MVD (n=40)	MVD+PSR (n=65)	P value
Facial numbness	3 (7.5%)	54 (83.1%)	0.000
Delayed wound healing	1 (2.5%)	2 (3.0%)	1.000
Hearing loss	2 (5.0%)	4 (6.2%)	1.000
Facial nerve paralysis	0 (0.0%)	1 (1.5%)	1.000
Aseptic meningitis	4 (10%)	2 (3.0%)	0.293

Abbreviations: MVD, microvascular decompression; PSR, partial sensory rhizotomy.

There was no statistically significant difference in short-term efficacy ($p = 0.196$) or long-term efficacy ($p = 0.819$) between groups. Although the mean pain-free survival of the MVD+PSR group was significantly longer than that of the MVD group (56.3 months vs 37.9 months; $p=0.009$), we also found that the MVD+PSR group had a longer follow-up time than the MVD group; therefore, we performed Kaplan-Meier survival analysis and found that the difference between the two groups was not statistically significant ($p = 0.329$).

In one study,⁴ 26% of the 164 TN patients who were treated with MVD had PSR added because no clear vascular compression was found during the operation. The pain-free rate of the MVD group was significantly higher than that of the MVD+PSR group. The pain-free rates of the two groups at 1 year, 5 years, and 10 years after surgery were 84%, 64%, and 53%, respectively, for MVD and 80%, 50%, and 20%, respectively, for MVD+PSR. In another study,⁵ the researchers compared the effect of surgery in 142 patients with MVD and 68 patients with MVD+PSR, finding that the MVD+PSR group had a higher rate of painlessness than the MVD group after 2 years of follow-up. However, the difference was not statistically significant. In addition, in the study

of Bederson,¹⁶ a total of 252 patients with TN received surgical treatment, including 56 instances of MVD + PSR, 166 instances of MVD alone, and 30 instances of PSR alone. The study suggested that MVD + PSR achieved better long-term effectiveness than MVD alone, but the difference was not significant. Our findings are similar to those of the latter two studies.

As PSR is a destructive procedure, its most common complication is paresthesia of the lateral side. A survey of patient satisfaction after MVD or PSR showed that the quality of life 5 years after MVD or PSR was worse than that of the general population, and patients who received PSR were more prone to anxiety, which may have been associated with a higher rate of complications after PSR.¹⁷ Young et al⁷ reported that among 83 TN patients receiving PSR, 41 (49%) had mild facial hypoesthesia, and 15 (18%) had severe facial numbness. Klun et al¹⁸ reported that all TN patients who received PSR had different degrees of facial sensory disorders after surgery, and almost all patients developed herpes labialis, but the corneal reflex did not disappear in any of the patients.

Among the complications reported by Terrier et al,³ 5 (22.7%) of 22 patients had facial hypoesthesia after the operation, and 2 patients developed facial pain and numbness. All patients had intact corneal reflexes and masticatory muscle motor function, and cutting the trigeminal sensory roots from approximately 2/3 of the dorsolateral side of the pons reduced the incidence of complications.

In our study, the incidence of postoperative facial numbness was significantly higher in the MVD+PSR group than in the MVD group (83.1% vs 7.5%; $p = 0.000$); 3 patients in the MVD group were mildly numb, while most of the patients in the MVD+PSR group had mild to moderate numbness, and severe numbness accounted for 16.7%. However, all patients indicated that their postoperative numbness was acceptable and had no significant effect on quality of life relative to preoperative pain.

Many previous studies have suggested that the proportion and location of trigeminal nerve sensory root section during PSR may be related to surgical efficacy and postoperative complications. Hussein²² and others presented the results of partial sensory root section in 25 patients, of which 15 patients had a sensory root excision rate between 75% and 100%. All 25 patients obtained immediate pain relief after surgery, and only one recurred during the 38- to 109-month follow-up period. Nineteen (76%) patients developed facial sensory disturbances, and 8 (32%) developed abnormal corneal sensations. Adams²³ et al performed

partial (35) or complete (19) section of the trigeminal nerve sensory root in 54 patients. Among those patients, 42 had their nerve roots cut by more than 50%. During an average follow-up of 4.5 years, only 2 patients relapsed, and 4 had mild pain. Of the 34 patients who were followed for more than 5 years, 29 (85%) did not have TN, but all patients who underwent complete sensory root section had corneal reflex damage. In our study, 57 patients had 2/3 of the sensory root cut, and 8 patients had 1/3 cut; the range of sensory root section was lower than in the above two studies, which may explain our higher postoperative recurrence rate.

Young et al⁷ implemented PSR for 83 patients with TN. Approximately 89% of the patients had their sensory roots cut by approximately 1/3-1/2, and 11% of the patients had their sensory roots cut by 2/3; the cutting position was 2–5 mm from the pons. The average follow-up was 72 months. Forty (48%) patients had immediate pain relief, another 18 (22%) patients had less pain than before surgery, and pain continued postoperatively in 25 (30%) patients. The failure rate in the first year after surgery was 17%, the average annual recurrence rate after surgery was 2.6%, and 67% of patients had facial sensory abnormalities. Among the 22 cases of PSR reported by Terrier et al,³ all patients had the ventrolateral 2/3 of the pars major of the trigeminal nerve cut, and the rhizotomy was performed as close to the pons as possible. The pain was completely relieved in 19 patients (86.4%) and partially relieved in 3 patients (13.6%). The recurrence rates at 1 and 5 years after surgery were 14.6% and 31.5%, respectively. Only 5 of 22 patients (22.7%) experienced hypoesthesia, and both the corneal reflex and masticatory motor function were intact in all patients. Compared with the study by Young et al, our study includes an expanded range of sensory roots, which may explain the increased immediate effectiveness rate we reported. Compared with the study by Terrier et al, our study found similar immediate and long-term efficacy, and the reduced postoperative complication rate reported may be related to the location of the sensory root cutting sites, which were closer to the pons.

Since trigeminal PSR is a destructive procedure, previous reports did not hold a positive attitude towards the application of PSR in TN surgery. Our study leads us to believe that in the retrosigmoid approach, when trigeminal nerve root exploration finds no clear causative vascular compression, when decompression of the responsible vessel is unsatisfactory or insufficient for various reasons, or the patient is ≥ 60 years old and states a preference for PSR, this procedure can be used as appropriate. PSR can achieve similar long-term efficacy

to MVD alone, and many patients are willing to risk facial numbness to undergo trigeminal sensory root section. The proportion and location of trigeminal nerve sensory root transaction may be related to surgical effectiveness and postoperative complications. Expanding the range of sensory root excision may increase the immediate pain-free rate and reduce the postoperative recurrence rate, but it also increases the risk of corneal sensory dysfunction or even loss. Cutting the sensory root as close as possible to the pons may reduce the incidence of facial numbness.

Limitations

Our study was a retrospective study, patients in this study were not randomly assigned to the different treatment groups (MVD or MVD+PSR), so their treatment choice was subject to bias. What's more, endoscope is essential to find anterior conflict and to assess completeness of decompression, unfortunately in our study, all cases did not use endoscope. Microscope plus endoscope for MVD will be studied in our future research.

Conclusion

MVD and MVD+PSR have similar short-term and long-term pain control rates in nonsecondary TN, although the incidence of facial numbness is significantly higher in MVD +PSR recipients than in MVD recipients. However, this numbness has no significant impact on daily life. Whether to add PSR during MVD in TN patients should be determined according to the specific conditions found during the operation as well as the patient's wishes. For patients who are not suitable to undergo pure MVD, MVD +PSR can be considered an effective alternative. PSR should have a place in the treatment of TN by posterior fossa microsurgery.

Ethical Approval

The study was approved by the Ethics Committee of the China-Japan Friendship Hospital and was conducted in accordance with the Declaration of Helsinki. All patients gave written informed consent to all procedures and to personal data processing for research purposes.

Funding

No funding was received for this research.

Disclosure

The authors report no conflicts of interest in this work.

References

1. Arnold M. Headache classification committee of the International Headache Society (IHS) the international classification of headache disorders, 3rd edition. *Cephalalgia*. 2018;38(1):1–211.
2. Cruccu G, Finnerup NB, Jensen TS, et al. Trigeminal neuralgia: new classification and diagnostic grading for practice and research[J]. *Neurology*. 2016;87(2):220–228. doi:10.1212/WNL.0000000000002840
3. Terrier L-M, Amelot A, François P, Destrieux C, Zemmoura I, Velut S. Therapeutic Failure in Trigeminal Neuralgia: from a Clarification of Trigeminal Nerve Somatotopy to a Targeted Partial Sensory Rhizotomy[J]. *World Neurosurg*. 2018;117:138–145. doi:10.1016/j.wneu.2018.05.211
4. Wang DD, Raygor KP, Cage TA, et al. Prospective comparison of long-term pain relief rates after first-time microvascular decompression and stereotactic radiosurgery for trigeminal neuralgia[J]. *J Neurosurg*. 2018;128(1):68–77. doi:10.3171/2016.9.JNS16149
5. Zhang L, Zhang Y, Li C, Zhu S. Surgical treatment of primary trigeminal neuralgia: comparison of the effectiveness between MVD and MVD+PSR in a series of 210 patients[J]. *Turk Neurosurg*. 2012;22(1):32–38. doi:10.5137/1019-5149.JTN.4447-11.2
6. Ko AL, Ozpinar A, Lee A, Raslan AM, McCartney S, Burchiel KJ. Long-term efficacy and safety of internal neurolysis for trigeminal neuralgia without neurovascular compression[J]. *J Neurosurg*. 2015;122(5):1048–1057. doi:10.3171/2014.12.JNS14469
7. Young JN, Wilkins RH. Partial sensory trigeminal rhizotomy at the pons for trigeminal neuralgia[J]. *J Neurosurg*. 1993;79(5):680–687. doi:10.3171/jns.1993.79.5.0680
8. Zakrzewska JM, Lopez BC, S E K, Coakham HB. Patient reports of satisfaction after microvascular decompression and partial sensory rhizotomy for trigeminal neuralgia[J]. *Neuro Surg*. 2005;56(6):1304–1311. doi:10.1227/01.neu.0000159883.35957.e0
9. Rogers CL, Shetter AG, Fiedler JA, Smith KA, Han PP, Speiser BL. Gamma knife radiosurgery for trigeminal neuralgia: the initial experience of the barrow neurological institute. *Int J Radiat Oncol Biol Phys*. 2000;47(4):1013–1019. doi:10.1016/S0360-3016(00)00513-7
10. Barker FG, Jannetta PJ, Bissonette DJ, Larkins MV, Jho HD. The long-term outcome of microvascular decompression for trigeminal neuralgia. *N Engl J Med*. 1996;334(17):1077–1083. doi:10.1056/NEJM199604253341701
11. Sindou M, Leston J, Howeid T, Decullier E, Chapuis F. Microvascular decompression for primary Trigeminal Neuralgia (typical or atypical). Long-term effectiveness on pain; prospective study with survival analysis in a consecutive series of 362 patients [J]. *Acta Neurochir (Wien)*. 2006;148(12):1235–1245. doi:10.1007/s00701-006-0809-2
12. Sarsam Z, Garcia-Fiñana M, Nurmikko TJ, Varma TR, Eldridge P. The long-term outcome of microvascular decompression for trigeminal neuralgia [J]. *Br J Neurosurg*. 2010;24(1):18–25. doi:10.3109/02688690903370289
13. Oesman C, Mooij JJ. Long-term follow-up of microvascular decompression for trigeminal neuralgia [J]. *Skull Base*. 2011;21(5):313–322. doi:10.1055/s-0031-1284213
14. Zhang H, Lei D, You C, Mao BY, Wu B, Fang Y. The long-term outcome predictors of pure microvascular decompression for primary trigeminal neuralgia [J]. *World Neurosurg*. 2013;79(5–6):756–762. doi:10.1016/j.wneu.2012.01.040
15. Burchiel KJ, Clarke H, Haglund M, Loeser JD. Long-term follow-up of microvascular decompression in trigeminal neuralgia. *J Neurosurg*. 1988;69:35–38. doi:10.3171/jns.1988.69.1.0035
16. Bederson JB, Wilson CB. Evaluation of microvascular decompression and partial sensory rhizotomy in 252 cases of trigeminal neuralgia[J]. *J Neurosurg*. 1989;71(3):359–367. doi:10.3171/jns.1989.71.3.0359

17. Jafree DJ, Williams AC, Zakrzewska JM. Impact of pain and post-operative complications on patient-reported outcome measures 5 years after microvascular decompression or partial sensory rhizotomy for trigeminal neuralgia[J]. *Acta Neurochir (Wien)*. 2018;160:1. doi:10.1007/s00701-017-3350-6
18. Klun B. Microvascular decompression and partial sensory rhizotomy in the treatment of trigeminal neuralgia: personal experience with 220 patients[J]. *Neurosurgery*. 1992;30(1):49–52. doi:10.1227/00006123-199201000-00009
19. Horinek D, Brezova V, Nimsky C, et al. The MRI volumetry of the posterior fossa and its substructures in trigeminal neuralgia: a validated study. *Acta Neurochir (Wien)*. 2009;151(6):669–675. doi:10.1007/s00701-009-0283-8
20. Macielak RJ, Harris MS, Kirsch CF, Prevedello LM, Adunka OF. Influence of posterior fossa volume on clinical outcomes after vestibular schwannoma resection. *Otol Neurotol*. 2016;37(8):1155–1161. doi:10.1097/MAO.0000000000001128
21. Liu R, Deng Z, Zhang L, Liu Y, Wang Z. The Long-Term Outcomes and Predictors of Microvascular Decompression with or without Partial Sensory Rhizotomy for Trigeminal Neuralgia. [J]. *J Pain Res*. 2020;13:301–312. doi:10.2147/JPR.S225188
22. Hussein M, Wilson LA, Illingworth R. Patterns of sensory loss following fractional posterior fossa Vth nerve section for trigeminal neuralgia. *Journal of Neurology, Neurosurgery & Psychiatry*. 1982;45(9):786–790. doi:10.1136/jnnp.45.9.786
23. Adams CB, Kaye AH, Teddy PJ. The treatment of trigeminal neuralgia by posterior fossa microsurgery. *Journal of Neurology, Neurosurgery & Psychiatry*. 1982;45(11):1020–1026. doi:10.1136/jnnp.45.11.1020

Journal of Pain Research

Publish your work in this journal

The Journal of Pain Research is an international, peer reviewed, open access, online journal that welcomes laboratory and clinical findings in the fields of pain research and the prevention and management of pain. Original research, reviews, symposium reports, hypothesis formation and commentaries are all considered for publication. The manuscript

Submit your manuscript here: <https://www.dovepress.com/journal-of-pain-research-journal>

Dovepress

management system is completely online and includes a very quick and fair peer-review system, which is all easy to use. Visit <http://www.dovepress.com/testimonials.php> to read real quotes from published authors.