

Poor Prognosis of Pulmonary Adenosquamous Carcinoma with *NRAS* and *HRAS* Double Mutation

This article was published in the following Dove Press journal:
OncoTargets and Therapy

Jidong Zhao¹
Xiangmei Zhang²
Ming He¹
Xin Chen¹
Xing Cui¹
Tian Qin³
Xueliang Niu³
Liyan Zhao⁴

¹Department of Thoracic Surgery, The Fourth Hospital of Hebei Medical University, Shijiazhuang, People's Republic of China; ²Research Center, The Fourth Hospital of Hebei Medical University, Shijiazhuang, People's Republic of China; ³Medical Department, Burning Rock Biotech, Guangzhou, People's Republic of China; ⁴Department of Internal Medicine, The First Hospital of Xingtai, Xingtai, People's Republic of China

Abstract: RAS mutations constitute one of the major tumorigenic mechanisms and are detected in approximately 20% of lung cancers. The most frequent mutated and well-studied RAS isoform is *KRAS*, which is associated with an overall poor prognosis in non-small-cell lung cancer (NSCLC). However, the clinical significances of *NRAS* and *HRAS* in NSCLC are rarely reported. Here, we present a 58-year-old male smoker who was diagnosed with stage IV lung adenosquamous carcinoma. A rare *NRAS* and *HRAS* double mutation was detected in the primary tumor and lymph node samples using next-generation sequencing (NGS). The patient showed rapid disease progression and passed away due to respiratory failure after 15 days of osimertinib in combination with cisplatin. To the best of our knowledge, this is the first report associating *NRAS* and *HRAS* double mutation in the poor prognosis of NSCLC.

Keywords: NSCLC, *NRAS*, *HRAS*

Introduction

The RAS oncogene affects numerous cellular functions, including proliferation, growth, apoptosis, migration, division, and differentiation of the cells. It has 3 known isoforms: Harvey-RAS (HRAS), Kirsten-RAS (KRAS), and neuroblastoma-RAS (NRAS).¹ The incidence of *KRAS* mutation in lung adenocarcinoma is between 12% and 36%. Previous studies have demonstrated that *KRAS* mutation frequently occurs in lung adenocarcinoma patients who are former or current smokers and are associated with poor overall prognosis.^{2,3} In contrast, *NRAS* and *HRAS* mutations are extremely rare in lung cancer regardless of histopathological subtypes, with only a few cases reported in the literature. Here, we present a case of pulmonary adenosquamous carcinoma harboring *NRAS* and *HRAS* double mutation, who failed to respond to chemotherapy plus targeted therapy.

Case Presentation

A 58-year-old male smoker presented to our hospital with one-month history of chest and back pain. The performance status (PS) value of the patient was 0. Systemic evaluation including brain magnetic resonance imaging (MRI) and contrast-enhanced computed tomography (CT) scan showed a cavitary nodule on the inferior lobe of the right lung and the presence of malignant pleural effusion (Figure 1). Histopathology review of the tissue biopsy sample suggested stage IV poorly differentiated carcinoma. Twelve days after admission, malignant pleural effusion was aggravated and a video-assisted thoracoscopic lobectomy and lymph node dissection was performed for symptom management. Pathological examination of

Correspondence: Xin Chen
Department of Thoracic Surgery, The Fourth Hospital of Hebei Medical University, No. 12, Jiankang Road, Shijiazhuang, Hebei Province, 050010, People's Republic of China
Tel +86-13633118699
Email 2029669284@qq.com

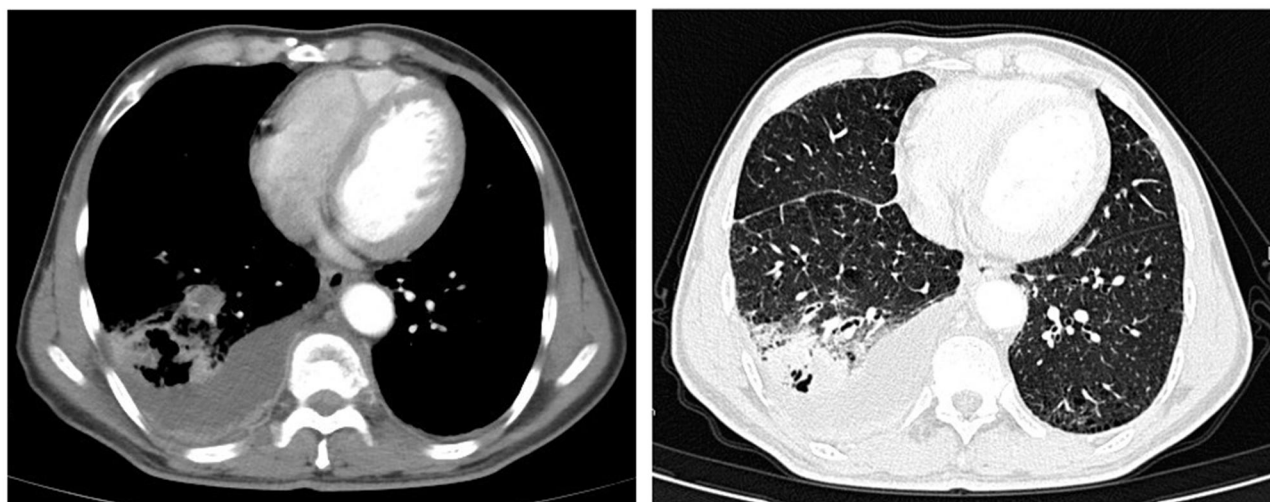


Figure 1 Chest CT at the time of the diagnosis.

tumor, visceral pleura, and lymph nodes confirmed the diagnosis of poorly differentiated adenosquamous carcinoma and the presence of tumor cells in the visceral pleura and lymph nodes. Amplification refractory mutation system (ARMS)-polymerase chain reaction (PCR) assay was performed using pleural effusion samples to profile the *EGFR* mutation status, which showed weak signals for L858R and T790M mutations (CT value: 43.83 and 40.67, respectively, [Figure 2A](#)). The patient was administered with third-generation *EGFR*-TKI osimertinib (150 mg, orally thrice daily) combined with cisplatin (40 mg every ten days). After 5 days of osimertinib treatment, pleural effusion was reduced. Unfortunately, the patient showed a rapid disease progression and died of respiratory failure after 15 days of osimertinib plus cisplatin administration. To understand the underlying mechanism of treatment failure, both surgical and lymph node tissue samples were subjected to capture-based ultra-deep sequencing that target the exons and critical introns of 520 cancer-related genes (Oncoscreen PlusTM, Burning Rock Biotech, China). *HRAS* Q61L and *NRAS* Q61K were consistently found in the primary tumor and lymph nodes ([Figure 2B](#) and [C](#)). However, *EGFR* mutations were not detected, indicating that the *EGFR* L858R and T790M detected by ARMS-PCR may be false-positive mutations.

Discussion

This case reported the poor prognosis of pulmonary adenosquamous carcinoma with *NRAS* and *HRAS* mutation. The patient had a rapid progression leading to death. To the best of our knowledge, this is the first case which

describes the detection of *NRAS/HRAS* double mutation and its prognostic value in lung cancer.

RAS mutations constitute a major tumorigenic mechanism and are detectable in approximately 20% of lung cancers. The most common *KRAS* mutations account for 80–90% of all *RAS* mutations. *KRAS* mutations are generally considered to be a negative predictive factor for *EGFR*-tyrosine kinase inhibitor (TKI) therapy and are associated with a poor overall prognosis in NSCLC.^{2,3} *HRAS* and *NRAS* mutations have been reported in various cancer types including head and neck carcinoma, gastrointestinal cancer, genitourinary cancer, and malignant melanoma.^{4–7} The frequency of *HRAS* and *NRAS* mutations in bladder cancer is up to 84%.⁸ In colorectal cancer, patients with any known *KRAS* or *NRAS* mutation should not be treated with either cetuximab or panitumumab according to the NCCN guidelines. Likewise, *HRAS*-mutated colorectal cancer also results in the resistance to anti-*EGFR* therapies.⁹ However, *HRAS* and *NRAS* mutations are extremely rare in lung cancer; hence, studies documenting their clinical significance are scarce. Cathcart-Rake et al have reported an elderly former smoker with *HRAS* mutant NSCLC. The patient had a rapid progression from stage IB disease to metastatic adenocarcinoma and death, indicating that *HRAS* mutations are associated with poor overall prognosis in NSCLC, similar to *KRAS*.¹⁰ An in vitro study has showed that mutant *HRAS* hyperactivates the *RAS* and the mTOR pathway in various cancer cell lines including lung cancer, which might serve as a therapeutic target.¹¹ *NRAS* mutations are more common in current/former smokers with NSCLC

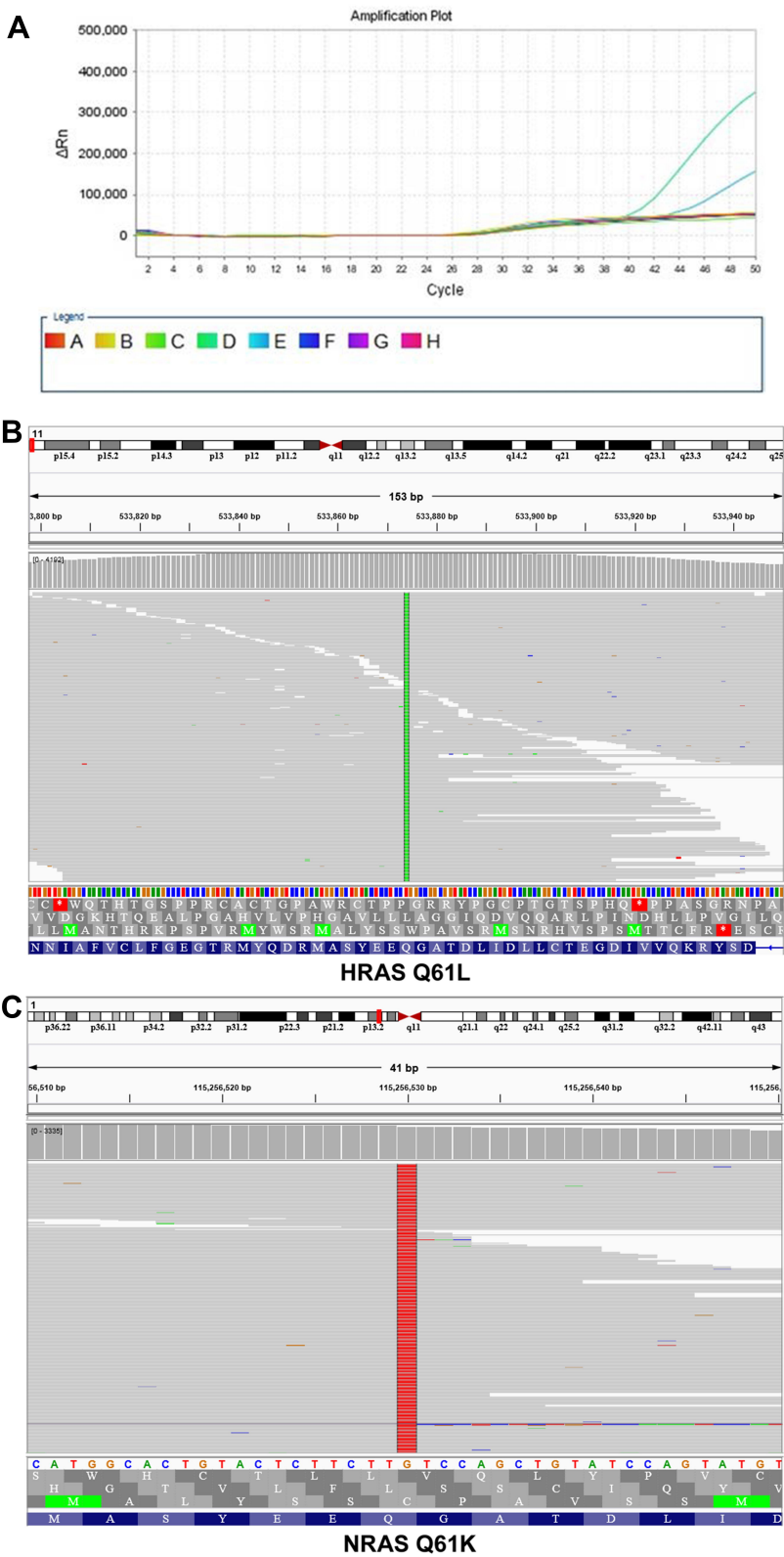


Figure 2 ARMS-PCR demonstrated *EGFR* mutations L858R and T790M (**A**) and NGS identified *HRAS* Q61L (**B**) and *NRAS* Q61K (**C**) mutations.

and *NRAS*-mutant cell lines were demonstrated to be sensitive to the MEK inhibitors, selumetinib and trametinib.¹²

While the single mutation in either *NRAS* or *HRAS* is rare in lung cancer, the double mutation in *NRAS* and *HRAS*, which we present in this case report, is even rarer and had never been reported before. The patient had rapid progression and died about 1 month after diagnosis. It is worth mentioning that *EGFR* L858R/T790M mutations were detected by ARMS-PCR in the pleural effusion sample, prompting the administration of osimertinib. However, no *EGFR* mutation was found by NGS, a more precise and comprehensive methodology for mutation analysis. Whether tumor heterogeneity or false detection that brought about these inconsistent results from the two molecular assays is unclear; however, the use of EGFR-TKIs could partly account for the patient's poor prognosis. In conclusion, our case indicates that *NRAS* and *HRAS* mutations in NSCLC are associated with poor prognosis. Further research and description of clinical cases are needed for improved better understanding of these genetic mutations in NSCLC.

Ethical Approval

Institutional approval was not required to publish the case details.

Patient Informed Consent

Written informed consent was obtained from the patient for the publication of his case details and images.

Acknowledgments

We are grateful to the patient and her family. Also, we wish to express our gratitude to the clinical investigators, study coordinators, operation staff, and all other team members on this project.

Disclosure

Tian Qin and Xuiliang Niu are affiliated with Burning Rock Biotech. The authors declare no other conflicts of interest.

References

1. Cox AD, Fesik SW, Kimmelman AC, Luo J, Der CJ. Drugging the undruggable RAS: mission possible? *Nat Rev Drug Discov*. 2014;13(11):828–851.
2. Karachaliou N, Mayo C, Costa C, et al. KRAS mutations in lung cancer. *Clin Lung Cancer*. 2013;14(3):205–214. doi:10.1016/j.clcc.2012.09.007
3. Chapman AM, Sun KY, Ruestow P, Cowan DM, Madl AK. Lung cancer mutation profile of EGFR, ALK, and KRAS: meta-analysis and comparison of never and ever smokers. *Lung Cancer*. 2016;102:122–134. doi:10.1016/j.lungcan.2016.10.010
4. Clinkscales W, Ong A, Nguyen S, Harruff EE, Gillespie MB. Diagnostic value of RAS mutations in indeterminate thyroid nodules. *Otolaryngol Head Neck Surg*. 2017;156(3):472–479. doi:10.1177/0194599816685697
5. Cicens J, Tamosaitis L, Kvederaviciute K, et al. KRAS, NRAS and BRAF mutations in colorectal cancer and melanoma. *Med Oncol*. 2017;34(2):26. doi:10.1007/s12032-016-0879-9
6. Tripathi K, Goel A, Singhai A, Garg M. Mutational analysis of Ras hotspots in patients with urothelial carcinoma of the bladder. *World J Clin Oncol*. 2020;11(8):614–628. doi:10.5306/wjco.v11.i8.614
7. Nassar KW, Tan AC. The mutational landscape of mucosal melanoma. *Semin Cancer Biol*. 2020;61:139–148. doi:10.1016/j.semcancer.2019.09.013
8. Mo L, Zheng X, Huang HY, et al. Hyperactivation of Ha-ras oncogene, but not Ink4a/Arf deficiency, triggers bladder tumorigenesis. *J Clin Invest*. 2007;117(2):314–325. doi:10.1172/JCI30062
9. Boidot R, Chevrier S, Julie V, Ladoire S, Ghiringhelli F. HRAS G13D, a new mutation implicated in the resistance to anti-EGFR therapies in colorectal cancer, a case report. *Int J Colorectal Dis*. 2016;31(6):1245–1246. doi:10.1007/s00384-015-2448-7
10. Cathcart-Rake E, Corless C, Sauer D, Lopez-Chavez A. Elderly former smoker with HRAS mutant non-small-cell lung cancer. *J Thorac Oncol*. 2014;9(10):e75–78. doi:10.1097/JTO.0000000000000315
11. Kiessling MK, Curioni-Fontecedro A, Samaras P, et al. Mutant HRAS as novel target for MEK and mTOR inhibitors. *Oncotarget*. 2015;6(39):42183–42196. doi:10.18632/oncotarget.5619
12. Ohashi K, Sequist LV, Arcila ME, et al. Characteristics of lung cancers harboring NRAS mutations. *Clin Cancer Res*. 2013;19(9):2584–2591. doi:10.1158/1078-0432.CCR-12-3173

OncoTargets and Therapy

Publish your work in this journal

OncoTargets and Therapy is an international, peer-reviewed, open access journal focusing on the pathological basis of all cancers, potential targets for therapy and treatment protocols employed to improve the management of cancer patients. The journal also focuses on the impact of management programs and new therapeutic

agents and protocols on patient perspectives such as quality of life, adherence and satisfaction. The manuscript management system is completely online and includes a very quick and fair peer-review system, which is all easy to use. Visit <http://www.dovepress.com/testimonials.php> to read real quotes from published authors.

Submit your manuscript here: <https://www.dovepress.com/oncotargets-and-therapy-journal>

Dovepress