

# Severe cast burn after bunionectomy in a patient who received peripheral nerve blocks for postoperative analgesia

Patrick K Boyle  
John J Badal  
Joelle W Boeve

Department of Anesthesiology,  
Arizona Health Sciences Center,  
Tucson, AZ, USA

**Abstract:** Although regional anesthesia offers advantages for intraoperative and postoperative pain relief, it is not possible without complications. A case of a significant burn injury after splint placement is described after a peripheral nerve block was performed for postoperative pain management. It is our hope that this case alerts physicians and others involved in the management of postoperative patients to the challenges of managing a blocked extremity after thermal cast placement and offers solutions that can be standardized.

**Keywords:** Peripheral nerve block, cast burn, postoperative complication

## Introduction

Although regional anesthesia offers advantages for intraoperative and postoperative pain relief, it is not without complications.<sup>1,2</sup> The majority of complications associated with peripheral nerve blocks are due to local anesthetic toxicity after inadvertent intravascular injection.<sup>3</sup> However, there are many other well known complications. The increasing use of ultrasound guidance for, eg, intraneural or intravascular injections, may reduce some of these risks, although not completely eliminate them. Postoperative management of peripheral nerve blocks, and cohesive standardized steps to prevent complications have received little attention. A case of a significant burn injury after splint placement is described after a peripheral nerve block was performed for postoperative pain management. It is our hope that this case alerts physicians and others involved in the management of postoperative patients to the challenges of managing a blocked extremity after thermal cast placement.

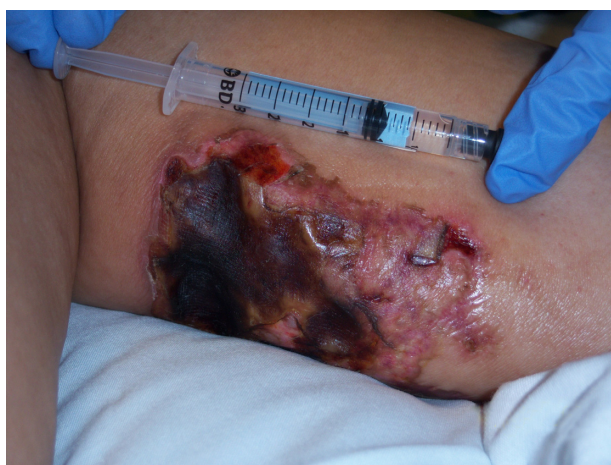## Case presentation

A 62-year-old woman weighing 61 kg presented for an elective modified right McBride bunionectomy, right first metatarsal osteotomy, and right second hammertoe correction. She previously underwent the same surgery for a left hallux valgus deformity, and did very well without complications under regional and general anesthesia. Her past medical history was significant for hypertension, migraine headaches, and depression.

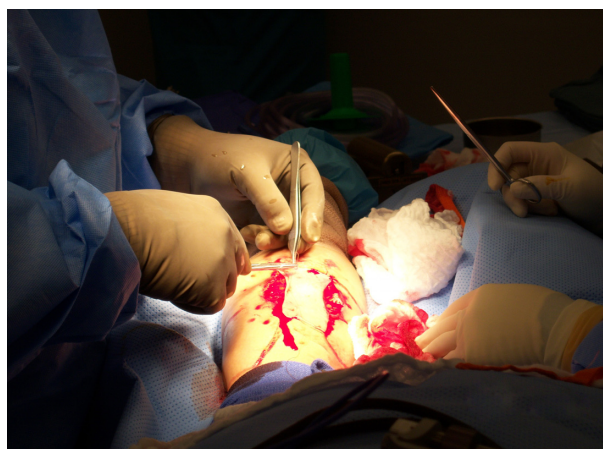
Preoperatively, at approximately 11:40 am on the day of surgery, popliteal and saphenous nerve blocks were administered for postoperative analgesia. Fentanyl 50 µg and midazolam 2 mg was given prior to the blocks. The area was cleaned with chlorhexidine solution. The skin was anesthetized with 5 mL of 1% lidocaine. Under ultrasound guidance, a 22-gauge 3.5-inch spinal needle was inserted, and 40 mL of 0.25% bupivacaine with 1:200,000 epinephrine was injected incrementally,

Correspondence: Patrick K Boyle  
Department of Anesthesiology, Arizona  
Health Sciences Center, 1501 N  
Campbell Avenue, Room 5301,  
Tucson, Arizona 85724, USA  
Tel +1 520 626 7221  
Fax +1 520 626 6943  
Email joshua19pb@aol.com

with aspiration every 5 mL, 30 mL in the popliteal region, and 10 mL in the saphenous region. There was no blood aspirated, pain, or paresthesias on injection. The patient was taken to the operating room at approximately 12:10 pm. She underwent an uneventful general anesthetic with a laryngeal mask airway. A tourniquet was placed on the right proximal thigh at 250 mmHg. The surgery went as planned, with no complications, and the total tourniquet time was approximately 120 minutes. At the conclusion of surgery at approximately 2:30 pm, a soft padded bulky Jones dressing was placed over the lower extremity with a plaster posterior splint (BSN Medical Specialist). The temperature of the water was noted to be warm, but no exact temperature was recorded. The splint was folded over slightly at the edge of the splint near the posterior knee. She was transferred to the postanesthesia care unit at 2:47 pm. Her stay in the postanesthesia care unit was uneventful until approximately 3:30 pm, when she complained of 6/10 pain in her foot. It was noted in the nurse's notes that she had difficulty localizing the pain and was given hydromorphone 0.4 mg. When this did not relieve her pain, the anesthesiologist was called, and it was decided to "touch up" her block. At 1605, popliteal nerve and saphenous nerve blocks were performed using the aforementioned technique, with 20 mL and 10 mL of 0.25%, respectively. She developed adequate analgesia and was discharged from the postanesthesia care unit at 5:24 pm with 0/10 pain. She presented to the orthopedic clinic on postoperative day 3 with severe pain in the lower extremity. The splint and dressing were removed to reveal a partial third degree burn on the posterior lower leg (Figure 1) which eventually required a skin graft (Figure 2). Follow-up with the patient after her recovery from the second surgery revealed no further problems or long-term pain conditions.



**Figure 1** Third degree burn after PACU block.



**Figure 2** Postoperative skin graft after burn.

## Discussion

Regional anesthesia is considered to be safe. It decreases postoperative mortality caused by thromboembolic disease and myocardial infarction, improves postoperative analgesia, decreases the incidence of early postoperative cognitive dysfunction, and allows shorter recovery times.<sup>1,2</sup> However, there are well known complications, including local anesthetic toxicity, infection, hematoma, nerve damage, and, depending on the area blocked, pneumothorax, hemothorax, and respiratory failure.<sup>5</sup> Certain situations and surgeries bring additional challenges to regional anesthesia, such as thermal cast placement applied to a blocked extremity. Cast application techniques are known to prevent burn injuries<sup>4,6</sup> but, as with any procedure, mistakes still occur. Internal temperatures can reach  $>50^{\circ}\text{C}$  with a fast curing plaster cast, and it has been found that  $>49^{\circ}\text{C}$  is enough to cause significant burn injuries.<sup>6</sup> Unfortunately, the pain of a burn injury from a thermal cast can be masked in a patient with a blocked extremity. Peripheral nerve blocks for orthopedic procedures are now becoming commonplace, so increasing awareness of this possible complication to prevent such injuries is needed. For patient safety, our institution focuses on leg elevation, moving noninjured digits of the affected limb, and monitoring pulse oximetry to test perfusion of the extremity, but little temperature related. One study measured the internal temperature using a simple temperature sensor (Temp Sensor Thermistor 400 series; Tyco Healthcare, Harrisburg, PA) and found it to be adequate for evaluating the skin under plaster cast burns.<sup>7</sup> This may be a simple technique to evaluate a blocked extremity with a cast. Subjective evaluation of the temperature of the cast by touching or measuring the external temperature is open to individual interpretation, and could introduce too much variability and inaccuracy based on the layering present and type of cast used.

Any complaint of pain should be thoroughly investigated by the nursing staff in the postoperative anesthesia care unit, with special consideration given to avoiding thermal injuries, and temperature measurements of the skin should be done prior to the administration of opioids. The anesthesiologist should be notified early about pain in these patients, should participate in the evaluation, and be mindful of the possibility of thermal burns occurring in the setting of postoperative regional blockade. It may be necessary to alert the surgeon, and strong consideration should be given to possible removal of the plaster material to assess for thermal injury.

This case is illustrative of the fact that, even in the setting of regional blockade, there may be other reasons for what could be perceived as a failed regional blockade, and additional opioids and/or touch up nerve blocks should not be done without a thorough evaluation of the plaster cast and underlying skin. While this case involves a competent, awake adult female, it does prompt consideration of the possibility that other patient populations may be at greater risk for this complication due to inability to provide appropriate feedback and communicate possible breakthrough thermal-mediated pain. These patient populations include children and the elderly, who may not be able to communicate, and patients who have been heavily sedated. The risk-benefit of performing regional blockade should be assessed prior to undertaking this procedure. Regarding the casting material used, in this case the BSN Medical Specialist synthetic splint (BSN Medical Distribution Ltd, Brierfield, UK), there are generalized precautions that include the warning to the patient that the splint may feel warm. There are no published precautions regarding the use of this material in conjunction with peripheral nerve blocks.<sup>8</sup>

## Conclusion

It is not known with certainty if the cast used in our patient was too hot, too thick, or if it was adequately padded. The patient certainly complained of increased pain in the postanesthesia care unit which resulted in an additional block leading to this poor outcome. There were no indicators that the patient failed to receive adequate blockade, so this

breakthrough pain was likely related to unrecognized ongoing thermal injury. Communication with nursing staff, as well as other anesthesiology colleagues, is important when a cast is placed on a blocked extremity to alert those involved in caring for the patient with a splint or cast of the possibility of thermal injury. The best method to assess for possible thermal injury is not known, but certainly the evaluation should begin early, and involve both the anesthesiologist and the surgeon. This could save patients from the debilitating complication of a burn injury, and improve our postoperative strategies.

## Acknowledgment

This paper was supported by the Department of Anesthesiology, University of Arizona, Tucson, Arizona.

## Disclosure

This case was presented as a “medically challenging case presentation” at the national meeting of the American Society of Anesthesiologists, October 2010, New Orleans, LA. Otherwise the authors report no conflicts of interest in this work.

## References

1. Rodgers A, Walker N, Schug S, et al. Reduction of postoperative mortality and morbidity with epidural or spinal anaesthesia: Results from overview of randomised trials. *BMJ*. 2000;321:1493.
2. Wulf H, Biscop J, Beland B, Bachmann-Mennenga B, Motsch J. Ropivacaine epidural anesthesia and analgesia versus general anesthesia and intravenous patient-controlled analgesia with morphine in the perioperative management of hip replacement. Ropivacaine Hip Replacement Multicenter Study Group. *Anesth Analg*. 1999;89:111–116.
3. Finucane B. *Complications of Regional Anesthesia*. 2nd ed. New York, NY: Springer; 2007.
4. Halanski M, Halanski A, Oza A, Vanderby R, Munoz A, Noonan K. Thermal injury with contemporary cast – application techniques and methods to circumvent morbidity. *J Bone Joint Surg Am*. 2007;89:2369–2377.
5. Morgan GE, Mikhail M. *Clinical Anesthesiology*. 4th ed. New York, NY: Lange Medical Books/McGraw-Hill Medical Publishing Division; 2006.
6. Hutchison MJ, Hutchison MR. Factors contributing to the temperature beneath plaster or fiberglass cast material. *J Orthop Surg Res*. 2008;3:10.
7. Read J, Ferguson N, Ricketts D. Plaster cast burns: The reality. *Emerg Med J*. 2008;25:827–828.
8. Package Insert. BSN Medical Specialist Ortho-Glass. [www.bsnmedical.com](http://www.bsnmedical.com).

### Local and Regional Anesthesia

### Publish your work in this journal

Local and Regional Anesthesia is an international, peer-reviewed, open access journal publishing on the development, pharmacology, delivery and targeting and clinical use of local and regional anesthetics and analgesics. The journal welcomes submitted papers covering original research, basic science, clinical studies, reviews & evaluations,

Submit your manuscript here: <http://www.dovepress.com/local-and-regional-anesthesia-journal>

Dovepress

guidelines, expert opinion and commentary, case reports and extended reports. The manuscript management system is completely online and includes a very quick and fair peer-review system, which is all easy to use. Visit <http://www.dovepress.com/testimonials.php> to read real quotes from published authors.