

# Acquired *ALK* Resistance Mutations Identified from Liquid Biopsy in an *ALK*-Rearranged Squamous Cell Lung Cancer Patient Treated with Sequential *ALK* TKI Therapy: A Case Report

Bin Yao<sup>1</sup>  
Xue Han<sup>2</sup>  
Linrong Pang<sup>1</sup>  
Caihong Xu<sup>1</sup>  
Sisi Liu<sup>2</sup>  
Xiaochun Cheng<sup>1</sup>  
Jun Chen<sup>1</sup>

<sup>1</sup>Department of Radiotherapy and Chemotherapy, The Affiliated People's Hospital of Ningbo University, Ningbo, Zhejiang, People's Republic of China;

<sup>2</sup>Department of Research and Development, Nanjing Geneseeq Technology Inc., Nanjing, Jiangsu, People's Republic of China

**Abstract:** Anaplastic lymphoma kinase (*ALK*) rearrangement is extremely rare in lung squamous cell carcinoma (LSCC), and it remains controversial as to whether LSCC patients with *ALK* rearrangement can benefit from *ALK* tyrosine kinase inhibitors (TKIs). Here, we report an LSCC patient with *ALK* rearrangement who was treated with sequential *ALK* TKI therapies and experienced a clinical benefit of 35 months. Although the use of *ALK* TKIs showed clinical benefits, targeted next-generation sequencing (NGS) for dynamic monitoring of circulating tumor DNA (ctDNA) from patient plasma revealed the accumulation of *ALK* resistance mutations, which could provide valuable information in designing the treatment strategy. Our study highlights the importance of dynamic monitoring of ctDNA using NGS to discover tumor evolution to guide treatment decision-making and provides meaningful insights into the potential treatment options for *ALK*-positive LSCC patients.

**Keywords:** *ALK* rearrangement, dynamic monitoring, resistance mutation, next-generation sequencing

## Introduction

Non-small cell lung carcinoma (NSCLC) is the main type of lung cancer, among which the most common histological subtypes are lung adenocarcinoma (LADC) and lung squamous cell carcinoma (LSCC).<sup>1</sup> With the development of targeted therapy and next-generation sequencing (NGS) technology, the therapeutic strategies for lung cancer have evolved into targeted precision medicine.

Tumor cells release circulating free DNA (cfDNA) into the blood. A liquid biopsy or blood sample can provide comprehensive genetic information of all cancerous lesions (primary and metastases), which overcomes spatial and temporal heterogeneity of a single tissue biopsy, as well as facilitates dynamic tracking of genomic evolution in a minimally invasive manner.

In LADC, anaplastic lymphoma kinase (*ALK*) rearrangement has been one of the most common targetable alterations, occurring in approximately 5% of LADC patients.<sup>2</sup> In contrast to LADC, *ALK*-rearranged LSCC is rare with an estimated frequency at 0–1.36%.<sup>3</sup> Crizotinib is a first-generation *ALK* tyrosine kinase inhibitor (TKI) approved for use in *ALK*-positive NSCLC patients. Despite a high initial efficacy, almost all treated patients eventually develop resistance to crizotinib, including secondary

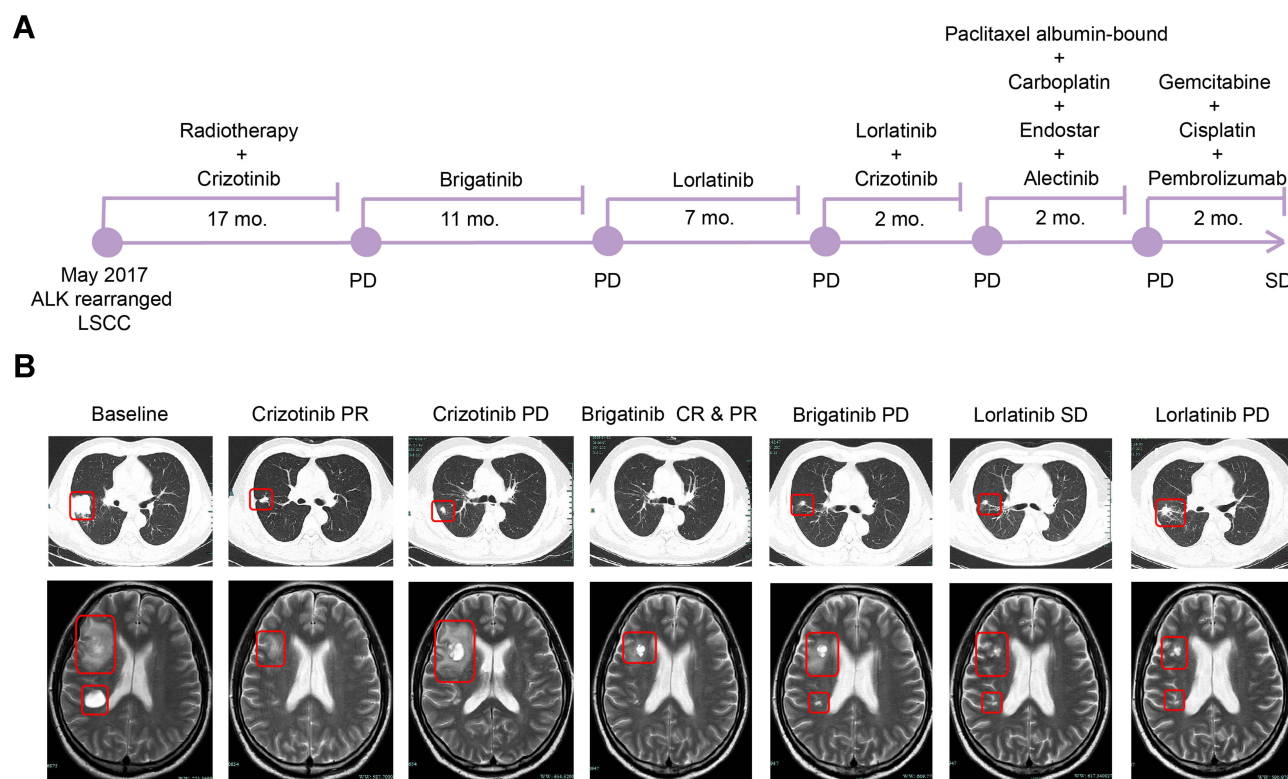
Correspondence: Xiaochun Cheng; Jun Chen  
Department of Radiotherapy and Chemotherapy, The Affiliated People's Hospital of Ningbo University, Ningbo, Zhejiang, People's Republic of China  
Tel +86-13736005125; +86-13777975439  
Email cxc5125@163.com  
junchen201211@163.com

mutations in *ALK*, and experience disease progression. However, the second-generation *ALK* TKIs ceritinib, alectinib and brigatinib, are effective against the acquired resistance mutations of crizotinib.<sup>4-6</sup> Additionally, third-generation *ALK* TKIs, including lorlatinib, entrectinib, and ensartinib, also overcome resistance to first- and second-generation *ALK* inhibitors and exhibit marked efficacy against brain metastasis.<sup>7,8</sup> Although *ALK*-targeted therapy has demonstrated clear clinical utility for NSCLC patients with *ALK* gene fusions, it remains controversial as to whether *ALK*-rearranged LSCC patients could benefit from *ALK* TKIs.<sup>9</sup> Herein, we report a LSCC patient with *ALK* rearrangement who was treated with sequential therapies of *ALK* TKIs. The patient exhibited a clinical benefit of 35 months and showed stable disease on immunotherapy plus chemotherapy after experiencing failure from multiline treatments.

## Case Report

A 46-year-old male with no smoking history was diagnosed with stage IVB LSCC (cT2bN2M1c) with three brain metastases in May 2017 (Supplementary Figure 1). A computed tomography (CT) scan and magnetic resonance

imaging (MRI) indicated a 4×5 cm dense mass in the right lung and metastatic lesions in the brain, respectively (Figure 1B, Baseline). Immunohistochemistry (IHC) staining of a tumor biopsy was positive for the LSCC markers P40, P63, and cytokeratin (CK) 5/6, but negative for the LADC markers thyroid transcription factor-1 (TTF-1), CK7, and Napsin-A. An *EML4-ALK* fusion was identified by amplification refractory mutation system-polymerase chain reaction (ARMS-PCR) using an AmoyDx *EML4-ALK* Fusion Gene Detection Kit. The patient was initially treated with crizotinib (250 mg once daily) and whole-brain radiotherapy (30Gy/10F) to relieve the symptom of dizziness. After an initial partial response (PR) was achieved (Figure 1B, Crizotinib PR), the patient exhibited a progression-free survival (PFS) of 17 months (Figure 1A). In October 2018, the size of the brain lesions increased and a new lung lesion was observed (Figure 1B, Crizotinib PD), thus, indicating progressive disease (PD). Subsequently, cell-free DNA extracted from 4 mL of plasma was subjected to library construction, followed by capture-based targeted NGS using a panel of 139 cancer-related genes spanning 110 KB of the human genome. NGS



**Figure 1** Medication strategy and disease conditions of the patient during treatment. **(A)** An illustrated summary of the treatment received by the patient. **(B)** Thoracic CT images of primary lung lesions and MRI images of brain metastatic lesions during sequential *ALK*-TKI treatment. Tumors are indicated by red frames.

**Abbreviations:** LSCC, lung squamous cell carcinoma; mo., months; CR, complete response; PR, partial response; PD, progressive disease; SD, stable disease.

revealed an *EML4-ALK* fusion (E6:A20) with a mutation allelic frequency (MAF) of 0.1% in the patient's plasma ctDNA (Table 1). The patient was then switched from crizotinib to brigatinib at a dose of 90 mg in the first week and 180 mg thereafter. The patient achieved a complete response (CR) for the lung lesion and a PR for the brain lesions (Figure 1B, Brigatinib CR & PR). In September 2019, the disease progressed again with a PFS of 11 months (Figure 1A). NGS of the patient's plasma using a panel of 139 cancer-related genes revealed a new *ALK* G1202R (MAF = 0.2%) mutation, in addition to the *EML4-ALK* fusion (MAF = 0.1%) (Table 1). A third-line treatment with lorlatinib was administered at a dose of 100 mg and achieved a PFS of 7 months (Figure 1A). Lorlatinib (100 mg QD) and crizotinib (250 mg QD) were then taken by the patient himself at the same time. However, within 2 months of initiating this therapy, additional symptoms developed, indicating PD (Figure 1A). Follow-up genomic testing with 139 cancer-related genes identified only the *EML4-ALK* fusion (MAF = 0.1%), while the *ALK* G1202R mutation was absent from plasma samples (Table 1). The patient was then administered a treatment of alectinib (600 mg twice daily) and chemotherapy consisting of albumin-bound paclitaxel (400 mg d1) and carboplatin (500 mg d1). Endostar, a modified recombinant human endostatin that suppresses angiogenesis, was also administered at a dose of 30 mg. After 2 months of treatment (Figure 1A), the disease progressed and in addition to the *EML4-ALK* (MAF = 0.1%) and *ALK* G1202R (MAF = 0.1%) mutations in the plasma, new mutations were again identified by NGS targeting 139 cancer-related genes, including *ALK* D1203N (MAF = 0.3%), *SMARCA4* R1243W (MAF = 0.3%), and *TP53* P152L (MAF = 0.3%) (Table 1).

In July 2020, although PD-L1 expression was negative, the therapy was switched to an immunochemotherapy regimen consisting of gemcitabine (1.8 g d1 and d8), cisplatin (40 mg d1–3), and pembrolizumab (100 mg). Following this treatment, the patient achieved SD with a sustained and ongoing response for 2 months (Figure 1A).

## Discussion

*ALK* rearrangement occurs in ~5% of LADC patients, but in only ~1% of LSCC patients.<sup>10</sup> Thus, it remains unknown whether LSCC patients with *ALK* rearrangements would benefit from *ALK* TKI therapy. In the present case, the patient was diagnosed with LSCC with an *ALK* fusion. Sequential administration of *ALK* TKIs (crizotinib, brigatinib, and lorlatinib) was performed and provided a clinical benefit of 35 months. However, such treatment may also have accelerated the accumulation of *ALK*-resistance mutations, which was also reported in a previous study.<sup>11</sup> Among the *ALK*-resistance mutations in NSCLC reported by other studies, including G1269R, F1174L, E1210K, L1196M, G1202R, D1203N and F1171T,<sup>11–13</sup> we identified the G1202R and D1203N mutations in this case using dynamic NGS monitoring. No resistance mutations were detected following crizotinib failure, which could be due to the MAF being below the detection limit of our assay (0.05% with sequencing depth at 30,000 x). Additionally, the patient's tumor sample, which might have had other resistance mutations, was insufficient for genetic testing as the tissue biopsy was too small and was subjected to pathological and immuno-histochemical analyses instead. Thus, further evaluations could be performed for this patient. Notably, *ALK* G1202R was previously reported as a potential brigatinib resistance mutation, which was also consistent with our findings.<sup>14</sup> It

**Table 1** Genetic Alterations Detected in ctDNA Samples During the Treatment Course

Gene	Variation Detected	Post-Treatment <sup>a</sup>			
		Crizotinib PD	Brigatinib PD	Lorlatinib + Crizotinib PD	Paclitaxel Albumin-Bound + Carboplatin + Endostar + Alectinib PD
<i>ALK</i>	<i>EML4</i> :exon 6- <i>ALK</i> : exon 20	0.1%	0.1%	0.1%	0.1%
<i>ALK</i>	G1202R	–	0.2%	–	0.1%
<i>ALK</i>	D1203N	–	–	–	0.3%
<i>SMARCA4</i>	R1243W	–	–	–	0.3%
<i>TP53</i>	P152L	–	–	–	0.3%

**Notes:** <sup>a</sup>Mutant allele frequencies are indicated; –Indicates not detected.

**Abbreviation:** PD, progressive disease.

was also reported that lorlatinib could inhibit the *ALK* G1202R mutant,<sup>7</sup> and in the current case, the *ALK* G1202R mutation was not detected following lorlatinib and crizotinib treatment. However, two *ALK*-resistance mutations, *ALK* G1202R and D1203N, were detected following the failure of the combined treatment (chemotherapy, endostar and alectinib).

*ALK* G1202R was also reported as an alectinib resistance mutation,<sup>15</sup> while D1203N has only been reported in a single patient who received ceritinib or brigatinib, but not alectinib.<sup>16</sup> However, the *ALK* D1203N mutation was more common following relapse on lorlatinib, and was almost always observed with other *ALK*-mutants.<sup>17</sup>

As chemotherapy with endostar has proved to be effective for advanced NSCLC patients and could be a salvage strategy for patients experiencing failure with targeted therapies,<sup>18–20</sup> the patient in this study received a combined treatment of chemotherapy, endostar, and alectinib.

Mutations in the *TP53* gene have been reported in 50% of NSCLC patients with the frequency of such alterations being highest in LSCC patients.<sup>21</sup> Moreover, non-disruptive *TP53* mutations are associated with shorter survival times in patients with advanced NSCLC.<sup>22</sup> In this case, the *TP53* mutation P152L was detected following the conclusion of the combined treatment of chemotherapy, endostar, and alectinib, and the disease progressed within two months thereafter. Currently, no standard treatment exists for patients with the acquired mutations identified in this study following sequential TKI therapy. It has been reported that pembrolizumab combined with platinum-based chemotherapy could improve OS and PFS for metastatic LSCC, regardless of the level of PD-L1 expression.<sup>23</sup> Hence, the patient was administered gemcitabine, cisplatin, and pembrolizumab as a sixth-line treatment and achieved SD.

## Conclusions

In summary, our report presented a rare *ALK*-positive LSCC patient who was treated with sequential TKI therapies and developed different resistance mutations, which were detected by dynamic NGS monitoring. We highlight the importance of dynamic monitoring of ctDNA using NGS to identify genomic tumor evolution and guide treatment decision-making. Thus, this study provides meaningful insight into the potential treatment options for *ALK*-positive LSCC patients.

## Data Sharing Statement

All datasets generated for this study are included in the manuscript.

## Ethics Approval and Consent for Publication

This research was approved by the Ethics Committee of The Affiliated People's Hospital of Ningbo University, and written informed consent for publication of the clinical details and images was obtained from the patient, and did not require institutional approval to publish the case details.

## Author Contributions

All authors made a significant contribution to the work reported, whether that is in the conception, study design, execution, acquisition of data, analysis and interpretation, or in all these areas; took part in drafting, revising or critically reviewing the article; gave final approval of the version to be published; have agreed on the journal to which the article has been submitted; and agree to be accountable for all aspects of the work.

## Disclosure

Xue Han and Sisi Liu are employees of Nanjing Geneseeq Technology Inc., China. The authors report no other conflicts of interest to declare.

## References

1. Fernandez-Cuesta L, Foll M. Molecular studies of lung neuroendocrine neoplasms uncover new concepts and entities. *Transl Lung Cancer Res.* 2019;8(Suppl 4):S430–S434. doi:10.21037/tlcr.2019.11.08
2. Devarakonda S, Morgensztern D, Govindan R. Genomic alterations in lung adenocarcinoma. *Lancet Oncol.* 2015;16(7):e342–e351. doi:10.1016/S1470-2045(15)00077-7
3. Watanabe J, Togo S, Sumiyoshi I, et al. Clinical features of squamous cell lung cancer with anaplastic lymphoma kinase (*ALK*)-rearrangement: a retrospective analysis and review. *Oncotarget.* 2018;9(35):24000–24013. doi:10.18632/oncotarget.25257
4. Kim DW, Tiseo M, Ahn MJ, et al. Brigatinib in patients with crizotinib-refractory anaplastic lymphoma kinase-positive non-small-cell lung cancer: a randomized, multicenter phase II trial. *J Clin Oncol.* 2017;35(22):2490–2498. doi:10.1200/JCO.2016.71.5904
5. Facchinetti F, Bordi P, Bini P, Bidin L, Camisa R, Tiseo M. Enteral administration of TKIs: report of a response to ceritinib in an *ALK*-positive NSCLC patient and literature review. *Curr Drug Targets.* 2018;19(14):1649–1656. doi:10.2174/1389450119666180213102939
6. Fan J, Xia Z, Zhang X, et al. The efficacy and safety of alectinib in the treatment of *ALK*+ NSCLC: a systematic review and meta-analysis. *Onco Targets Ther.* 2018;11:1105–1115. doi:10.2147/OTT.S156170



7. Zou Helen Y, Friboulet L, Kodack David P, et al. PF-06463922, an ALK/ROS1 inhibitor, overcomes resistance to first and second generation ALK inhibitors in preclinical models. *Cancer Cell*. 2015;28(1):70–81. doi:10.1016/j.ccell.2015.05.010
8. Karachaliou N, Santarpia M, Gonzalez Cao M, et al. Anaplastic lymphoma kinase inhibitors in Phase I and phase II clinical trials for non-small cell lung cancer. *Expert Opin Investig Drugs*. 2017;26(6):713–722. doi:10.1080/13543784.2017.1324572
9. Wang H, Sun L, Sang Y, et al. A study of ALK-positive pulmonary squamous-cell carcinoma: from diagnostic methodologies to clinical efficacy. *Lung Cancer*. 2019;130:135–142. doi:10.1016/j.lungcan.2019.02.015
10. Yang X, Peng P, Zhang L. Multiline treatment of advanced squamous cell carcinoma of the lung: a case report and review of the literature. *World J Clin Cases*. 2019;7(14):1899–1907. doi:10.12998/wjcc.v7.i14.1899
11. Ding M, Deng L, Yu R, et al. Case report: temporal heterogeneity of ALK activating mutations in sequential ALK TKI-treated non-small-cell lung cancer revealed using NGS-based liquid biopsy. *Clin Lung Cancer*. 2019;20(3):e229–e232. doi:10.1016/j.clcc.2019.02.014
12. Nagasundaram N, Wilson Alphonse CR, Samuel Gnana PV, Rajaretinam RK. Molecular dynamics validation of crizotinib resistance to ALK mutations (L1196M and G1269A) and identification of specific inhibitors. *J Cell Biochem*. 2017;118(10):3462–3471. doi:10.1002/jcb.26004
13. Katayama R, Friboulet L, Koike S, et al. Two novel ALK mutations mediate acquired resistance to the next-generation ALK inhibitor alectinib. *Clin Cancer Res*. 2014;20(22):5686–5696. doi:10.1158/1078-0432.CCR-14-1511
14. Sabari JK, Santini FC, Schram AM, et al. The activity, safety, and evolving role of brigatinib in patients with ALK-rearranged non-small cell lung cancers. *Onco Targets Ther*. 2017;10:1983–1992. doi:10.2147/OTT.S109295
15. Ou SH, Azada M, Hsiang DJ, et al. Next-generation sequencing reveals a novel NSCLC ALK F1174V mutation and confirms ALK G1202R mutation confers high-level resistance to alectinib (CH5424802/RO5424802) in ALK-rearranged NSCLC patients who progressed on crizotinib. *J Thorac Oncol*. 2014;9(4):549–553. doi:10.1097/JTO.0000000000000094
16. Urbanska EM, Sorensen JB, Melchior LC, Costa JC, Santoni-Rugiu E. Changing ALK-TKI-resistance mechanisms in rebiopsies of ALK-rearranged NSCLC: ALK- and BRAF-mutations followed by epithelial-mesenchymal transition. *Int J Mol Sci*. 2020;21(8):2847. doi:10.3390/ijms21082847
17. Dagogo-Jack I, Rooney M, Lin JJ, et al. Treatment with next-generation ALK inhibitors fuels plasma ALK mutation diversity. *Clin Cancer Res*. 2019;25(22):6662–6670. doi:10.1158/1078-0432.CCR-19-1436
18. Qiu D, Zhang Y, Xue YB, et al. Chemotherapy combined with Endostar as salvage treatment for EGFR-tyrosine kinase inhibitor primary resistance in an advanced non-small cell lung cancer patient with EGFR L858R mutation and ROS1 fusion: a case report. *Thorac Cancer*. 2019;10(4):1023–1028. doi:10.1111/1759-7714.13003
19. Wang J, Sun Y, Qin S. Results of Phase IV clinical trial of combining endostar with chemotherapy for treatment of advanced non-small cell lung cancer (NSCLC). *J Clin Oncol*. 2010;28(15\_suppl):7598. doi:10.1200/jco.2010.28.15\_suppl.7598
20. Han B, Xiu Q, Wang H, et al. A multicenter, randomized, double-blind, placebo-controlled study to evaluate the efficacy of paclitaxel-carboplatin alone or with endostar for advanced non-small cell lung cancer. *J Thorac Oncol*. 2011;6(6):1104–1109. doi:10.1097/JTO.0b013e3182166b6b
21. Mogi A, Kuwano H. TP53 mutations in nonsmall cell lung cancer. *J Biomed Biotechnol*. 2011;2011:583929. doi:10.1155/2011/583929
22. Molina-Vila MA, Bertran-Alamillo J, Gascó A, et al. Nondisruptive p53 mutations are associated with shorter survival in patients with advanced non-small cell lung cancer. *Clin Cancer Res*. 2014;20(17):4647–4659. doi:10.1158/1078-0432.CCR-13-2391
23. Paz-Ares L, Luft A, Vicente D, et al. Pembrolizumab plus chemotherapy for squamous non-small-cell lung cancer. *N Engl J Med*. 2018;379(21):2040–2051. doi:10.1056/NEJMoa1810865

## OncoTargets and Therapy

### Publish your work in this journal

OncoTargets and Therapy is an international, peer-reviewed, open access journal focusing on the pathological basis of all cancers, potential targets for therapy and treatment protocols employed to improve the management of cancer patients. The journal also focuses on the impact of management programs and new therapeutic

agents and protocols on patient perspectives such as quality of life, adherence and satisfaction. The manuscript management system is completely online and includes a very quick and fair peer-review system, which is all easy to use. Visit <http://www.dovepress.com/testimonials.php> to read real quotes from published authors.

Submit your manuscript here: <https://www.dovepress.com/oncotargets-and-therapy-journal>

Dovepress