

A Novel *LOC101927967* Intergenic Region *ALK* Fusion Identified by NGS and Validated by IHC and FISH in a Patient with Early Stage Adenocarcinoma of Lung

Xiaojing Jia¹, Qianru He²⁻⁴, Xiaodan Xing²⁻⁴, Yanming Yang¹, Yan Ma¹

¹Department of Radiotherapy, The Second Hospital of Jilin University, Changchun, People's Republic of China; ²The Medical Department, Jiangsu Simcere Diagnostics Co., Ltd, Nanjing, People's Republic of China; ³Nanjing Simcere Medical Laboratory Science Co., Ltd, Nanjing, People's Republic of China; ⁴The State Key Lab of Translational Medicine and Innovative Drug Development, Jiangsu Simcere Diagnostics Co., Ltd, Nanjing, People's Republic of China

Correspondence: Yanming Yang; Yan Ma, Department of Radiotherapy, The Second Hospital of Jilin University, 218 Ziqiang Street, Changchun, 130041, People's Republic of China, Email yym180@163.com; 729958847@qq.com

Abstract: Anaplastic lymphoma kinase (*ALK*) gene rearrangement is an essential driver mutation identified in approximately 5% of non-small cell lung cancers (NSCLCs). The results of clinical trials have demonstrated the impressive efficacy of *ALK* tyrosine kinase inhibitors (*ALK*-TKIs). Besides the classic *EML4-ALK* fusions, a growing list of gene fusion partners for *ALK* in NSCLC have been identified with heterogeneous clinical responses to *ALK*-TKIs. However, a *LOC101927967-ALK* fusion has not been reported in NSCLC. Herein, a novel *LOC101927967* downstream intergenic region *ALK* fusion in an early-stage patient with lung adenocarcinoma was first identified by next-generation sequencing (NGS) and verified by immunohistochemical staining (IHC) and fluorescence in situ hybridization (FISH), which might provide a treatment option for postoperative recurrence.

Keywords: lung cancer, intergenic fusion, *ALK*

Introduction

Anaplastic lymphoma kinase (*ALK*) gene rearrangements appeared in approximately 5% of lung adenocarcinomas, which define a distinct molecular subgroup of non-small cell lung cancers (NSCLCs).¹ Clinical management *ALK* tyrosine kinase inhibitors (*ALK*-TKIs) have achieved impressive clinical outcomes.² Besides the classic *EML4-ALK* fusions, emerging fusion partners for *ALK* in NSCLCs have been identified, including intergenic-breakpoint fusions, which might also generate functional fusion protein by chromothripsis or alternative splicing and respond to crizotinib or alectinib.³ Herein, we reported a novel *LOC101927967* downstream intergenic region *ALK* fusion in an early-stage patient with lung adenocarcinoma by next-generation sequencing (NGS) and was verified by immunohistochemical staining (IHC) and fluorescence in situ hybridization (FISH).

Case Presentation

A 61-year-old Chinese man went to our hospital with cough, fever, and chest tightness for one month in April 2020. A chest computed tomography (CT) scan showed 8mm frosted glass in the left superior lobe. The edge was not smooth and had a burr (Figure 1A). According to the examinations related to admission, the preliminary diagnosis was a pulmonary malignancy. After the exclusion of surgical contraindications, the left upper lobectomy was performed on April 15, 2020. Postoperative pathology released invasive mucinous adenocarcinoma with a predominant lepidic growth consisting of a less micropapillary pattern. The patient was diagnosed with stage IA (pT1aN0M0) lung adenocarcinoma. CT scan was performed after the surgery in June 2020 (Figure 1B). For precision therapy, NGS analysis was carried out using a commercially available capture-based

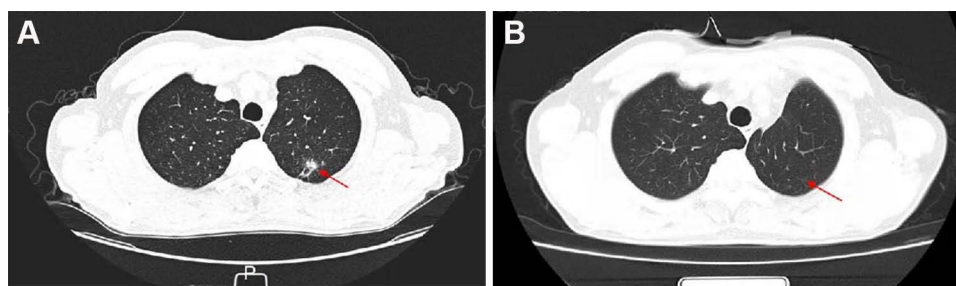


Figure 1 Chest computed tomography revealed the different stages of the patient's lung tumor. (A) Initial diagnosis revealed a nodular high-density shadow in the posterior segment of the upper lobe tip of the left lung in April 2020. (B) CT scan after the surgery in June 2020.

targeted sequencing panel, targeting 11 driver genes (*EGFR*, *ALK*, *ROS1*, *BRAF*, *ERBB2*, *MET*, *RET*, *KRAS*, and *NTRK1-3*) (Simceredx, CAP certified Laboratory) to provide a treatment option for postoperative recurrence. A novel *LOC101927967* (Intergenic)-*ALK* fusion was detected (Figure 2A and B). This fusion was generated by chr2:78561496 (intergenic region between *LOC101927967* and *REG3G*) and exons 20–29 of *ALK*, with the abundance of 13.35%. No other mutations were discovered. The result was confirmed by IHC staining (Ventana with D5F3 clone) and FISH (ZytoLight *ALK* Break Apart FISH Probe)(MEDx (Suzhou) Translational Medicine Co. Ltd) (Figure 3).

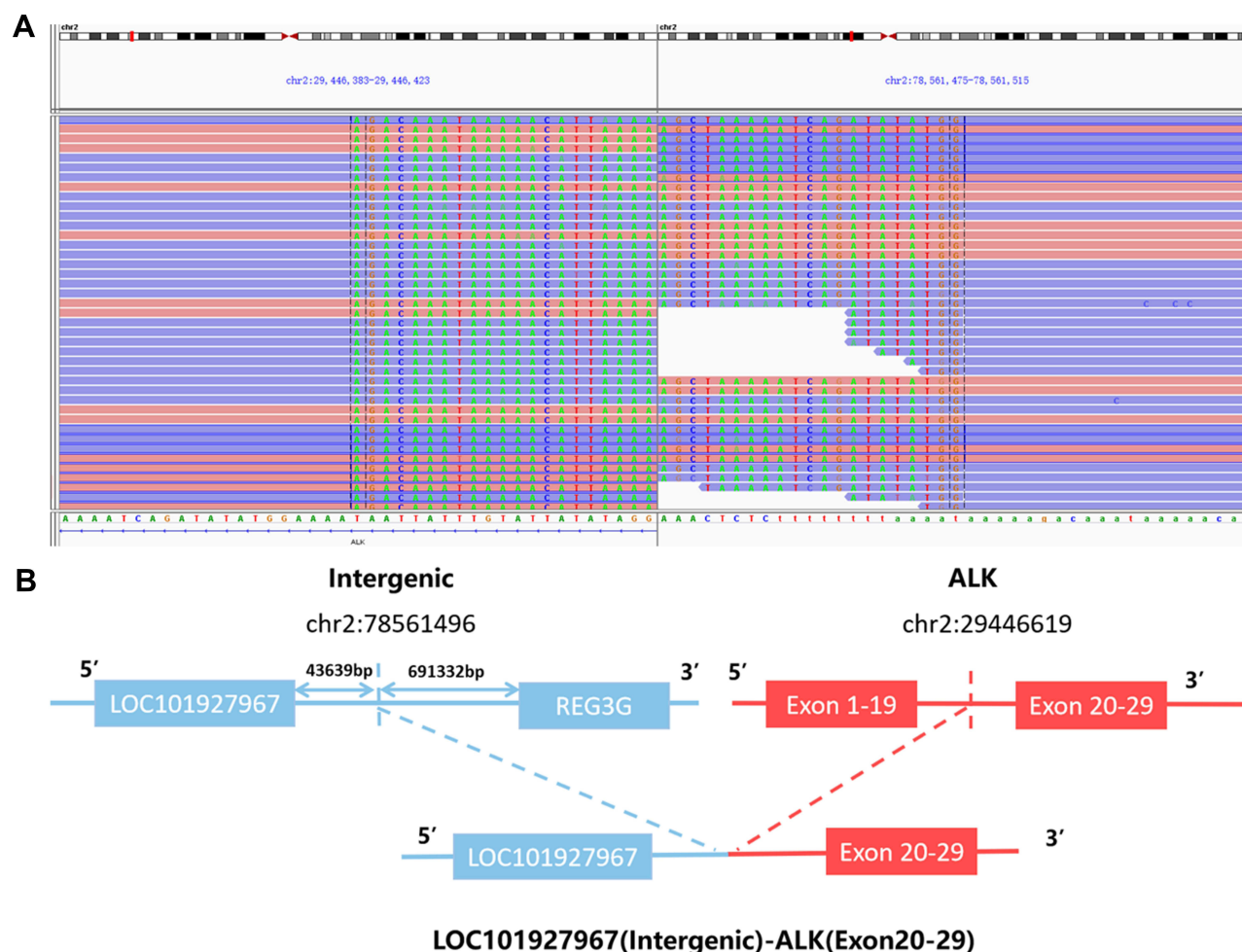


Figure 2 Next-generation sequencing findings of *LOC101927967*-*ALK* fusion. (A) The Integrative Genomics Viewer snapshot of *LOC101927967*-*ALK*. (B) Schematic representation of the *LOC101927967* intergenic region *ALK* fusion, this variant was generated by the fusion of intergenic region between *LOC101927967* and *REG3G* with exons 20–29 of *ALK*.

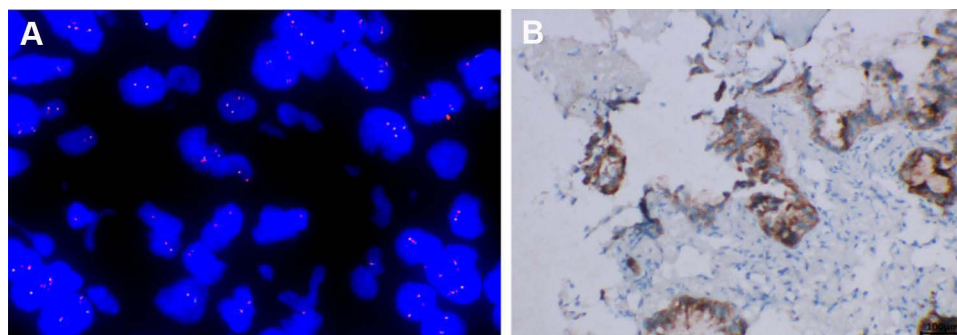


Figure 3 *LOC101927967*-*ALK* fusion in the patient with lung adenocarcinoma. **(A)** A split signal of *ALK* was observed with a frequency of 66% in the fluorescence in situ hybridization image. **(B)** The immunohistochemistry staining indicated strong positive *ALK* protein expression.

To date, there is no information about *LOC101927967*(Intergenic)-*ALK* fusion and validation assay. This *LOC101927967*(Intergenic)-*ALK* fusion was generated by the downstream intergenic region of *LOC101927967* with exons 19–29 of *ALK*, retaining the complete kinase domain of *ALK*. In addition, the results of IHC and FISH confirmed *ALK* fusion existed, which might drive oncogenesis. It is typically challenging to identify *ALK* fusion variants, incredibly complex rearrangements with intergenic breakpoints.

Discussion

To our knowledge, this is the first report describing the fusion of the intergenic region between *LOC101927967* intergenic region and *ALK* exon 20 in lung adenocarcinoma. The verification results of IHC and FISH indicated this novel fusion could be considered a sensitive variant, which may benefit from *ALK*-TKIs such as crizotinib or alectinib. *ALK* rearrangements generate an oncogenic *ALK* tyrosine kinase, which could activate downstream signaling pathways involving *MAPK* and *PIK3/AKT/mTOR* pathways.⁴ Multiple fusion partners have been described in lung cancer, but the response magnitude and duration are heterogeneous. To date, FISH and IHC methods are commonly used in clinical practice,^{5–7} although neither can identify a specific type of *ALK* fusion partners. FISH, the only FDA-approved companion diagnostic test for crizotinib treatment, is recognized as the standard gold method for clinical testing of *ALK* status. However, it is fraught with technical and financial problems and has a potential for a false-negative rate.⁸ IHC is widely implemented in pathology laboratories, is relatively inexpensive, faster, and easy to use. But its interpretation remains challenging to standardize and time-consuming.⁹ NGS, a high-throughput molecular analysis, can simultaneously detect single nucleotide variants (SNVs), gene copy number changes, deletions, insertions, and fusions, which can provide a wealth of information for clinical treatment. Thus NGS can be used as a screening method for *ALK* status and other driver genes,^{10,11} and FISH and/or IHC test can be a reasonable verification.¹²

In resected early-stage NSCLC, reports of the prognostic significance of *ALK*-rearrangement have been contradictory. A European Project reported *ALK*-positive early-stage lung adenocarcinomas was related to better overall survival (OS).¹³ In contrast, *ALK* rearrangements were associated with worse recurrence-free survival (RFS) than other driver genes.¹⁴ However, Liu et al reported that *ALK* rearrangement was not an independent prognostic factor in patients with surgically resected lung adenocarcinoma.¹⁵ Due to the early stage of lung cancer and financial considerations, the patient chooses to regularly surveillance instead of adjuvant therapy. *ALK*-TKIs can be considered after the patient progresses in our case. Our case report expands the spectrum of *ALK* arrangement types and provides possible *ALK*-TKI for consideration. Furthermore, more research is needed better to understand intergenic *ALK* fusion and *ALK*-positive early-stage NSCLC.

Conclusion

In conclusion, a novel *LOC101927967*(Intergenic)-*ALK* oncogenic fusion in a patient with early-stage adenocarcinoma of the lung was identified for the first time, which expanded the *ALK* fusion spectrum, and the patient in our case might benefit from the *ALK*-TKIs in the future.

Ethical Approval and Consent to Participate

The patient agreed to publish their case details. A written informed consent was obtained from the patient's family for publication of the case details.

Acknowledgments

We thank Ran Ding, Guanghua Lu, Wanglong Deng, Tingting Sun, and Chuang Qi from Jiangsu Simcere Diagnostics for their kind assistance.

Funding

This research did not receive any specific grant from funding agencies in the public, commercial, or not-for-profit sectors.

Disclosure

The authors have no conflicts of interest to declare in this work.

References

1. Barlesi F, Mazieres J, Merlio J-P, et al. Routine molecular profiling of patients with advanced non-small-cell lung cancer: results of a 1-year nationwide programme of the French Cooperative Thoracic Intergroup (IFCT). *Lancet (London, England)*. 2016;387(10026):1415–1426. doi:10.1016/s0140-6736(16)00004-0
2. Paliouras AR, Buzzetti M, Shi L, et al. Vulnerability of drug-resistant EML4-ALK rearranged lung cancer to transcriptional inhibition. *EMBO Mol Med*. 2020;12(7):e11099. doi:10.15252/emmm.201911099
3. Li W, Liu Y, Li W, Chen L, Ying J. Intergenic breakpoints identified by DNA sequencing confound targetable kinase fusion detection in NSCLC. *J Thorac Oncol*. 2020;15(7):1223–1231. doi:10.1016/j.jtho.2020.02.023
4. Yip PY. Phosphatidylinositol 3-kinase-AKT-mammalian target of rapamycin (PI3K-Akt-mTOR) signaling pathway in non-small cell lung cancer. *Transl Lung Cancer Res*. 2015;4:165–176. doi:10.3978/j.issn.2218-6751.2015.01.04
5. Solomon BJ, Mok T, Kim DW, et al. First-line crizotinib versus chemotherapy in ALK-positive lung cancer. *N Engl J Med*. 2014;371(23):2167–2177. doi:10.1056/NEJMoa1408440
6. Takeuchi K, Togashi Y, Kamihara Y, et al. Prospective and clinical validation of ALK immunohistochemistry: results from the Phase I/II study of alectinib for ALK-positive lung cancer (AF-001JP study). *Ann Oncol*. 2016;27(1):185–192. doi:10.1093/annonc/mdv501
7. Thorne-Nuzzo T, Williams C, Catallini A, et al. A sensitive ALK immunohistochemistry companion diagnostic test identifies patients eligible for treatment with crizotinib. *J Thorac Oncol*. 2017;12(5):804–813. doi:10.1016/j.jtho.2017.01.020
8. Smuk G, Pajor G, Szuhai K, et al. Attenuated isolated 3' signal: a highly challenging therapy relevant ALK FISH pattern in NSCLC. *Lung Cancer (Amsterdam, Netherlands)*. 2020;143:80–85. doi:10.1016/j.lungcan.2020.03.007
9. Marchetti A, Di Lorito A, Pace MV, et al. ALK protein analysis by IHC staining after recent regulatory changes: a comparison of two widely used approaches, revision of the literature, and a new testing algorithm. *J Thorac Oncol*. 2016;11(4):487–495. doi:10.1016/j.jtho.2015.12.111
10. Vendrell JA, Taviaux S, Béganton B, et al. Detection of known and novel ALK fusion transcripts in lung cancer patients using next-generation sequencing approaches. *Sci Rep*. 2017;7(1):12510. doi:10.1038/s41598-017-12679-8
11. Cainap C, Balacescu O, Cainap SS, Pop LA. Next generation sequencing technology in lung cancer diagnosis. *Biology*. 2021;10(9):864. doi:10.3390/biology10090864
12. Zhang J, Zou C, Zhou C, et al. A novel Linc00308/D21S2088E intergenic region alk fusion and its enduring clinical responses to crizotinib. *J Thorac Oncol*. 2020;15(6):1073–1077. doi:10.1016/j.jtho.2020.03.009
13. Blackhall FH, Peters S, Bubendorf L, et al. Prevalence and clinical outcomes for patients with ALK-positive resected stage I to III adenocarcinoma: results from the European Thoracic Oncology Platform Lungscape Project. *J Clin Oncol*. 2014;32(25):2780–2787. doi:10.1200/jco.2013.54.5921
14. Chaft JE, Dagogo-Jack I, Santini FC, et al. Clinical outcomes of patients with resected, early-stage ALK-positive lung cancer. *Lung Cancer (Amsterdam, Netherlands)*. 2018;122:67–71. doi:10.1016/j.lungcan.2018.05.020
15. Liu Y, Ye X, Yu Y, Lu S. Prognostic significance of anaplastic lymphoma kinase rearrangement in patients with completely resected lung adenocarcinoma. *J Thorac Dis*. 2019;11(10):4258–4270. doi:10.21037/jtd.2019.09.65

OncoTargets and Therapy

Dovepress

Publish your work in this journal

OncoTargets and Therapy is an international, peer-reviewed, open access journal focusing on the pathological basis of all cancers, potential targets for therapy and treatment protocols employed to improve the management of cancer patients. The journal also focuses on the impact of management programs and new therapeutic agents and protocols on patient perspectives such as quality of life, adherence and satisfaction. The manuscript management system is completely online and includes a very quick and fair peer-review system, which is all easy to use. Visit <http://www.dovepress.com/testimonials.php> to read real quotes from published authors.

Submit your manuscript here: <https://www.dovepress.com/oncotargets-and-therapy-journal>