




Bacterial Peritonitis Caused by *Tsukamurella inchonensis* in a Patient Undergoing Continuous Ambulatory Peritoneal Dialysis

Ling Tang , Ying Huang, Tingting Li, Yajuan Li , Yuanhong Xu 

Department of Clinical Laboratory, First Affiliated Hospital of Anhui Medical University, Hefei, People's Republic of China

Correspondence: Yuanhong Xu, Email xyhong1964@163.com

Background: *Tsukamurella* is an environmental saprophyte that potentially causes various infections in humans. It has been reported to cause rare opportunistic infections in immunocompromised patients or patients with indwelling foreign bodies.

Case Presentation: We report a case of continuous ambulatory peritoneal dialysis (CAPD)-related peritonitis caused by *Tsukamurella inchonensis* (*T. inchonensis*). The patient was admitted to our hospital while demonstrating a cloudy peritoneal dialysate. Peritoneal fluid sample culturing yielded yellow-greyish, dry and membrane-like colonies. Gram staining showed straight, gram-positive rods. The organism was identified to be *Tsukamurella* species by matrix-assisted laser desorption/ionization-time of flight mass spectrometry (MALDI-TOF MS). It was then characterized to be homologous to *T. inchonensis* in the GenBank database by 16S Ribosomal RNA Sequencing. The strain was susceptible to quinolones, carbapenems and linezolid, but intermediately resistant to vancomycin in drug susceptibility testing. Eventually, the peritonitis was controlled with meropenem and the patient discharged from the hospital.

Conclusion: Here, we describe the first case of CAPD-related peritonitis caused by *T. inchonensis* in China. Importantly, *T. inchonensis* show resistance to cephalosporins and heterogeneous resistance to vancomycin, guideline-based empiric therapy occasionally fails. Further analyses of similar cases are required to understand the characteristics and formulate appropriate therapy regimen for *T. inchonensis* infections.

Keywords: *Tsukamurella inchonensis*, CAPD-related peritonitis, drug sensitivity test

Introduction

Tsukamurella species are gram-positive, weakly acid-fast bacilli bacterium belonging to the *Actinomycetes* family.¹ *Tsukamurella* can be isolated from soil, arthropods, water, sludge foam and sponges. The organism share many common features with *Corynebacterium*, *Rhodococcus*, *Nocardia* and some nontuberculous *Mycobacteria* species in their morphological and biochemical properties.² Traditional phenotypic methods and commercial kits which could identify most commonly encountered bacterial species in clinical microbiology laboratories, often fail to distinguish *Tsukamurella* from related genera.³ So that molecular methods are required for *Tsukamurella* identification.

As opportunistic pathogens for humans, *Tsukamurella* can spread through clinical instruments and infect immunocompromised patients. The spectra of *Tsukamurella* infections comprise pulmonary infections,^{4–7} cutaneous infections,⁸ bacteremia,^{9–11} meningitis,¹² conjunctivitis¹³ and peritonitis.^{14,15}

Bacterial peritonitis remains a main cause of fatal complications in patients undergoing continuous ambulatory peritoneal dialysis (CAPD). The empiric treatment of bacterial peritonitis should include two types of antibiotics to cover both gram-positive and gram-negative bacteria.¹⁶ However, *T. inchonensis* infection is rare. According to the existing literature reports, *T. inchonensis* shows resistance to cephalosporin and heterogeneous resistance to vancomycin, which is usually an empiric antibiotic regimen for peritonitis.^{17–19} In this article, we provide a case of CAPD-related peritonitis caused by *T. inchonensis*, which is the first report in China.

Case Report

A 34-year-old Chinese male who had received 3 years of continuous ambulatory peritoneal dialysis (CAPD) therapy was admitted to our hospital with complaints of abdominal pain and vomiting. He has been diagnosed as having type 1 diabetes mellitus for 15 years and received conservative treatment, including treatments with insulin injection and antihypertensive drugs. Unfortunately, diabetic nephropathy gradually progressed, and he began receiving CAPD for end-stage renal disease at 31 years old. One month prior to hospitalization, the patient had frequent diarrhea which was relieved by norfloxacin (0.1g, every day, P.O.). One day prior to admission, he developed abdominal pain, vomiting but afebrile, followed by a cloudy peritoneal dialysate on the day of admission.

Laboratory investigation revealed white blood cell count of $6.76 \times 10^3/\text{ul}$, C-reactive protein (CRP) 44.67 mg/L (0–10 mg/L), and procalcitonin 4.96 ng/mL (0–0.5 ng/mL). The peritoneal dialysate was cloudy, and microscopic examination showed a concentration of 5.45×10^3 cells/ul with 87.5% of neutrophils. In addition, gram-positive rods were detected in the peritoneal dialysis fluid cultures, suggesting the development of CAPD-related peritonitis.

Peritonitis remains one of the most serious and life-threatening complications of CAPD. It is closely related to permanent peritoneal membrane damage, as well as to the necessity of catheter removal and conversion to hemodialysis. So, the patient was treated empirically with meropenem (1g, every 12 h, i.p.) to resistant bacterial infection and fluconazole (100mg, every day, P.O.) to prevent fungal infections. According to the International Society of Peritoneal Dialysis (ISPD) guidelines in 2016, the Committee recommended that vancomycin should preferably be administered intermittently (in one exchange every 5–7 days) and not continuously (in every exchange).¹⁶ In our case, the dosage and frequency of vancomycin was also administered empirically and based on clinical experience (2g, i.p. on day 1, day 4, day 9 and day 18). After 5 days of antibiotic treatment, the peritoneal dialysis fluid was clear and the white blood cells count recovered to 67 cells/ul with 6% of neutrophils. On the 18th hospital day, the patient was uneventfully discharged after a full course of antimicrobial therapy.

As described above, the peritoneal dialysate cultures were positive in aerobic bottles of the Bact/Alert 3D system (bioMérieux, France) after 29.2h of incubation. Anaerobic cultures were negative after 5 days of incubation. The specimens from the positive bottles were plated onto Columbia blood plate medium and incubated at 35°C in 5% CO₂ chamber. After 48h of incubation, odourless, yellow-greyish, dry and membrane-like colonies were observed on blood agar (Figure 1A). Gram staining showed straight, gram-positive rods (Figure 1B).

The isolated strain was identified as *Tsukamurella* species by MALDI-TOF MS with a confidence level of 99.9% (Figure 2). Further identification was carried out by 16S rRNA gene sequencing. We performed PCR sequencing for 16S rRNA using the forward primer 27F (5'-AGAGTTTGATCATGGCTCAG-3') and the reverse primer 1492R (5'-

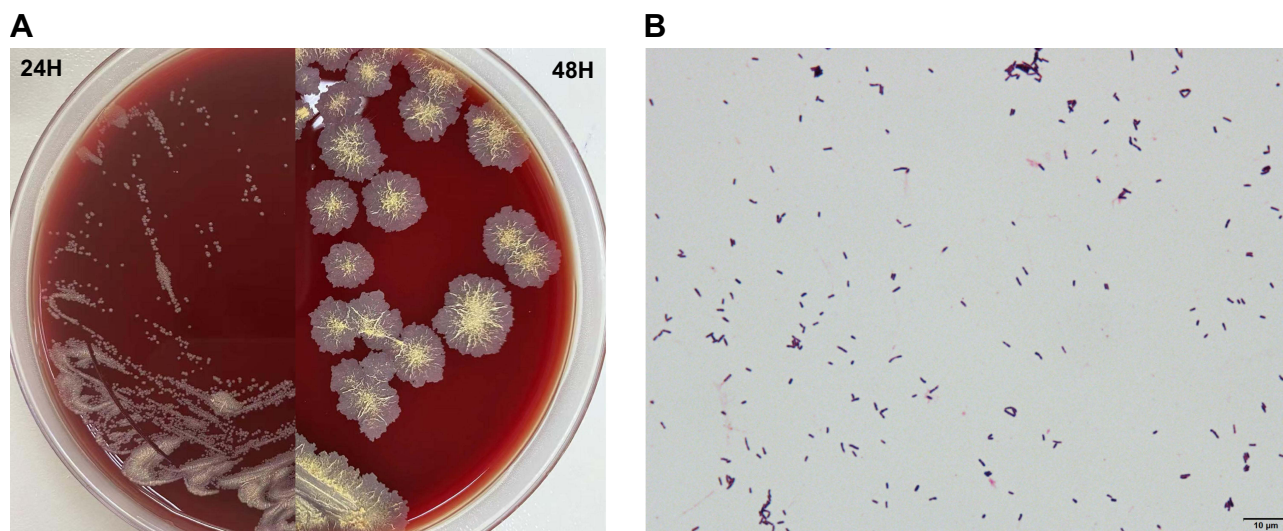


Figure 1 Colonial appearance and gram staining of *T. inchoensis*. (A) Colonial appearance of *T. inchoensis* on a Columbia blood agar plate after 24h and 48h of incubation; (B) Gram staining (bioMérieux, SA) of *T. inchoensis* isolated from peritoneal dialysate cultures ($\times 1000$).

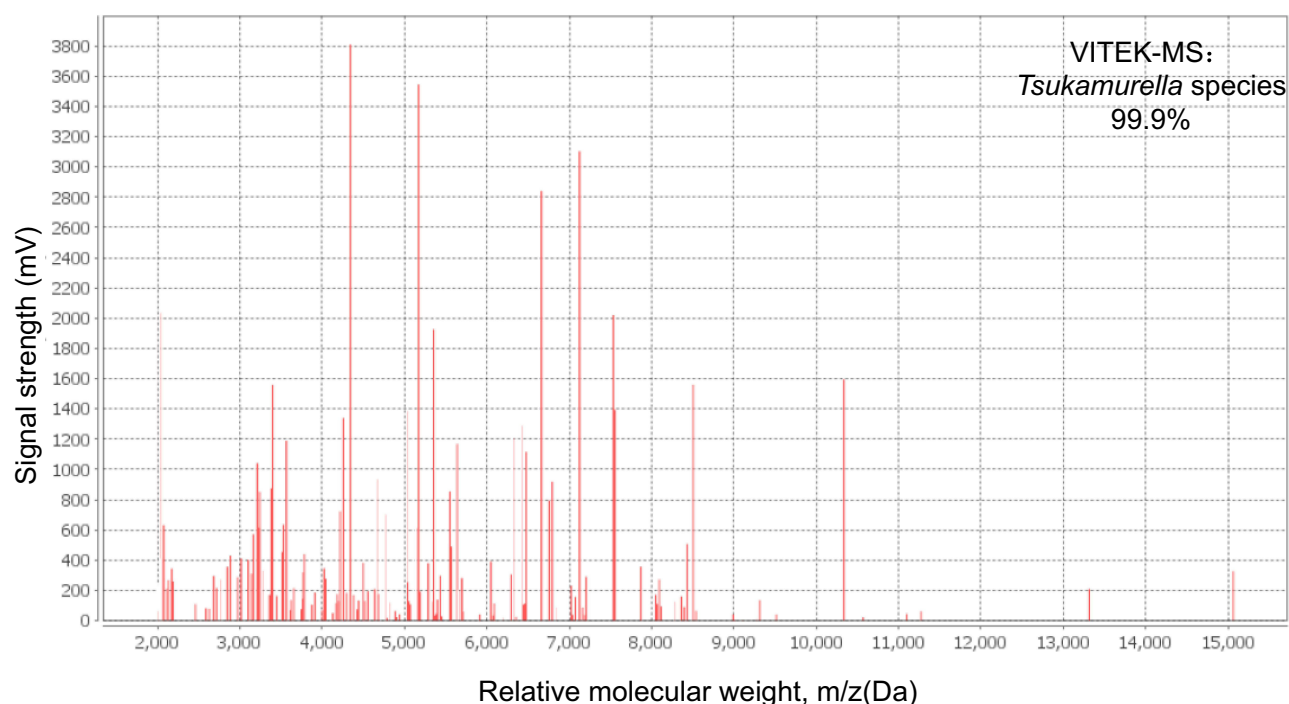


Figure 2 Mass spectra of the bacterial isolate. The isolate strain was identified by VITEK-MS.

TACGGCTACCTTGTACGACTT-3'). The sequence were compared with the 16S rRNA gene sequence of known bacteria in the GenBank database. The concordance rates were as follows: *T. inchonensis* ATCC700082, 100% (1381/1381 bps); *T. inchonensis* G-53 KY949477.1100% (1381/1381 bps). By constructing a phylogenetic tree, we found that the isolate was located in the same branch as *T. inchonensis* (Figure 3). The nucleotide data were registered in the NCBI database with accession numbers of ON004908 (16S ribosomal RNA).

An anti-microbial susceptibility test was performed using dry plate broth microdilution panels. We used cation-adjusted Mueller Hinton Broth and cultured for 24 hours under 35°C ambient condition. Minimum inhibitory concentrations (MICs) of the tested antimicrobials are shown in Table 1. The susceptibilities were interpreted by the criteria established by the Clinical and Laboratory Standards Institute (CLSI), referring to the criteria for *Nocardia* species.²⁰ The strain was sensitive to imipenem, ciprofloxacin, levofloxacin, moxifloxacin and linezolid, but resistant to SXT. However, *T. inchonensis* isolated from our case show intermediate-level resistance to vancomycin and resistance to cephalosporins, which is usually an empiric antibiotic regimen for peritonitis.

Discussion

Tsukamurella is a bacterial genus of dry, yellow-greyish and gram-positive rods that have been cultured from blood, conjunctival swab, lung and other clinical specimens for the last several decades.²¹ This organism is difficult to identify and has been misidentified as *Corynebacterium* and atypical *Mycobacteria*, so that molecular methods are necessary for the accurate identification. MALDI-TOF MS, as a rapid and accurate method for the identification of bacterial and fungal pathogens, has been widely used in clinical microbiology laboratories. In our case, identification of *Tsukamurella* is limited to genus-level using MALDI-TOF MS. Differentiation of *Tsukamurella* from other related genera and species identification within these genera are difficult, as they share similar phenotypic properties. So, 16S rRNA gene sequencing was needed to identify the organism to accurate species-level. However, identification by sequencing is still beyond the reach of many routine clinical laboratories. MALDI-TOF MS, as a cost-effective and user-friendly method, still should be useful for routine species identification of *Tsukamurella* in clinical microbiology laboratories after optimization of the database by adding reference mass spectrum profiles of all the known *Tsukamurella* species.²²

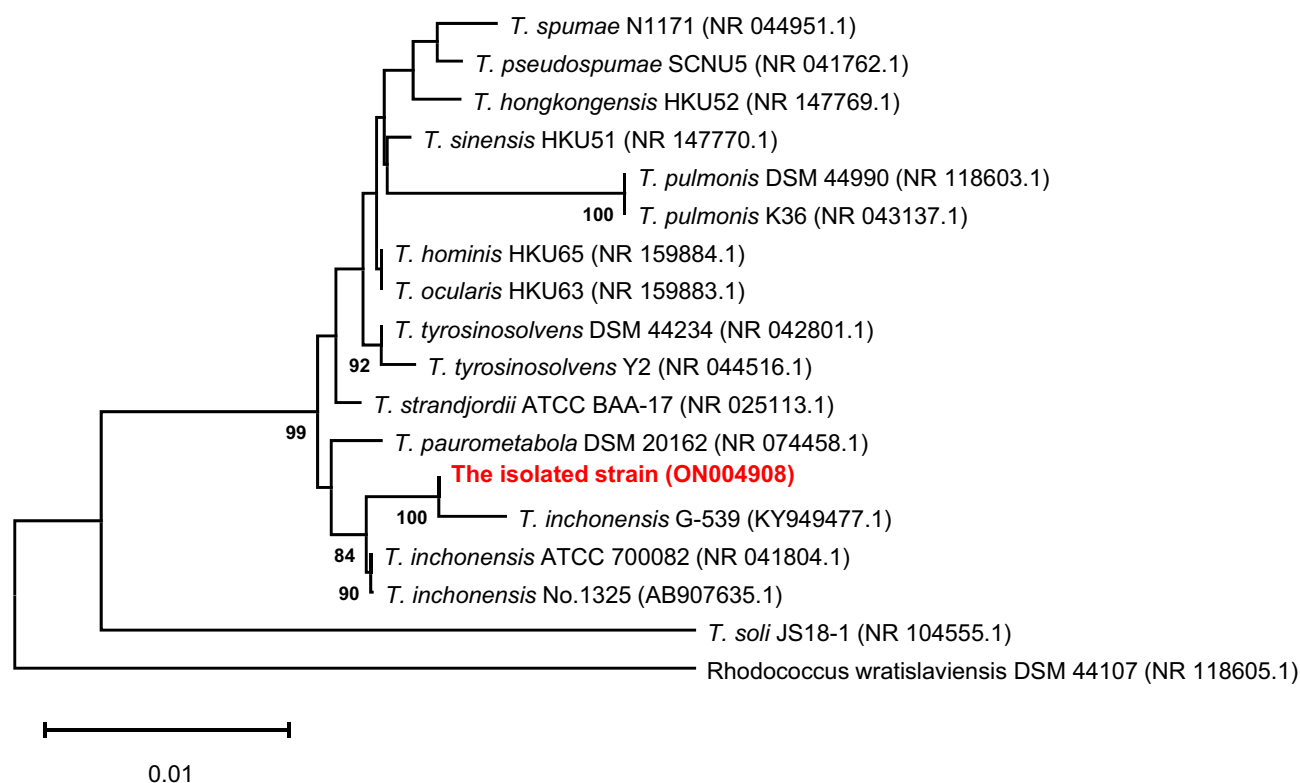


Figure 3 Phylogenetic trees presenting the relationship between the isolated strain with *Tsukamurella* strains. The evolutionary history was inferred using the neighbor-joining method. The isolated strain was marked in red. Evolutionary analyses were conducted in MEGA11.

Tsukamurella infection is not routine and most cases have been reported in immunocompromised patients, malignant tumor patients or patients with indwelling foreign bodies. To date, there are only four previous reports of the *T. inchonensis* infection. The organism was first isolated from bloodstream infection in a South Korea patient who ingested

Table 1 Minimum Inhibitory Concentrations (MIC) of *Tsukamurella inchonensis* Isolated in This Case and Previous Literature

Antimicrobial Agent	MIC Range (mg/L)				
	This Case	Susceptibility ^a	Ref2020 ¹⁸	Ref2014 ¹⁷	Ref1997 ¹⁹
Penicillin	8	NA	–	8	>128
Ampicillin	8	NA	–	16	–
Ampicillin/sulbactam	–	NA	16	–	–
Piperacillin/tazobactam	128/4	NA	32	–	>256
Cefazolin	>16	NA	>16	–	–
Ceftazidime	>16	NA	–	–	>128
Imipenem	≤ 1	S	≤ 1	0.25	0.38
Gentamicin	≤ 0.5	NA	2	–	6
Ciprofloxacin	1	S	1	–	0.19
Levofloxacin	≤ 1	S	0.5	0.5	–
Moxifloxacin	≤ 1	S	–	≤ 0.5	–
Vancomycin	4	I	16	1	–
Linezolid	≤ 1	S	≤ 1	–	–
SXT	>2/38	R	1/19	>4	–

Notes: SXT, trimethoprim/sulfamethoxazole. Broth microdilution MicroScan WalkAway plus System (Beckman Coulter) was applied for the antimicrobial susceptibility testing in our case. ^aThe susceptibilities were interpreted according to the critical developed by the Clinical and Laboratory Standards Institute.

Abbreviations: S, susceptible; R, resistant; NA, not assessed.

hydrochloric acid.¹⁹ Then, a case of catheter-related bloodstream infection by *T. inchonensis* in a Japanese patient after bone marrow transplantation was reported.¹⁷ Additionally, the organism was detected in a 14-year-old Japanese patient with Hodgkin's lymphoma who developed *T. inchonensis* bacteremia, which was associated with the peripherally inserted central venous catheter.²³ *T. inchonensis* bacteremia complicated with septic pulmonary emboli was also reported in a Japanese woman with tongue cancer who underwent peripheral insertion of the central catheter and radiation therapy.¹⁸ To our knowledge, this case is the fifth report globally and the first report of CAPD-related peritonitis caused by *T. inchonensis*.

The rate of gram-positive rod infection has increased over the past few years and it is closely related to repeat and relapsing peritonitis, hospitalization, permanent catheter loss, transfer to hemodialysis and even death, the Committee suggests that it should be treated with proper antibiotics for 3 weeks as in *Staphylococcus aureus* peritonitis based on the 2016 ISPD guidelines.¹⁶ Vancomycin or a first-generation cephalosporin plus a third-generation cephalosporin or an aminoglycoside remains the recommended combination in order to cover for both gram-positive and gram-negative organisms.¹⁶ However, according to previous studies, *Tsukamurella* species are resistant to penicillins and cephalosporins, and possibly susceptible to macrolides, aminoglycosides, fluoroquinolones and carbapenems.²¹ In our report, *T. inchonensis* showed sensitivity to fluoroquinolones and carbapenems and intermediate-level resistance to vancomycin. We successfully treated the patient with meropenem. Additionally, different *Tsukamurella* species present variable antimicrobial susceptibility.²⁴ So, 16S rRNA gene sequencing or MALDI-TOF MS equipped with optimization of the database is needed to identify the organism to accurate species-level.

Conclusion

In conclusion, we described a case of CAPD-related peritonitis caused by *T. inchonensis*, in which the bacteria was identified by 16S rRNA gene sequencing. Importantly, *T. inchonensis* show resistance to cephalosporins and heterogeneous resistance to vancomycin, guideline-based empiric therapy occasionally fails. Further analyses of similar cases are required to understand the characteristics and formulate appropriate therapy regimen for *T. inchonensis* infections.

Ethics Approval and Consent to Participate

This report complies with the guidelines for human studies and is in accordance with the Declaration of Helsinki. All clinical data of the patient were collected in accordance with the Local Research Ethics committee of the First Affiliated Hospital of Anhui Medical University (Quick-PJ 2022-03-21).

Informed Consent for Publication

Written informed consent was obtained from the patient for the publication. The patient provided written informed consent to participate in this study.

Funding

This work was supported by Anhui Provincial Key Research and Development Plan Project (201904a07020049).

Disclosure

The authors have no conflicts of interest to declare in this work.

References

1. Stackebrandt E, Rainey FA, Ward-Rainey NL. Proposal for a new hierarchic classification system, actinobacteria classis nov. *Int J Syst Bacteriol*. 1997;47(2):479–491. doi:10.1099/00207713-47-2-479
2. Kattar MM, Cookson BT, Carlson LC, et al. *Tsukamurella strandjordae* sp. nov., a proposed new species causing sepsis. *J Clin Microbiol*. 2001;39(4):1467. doi:10.1128/JCM.39.4.1467-1476.2001
3. Alcaide ML, Espinoza L, Abbo L. Cavitory pneumonia secondary to *Tsukamurella* in an AIDS patient. First case and a review of the literature. *J Infect*. 2004;49(1):17–19. doi:10.1016/S0163-4453(03)00139-7
4. Chen CH, Lee CT, Chang TC. *Tsukamurella tyrosinosolvens* bacteremia with coinfection of *Mycobacterium bovis* pneumonia: case report and literature review. *Springerplus*. 2016;5(1):2033. doi:10.1186/s40064-016-3707-y

5. Roger M. First case report of community-acquired pneumonia due to *Tsukamurella pulmonis*. *Ann Intern Med*. 2009;150(2):147–148. doi:10.7326/0003-4819-150-2-200901200-00022
6. Ménard A, Khasakhala LI, Kuria MW, et al. *Tsukamurella tyrosinosolvens* - An unusual case report of bacteremic pneumonia after lung transplantation. *Ann Gen Psychiatry*. 2009;8(1):1–5. doi:10.1186/1744-859X-8-1
7. Mehta YB, Simonelli P, Goswami R, et al. *Tsukamurella* infection: a rare cause of community-acquired pneumonia. *Am J Med Sci*. 2011;341(6):500–503. doi:10.1097/MAJ.0b013e3182129d02
8. Granel F, Lozniewski A, Barbaud A, et al. Cutaneous infection caused by *Tsukamurella paurometabolum*. *Clin Infect Dis*. 1996;4:839.
9. Elshibly S, Doherty J, Xu J, et al. Central line-related bacteraemia due to *Tsukamurella tyrosinosolvens* in a haematology patient. *Ulst Med J*. 2005;74(1):43–46.
10. Schwartz MA, Tabet SR, Collier AC, et al. Central venous catheter-related bacteremia due to *Tsukamurella* species in the immunocompromised host: a case series and review of the literature. *Clin Infect Dis*. 2002;35(7):908.
11. Shapiro CL, Haft RF, Gantz NM, et al. *Tsukamurella paurometabolum*: a novel pathogen causing catheter-related bacteremia in patients with cancer. *Clin Infect Dis*. 1992;14(1):200–203. doi:10.1093/clinids/14.1.200
12. Prinz G, Bán E, Fekete S, et al. Meningitis caused by *Gordona aurantiaca* (*Rhodococcus aurantiacus*). *J Clin Microbiol*. 1985;22(3):472–474. doi:10.1128/jcm.22.3.472-474.1985
13. Kechker P, Senderovich Y, Ken-Dror S, et al. *Tsukamurella pulmonis* conjunctivitis in patients with an underlying nasolacrimal duct obstruction - report of two cases. *Access Microbiol*. 2021;3(2):000185. doi:10.1099/acmi.0.000185
14. Shaer AJ, Gadegbeku CA. *Tsukamurella* peritonitis associated with continuous ambulatory peritoneal dialysis. *Clin Nephrol*. 2001;56(3):241–246.
15. Ismayilov R, Duran ZC, Hazirolan G, et al. *Tsukamurella paurometabola* peritonitis in a patient on automated peritoneal dialysis. *Enferm Infecc Microbiol Clin*. 2021;39(8):422. doi:10.1016/j.eimc.2020.10.010
16. Liakopoulos V, Nikitidou O, Kalathas T, et al. Peritoneal dialysis-related infections recommendations: 2016 update. What is new? *Int Urol Nephrol*. 2017;49(12):2177–2184. doi:10.1007/s11255-017-1632-9
17. Takebe I, Sawabe E, Ohkusu K, et al. Catheter-related bloodstream infection by *Tsukamurella inchoensis* in an immunocompromised patient. *J Clin Microbiol*. 2014;52(6):2251–2253. doi:10.1128/JCM.00421-14
18. Gotoh K, Mayura IPB, Hagiya H, et al. Septic pulmonary emboli caused by *Tsukamurella inchoensis*: a case report. *J Infect Chemother*. 2020;27(2):369–372. doi:10.1016/j.jiac.2020.09.024
19. Chong Y, Lee K, Chon CY, et al. *Tsukamurella inchoensis* bacteremia in a patient who ingested Hydrochloric acid. *Clin Infect Dis*. 1997;24(6):1267–1268. doi:10.1093/clinids/24.6.1267
20. Woods G, Lin SY, Desmond EP. Susceptibility testing of *Mycobacteria*, *Nocardiae*, and other aerobic actinomycetes. Approved Standard M24-A2. *Man Clin Microbiol*. 2011;31:1356–1378.
21. Safaei S, Fatahi-Bafghi M, Pouresmaeil O. Role of *Tsukamurella* species in human infections: the first literature review. *New Microbes New Infect*. 2018;22(C):6–12. doi:10.1016/j.nmni.2017.10.002
22. Teng JLL, Tang Y, Wong SSY, et al. MALDI-TOF MS for identification of *Tsukamurella* species: *Tsukamurella tyrosinosolvens* as the predominant species associated with ocular infections. *Emerg Microbes Infect*. 2018;7(1):80. doi:10.1038/s41426-018-0083-4
23. Ochi F, Tauchi H, Moritani K, et al. *Tsukamurella inchoensis* infection in a child with Hodgkin's lymphoma. *Pediatr Int*. 2015;57(1):e7–e10. doi:10.1111/ped.12472
24. Liu CY, Lai C-C, Lee M-R, et al. Clinical characteristics of infections caused by *Tsukamurella* spp. and antimicrobial susceptibilities of the isolates. *Int J Antimicrob Agents*. 2011;38(6):534–537. doi:10.1016/j.ijantimicag.2011.07.018

Infection and Drug Resistance

Dovepress

Publish your work in this journal

Infection and Drug Resistance is an international, peer-reviewed open-access journal that focuses on the optimal treatment of infection (bacterial, fungal and viral) and the development and institution of preventive strategies to minimize the development and spread of resistance. The journal is specifically concerned with the epidemiology of antibiotic resistance and the mechanisms of resistance development and diffusion in both hospitals and the community. The manuscript management system is completely online and includes a very quick and fair peer-review system, which is all easy to use. Visit <http://www.dovepress.com/testimonials.php> to read real quotes from published authors.

Submit your manuscript here: <https://www.dovepress.com/infection-and-drug-resistance-journal>