


A Retrospective Study of Clinical Efficacy of Cantharidin Cream for Verruca Plantaris

Xuelin Wu^{1,2}, Yanqing Hu^{1,2}, Yan Lu^{1,2}, Xiuling Ke^{1,2}, Kangxing Liu^{1,2}, Xianyi Zhou^{1,2}, Yongxuan Hu^{1,2} 

¹Department of Dermatology and Venereology, The Third Affiliated Hospital of Southern Medical University, Guangzhou, People's Republic of China;

²Guangdong Provincial Key Laboratory of Bone and Joint Degeneration Diseases, Guangzhou, People's Republic of China

Correspondence: Xianyi Zhou; Yongxuan Hu, Department of Dermatology and Venereology, The Third Affiliated Hospital of Southern Medical University, 183 West Zhongshan Road, Guangzhou, People's Republic of China, Tel/Fax + 86 20 62784561; + 86 20 62784560, Email zxy1962@163.com; huyongxuan2003@163.com

Abstract: Verruca plantaris (plantar wart) is a type of benign feet hyperplasia that is caused by a human papillomavirus (HPV) infection. In this study, we aimed to assess the clinical efficacy underlying cantharidin cream in the treatment of Verruca plantaris compared to CO₂ laser and liquid nitrogen cryotherapy. One hundred and fifty patients affected with Verruca plantaris were enrolled in this retrospective clinical study. The treatment efficacy rate in the three groups was assessed 4 and 12 weeks after treatment. After 4 weeks of treatment, 46 cases in the externally applied cantharidin cream therapy group were cured with an apparent efficiency of 92.0% (46/50). Contrarily, 42 cases in the CO₂ laser group were cured with 84.0% (42/50) efficiency, while 40 cases in the liquid nitrogen cryotherapy group were cured with an apparent efficiency of 80.0% (40/50). Although the clinical cure rate of Verruca plantaris in the Cantharidin group was greater than in the CO₂ laser group and in the liquid nitrogen cryotherapy group, there were no statistical differences found among the three groups ($P = 0.225$). After 12 weeks of treatment, 43 cases in the external cantharidin cream therapy group were cured with an apparent efficiency of 86.0% (43/50). Similarly, 39 cases in the CO₂ laser group were cured with an apparent efficiency of 78.0% (39/50), while 36 cases in the liquid nitrogen cryotherapy group were cured with an apparent efficiency of 72.0% (36/50). The statistical differences among the three groups were not found ($P = 0.230$), but the resolution rate of warts in Cantharidin group was the highest among the three groups. The results from this study demonstrated that external cantharidin cream therapy could be served as an alternative treatment for Verruca plantaris.

Keywords: cantharidin, HPV, verruca plantaris, plantar wart

Introduction

Verruca plantaris (plantar wart) is a type of benign epithelial hyperplasia that is caused by a human papillomavirus (HPV) infection, and affects 7% to 10% of the global population. Plantar warts are characterized by the benign proliferation of epithelial cells on the feet and are typically caused by infection with HPV type 1.¹ Asymptomatic infection with HPV occurs frequently, however most infections are controlled or cleared by cellular and humoral immune responses. Certain patient populations manifest plantar warts at a higher rate and hence require a more active treatment plan.² There are several clinical treatments available for Verruca plantaris such as microwave therapy, CO₂ laser therapy, liquid nitrogen phytotherapy, surgical excision, photodynamic therapy, *Candida albicans* immunotherapy, podophyllotoxin, and salicylic acid therapy.^{3,4} However, the side effects associated with the treatment plan for disease recurrence prevention are not ideal.⁵

Cantharidin, a blister agent produced by beetles of the *Meloidae coleoptera* family.³ It was used medicinally for the past 2000 years, and used to treat warts since the 1950s.⁶ In recent years, it has been used in the treatment of condyloma acuminatum.⁷ There are few clinical studies about Cantharidin cream for the treatment of Verruca plantaris. We used external applications of 0.025% cantharidin cream in this study to treat 50 patients with Verruca plantaris. Patients treated with CO₂ laser or liquid nitrogen cryotherapy were served as two control groups (50 patients per group). The clinical efficacy of each treatment group was explored 4 and 12 weeks posttreatment.

Materials and Methods

Fifty patients with Verruca plantaris, previously diagnosed by the Department of Dermatology and Venereology, The 3rd Affiliated Hospital of Southern Medical University from 2019 to 2021, were randomly assigned to the cantharidin cream treatment group. The disease course in the patients ranged from 1 to 48 months. The patients in the cantharidin treatment group were treated with 0.025% cantharidin cream (Hainan Huiyuantang Pharmaceutical co. LTD, China), and the treatment methods were performed according to the manufacturer's instructions. The curative treatment was external cantharidin cream for skin lesions applied once daily for plastic wrap 8 h. The total treatment course was 3–4 weeks.

Fifty patients with Verruca plantaris were randomly assigned to the CO₂ laser treatment group. The disease course in the patients ranged from 1 to 32 months. The patients were treated with CO₂ laser once.

Similarly, 50 patients with Verruca plantaris were randomly assigned to the liquid nitrogen cryotherapy group. The disease course in the patients ranged from 1 to 36 months. The patients in this group were treated using liquid nitrogen cryotherapy once. All the patients were asked to avoid water contact on the treatment areas during the first week of treatment. All the patients had follow-ups at 4 and 12 weeks.

Baseline demographic characteristics of factors (Age, sex, number of lesions) showed no statistical differences among the three groups ($P>0.05$) (Table 1).

Statistical analysis was performed using SPSS 26.0 at a two-sided significant level of $P<0.05$. Chi-Squared test was used to compare the clinical cure rate among three groups.

Results

One hundred and fifty patients with Verruca plantaris were treated in this study. The therapeutic evaluation was based on the clinical outcome of patients assessed before treatment and after 4 and 12 weeks of follow-up (Figure 1). After 4 weeks of treatment, 46 patients (92%) treated with cantharidin cream were clinically cured and exhibited no recurrence of disease. In contrast, 42 patients (84%) in the CO₂ laser treatment group and 40 patients (80%) in the liquid nitrogen cryotherapy treatment group were clinically cured and exhibited no recurrence, respectively (Table 1). Although there were no statistically significant differences in the clinical efficacy rate among the three groups ($P = 0.225$), the clinical cure rate was highest in the Cantharidin therapy group as compared to the other two treatment groups.

During the 12-week follow-up, 43 patients (86%) treated with cantharidin cream were clinically cured and exhibited no recurrence. Similarly, 39 patients (78%) in the CO₂ laser treatment group and 36 patients (72%) in the liquid nitrogen cryotherapy treatment group were clinically cured and exhibited no recurrence, respectively (Table 2). Although the differences in the clinical efficacy rate among the three groups were not statistically significant ($P = 0.230$), the clinical outcome of Cantharidin group was greater than CO₂ laser therapy group and liquid nitrogen cryotherapy group.

During the course of the cantharidin cream treatment, five patients presented with erythema, edema, and erosion to different degrees, while 20 patients presented with varying levels of pain. Five of these patients received analgesics once

Table 1 Four-Week Follow-Up to Assess Clinical Efficacy of Verrucae Plantaris Treatment

Group	Number	Sex		Mean Age (Years)	Number of Warts		Outcome (Follow-up After 4 Weeks)			P-value
		M	F		Single	Multiple	Clinically Cured	Clinical Recurrence	Clinical Efficiency (%)	
Cantharidin treatment	50	28	22	34.02±16.01	20	30	46	4	92.0	0.225 (>0.05)
CO ₂ laser treatment	50	30	20	33.25±8.00	30	20	42	8	84.0	
Liquid nitrogen cryotherapy	50	25	25	35.13±15.12	21	29	40	10	80.0	

Abbreviations: M, male; F, female.

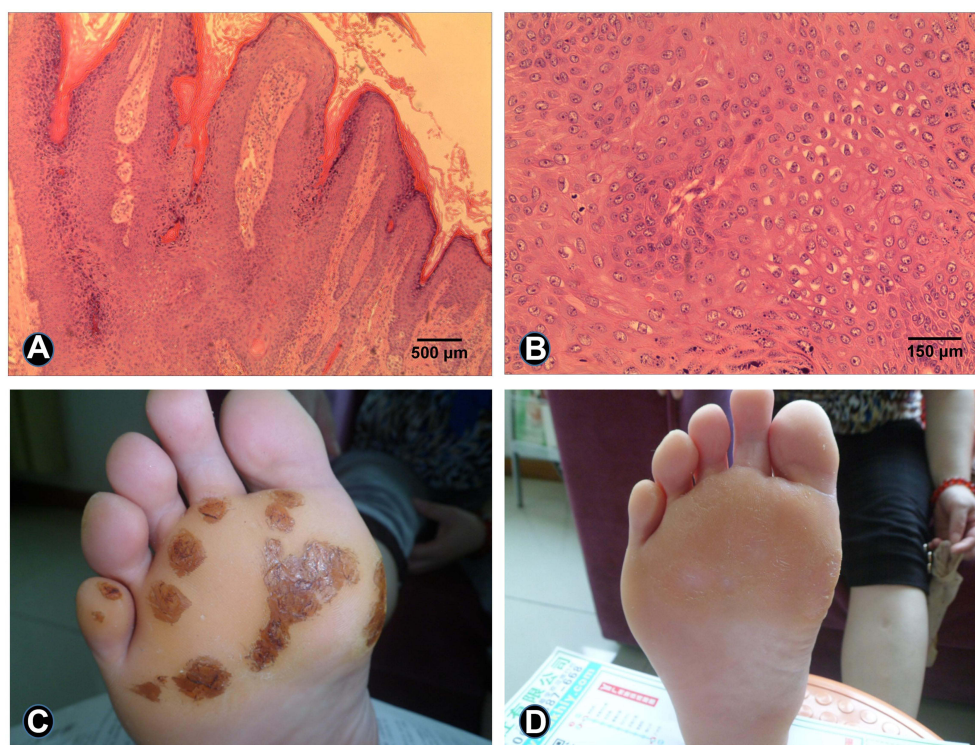


Figure 1 Histopathology examination before and after treatment with cantharidin cream in patients with Verruca plantaris. Patients with Verruca plantaris completed 4 weeks of treatment. (A) The histopathological examination demonstrated parakeratosis and papillomatous hyperplasia of the epidermis (hematoxylin-eosin stain, magnification 100×). (B) The histopathological examination revealed a large number of vacuolated cells in the epidermis (hematoxylin-eosin stain, magnification 400×). (C) Several neoplasms detected on the foot prior to the treatment. (D) The foot lesions were eliminated post treatment.

or twice. All the adverse reactions were resolved within 6 days upon external application of polymyxin B ointment. No serious adverse reactions were observed, and none of the treatments had to be discontinued.

Discussion

Verruca plantaris is a type of benign foot lesion typically caused by an infection with HPV type 1.¹ Recurrence is one of the characteristics of this disease, and is prominently observed in certain populations.² Though most HPV infections are resolved by cellular and humoral immune responses, asymptomatic infection with HPV is commonly observed in our environment.² Some clinicians focus on patients belonging to the high recurrence rate population.

Table 2 Twelve-Week Follow-Up to Assess Clinical Efficacy of Verruca Plantaris Treatment

Group	Number	Sex		Mean Age (Years)	Number of Warts		Outcome (Follow-up After 4 Weeks)			P-value
		M	F		Single	Multiple	Clinically Cured	Clinical Recurrence	Clinical Efficiency (%)	
Cantharidin treatment	50	28	22	34.02±16.01	20	30	43	7	86.0	0.230 (>0.05)
CO ₂ laser treatment	50	30	20	33.25±8.00	30	20	39	11	78.0	
Liquid nitrogen cryotherapy	50	25	25	35.13±15.12	21	29	36	14	72.0	

Abbreviations: M, male; F, female.

Cantharidin, which is absorbed by lipids in keratinocytes, activates serine proteases and leads to acantholysis.⁶ It has been used in the alternative treatment of genital warts in recent years.⁷ As an alternative treatment, Cantharidin also was used for viral infectious diseases such as verruca vulgaris, verruca plantaris and molluscum contagiosum.^{1,8,9} In terms of treatment costs and efficacy, CO₂ laser therapy is expensive and often used on recalcitrant warts. Liquid nitrogen cryotherapy is safe and cost-effective, but postoperative pain may disturb patients. Cantharidin's cost is between the above two therapy with no application pain and less scarring.²

In this study, cantharidin cream was applied for the treatment of Verruca plantaris and clinical efficacy was assessed during 4 and 12 weeks of follow-up. The results demonstrated that although the therapeutic effectiveness of cantharidin cream was not superior to CO₂ laser and liquid nitrogen cryotherapy in treating Verruca plantaris, considering the acceptable price and no application pain as well as less scarring of cantharidin, it could be a proper alternative. A limitation of this study is that a small number of cases were assessed. Additionally, the possible mechanism of action of cantharidin was not simultaneously studied.

Ethics Statement

The study was approved by the Ethics Committee of the Third Affiliated Hospital of Southern Medical University. All subjects were adults and provided written informed consent. This study was conducted in accordance with the Declaration of Helsinki.

Acknowledgments

This work was supported by grants from the Scientific Research Project of Traditional Chinese Medicine Bureau of Guangdong Provincial (grant no-20212147).

Author Contributions

All authors made substantial contributions to conception and design, acquisition of data, or analysis and interpretation of data; took part in drafting the article or revising it critically for important intellectual content; agreed to submit to the current journal; gave final approval of the version to be published; and agree to be accountable for all aspects of the work.

Disclosure

The authors have no conflicts of interest to declare.

References

1. Hood CR Jr, Miller JR. The ring verruca plantaris in cantharidin use (A case report). *J Am Podiatr Med Assoc.* 2018;108(2):189–193. doi:10.7547/16-115
2. Witchev DJ, Witchev NB, Roth-Kauffman MM, et al. Plantar warts: epidemiology, pathophysiology, and clinical management. *J Am Osteopath Assoc.* 2018;118(2):92–105. doi:10.7556/jaoa.2018.024
3. López-López D, Agrasar-Cruz C, Bautista-Casasnovas A, et al. Aplicación de cantaridina-podofilotoxina-ácido salicílico en las verrugas plantares recalcitrantes. Un estudio preliminar [Application of cantharidin, podophyllotoxin, and salicylic acid in recalcitrant plantar warts. A preliminary study]. *Gac Med Mex.* 2015;151(1):14–19. Spanish.
4. López-López D, Vilar-Fernández JM, Losa-Iglesias ME, et al. Safety and effectiveness of cantharidin-podophyllotoxin-salicylic acid in the treatment of recalcitrant plantar warts. *Dermatol Ther.* 2016;29(4):269–273. doi:10.1111/dth.12356
5. Vlahovic TC, Khan MT. The human papillomavirus and its role in plantar warts: a comprehensive review of diagnosis and management. *Clin Podiatr Med Surg.* 2016;33(3):337–353. doi:10.1016/j.cpm.2016.02.003
6. Recanatì MA, Kramer KJ, Maggio JJ, et al. Cantharidin is superior to trichloroacetic acid for the treatment of non-mucosal genital warts: a pilot randomized controlled trial. *Clin Exp Obstet Gynecol.* 2018;45(3):383–386. doi:10.12891/ceog4112.2018
7. Ruini C, Clanner-Engelshofen BM, Heppt M, et al. Cantharidin as an alternative treatment for genital warts: a case monitored with optical coherence tomography. *Acta Derm Venereol.* 2020;100(16):adv00259. doi:10.2340/00015555-3623
8. Robson KJ, Cunningham NM, Kruzan KL, et al. Pulsed-dye laser versus conventional therapy in the treatment of warts: a prospective randomized trial. *J Am Acad Dermatol.* 2000;43(2 Pt 1):275–280. doi:10.1067/mjd.2000.106365
9. Cotton CH. Pediatric Game Changers*: cantharidin for treatment of facial molluscum contagiosum: a retrospective review. *J Am Acad Dermatol.* 2021;84(6):1800. doi:10.1016/j.jaad.2021.02.015

Infection and Drug Resistance

Dovepress

Publish your work in this journal

Infection and Drug Resistance is an international, peer-reviewed open-access journal that focuses on the optimal treatment of infection (bacterial, fungal and viral) and the development and institution of preventive strategies to minimize the development and spread of resistance. The journal is specifically concerned with the epidemiology of antibiotic resistance and the mechanisms of resistance development and diffusion in both hospitals and the community. The manuscript management system is completely online and includes a very quick and fair peer-review system, which is all easy to use. Visit <http://www.dovepress.com/testimonials.php> to read real quotes from published authors.

Submit your manuscript here: <https://www.dovepress.com/infection-and-drug-resistance-journal>