

# *Pneumocystis jirovecii* and *Mycobacterium tuberculosis* Pulmonary Coinfection in an HIV-Seronegative Patient: A Case Report and Literature Review

Shanchen Wei , Lianjun Lin

Geriatric Department, Peking University First Hospital, Beijing, 100034, People's Republic of China

Correspondence: Lianjun Lin, Geriatric Department, Peking University First Hospital, Xicheng District, Beijing, 100034, People's Republic of China, Email 13671246076@126.com

**Background:** Coinfection with *Pneumocystis jirovecii* and *Mycobacterium tuberculosis* is rare in HIV-seronegative patients. Because it is associated with unknown morbidity and a high mortality rate especially in patients with immunosuppression, health care practitioners should have a high index of suspicion when dealing with such patients.

**Case Presentation:** A 66-year-old man with glucocorticoid therapy for 9 years had a fever after getting a cold and developed respiratory failure rapidly within 3 days. He was given trimethoprim-sulfamethoxazole empirically before *Pneumocystis* pneumonia (PCP) was confirmed with the presence of cysts in the sputum. Although there was a partial improvement of symptoms, an area of consolidation on the left upper lung lobe gradually enlarged. Bronchoscopy was performed 3 times and *Mycobacterium tuberculosis* infection was finally diagnosed. For 1 years, he was treated with standard antituberculosis agents, and his psychological well-being was managed using traditional Chinese medicine techniques. After 3 years of follow-up, his outcome was very good.

**Conclusion:** HIV-seronegative patients on long-term glucocorticoid therapy in areas with a high incidence of *Mycobacterium tuberculosis* may be co-infected with *Pneumocystis jirovecii*. When opportunistic infections are suspected, diagnostic procedures including invasive ones should be performed as soon as possible and appropriate interventions need to be carried out promptly.

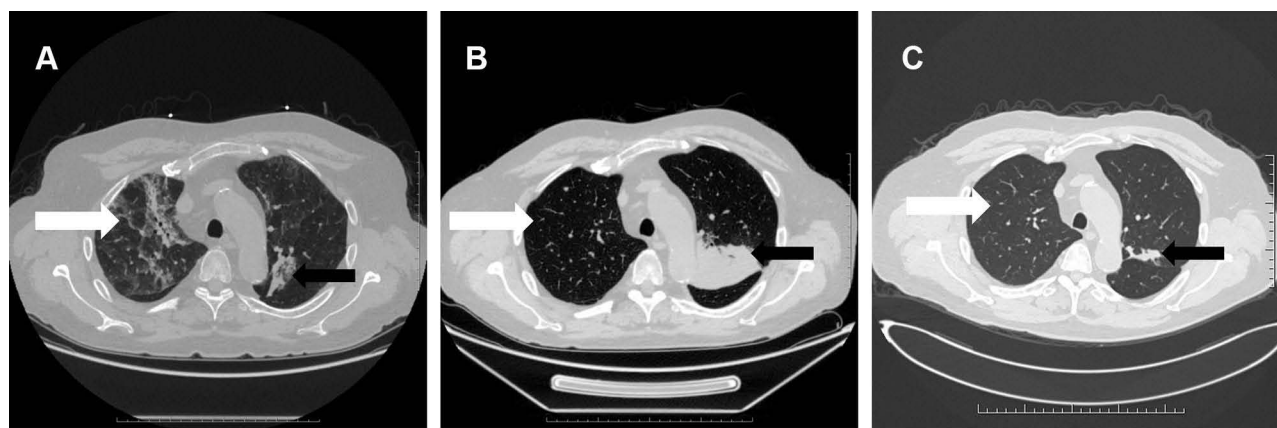
**Keywords:** *Mycobacterium tuberculosis*, *Pneumocystis jirovecii*, PCP, HIV-seronegative, Immunosuppressed, corticosteroids

## Background

*Pneumocystis jirovecii* and *Mycobacterium tuberculosis* are common opportunistic pulmonary pathogens in patients infected with human immunodeficiency virus (HIV). However, co-infection is extremely rare in HIV-seronegative patients,<sup>1</sup> while once occurred, it is severe and has a higher mortality rate.<sup>2</sup> Early diagnosis is difficult and delays in antibiotic treatment are more common in HIV-negative patients, which may lead to a poor prognosis.<sup>3,4</sup> Currently, there are no accurate diagnostic tools, so being aware of the possibility of coinfection and rapidly performing diagnostic procedures that may include invasive ones are key to improving clinical outcomes.

## Case Presentation

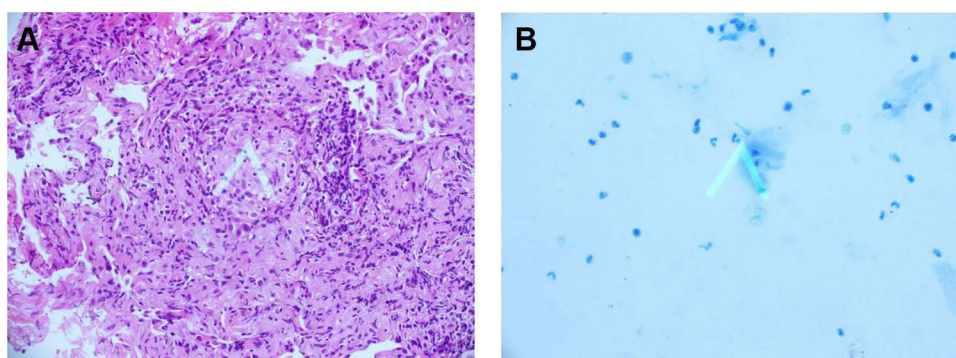
A 66-year-old man presented and was admitted to the hospital with fever for 3 days and dyspnea for 1 day. The patient had been diagnosed with malignant pemphigus vulgaris and put on prednisolone, methylprednisolone and other immunosuppressive drugs for the past 9 years. On admission, he experienced respiratory failure. The absolute count of regulatory T lymphocytes was 156.67 cells/uL. The lactate dehydrogenase increased to 457 IU/L. The chest computed tomography (CT) scan revealed multiple flaky, fuzzy, and high-density opacities in both lungs (Figure 1A). The patient had been on steroids for a long time. He had obvious hypoxia and had never had any other respiratory symptoms or other infections. On respiratory examination, the patient did not have many rales in the lungs. The lung CT scan showed interstitial changes. PCP, usually treated with sulfonamides, was considered a possible etiology because of his



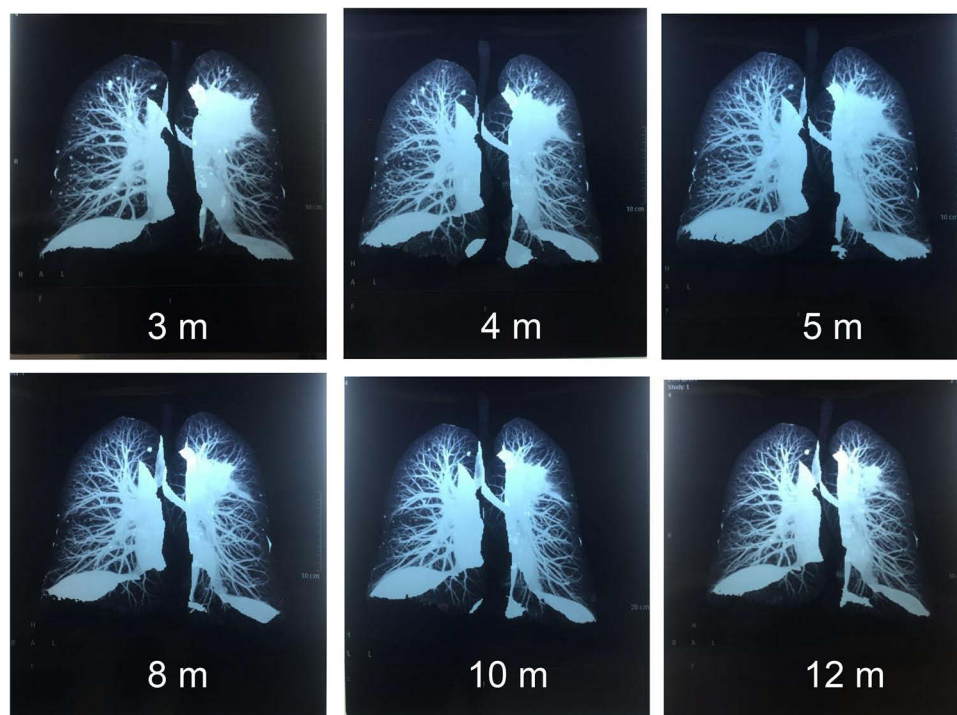
**Figure 1** A chest CT scan of the 66-year-old man showing *Pneumocystis jirovecii* Pneumonia and *Mycobacterium tuberculosis* Infection. **(A)** A transverse chest CT scan obtained on the first day after admission showed multiple ground-glass opacities in both lungs (white arrow), and an area of consolidation in the left upper lung lobe (black arrow). **(B)** A follow-up chest CT scan obtained 1 month after admission showed the ground-glass opacities in both lungs were reduced (white arrow), but the left upper lobe consolidation was enlarged (black arrow). **(C)** A follow-up chest CT scan obtained on month 41 after initial admission showed gradual absorption of the ground glass opacities in both lungs (white arrow), a decrease in the left upper lobe consolidation, and a gradual disappearance of the multiple lung nodules (black arrow).

immunocompromised state. Caspofungin is a good treatment of choice for *Aspergillus* infection, which could not be excluded. For other atypical pathogens, moxifloxacin should be added. Thus he was given trimethoprim-sulfamethoxazole (3 tablets, twice daily for 3 weeks), caspofungin (loading dose, 70mg infused over 1 hour; maintenance dose, 50 mg daily infused over 1 hour for 2 weeks), steroids, and moxifloxacin. Consequently, his respiratory function improved, and his body temperature dropped. PCP was confirmed 4 days later when cysts were found in the sputum ([Supplementary Material](#)).

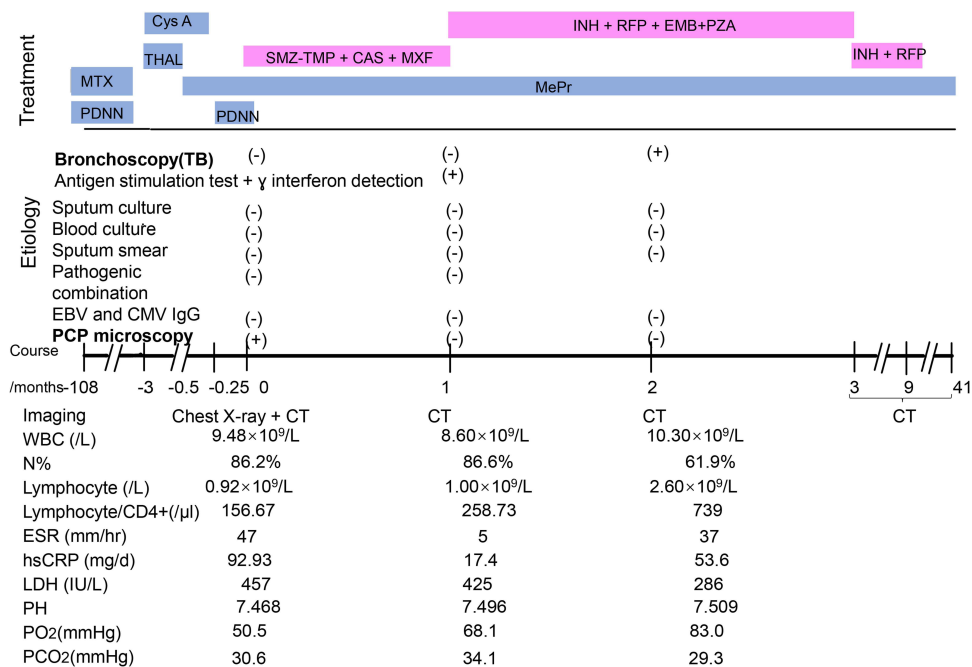
Curiously, the follow-up chest CT suggested an enlarged consolidation in the left upper lobe ([Figure 1A–C](#)). The patient was admitted to the hospital again due to cough, expectoration, and intermittent fever. Bronchoscopy was performed for 3 times. Smears and culture of the bronchial brush, tracheal secretions, and bronchoalveolar lavage fluid (BALF) were performed. Lung tissue was taken for culture and pathological examination, and tuberculosis was diagnosed ([Figure 2](#)). Antituberculosis treatment (isoniazid 300 mg once daily, rifapentine 600 mg twice weekly, ethambutol 750 mg once daily, and pyrazinamide 500 mg thrice daily) was given for 2 months and later ethambutol and pyrazinamide were excluded. Antituberculosis treatment lasted for 1 year. Simultaneously, traditional Chinese medicine techniques were used to manage the patient's psychological well-being and improve mental state. After 3 years of follow-up, the clinical outcome was good ([Figure 3](#)). The patient's complete course is shown in [Figure 4](#).



**Figure 2** Pathological examination of bronchoscopy samples. **(A)** Pathological examination of bronchoscopy samples obtained on month 2 after the first admission showed a wide alveolar cavity, fibrous proliferation, collagenization, lymphocyte infiltration, and carbon dust deposition. The formation of small focal granulomas can be seen, with inflammatory necrosis and small abscesses in the center (white arrow). The lesion was consistent with tuberculosis. **(B)** A smear of secretions: acid-fast bacillus was found, +, the shape suggested *M. tuberculosis* (white arrow).



**Figure 3** Three-dimensional CT Reconstruction of the Lungs. The consolidation in the left upper lung lobe and the multiple lung nodules gradually disappeared. CT was obtained on month 3 after the first admission. m, months.



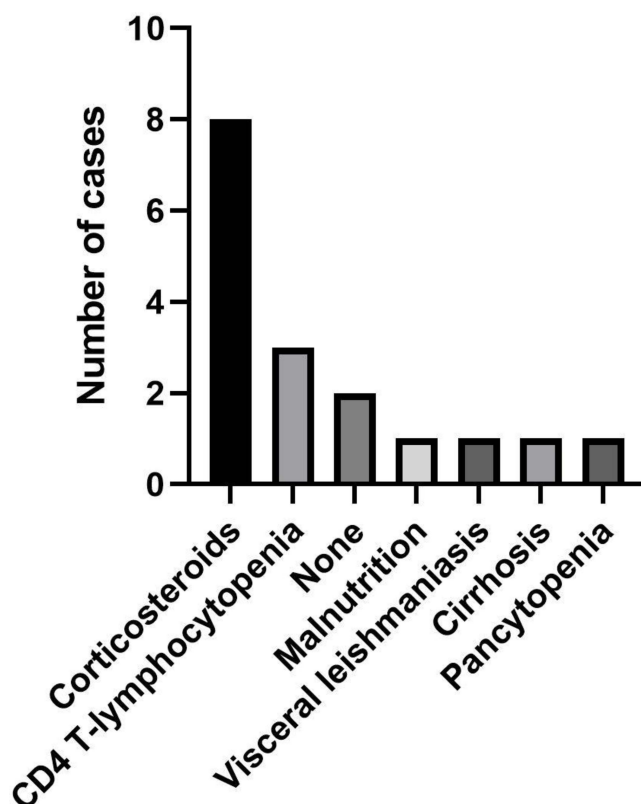
**Figure 4** Timeline of diagnostic testing, imaging, and procedures. For treatment, each bar indicates the time between starting and ending.

**Abbreviations:** MTX, methotrexate; PDNN, prednisolone; Cys A, cyclosporin A; THAL, thalidomide; MePr, methylprednisolone; SMZ-TMP, sulfamethoxazole-trimethoprim; Cas, caspofungin; INH, isoniazid; RFP, rifapentine; EMB, ethambutol; PZA, pyrazinamide; MXF, moxifloxacin; EBV, Epstein-Barr virus; CMV, cytomegalovirus; PCP, *Pneumocystis jirovecii* pneumonia; CT, computed tomography; WBC, white blood cell; N%, neutrophilic granulocyte percentage; ESR, erythrocyte sedimentation rate; hsCRP, high-sensitivity C-reactive protein; LDH, lactate dehydrogenase; PH, potential of hydrogen; PO<sub>2</sub>, partial pressure of oxygen; PCO<sub>2</sub>, partial pressure of carbon dioxide.

## Discussion and Conclusion

We performed a PubMed literature review of HIV-seronegative patients with PCP and tuberculosis (TB) coinfection using the keywords “tuberculosis” and “pneumocystis pneumonia”. From 2000 to 2021, a total of 17 cases including our case were reported. We divided these 17 reported cases based on the cause of the disease into the following categories: steroid therapy (alone or with chemotherapy) (8 cases), CD4+ lymphocytopenia (3 cases), malnutrition (1 case), visceral leishmaniasis (1 case), alcohol-related cirrhosis (1 case), and pancytopenia (1 case). There were 2 cases with no obvious cause (Figure 5). Based on these categories, steroid therapy appears to be the major predisposing factor for PCP and TB coinfection.

Glucocorticoids have a variety of anti-inflammatory and immunosuppressive effects on virtually all immune cells, and their exact effects depend on the state of cell differentiation and activation.<sup>5</sup> Glucocorticoid use increases the risk of new infections and reactivation of chronic infections, which influences the vaccines that are recommended.<sup>6</sup> Observational studies from the “real world” consistently show a dose-dependent increase in the risk of severe infections and opportunistic infections such as TB and PCP.<sup>7</sup> A Mayo Clinic study of 116 patients with PCP (without HIV) from 1985 to 1991 found that 105 patients (91%) received corticosteroids for multiple indications within 1 month of a PCP diagnosis. They had a median prednisone equivalent (PEQ) dose of 30 mg/day.<sup>8</sup> In a case-control study, the adjusted odds ratio of TB was 2.8 (95% confidence interval [CI], 1.0–7.9) for less than a 15 mg daily dose of prednisone and 7.7 (95% CI, 2.8–21.4) for more than a 15 mg daily dose of prednisone.<sup>9</sup> Vaccination and screening strategies should be used to mitigate this risk in patients who are starting chronic steroid therapy.<sup>6</sup> Trimethoprim-sulfamethoxazole is an effective PCP prophylactic agent with a low risk of adverse effects.<sup>7</sup> The tuberculin skin test (TST) or the interferon-gamma release assay (IGRA) can be used to screen and identify patients at a higher risk of active TB and treat them appropriately.<sup>10,11</sup>



**Figure 5** Distribution of predisposing factors for TB and PCP coinfection in cases reported in literature.

In our case, we suspected that the patient had PCP and treated them accordingly before we received the sputum results. Bronchoscopy was done to diagnose TB because other non-invasive diagnostic procedures were not useful. Antituberculosis drug treatment was carried out in time. The patient was followed up for 3 years after discharge and his prognosis was good.

In conclusion, co-infection with *Pneumocystis jirovecii* and *Mycobacterium tuberculosis* may exist in HIV-seronegative patients on long-term glucocorticoid therapy. When it is suspected, diagnostic procedures including invasive ones should be done as soon as possible and appropriate therapeutic interventions need to be given promptly.

## Abbreviations

CT, computed tomography; HIV, human immunodeficiency virus; PCP, pneumocystis pneumonia; TB, tuberculosis.

## Data Sharing Statement

All data are presented in this manuscript and can be accessed through the corresponding author on request.

## Ethics Approval and Consent to Participate

This study was approved by the institutional review boards of Peking University First Hospital (2021keyan111). The patient had given his written, informed consent to the use of his data for research.

## Consent to Publication

Written informed consent was obtained from the patient for publication of this case report and any accompanying images. A copy of the written consent is available for review by the Editor of this journal.

## Funding

This work was supported by National Key R&D Program of China (2020YFC2005401), Xicheng financial, scientific and technological project (XCSTS-SD2021-02), and Project funded by Baidu Fund of Peking University (2020BD045).

## Disclosure

The authors declare that they have no competing interests.

## References

1. Mongardon N, Bruneel F, Henry-Lagarrigue M, Legriel S, Azarian R, Bedos JP. Pneumonia involving *Mycobacterium tuberculosis* and *Pneumocystis jirovecii* in HIV-seronegative patients. *Eur J Intern Med*. 2008;19(7):e70–e72. doi:10.1016/j.ejim.2008.04.004
2. Suk CW, Bai KJ, Yu MC, Hu TY. Coinfection of *Pneumocystis jirovecii* pneumonia and pulmonary tuberculosis in a non-HIV-infected patient. *J Microbiol Immunol Infect*. 2015;48(6):711–712. doi:10.1016/j.jmii.2014.07.001
3. Li MC, Lee NY, Lee CC, Lee HC, Chang CM, Ko WC. *Pneumocystis jirovecii* pneumonia in immunocompromised patients: delayed diagnosis and poor outcomes in non-HIV-infected individuals. *J Microbiol Immunol Infect*. 2014;47(1):42–47. doi:10.1016/j.jmii.2012.08.024
4. World Health Organization. *Global Tuberculosis Report*. World Health Organization; 2019.
5. Coutinho AE, Chapman KE. The anti-inflammatory and immunosuppressive effects of glucocorticoids, recent developments and mechanistic insights. *Mol Cell Endocrinol*. 2011;335(1):2–13. doi:10.1016/j.mce.2010.04.005
6. Youssef J, Novosad SA, Winthrop KL. Infection risk and safety of corticosteroid use. *Rheum Dis Clin North Am*. 2016;42(1):157–176. doi:10.1016/j.rdc.2015.08.004
7. Caplan A, Fett N, Rosenbach M, Werth VP, Micheletti RG. Prevention and management of glucocorticoid-induced side effects: a comprehensive review: infectious complications and vaccination recommendations. *J Am Acad Dermatol*. 2017;76(2):191–198. doi:10.1016/j.jaad.2016.02.1240
8. Yale SH, Limper AH. *Pneumocystis carinii* pneumonia in patients without acquired immunodeficiency syndrome: associated illness and prior corticosteroid therapy. *Mayo Clin Proc*. 1996;71(1):5–13. doi:10.4065/71.1.5
9. Jick SS, Lieberman ES, Rahman MU, Choi HK. Glucocorticoid use, other associated factors, and the risk of tuberculosis. *Arthritis Rheum*. 2006;55(1):19–26. doi:10.1002/art.21705
10. Abubakar I, Stagg HR, Whitworth H, Lalvani A. How should I interpret an interferon gamma release assay result for tuberculosis infection? *Thorax*. 2013;68(3):298–301. doi:10.1136/thoraxjnl-2013-203247
11. Pai M, Denking CM, Kik SV, et al. Gamma interferon release assays for detection of *Mycobacterium tuberculosis* infection. *Clin Microbiol Rev*. 2014;27(1):3–20. doi:10.1128/CMR.00034-13



**Infection and Drug Resistance****Dovepress****Publish your work in this journal**

Infection and Drug Resistance is an international, peer-reviewed open-access journal that focuses on the optimal treatment of infection (bacterial, fungal and viral) and the development and institution of preventive strategies to minimize the development and spread of resistance. The journal is specifically concerned with the epidemiology of antibiotic resistance and the mechanisms of resistance development and diffusion in both hospitals and the community. The manuscript management system is completely online and includes a very quick and fair peer-review system, which is all easy to use. Visit <http://www.dovepress.com/testimonials.php> to read real quotes from published authors.

Submit your manuscript here: <https://www.dovepress.com/infection-and-drug-resistance-journal>