


Acquired Hemophilia Associated with Rheumatic Diseases: A Case-Based Systematic Review

Qi Tang, Jiafen Liao, Xi Xie 

Department of Rheumatology and Immunology, the Second Xiangya Hospital, Central South University, Changsha, People's Republic of China

Correspondence: Xi Xie, Department of Rheumatology and Immunology, the Second Xiangya Hospital, Central South University, Changsha, 410011, People's Republic of China, Tel/Fax +86 0731 8529 5255, Email Hsxiexie1997@csu.edu.cn

Abstract: To strengthen the understanding of rheumatic diseases (RDs) as the most common underlying conditions associated with acquired hemophilia (AH), a potentially fatal bleeding condition due to the development of autoantibodies or inhibitors to coagulation factor VIII, and rarely to factor IX, here we presented two cases of RDs associated AH to elucidate the disease progression, treatment, and prognosis. The presented 2 cases showed good responses to glucocorticoid (GC) and immunosuppressive agents. And then, a case-based systematic review was conducted to better understand the clinically practiced diagnosis and treatment of RDs associated AH. A total of 14 articles were included in the final literature review. All the identified 14 patients with underlying RDs and AH presented with bleeding symptoms, increased APTT, decreased FVIII activity, and positive FVIII inhibitors. Twelve of the 14 patients (85.7%) started an eradication of autoantibodies treatment with GC and immunosuppressive agents. Among which six patients achieved partial or complete remission, and four patients (28.6%) switched to Rituximab and responded well. Nine of the 14 patients received hemostasis therapy, including recombinant human FVIIa (rFVIIa). Two patients (14.3%) died due to mass bleeding and key organ failure. AH should be highly suspected in patients with RDs presenting spontaneous mucocutaneous or internal bleeding and an isolated prolonged APTT. Given the high morbidity of AH, it is important to facilitate efficient and proper management.

Keywords: acquired hemophilia, systemic lupus erythematosus, Sjogren syndrome, rheumatoid arthritis, connective tissue disease

Introduction

Acquired hemophilia (AH) is a potentially fatal bleeding condition due to the development of autoantibodies or inhibitors to a coagulation factor, usually factor VIII (FVIII), and seldom factor IX (FIX). It occurs with a low incidence rate of approximately 0.2–1.0 per 1 million people per year and with a mortality rate of about 5–10% as a direct result of FVIII inhibitors.^{1,2} The autoantibodies against specific domains of the FVIII/FIX molecules impair their function of binding, resulting in bleeding into the skin, muscles, gastrointestinal tracts, and other sites.² The most common underlying conditions associated with AH are malignant tumors, infections, and rheumatic diseases (RDs).¹ Although rare, AH has a high fatality, and it poses a great challenge for clinicians to diagnose timely and treat properly. Since autoimmune diseases are among the most common underlying conditions associated with acquired FVIII inhibitors, it is important that the clinician managing patients with RDs be familiar with the diagnosis and treatment of RDs associated AH. Here, we share our own experiences and make a concise and in-depth review to better understand the diagnosis and treatment of RDs associated AH.

Case Presentation

Patient I

A 60-year-old woman complained of ecchymosis over limbs for 10 days. She had repeated attacks of oral ulcers, alopecia, mouth and eye dryness over the past year. Physical examination showed a large amount of subcutaneous hemorrhage. Her right buttock and left thigh were painful with swelling, which was suspected to be a hematoma (Figure 1A). Complete blood count (CBC) showed decreased Hemoglobin (HGB) 44g/L, and Platelet (PLT) $78 \times 10^9/L$. Routine urine analysis (RUA)

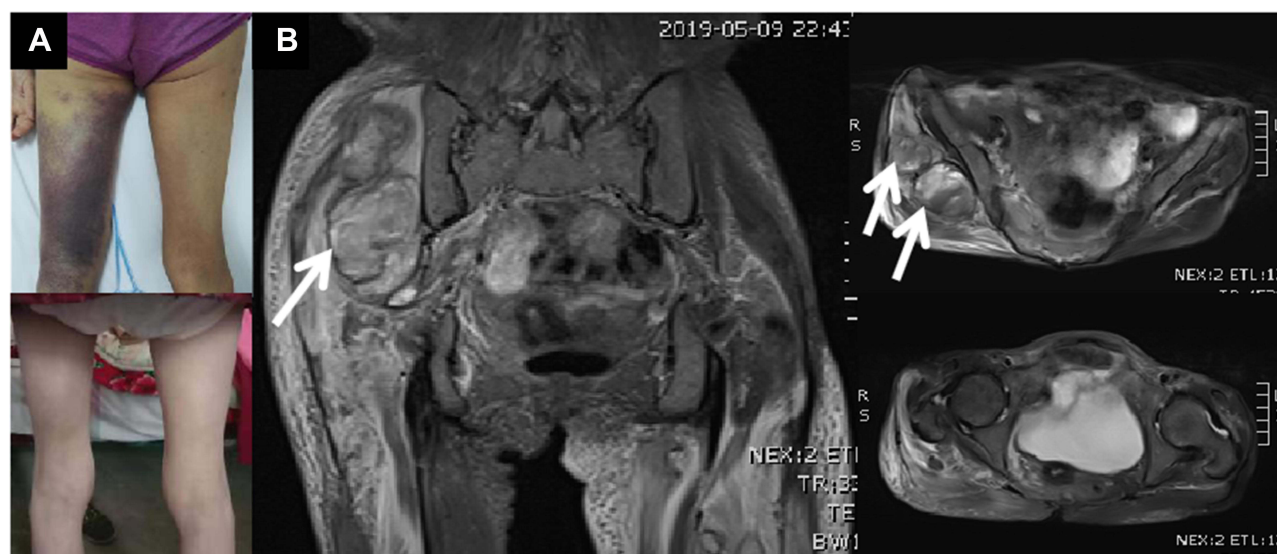

Figure 1 (A): The patient's right buttock and left thigh was obviously enlarged. There was ecchymosis over left thigh (above). The ecchymosis disappeared after 3 months (below). **(B):** T2 weighted imaging of magnetic resonance imaging showed occupying lesion (probably hematoma, see white arrows) deep under the right gluteus maximus, and the signal of muscles and other soft tissues around the pelvis and femur increased widely.

revealed proteinuria (+) and microscopic hematuria (++). Complement 3 (C3) decreased to 0.39 g/L and immunoglobulin (Ig) G elevated to 19.80g/L. Autoantibodies showed ANA1: 320+, anti-U1RNP+++, anti-SSA+, anti-Ro-52+++, AMA-M2+, anti-3E/BPO+. Coagulation tests revealed prolonged APTT as 108.6 sec, decreased FVIII activity as 0.5% (reference range: 50–150%), and positive Anti-FVIII antibody. Schirmer test 3mm/5 min. Magnetic resonance imaging (MRI) scanning showed occupying lesion (see white arrows) deep under the right gluteus Maximus (Figure 1B). The patient was diagnosed with systemic lupus erythematosus (SLE) (based on 2019 EULAR/ACR classification criteria for SLE), secondary Sjogren Syndrome (SS) and AH. She was treated with 400 mg/kg/day intravenous immunoglobulin (IVIG) for 5 days, 2 mg/kg/day intravenous (IV) methylprednisolone (mPSN), oral hydroxychloroquine (HCQ) 200 mg Bid, cyclosporin A (CsA) 50 mg Bid, and IV cyclophosphamide (CTX) 600 mg in total, accompanied with a supplement of washing red cells (WRCs) and activated prothrombin complex concentrate (APCC). After 15 days of aggressive therapy, she felt better and bleeding regressed, although her lab examinations still demonstrated a lower HGB 42g/L, prolonged APTT 110.7 sec, and decreased FVIII activity of 0.6%. After discharge, she continued to receive oral mPSN gradually tapered from 40mg/d to 8mg/d over six months, with hydroxychloroquine (HCQ) at 200 mg Bid and cyclosporin A (CsA) at 50 mg Bid applied together during the same period. At three months after discharge, she improved significantly with HGB 98g/L, APTT 53.5 sec, and C3 0.56g/L. After six months since discharge, her lab examinations returned to normal range: HGB 110g/L, APTT 26.7 sec, C3 0.77 g/L. There was no relapse during the 2-year follow-up.

Patient 2

A 67-year-old man presented with ecchymosis over limbs for 1 month. His CBC showed a decreased level of HGB 87 g/L. Autoantibodies revealed ANA (1:320)+, anti-SSA++, anti-Ro-52+, anti-Sp100+, anti-gp210+. Coagulation tests revealed prolonged APTT 76.3 sec, decreased FVIII activity 2.5%, and positive anti-FVIII antibody. He was diagnosed with AH associated with undifferentiated connective tissue disease (UCTD). He received IV mPSN 1mg/kg/day and CTX 600 mg as initial therapy, and then continued to receive oral mPSN gradually tapered from 40mg/d to 8mg/d and HCQ at 200 mg Bid as maintenance therapy after discharge. Hemorrhagic manifestations subsided considerably during the 1-year follow-up.

Systematic Review

In order to obtain a better and deeper understanding of RDs associated with AH, we searched PUBMED and EMBASE from Jan 1st, 2010 to Dec 31, 2021 using the following keywords: acquired hemophilia, connective tissue disease, rheumatic diseases, rheumatoid arthritis, systemic lupus erythematosus. The detailed searching strategies and PRISMA

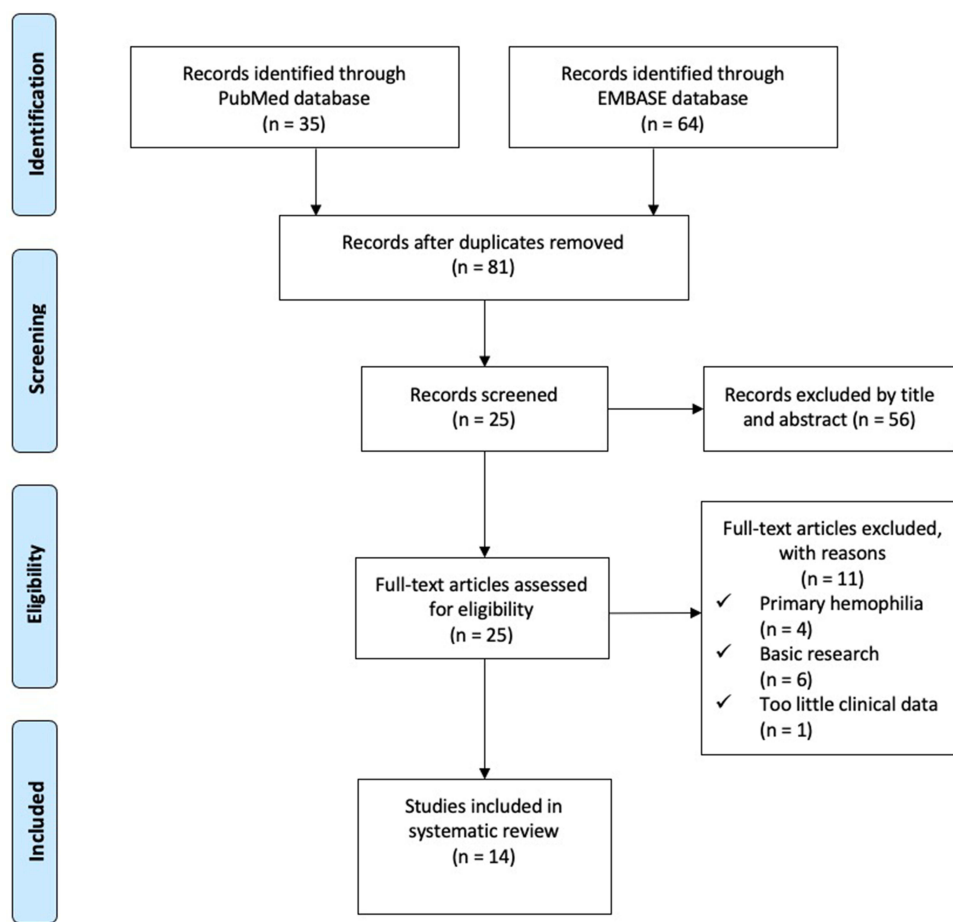


Figure 2 PRISMA Flow Diagram. PubMed Searching Strategy: ("acquired hemophilia" OR "secondary hemophilia") AND ("connective tissue disease" OR "rheumatic diseases" OR "rheumatoid arthritis" OR "systemic lupus erythematosus") AND ("2010/01/01"[Date - Publication]: "2021/12/31"[Date - Publication]) AND English[Language] EMBASE Searching Strategy: ("acquired hemophilia": ab,ti OR "secondary hemophilia": ab,ti) AND ("connective tissue disease": ab,ti OR "rheumatic diseases": ab,ti OR "rheumatoid arthritis": ab,ti OR "systemic lupus erythematosus": ab,ti) AND English: la AND (2010: py OR 2011: py OR 2012: py OR 2013: py OR 2014: py OR 2015: py OR 2016: py OR 2017: py OR 2018: py OR 2019: py OR 2020: py OR 2021: py).

flow chart are seen in [Figure 2](#). Thirty-five articles resulted from PUBMED and 64 from EMBASE. After excluding reviews, duplicates, and articles with too little clinical data, a total of 14 articles were included in the final literature review.^{3–16} Detailed characteristics were listed in [Table 1](#). SLE (7/14) and rheumatoid arthritis (RA) (4/14) were the most common concurrent RDs. All 14 patients presented with bleeding symptoms, increased APTT, decreased FVIII activity, and positive FVIII inhibitors. Most patients (92.9%) showed negative antiphospholipid antibody and lupus anticoagulant. Twelve of the 14 patients (85.7%) started treatment with GC and immunosuppressive agents (CTX and CsA were the most commonly used) with/without IVIG, with good responses. Four patients (28.6%) switched to B cell-targeted biologic therapy with Rituximab, and one patient (7.1%) switched to IL-6 targeted therapy with tocilizumab. One patient received concomitant plasmapheresis. Nine patients (64.3%) received hemostasis therapy such as recombinant FVIIa (rFVIIa) or APCC. Two patients (14.3%) died due to mass bleeding and multiple organ failures.

Discussion

AH is a rare but fatal autoimmune disorder based on antibody-mediated depletion of coagulation FVIII/FIX. AH is easily ignored or mistaken as other hemorrhagic diseases. The incidence of AH was estimated to be 1–4 per million based on results from the European Acquired Haemophilia Registry,¹⁷ although the incidence is increasing. A large survey in the 1980s suggested a mortality rate of 22%;¹⁸ however, lower mortality rate <10% was reported in two recent studies, which may be attributed to improved hemostatic agents.^{19,20} AH is a disorder driven by autoimmune B cells producing FVIII-

Table 1 14 Cases of Acquired Hemophilia Associated with Rheumatic Diseases

Reference	Age/Sex	Race	Chief Complaint	Tests	Basic RDs	Treatment	Prognosis
Braunert et al ³	76y/M	Caucasion	Hematoma	FVIII activity 1.2%; FVIII inhibitor 31.7 BU	Polymyalgia rheumatica	No improvement with aPCC, oral PED (1 mg/kg daily) and CTX (1.5mg/kg daily) after 2 weeks. Improvement with IV Rit at 375 mg/m ² weekly for four weeks.	No relapse within 6 months follow-up.
Arthanari et al ⁴	78y/F	Caucasion	Spontaneous subcutaneous bleeding	APTT 56s; FVIII inhibitor 22 BU; FVIII activity 3%; RF+, ANA+	RA	CTX 100mg daily, Transfusion of aPCC	Died less than 2 months after diagnosis due to mass bleeding and multiorgan failure.
Rezaieyazdi et al ⁵	37y/F	UK	Fatigue, malaise, abdominal pain, haematuria, large ecchymotic area on the left flank and leukopenia	HBG 12.5g/dl; PLT 180×10 ³ /μL; WBC 3×10 ³ /μL; APTT 95s; FVIII activity 3.9%; FVIII inhibitors>200 BU; ANA+, anti-Sm+, anti small nuclear RNP+, anti-dsDNA+; proteinuria 2350mg per 24h	SLE	Fresh frozen plasma infusion (10mL/kg), IV mPSN pulse 1000mg/day for 3 days, continued with 60mg PSN per day, IV pulse CTX	APTT, FVIII activity, and FVIII inhibitors became normal after 4 weeks. No relapse during the 1.5-year follow-up.
Drobiecki et al ⁶	48y/F	Caucasion	Diffuse bruising of the forearms, the trunk and right breast	HGB 80g/l, PLT 444*10 ⁹ /l; APTT 112s; FVIII activity 5.48%; FVIII inhibitor 29.9 BU	RA	rFVIIa, PED 60mg/day, and CTX 100mg/day	FVIII activity 29%, APTT 50.6s after 6 weeks. Experiences several relapses after discontinuation of CTX. Success with Rit 375mg/m ² /week for four doses.
Sebastian et al ⁷	25y/F	Caucasion	Multiple areas of ecchymoses on the upper and lower extremities, an episode of hemoptysis and increasing dyspnea	APTT 100s; Leukopenia 2.51×10 ³ /μL; HGB 7.2g/dl, PLT 210×10 ³ /μL; ANA1: 320+, SS-A +, Ro52+, ACA-; FVIII activity <5%; FVIII inhibitor 614.4 IU/mL	SLE	Oral mPSN 20 mg/day, chloroquine 250 mg/day and CsA 200 mg/day	Partially remission. Experienced a relapse due to pregnancy, and recieved remission with rFVIIa, PED 1 mg/kg and CsA 250 mg/day. No relapse during the 5-year follow-up with chloroquine 250 mg/ day, CsA 200 mg/day and mPSN in a maintenance dose.

Cui et al ⁸	42y/M	Asia	Gradually enlarged subcutaneous hematoma on the right scapula, sporadic skin ecchymosis, and painful swelling for 2 months	APTT 121.9s; FVIII activity 1%; FIX activity 4%; FVIII and FIX inhibitors levels were 30 and 15 BU; Proteinuria was 4.5 g per 24 hours; ANA 1:160+, anti-dsDNA 1:160+, anti-SSA+, anti-SSB+	SLE	Failed to respond to aPCC and PED 60 mg/day for 6 weeks. Weekly Rit at 375 mg/m ² for four consecutive weeks	Achieved partially remission with no haemorrhagic manifestations during the 1-year follow-up. Experienced relapse of both nephritis and AH after 1 year and 4 months, and died of progressive renal failure, severe pneumonia and intra-abdominal bleeding.
Khodamoradi et al ⁹	55y	UK	Hematoma and hematuria	Prolonged APTT, normal PT and platelet, low FVIII, high FVIII inhibitor	SLE	GC, FEIBA and Rit	Recovered.
Hashimoto et al ¹⁰	61y/F	Asia	Extensive subcutaneous bleeding	UK	RA	Failure with GC and CTX, success with tocilizumab	UK
Mo et al ¹¹	87y/F	Asia	Diffuse ecchymoses, melena, vaginal bleeding	HBG 5.7 mg/d; APTT>150s; FVIII level <1%; FVIII inhibitor 27.6 BU; ANA 1:160+, anti-SSA+; CT showed deep venous thrombosis	Undifferentiated connective tissue disease	GC and HCQ, an inferior vena cava catheter was placed	Achieved remission after 3 months.
Yang et al ¹²	53y/M	Asia	Arthralgia and ecchymotic skin lesions after arthrocentesis of knee joint	APTT 92.2 s; FVIII activity 1%; FVIII inhibitors 60.0 BU	SLE	IV pulse mPSN 500 mg/d, IV CTX, plasma and aPCC infusion	Achieved remission with no relapse.
Ghazlani et al ¹³	66y/M	UK	Spontaneous ecchymotic patches and hemarthrosis	APTT 49s; FVIII inhibitors 19 BU/mL; RF and CCP positive	RA	IV mPSN 240 mg for 3 days followed up with MTX 20mg/week and PED 7.5 mg/day; Rit 1g/2 weeks for 2 times; rFVIIa infusion	After 6 months, FVIII was 75% and the RA was in remission.

(Continued)

Table I (Continued).

Reference	Age/Sex	Race	Chief Complaint	Tests	Basic RDs	Treatment	Prognosis
Wei et al ¹⁴	40y/F	Asia	Oral cavity and nose mucosal bleeding, joint hemarthrosis	HGB 49g/l, PLT $31 \times 10^9/l$; APTT 107.4s; FVIII inhibitor positive; Platelet associated antibody IgG positive	ITP	IVIG 2g/kg; PED 1mg/kg/day; IV CTX 2 mg/kg/day. After failure, Rit at 375mg/m ² /week was added	After 4 weeks of Rit, APTT, FVIII activity, and FVIII inhibitors became normal. No relapse during 3-year follow-up.
Zaidi et al ¹⁵	20y/F	Saudi	Sudden onset swelling of the right hand	APTT 102.9s; FVIII activity 0.02%; FVIII inhibitor 22.4BU; ACA and anti- β 2GPI antibody were very high; ANA+, anti-dsDNA+	SLE APS	rFVIIa, PSN 1 mg/kg and HCQ. As the patient's APTT was still prolonged 2 weeks later with mild bleeding, she was started on Rit at 375 mg/m ² weekly for 4 weeks	APTT, FVIII levels, and FVIII inhibitors became normal after two weeks of initiating Rit. No relapse during the 2-year follow-up.
Shen et al ¹⁶	51y/F	Asia	Fatigue, hematuria and ecchymoses for 1 week	HGB 55g/l, PLT $37 \times 10^9/l$; APTT 65.7s; FVIII activity 1.4%; FVIII inhibitor 8.5BU; ANA+, SSA+	SLE	Transfusion of rFVIIa, IV mPSN 80mg daily, IV CTX 200 mg weekly, plasmapheresis	Achieved remission after 1 month. No relapse during the 1-year follow-up.

specific antibodies, which are capable of hydrolyzing FVIII into smaller fragments and resulting in severe, spontaneous, life-threatening bleeding.²¹

From our experience. When patients with RDs present with bleeding symptoms, platelet count and clotting screen tests should be performed as soon as possible. If APTT is prolonged, further tests should be undertaken to evaluate FVIII/ FIX activity, acquired FVIII/FIX inhibitors, and lupus anticoagulant. After the diagnosis of AH is confirmed based on decreased FVIII/IX activity and positive FVIII/IX inhibitors, immediate interventions should be taken to stop the bleeding and to reduce inhibitors (Figure 3). In AH, FVIII inhibitors are most common, and FIX inhibitors are extraordinarily rare.

Based on the case series, GC and immunosuppressive agents presented to be highly cost-effective as the preferred treatment to reduce inhibitors. As for the patients who did not respond to or could not tolerate treatment with GC and immunosuppressive agents, biologics, most commonly Rituximab, seemed to be a good choice. This result is almost in accordance with a study of 331 patients from the prospective EACH2 registry,²² suggesting that GC combined with CTX resulted in more stable complete remission than GC alone or Rituximab-based regimens. This study also showed that Rituximab-based regimens required a longer time to achieve complete remission compared with GC with or without CTX. However, the case series in our review showed GC, and immunosuppressive agents took around 4–8 weeks, and Rituximab took around 2–4 weeks to show therapeutic effects. Patients with fatal and quick progressive bleeding should also be administered with bypassing agents, including APCC and rFVIIa, to control bleeding episodes. If bleeding

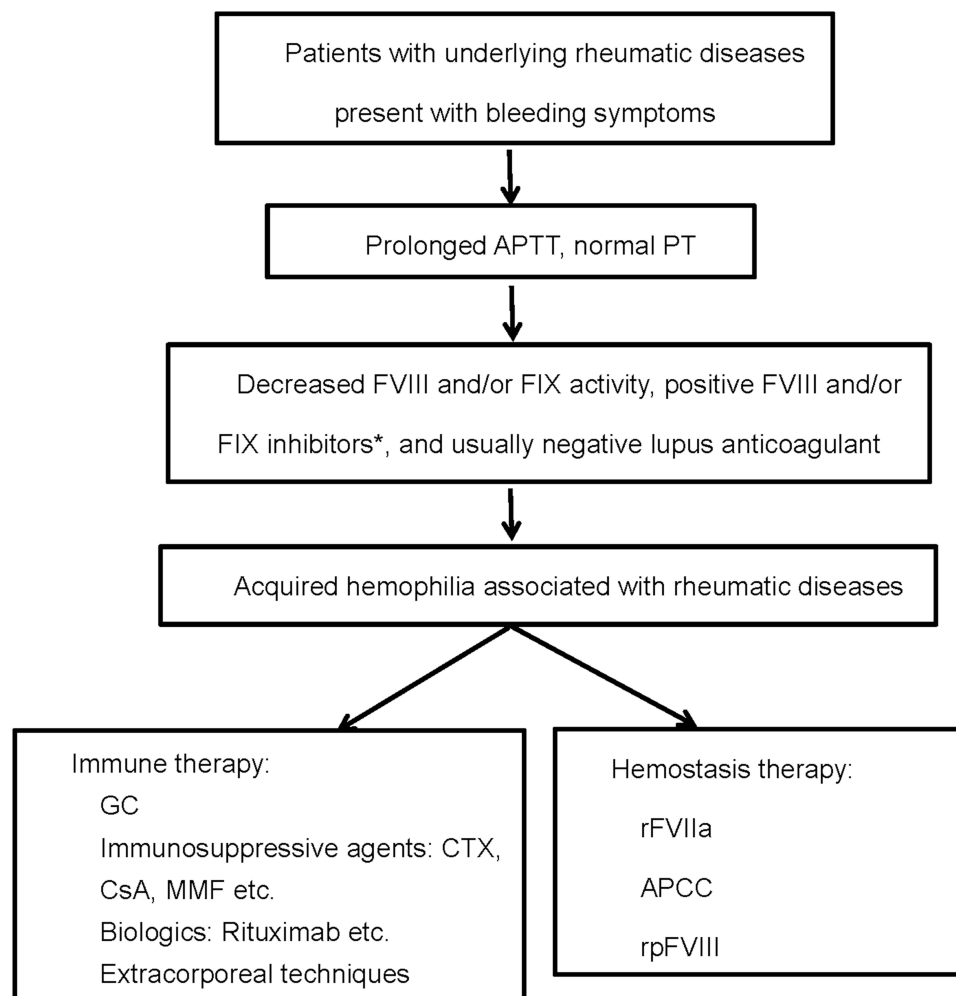


Figure 3 Diagnosis and treatment flow chart of rheumatic diseases associated acquired hemophilia. *FVIII inhibitors are most common in AH, and FIX inhibitors are extraordinarily rare.

persists, recombinant porcine FVIII (rpFVIII) can be used.²³ When patients with RDs associated AH are accompanied by immune thrombocytopenia, they are at higher risk of life-threatening hemorrhage. Exploratory surgery or arterial punctures for angiograms should be avoided in case of severe blood loss and uncontrollable hemorrhage.²⁴

Conclusion

AH should be highly suspected in patients with RDs presenting with spontaneous bleeding and an isolated prolonged APTT. Given the high morbidity of AH, it is important to facilitate efficient and proper management. GC combined with immunosuppressive agents is a first-line treatment. After failure, Rituximab seems to be a good choice. Patients with fatal and quick progressive bleeding should be administered with APCC and rFVIIa.

Abbreviations

AH, acquired hemophilia; FVIII, coagulation factor VIII; FIX, coagulation factor IX; RDs, rheumatic diseases; BU, Bethesda units; APCC, activated prothrombin complex concentrate; PED, prednisone; Rit, Rituximab; CTX, cyclophosphamide; MMF, mycophenolate mofetil; IVIG, intravenous immunoglobulin; UK, unknown; Anti-Sm, anti-Smith; Anti-RNP, anti ribonucleoproteins; Anti dsDNA, anti double-stranded DNA; mPSN, methylprednisolone; PSN, prednisolone; rFVIIa, recombinant FVIIa; GC, glucocorticoid; FEIBA, factor VIII inhibitor bypass activity; HCQ, hydroxychloroquine; ITP, immune thrombocytopenia; ACA, anticardiolipin antibodies; anti- β 2GPI, anti beta 2-glycoprotein I; APS, antiphospholipid syndrome.

Ethics and Consent

The ethics committee of the Second Xiangya Hospital of Central South University approved this study. The patients/participants provided their written informed consent to participate in this study. Written informed consent was obtained from the individual(s) for the publication of any potentially identifiable images or data included in this article.

Acknowledgments

Thank Dr. Jinshen He, for his editorial contributions to the manuscript.

Funding

The study is supported by the National Natural Science Foundation of China (No. 81701552, No. 81873882).

Disclosure

The authors report no conflicts of interest in this work.

References

1. O'Connor CR. Systematic review of the presentation of coagulation factor VIII inhibitors in rheumatic diseases: a potential cause of life-threatening hemorrhage. *Semin Arthritis Rheum*. 2015;44(6):695–709. doi:10.1016/j.semarthrit.2014.11.008
2. Boggio LN, Green D. Acquired hemophilia. *Rev Clin Exp Hematol*. 2001;5(4):389–431. doi:10.1046/j.1468-0734.2001.00049.x
3. Braunert L, Bruegel M, Pfeiffer C, et al. Rituximab in der Behandlung der erworbenen Hämophilie A bei einem Patienten mit polymyalgia rheumatica [Rituximab in the treatment of acquired haemophilia A in a patient with polymyalgia rheumatica]. *Hamostaseologie*. 2010;30(Suppl 1):S40–S43. doi:10.1055/s-0037-1619069
4. Arthanari S, Ahmad H, Nisar M. Fatal acquired hemophilia A in a patient with rheumatoid arthritis treated with Adalimumab. *J Clin Rheumatol*. 2012;18(1):50–51. doi:10.1097/RHU.0b013e31823ee3cd
5. Rezaieyazdi Z, Sharifi-Doloui D, Hashemzadeh K, et al. Acquired haemophilia A in a woman with autoimmune hepatitis and systemic lupus erythematosus: review of literature. *Blood Coagul Fibrinolysis*. 2011;22(8):738–741. doi:10.1097/MBC.0b013e32834a5c8e
6. Drobiecki A, Pasiarski M, Hus I, et al. Acquired hemophilia in the patient suffering from rheumatoid arthritis: case report. *Blood Coagul Fibrinolysis*. 2013;24(8):874–880. doi:10.1097/MBC.0b013e3283646635
7. Sebastian A, Misterska-Skóra M, Podolak-Dawidziak M, et al. Pregnancy exacerbates complications of acquired hemophilia in a patient with systemic lupus erythematosus. *Postepy Dermatol Alergol*. 2015;32(3):235–238. doi:10.5114/pdia.2014.40964
8. Cui QY, Wu TQ, Shen HS, et al. Refractory lupus nephropathy and acquired factor VIII and IX deficiencies in a patient with systemic lupus erythematosus treated with Rituximab. *Haemophilia*. 2017;23(6):e504–e506. doi:10.1111/hae.13232

9. Khodamoradi Z, Nazarinia MA, Bazdar S. Acquired hemophilia as initial presentation in a patient with systemic lupus erythematosus. *Curr Rheumatol Rev*. 2017;13(3):236–238. doi:10.2174/1573397113666170519121952
10. Hashimoto A, Takafuta T, Kido M, et al. Successful management of recurrent bleeding with tocilizumab in an acquired hemophilia A patient with rheumatoid arthritis. *Rinsho Ketsueki*. 2017;58(7):738–742. doi:10.11406/rinketsu.58.738
11. Mo L, Bao GC. Acquired factor VIII deficiency: two case reports and a review of literature. *Exp Hematol Oncol*. 2017;6:8. doi:10.1186/s40164-017-0068-3
12. Yang F, Zhou YS, Jia Y. Systemic lupus erythematosus with acquired hemophilia A: a case report. *Beijing Da Xue Xue Bao Yi Xue Ban*. 2018;50(6):1108–1111.
13. Ghazlani I, Mounach A, Ghazi M, et al. Targeting acquired hemophilia a with rheumatoid arthritis by a rituximab shot: a case report and review of the literature. *Am J Case Rep*. 2018;19:582–588. doi:10.12659/AJCR.908854
14. Wei F. Successful treatment of acquired hemophilia A associated with immune thrombocytopenia and joint hemarthrosis: a case report and literature review. *Medicine*. 2018;97(38):e12044. doi:10.1097/MD.00000000000012044
15. Zaidi ARZ, AlSheef M, Motabi IH, et al. Systemic lupus erythematosus presenting as hematoma of the hand due to acquired inhibitors to factor VIII: early and prolonged remission achieved with upfront rituximab. *Cureus*. 2019;11(5):e4786. doi:10.7759/cureus.4786
16. Shen P, Li J, Tu S, et al. Acquired hemophilia A in a woman with systemic lupus erythematosus: a case report and review of literature. *Medicine*. 2020;99(43):e22926. doi:10.1097/MD.00000000000022926
17. Knoebl P, Marco P, Baudo F, et al. Demographic and clinical data in acquired hemophilia A: results from the European Acquired Haemophilia Registry (EACH2). *J Thromb Haemost*. 2012;10(4):622–631. doi:10.1111/j.1538-7836.2012.04654.x
18. Green D, Lechner K. A survey of 215 non-hemophilic patients with inhibitors to factor VIII. *Thromb Haemost*. 1981;45(3):200–203. doi:10.1055/s-0038-1650169
19. Schep SJ, van Dijk W, Beckers E, et al. Treatment of acquired hemophilia A, a balancing act: results from a 27-year Dutch cohort study. *Am J Hematol*. 2021;96(1):51–59. doi:10.1002/ajh.26009
20. Holstein K, Liu X, Smith A, et al. Bleeding and response to hemostatic therapy in acquired hemophilia A: results from the GTH-AH 01/2010 study. *Blood*. 2020;136(3):279–287. doi:10.1182/blood.2019003639
21. Mahendra A, Padiolleau-Lefevre S, Kaveri SV, et al. Do proteolytic antibodies complete the panoply of the autoimmune response in acquired haemophilia A? *Br J Haematol*. 2012;156(1):3–12. doi:10.1111/j.1365-2141.2011.08890.x
22. Collins P, Baudo F, Knoebl P, et al. Immunosuppression for acquired hemophilia A: results from the European Acquired Haemophilia Registry (EACH2). *Blood*. 2012;120(1):47–55. doi:10.1182/blood-2012-02-409185
23. Leebeek FWG. New developments in diagnosis and management of acquired hemophilia and acquired von Willebrand Syndrome. *Hemasphere*. 2021;5(6):e586. doi:10.1097/HS9.0000000000000586
24. Hay CR. Acquired haemophilia. *Bailliere's Clin Haematol*. 1998;11(2):287–303. doi:10.1016/S0950-3536(98)80049-8

Publish your work in this journal

The Journal of Inflammation Research is an international, peer-reviewed open-access journal that welcomes laboratory and clinical findings on the molecular basis, cell biology and pharmacology of inflammation including original research, reviews, symposium reports, hypothesis formation and commentaries on: acute/chronic inflammation; mediators of inflammation; cellular processes; molecular mechanisms; pharmacology and novel anti-inflammatory drugs; clinical conditions involving inflammation. The manuscript management system is completely online and includes a very quick and fair peer-review system. Visit <http://www.dovepress.com/testimonials.php> to read real quotes from published authors.

Submit your manuscript here: <https://www.dovepress.com/journal-of-inflammation-research-journal>