

Corynebacterium striatum Endocarditis After Renal Transplantation Confirmed by Metagenomic Next-Generation Sequencing: Case Report and Literature Review

Meng-meng Zheng*, Li-min Shang*, Chun-kai Du*, Lei Zhang, Wen Sun, Zhi-peng Wang, Yi-chen Zhu, Ye Tian

Department of Urology, Beijing Friendship Hospital, Capital Medical University, Beijing, People's Republic of China

*These authors contributed equally to this work

Correspondence: Yi-chen Zhu; Ye Tian, Department of Urology, Capital Medical University, Beijing Friendship Hospital, No. 95 Yong'an Road, Xicheng District, Beijing, 100050, People's Republic of China, Email zhuyc82@sina.com; tianye166@126.com

Background: Potent immune-suppressive therapy has been demonstrated to increase the risk of infective endocarditis (IE) in renal recipients. Reports of *Corynebacterium striatum* (*C. striatum*) endocarditis in renal recipients are scarce, thus limiting understanding of the disease.

Case Presentation: We describe a case of native valve endocarditis caused by *C. striatum* in a 35-year-old male patient. The young man with end-stage renal failure underwent kidney transplantation because of autosomal dominant polycystic kidney disease. Ceftazidime was administered after the surgery according to routine procedures, and the patient was discharged on the 14th day after the surgery without any evidence of infection. The patient experienced fever on the 56th day, and *Corynebacterium* was cultured from the patient's blood, in agreement with the results of testing of the donor kidney preservation solution. On the 64th day, multiple thromboses were found in the right external iliac artery, particularly around the anastomotic orifice of the transplanted renal artery. Vegetation was found in the posterior mitral valve tip on the 65th day. The patient had symptoms of persistent angina pectoris and chest tightness and underwent mitral valve replacement and vegetative resection. The patient eventually died. *C. striatum* was detected in the mitral valve and vegetation tissue with metagenomic next-generation sequencing.

Conclusion: *C. striatum* may cause endocarditis and endanger patients' lives and thus warrants greater attention. Genotypic assays such as metagenomic next-generation sequencing are demonstrated to be effective in confirming species identity. Adequate anti-infection therapy and early surgery are required after IE is discovered.

Keywords: kidney transplantation, infection, endocarditis, *Corynebacterium striatum*, case report

Background

Infective endocarditis (IE) refers to inflammation of the heart valve or ventricular wall caused by various pathogens. IE may result in valve disease, heart failure and possibly thromboembolic disease, thus endangering patients' lives. Renal transplant recipients receive life-long immunosuppressive therapy, which may result in a greater risk of severe infections than that in the immunocompetent population. When IE occurs in renal recipients, the infection usually presents specific clinical features and is more difficult to control. The frequency of *Corynebacterium striatum* (*C. striatum*) infections appears to have increased in recent years, possibly because of improved simplicity and accuracy in its identification through molecular genetic assays.¹ Case reports of *C. striatum* endocarditis in renal transplant recipients are rare. Here, we report the first case of native valve endocarditis caused by *C. striatum*, which was accurately identified through metagenomic next-generation sequencing (mNGS).

Case Presentation

A 35-year-old male patient with autosomal dominant polycystic kidney disease underwent kidney transplantation because of end-stage renal failure, without removal of the original bilateral polycystic kidneys. The donor was a 57-year-old man with a confirmed diagnosis of brain death caused by hypertensive intracerebral hemorrhage, and no confirmed infection was reported in the donor. The patient was administered a total of $21.15 \text{ mg} \times \text{kg}^{-1}$ of methylprednisolone, $0.24 \text{ mg} \times \text{kg}^{-1}$ of basiliximab and $1.83 \text{ mg} \times \text{kg}^{-1}$ of rabbit anti-human thymocyte immunoglobulin (ATG) for immune induction therapy. Methylprednisolone (1000 mg) and basiliximab (20 mg) were administered during the operation, and methylprednisolone (500, 240, 120, 80 and 40 mg from the 1st to the 5th day after surgery, respectively) and ATG (50, 25, 25, 25 and 25 mg from the 1st to the 5th day, respectively) were administered postoperatively because of delayed graft function. The maintenance immunosuppressive regimen comprised tacrolimus, mycophenolate mofetil and prednisone. The valley value of tacrolimus concentration was maintained at 6–8 ng/mL. The patient underwent hemodialysis before renal transplantation, had a urine output of more than 3000 mL per day and did not require dialysis after surgery. *Corynebacterium* was detected in the donor kidney preservation solution (without the drug sensitivity test) on the 4th day, but no evidence of subsequent *Corynebacterium*-related infection was observed, including an absence of symptoms of infection, or pathogens cultured from subsequent blood, urine and surgical site samples on the 3rd, 7th and 11th day. The antibiotic regimen of 2 g ceftazidime q12 h was prophylactically administered for 2 weeks after surgery, and the patient routinely took oral trimethoprim/sulfamethoxazole for PJP prophylaxis. The patient was discharged on the 14th day with a serum creatinine (Scr) level of 160–170 $\mu\text{mol/L}$. On the 56th day, the patient had a low fever of 37.9°C with light hematuria, as well as mild frequent, urgent and painful urination. The patient had a white blood cell count of $17.46 \times 10^9/\text{L}$, hemoglobin level of 95 g/L, C-reactive protein level of 231.06 mg/L, Scr level of 196.1 $\mu\text{mol/L}$, prothrombin time of 15.40 s and blood pressure of 87/64 mmHg. Partial intracapsular hemorrhage in the primary bilateral polycystic kidneys was detected by CT. The patient was diagnosed with septic shock and disseminated intravascular coagulation due to severe infection. The possibility of intracapsular hemorrhage with infection of cysts in bilateral polycystic kidney disease could not be ruled out. We carried out supportive treatment after the patient was readmitted to our hospital, and the patient's vital signs remained stable due to our treatment. The maintenance immunosuppressive regimen was then tapered with withdrawal of mycophenolate, tacrolimus was replaced by cyclosporin, and meropenem was administered to eliminate infection. *Corynebacterium* was found in the patient's blood, and *Enterococcus faecium* and *Pseudomonas putida* were found in the patient's urine on the 59th day. Linezolid was additionally administered. Ultrasound examination was performed on the 63rd day, and no special finding was noticed. Tacrolimus was used again on the 63rd day to replace cyclosporin (used for 3 days) due to patient intolerance.

The patient's troponin T and atrial natriuretic peptide levels continually increased during hospitalization. The patient began to complain of chest pain and dyspnea and became unable to lie in the supine position on the 64th day. The patient's electrocardiogram revealed sinus tachycardia with premature ventricular beats. On the same day, the patient developed acute anuria, and a gradual increase in Scr to 346 $\mu\text{mol/L}$ was detected. Multiple thromboses were found in the right external iliac artery by ultrasound, the largest of which was positioned around the anastomotic orifice of the transplanted renal artery, with a range of approximately $3.8 \times 1.0 \text{ cm}$. The patient was then transferred to the intensive care unit for bedside continuous renal replacement therapy, and an adjusted scheme of meropenem and vancomycin was used for anti-infection treatment.

Sudden persistent angina pectoris in the precordial region, accompanied by chest tightness and no sweating, appeared on the 65th day, and an increase in myocardial enzymes was detected. A cardiac murmur in each valve of the heart was found, particularly in the apical region, with a grade 3/6 diastolic murmur. Echocardiography revealed a medium echoic mass ($2.7 \times 1.4 \text{ cm}$ in diameter and approximately 3.2 cm^2 in area) at the posterior mitral valve tip, which swung with the cardiac cycle (Figure 1). Moderate-to-severe mitral regurgitation and mild-to-moderate tricuspid regurgitation were detected. Chest tightness accompanied by a significant increase in myocardial enzymes occurred on the 66th day. Thus, non-ST segment elevation myocardial infarction was diagnosed, and fraxiparin (0.2 mL, q12 h) was given. The patient had a cough with bloody sputum on the 69th day, and fraxiparin was stopped because of the possibility of pulmonary hemorrhage.

The operation was scheduled on the 71st day. Allograft nephrectomy was planned to be performed after mitral valve replacement and vegetative resection on the same operation day. The patient experienced cardiac arrest and ventricular

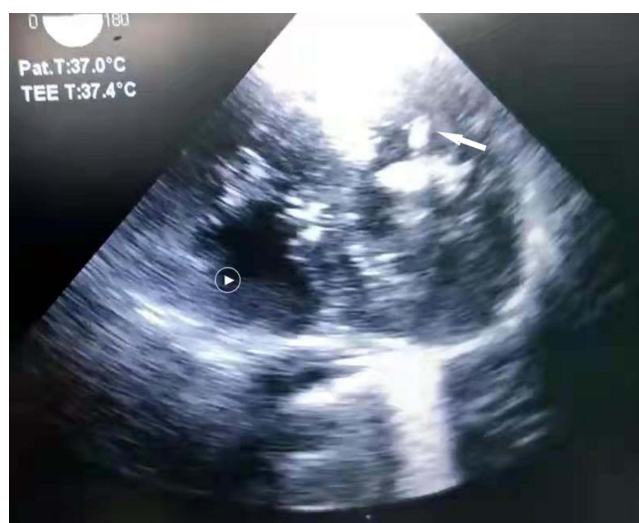

Figure 1 A medium echoic mass revealed by echocardiography.

Note: The white arrow shows large polypoid vegetations in the posterior leaflet of the mitral valve due to *Corynebacterium* infection.

fibrillation before entering the operating room. Emergency external chest compression, electric defibrillation, and endotracheal intubation were performed. Mitral valve replacement surgery and vegetative resection were performed after vital signs stabilized. Considering the large operative trauma and patient tolerance, we did not perform allograft nephrectomy. Large polypoid vegetation was found attached to the posterior leaflet of the mitral valve in the resected specimen (Figure 2A). The patient died on the 73rd day after being unable to maintain vital signs after surgery. No pathogens were cultured from the mitral valve or vegetation tissue.

We retrospectively analysed this case 1 year after the operation. Large polypoid excrescences of fibrin and platelets along the disrupted endocardial surface were seen in the pathological sections of valve tissue and vegetation (Figure 2B). Gram staining of the pathological sections revealed that the vegetations were acutely inflamed, with areas of valvular and leukocyte necrosis containing colonies of bacteria (Figure 2C). mNGS was retrospectively performed to detect pathogens in the mitral valve and vegetation wax tissue, using the following steps: DNA was extracted using the Generic Rapid Genomic DNA Extraction Kit (Lifefeng: DK806-02), quantified by Qubit (Thermo Fisher Scientific) and qualified by NanoDrop (Thermo Fisher Scientific); KAPA Hyper Prep kit (KAPA Biosystems) was used for the preparation of DNA libraries according to the manufacturer's protocols. Quality control was performed using Agilent 2100 and DNA libraries were 75 bp single-end sequenced on Illumina NextSeq 550Dx (Illumina); High-quality sequencing data were collected by removing low-quality reads, adapter contamination, duplicated and short (length <36 bp) reads. Human host sequences were identified by mapping to the human reference genome (hs37d5) using Bowtie2 software. Pathogen identification was performed by retaining nonhuman sequences and aligning them with the microorganism genome database, which contained bacterial, fungal, viral and parasite genomic sequences (download from <https://www.ncbi.nlm.nih.gov/>); the result was considered positive if a species detected by mNGS had a species-specific read number ≥ 1 with sequences of *Mycobacterium*, *Nocardia* and *Legionella pneumophila*, and the result was considered positive if species had at least 3 nonoverlapping reads with sequences of bacteria (excluding *Mycobacterium*, *Nocardia* and *Legionella pneumophila*), fungi, viruses and parasites. The identified gene sequences were found to be identical to those of *C. striatum*, thus confirming *C. striatum* endocarditis. The raw sequencing data were submitted and deposited at the National Center for Biotechnology Information (NCBI) Sequence Read Archive (SRA) with the accession number SAMN30015192.

Literature Review

We reviewed 30 previously reported cases of *C. striatum* endocarditis through an English language literature search in PubMed with the following keywords: “*Corynebacterium striatum*” and “Endocarditis” (Table 1). The mean age of the patients was 62.1 years (range 24–83), 19 patients (63.3%) were male, and 17 (56.7%) patients had heart disease. Most of the cases exhibited native valve endocarditis (80%, 24/30), most of which were associated with the mitral valve (43.3%,

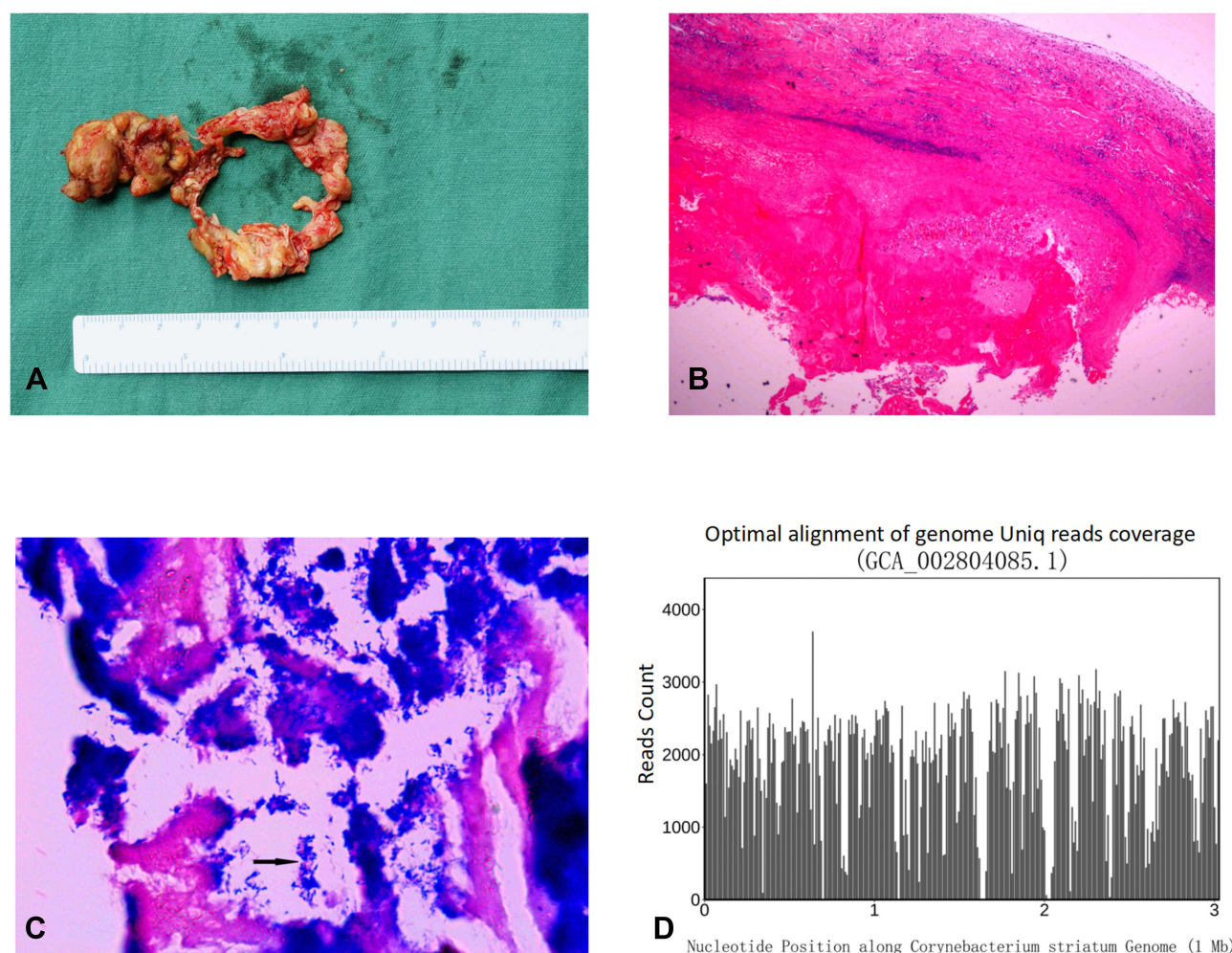


Figure 2 Morphological, pathological and microbiological data of valve tissue and vegetation after mitral valve and vegetation resection.

Notes: Gross pathology of valve tissue and vegetation (A); histopathology of valve tissue and vegetation (B); tissue Gram stain of valve tissue and vegetation (C); optimal alignment of genome Uniq read coverage (D). “1 Mb” means “mega base pairs”, which represents the size unit of the genome (D).

13/30), followed by the aortic valve (30%, 9/30). Several cases were associated with medical devices (including one case with an artificial valve and five cases with a pacemaker lead). Among all cases, four cases of *C. striatum* endocarditis were identified through molecular genetic assays, and other cases were identified through traditional culture tests. All patients, except for two with unknown status, accepted antibiotic treatment, and 15 (50%) patients underwent surgery in addition to antibiotic treatment. Four patients (13.3%) eventually died, and 21 (70%) survived. The outcomes of the remaining patients are unknown. The mortality rate in patients who underwent surgery was 20% and that among all patients was 23.3%.

C. striatum is a commonly isolated *Corynebacterium* in clinical microbiology laboratories, but confirmed *C. striatum* infections are relatively rare. In the diagnosis of *C. striatum* endocarditis, traditional diagnostic methods based on microbiology laboratory findings are mature and relatively inexpensive; however, most are time-consuming and have low positivity,² and may even lead to misidentification.^{1,3} mNGS has higher sensitivity than the traditional method and thus has been recommended for early pathogen diagnosis.² A combination of pathology and etiology has also been suggested to diagnose IE.⁴ Appropriate antibiotic therapy along with strict source control (eg, removal of prosthetic devices) are usually considered effective methods for the treatment of *C. striatum* endocarditis.⁵ Among all cases reviewed, seven received daptomycin as an antibiotic treatment, which has been demonstrated to be a useful option for patients whose infections are refractory to traditional antibiotics.^{6–8} During the course of conservative management, surgical intervention should always be considered to prevent fatal cardiovascular events.^{9–11}

Table I 30 Reported Cases of Infective Endocarditis Caused by *Corynebacterium striatum*

Year	Sex	Age	Trans	ESRD	Heart Disease	Artificial Valve/Heart Surgery	Pacemaker	Position	Vegetation	Antibiotic	Drug Resistance	Surgery	Survival
2016	M	55	N	N	N	N	N	MV	Y	Vancomycin	N	Y	A
2012	M	56	N	Y	N	N	N	MV	Y	Telavancin	Y	Y	D
2021	M	55	N	Y	Y	N	Y	AV	Y	Daptomycin, rifampin	N	Y	D
2021	M	82	N	N	Y	N	N	AV	Y	Vancomycin	N	N	D
2018	M	54	N	Y	N	N	N	MV, AV, TV	Y	N/A	N/A	Y	N/A
2008	F	73	N	N	Y	N	N	MV	Y	Vancomycin	N	N	A
2014	F	53	N	N	N	N	N	AV	Y	Ampicillin/sulbactam, gentamycin	N	Y	A
2022	F	73	N	N	N	N	Y	Pacemaker	N	Vancomycin	N	Y	A
2010	F	71	N	N	Y	N	Y	Pacemaker	Y	Daptomycin	Y	Y	A
2002	F	62	N	N	Y	Y	N	Artificial valve	N	Vancomycin	N	N	A
2005	F	72	N	N	Y	Y	N	N/A	Y	Vancomycin, rifampin	N	N	A
2005	F	61	N	N	Y	N	N	MV	Y	Vancomycin, gentamicin	N	N	A
1996	M	24	N	N	Y	Y	N	Pulmonary valve	Y	Moxicillin, netilmicin, teicoplanin	N	Y	A
1996	M	68	N	N	Y	N	N	MV	Y	Vancomycin, penicillin	N	N	N/A
2017	M	63	N	N	Y	N	N	Left atrium	Y	Linezolid, daptomycin	Y	Y	A
1990	M	76	N	N	N	N	N	AV	Y	Ampicillin, gentamicin	N	Y	D
2021	M	48	N	N	Y	N	Y	TV, pacemaker	Y	Vancomycin, daptomycin	Y	Y	A
2005	F	46	N	Y	N	N	N	TV	Y	Linezolid, vancomycin, daptomycin, rifampin	N	N	A
1994	M	54	N	N	N	N	N	AV	N	Vancomycin, ampicillin, gentamicin	N	Y	A
2018	M	69	N	N	Y	Y	N	AV	Y	Vancomycin	N	N	D
2006	M	68	N	N	Y	Y	N	Prosthetic MV	Y	Vancomycin	Y	N	A
2008	M	83	N	N	N	N	N	MV	Y	Penicillin, gentamicin, daptomycin	N	N	D
2020	M	54	N	Y	N	N	N	MV, AV, TV	Y	Vancomycin, ceftriaxone	N/A	Y	A
2002	F	72	N	N	Y	Y	N	MV	Y	Vancomycin, gentamicin, benzyl penicillin	N/A	N	D
2015	M	27	N	N	Y	N	N	MV	Y	Penicillin, cefuroxime	N/A	N	A
2012	M	78	N	Y	Y	N	Y	TV	Y	Daptomycin	Y	N	A
1996	M	72	N	N	Y	N	Y	MV, pacemaker	Y	Vancomycin, rifampin	Y	N	A
2002	M	50	N	N	N	N	N	AV	Y	Vancomycin, netilmicin	Y	Y	A
2006	F	77	N	N	N	N	N	MV	Y	Unknown	N/A	N	A
2006	F	69	N	N	N	N	N	MV	N	Vancomycin, cefepime	N	Y	A

Abbreviations: AV, aortic valve; TV, tricuspid valve; MV, mitral valve; N/A, no mention.

Discussion and Conclusions

Clinical features of *Corynebacterium* infection have been described as subacute because of its low virulence, and its tendency to occur in older patients with comorbidities or prosthetic devices.¹² The incidence is rare, but the mortality rate is substantial. A previous study¹³ has reported 4246 IE cases caused by various pathogens over a 10-year period, only 30 of which were caused by *Corynebacterium*. The incidence rate during that period was as low as 0.032 IE/10⁵ annually. Compared with the immunocompetent population, the population receiving long-term immunosuppressive therapy may have a greater risk of infection after solid organ transplantation. When IE occurs in renal transplant recipients, it usually exhibits unique characteristics and is more difficult to control. According to a previous retrospective study¹⁴ analysing the clinical characteristics of 73 cases of IE in renal transplant recipients, the average age of the affected recipients was 45 years, which was younger than that of the general population, which had a mean age of >60 years. Unlike immunocompetent patients with IE, immunocompromised recipients remain at high risk of IE even without cardiac structural abnormalities. *C. striatum* is a Gram-positive, rod-shaped, nonspore-forming bacillus from the nondiphtherial *Corynebacterium* species. Reports of *C. striatum* endocarditis in renal transplant recipients are scarce, thus limiting the understanding of the clinical manifestations.

Corynebacterium was cultured from both the donor kidney preservation solution and the patient's blood after the patient experienced fever, but no confirmed *Corynebacterium* infection was reported in the donor. The case we reported cannot be classified as a proven or possible DDI, but transmission of infection from the donor kidney to the recipient cannot be formally excluded; similarities were observed in a previous report.¹⁵ Here, we propose the possibility of donor kidney-derived *Corynebacterium* sp infection, which is also the first case of *C. striatum* endocarditis in a renal recipient confirmed by mNGS to date. The patient was discharged with no evidence of *C. striatum* infection, and the antibiotic regimen of ceftazidime was not adjusted because of the lack of drug sensitivity testing. The infection occurred 2 months postoperatively. One possibility was that the original ceftazidime antibiotic administered was not active against this particular strain of *Corynebacterium*, and the use of high-dose methylprednisolone and ATG might also have been associated with the delayed onset of *C. striatum* infection. The patient was initially admitted with symptoms of low fever and mild urinary tract infection, followed by signs of septic shock. The manifestation of intracapsular hemorrhage in polycystic kidneys detected on CT scans brought our attention to the possibility of infection secondary to intracapsular hemorrhage of the primary bilateral polycystic kidneys. The patient was 35 years old—younger than the average age of 64 years in the general population with IE in our literature review. The patient's condition developed so rapidly that we did not realize the occurrence of IE until the patient had experienced an acute renal transplant artery embolism event. All these findings highlight the challenges in the management of *Corynebacterium* infections among immunosuppressed renal recipients. Clinical detection of IE is critical, and echocardiography is the primary tool used. In our experience, in cases of unexplained fever, cardiac murmur, anemia and other conditions in renal transplant recipients, even if no structural heart lesions are present and the patient is young, the possibility of IE should be considered, and echocardiography should be performed early and repeatedly throughout the diagnosis and treatment process.

Descriptions of native valve *C. striatum* endocarditis in previous case reports are rare and were usually confirmed from only blood cultures. Only four cases of *C. striatum* endocarditis identified by genotypic assays were found in our literature review.^{1,3,16,17} Interestingly, except for only one positive blood culture result of *Corynebacterium* after fever, *Corynebacterium* was not cultured again from the patient's blood specimens or from resected endocardial specimens, possibly because of the slow growth rate of *Corynebacterium* and potential bactericidal effects due to the antibiotic treatment. We also note that *Corynebacterium* has usually been considered contamination when cultured from clinical specimens, and thus drug sensitivity testing for *Corynebacterium* may be ignored. The findings underscore the low detection rate of this bacterium through laboratory blood culture. Recently developed genotypic assays, such as mNGS, 16S ribosomal RNA sequencing and rpoB gene sequencing, have been used to improve pathogen identification in recent years. In this case report, we highly suspected that the endocarditis in our patient was caused by *Corynebacterium*; however, no pathogens were cultured from the mitral valve and vegetation tissue according to our microbiology laboratory results. We retrospectively performed mNGS on the valve tissue 1 year later and finally identified *C. striatum* endocarditis; therefore, we believe that mNGS has good application prospects for the management of IE. mNGS was recommended for early infection diagnosis on the basis of clinical suspicion of rare infection (eg, there is evidence of infection, but no pathogen cultured from clinical specimens based on our clinical microbiology laboratory

results; infection caused by pathogens detected by our clinical microbiology laboratory tests cannot explain the clinical symptoms of the patient). To our knowledge, this is the first case of native mitral valve *C. striatum* endocarditis confirmed in valve and vegetation tissue using mNGS.

Most *C. striatum* strains have been reported to be resistant to erythromycin, clindamycin and tetracycline, whereas penicillin, gentamicin, erythromycin and vancomycin have been reported to be most effective against *C. striatum*.^{18,19} In our case, antimicrobial therapy (linezolid, meropenem and vancomycin) was used empirically in the absence of bacterial sensitivity test results. Nonetheless, the patient's condition deteriorated so rapidly that we needed to perform valve replacement and vegetation resection to prevent the occurrence of cardiovascular events threatening the patient's life. We recognize that even with surgical treatment, the mortality rate of IE patients remains high. Half the patients in our literature review underwent valve replacement surgery, and the total mortality rate was approximately 23.3%. The resistome of *C. striatum* has been highlighted as dynamic and in evident expansion, which emphasizes the importance of implementing genomic surveillance programs and studies on the mechanisms of antimicrobial resistance should be further carried out.²⁰

The following experience can be summarized from this case. Adequate anti-infection treatment should be administered to renal transplant recipients at high risk of IE, and intermittent monitoring of bacterial culture and sensitivity testing should be performed during hospitalization and follow-up after discharge. Molecular methods are recommended for monitoring infection based on a clinical suspicion of rare infection. Requirements for anti-infection treatment may include sufficient long-term and combined application of antibiotics according to drug sensitivity testing. The risk of IE should be considered in cases of unexplained low fever and nonspecific clinical symptoms, and echocardiography should be performed promptly. Renal transplant recipients may have an extremely high risk of death and poor prognosis when they develop IE with valve vegetation. Early surgical intervention can improve the survival rate and decrease the mortality rate of IE, according to previous reports.^{21,22} Thus, such intervention is recommended concurrently with anti-infection treatment.

Abbreviations

C. striatum, *Corynebacterium striatum*; mNGS, metagenomic next-generation sequencing; IE, Infective endocarditis.

Data Sharing Statement

All data generated or analysed during this study are included in this published article [Figures 1 and 2].

Ethics Approval and Consent to Participate

The study protocol was approved by the Ethics Committee of Beijing Friendship Hospital and was conducted in accordance with the principles of the Declaration of Helsinki.

Consent for Publication

Written informed consent for publication of clinical details and images was obtained from a relative of the patient.

Acknowledgments

The authors acknowledge the Clinical Laboratory (Nanjing Dinfectome Inc., Jiangsu Province, China) for assistance with sample acquisition and analyses.

Funding

This research did not receive any specific grant from funding agencies in the public, commercial, or not-for-profit sectors.

Disclosure

The authors declare that they have no competing interests.

References

1. Hong HL, Koh HI, Lee AJ. Native valve endocarditis due to *Corynebacterium striatum* confirmed by 16s ribosomal RNA sequencing: a case report and literature review. *Infect Chemother*. 2016;48(3):239–245. doi:10.3947/ic.2016.48.3.239

2. Duan H, Li X, Mei A, et al. The diagnostic value of metagenomic next-generation sequencing in infectious diseases. *BMC Infect Dis.* 2021;21(1):62. doi:10.1186/s12879-020-05746-5
3. Elshibly S, Xu J, Millar BC, Armstrong C, Moore JE. Molecular diagnosis of native mitral valve endocarditis due to *Corynebacterium striatum*. *Br J Biomed Sci.* 2006;63(4):181–184. doi:10.1080/09674845.2006.11978096
4. Xu J, Yang Q, Li J, Zheng X. The left atrial bacterial vegetative mass due to *Corynebacterium striatum* as a presentation of myxoma: a case report. *BMC Infect Dis.* 2017;17(1):368. doi:10.1186/s12879-017-2468-8
5. Khan D, Shadi M, Mustafa A, et al. A wolf in sheep's clothing; case reports and literature review of *Corynebacterium striatum* endocarditis. *IDCases.* 2021;24:e01070. doi:10.1016/j.idcr.2021.e01070
6. Bhat Y, Bal AM, Rochow S, Gould IM. An unusual case of *Corynebacterium striatum* endocarditis and a review of the literature. *Int J Infect Dis.* 2008;12(6):672–674. doi:10.1016/j.ijid.2007.12.010
7. Shah M, Murillo JL. Successful treatment of *Corynebacterium striatum* endocarditis with daptomycin plus rifampin. *Ann Pharmacother.* 2005;39(10):1741–1744. doi:10.1345/aph.1G242
8. Fernández Guerrero ML, Molins A, Rey M, Romero J, Gadea I. Multidrug-resistant *Corynebacterium striatum* endocarditis successfully treated with daptomycin. *Int J Antimicrob Agents.* 2012;40(4):373–374. doi:10.1016/j.ijantimicag.2012.06.001
9. Mizoguchi H, Sakaki M, Inoue K, et al. Quadricuspid aortic valve complicated with infective endocarditis: report of a case. *Surg Today.* 2014;44(12):2388–2391. doi:10.1007/s00595-014-0844-1
10. Lee JY, Lee SH, Kim WH. Three-valve endocarditis caused by *Corynebacterium striatum*. *Korean Circ J.* 2018;48(9):861–862. doi:10.4070/kcj.2018.0126
11. Naqvi SY, Salama IG, Narins C, Stuver T. *Corynebacterium striatum* prosthetic valve endocarditis with severe aortic regurgitation successfully treated with transcatheter aortic valve replacement. *BMJ Case Rep.* 2018;11(1):e226881. doi:10.1136/bcr-2018-226881
12. Mashavi M, Soifer E, Harpaz D, Beigel Y. First report of prosthetic mitral valve endocarditis due to *Corynebacterium striatum*: successful medical treatment. Case report and literature review. *J Infect.* 2006;52(5):e139–e141. doi:10.1016/j.jinf.2005.08.027
13. Bläckberg A, Falk L, Oldberg K, Olaison L, Rasmussen M. Infective endocarditis due to *Corynebacterium* species: clinical features and antibiotic resistance. *Open Forum Infect Dis.* 2021;8(3):ofab055. doi:10.1093/ofid/ofab055
14. Nardi Agmon I, Goldberg E, Cohen E, Krause I. Infective endocarditis in the setting of renal transplantation: case report and review of the literature. *Transpl Infect Dis.* 2017;19(6):e12786. doi:10.1111/tid.12786
15. Zhang F, Zhong J, Ding H, Liao G. Effects of preservative fluid associated possible donor-derived carbapenem-resistant *Klebsiella pneumoniae* infection on kidney transplantation recipients. *BMC Nephrol.* 2022;23(1):101. doi:10.1186/s12882-022-02733-7
16. Oliva A, Belvisi V, Iannetta M, et al. Pacemaker lead endocarditis due to multidrug-resistant *Corynebacterium striatum* detected with sonication of the device. *J Clin Microbiol.* 2010;48(12):4669–4671. doi:10.1128/JCM.01532-10
17. Tran TT, Jaijakul S, Lewis CT, et al. Native valve endocarditis caused by *Corynebacterium striatum* with heterogeneous high-level daptomycin resistance: collateral damage from daptomycin therapy? *Antimicrob Agents Chemother.* 2012;56(6):3461–3464. doi:10.1128/AAC.00046-12
18. Martínez-Martínez L, Suárez AI, Winstanley J, Ortega MC, Bernard K. Phenotypic characteristics of 31 strains of *Corynebacterium striatum* isolated from clinical samples. *J Clin Microbiol.* 1995;33(9):2458–2461. doi:10.1128/jcm.33.9.2458-2461.1995
19. Rufael DW, Cohn SE. Native valve endocarditis due to *Corynebacterium striatum*: case report and review. *Clin Infect Dis.* 1994;19(6):1054–1061. doi:10.1093/clinids/19.6.1054
20. Leyton B, Ramos JN, Baio PVP, et al. Treat me well or will resist: uptake of mobile genetic elements determine the resistome of *Corynebacterium striatum*. *Int J Mol Sci.* 2021;22(14):7499. doi:10.3390/ijms22147499
21. Chu VH, Park LP, Athan E, et al. Association between surgical indications, operative risk, and clinical outcome in infective endocarditis: a prospective study from the International Collaboration on Endocarditis. *Circulation.* 2015;131(2):131–140. doi:10.1161/CIRCULATIONAHA.114.012461
22. Habib G, Erba PA, Iung B, et al. Clinical presentation, aetiology and outcome of infective endocarditis. Results of the ESC-EORP EURO-ENDO (European infective endocarditis) registry: a prospective cohort study. *Eur Heart J.* 2019;40(39):3222–3232. doi:10.1093/eurheartj/ehz620

Infection and Drug Resistance

Dovepress

Publish your work in this journal

Infection and Drug Resistance is an international, peer-reviewed open-access journal that focuses on the optimal treatment of infection (bacterial, fungal and viral) and the development and institution of preventive strategies to minimize the development and spread of resistance. The journal is specifically concerned with the epidemiology of antibiotic resistance and the mechanisms of resistance development and diffusion in both hospitals and the community. The manuscript management system is completely online and includes a very quick and fair peer-review system, which is all easy to use. Visit <http://www.dovepress.com/testimonials.php> to read real quotes from published authors.

Submit your manuscript here: <https://www.dovepress.com/infection-and-drug-resistance-journal>