

# A Rare Case of Spontaneous Bladder Rupture in a Herpes Zoster Patient

Jiaguo Huang<sup>1,\*</sup>, Shengcheng Tai<sup>1,\*</sup>, Hongxiang Ding<sup>1</sup>, Li Xu<sup>2</sup>, Runmiao Hua<sup>1</sup>, Yufu Yu<sup>1</sup>, Dikai Mao<sup>1</sup>

<sup>1</sup>Department of Urology, Affiliated Xiaoshan Hospital, Hangzhou Normal University, Hangzhou, People's Republic of China; <sup>2</sup>School of Medicine, Hangzhou Normal University, Hangzhou, People's Republic of China

\*These authors contributed equally to this work

Correspondence: Dikai Mao, Department of Urology, Affiliated Xiaoshan Hospital, Hangzhou Normal University, No. 728 North Yucai Road, Xiaoshan District, Hangzhou, People's Republic of China, Tel +8618967103936, Email Modikai@126.com

**Abstract:** Herpes zoster infection in the sacral area accounts for a considerable number of all herpes zoster cases, and cases of acute urinary retention and defecation disorders caused by herpes zoster infection in the sacral area have been reported. However, no clinical case of spontaneous bladder rupture has been reported. In this report, we describe a 77-year-old male patient with severe complications of spontaneous bladder rupture caused by herpes zoster-associated urinary retention. The patient regained complete bladder function after undergoing surgery to repair the bladder and treatment with antiviral drugs.

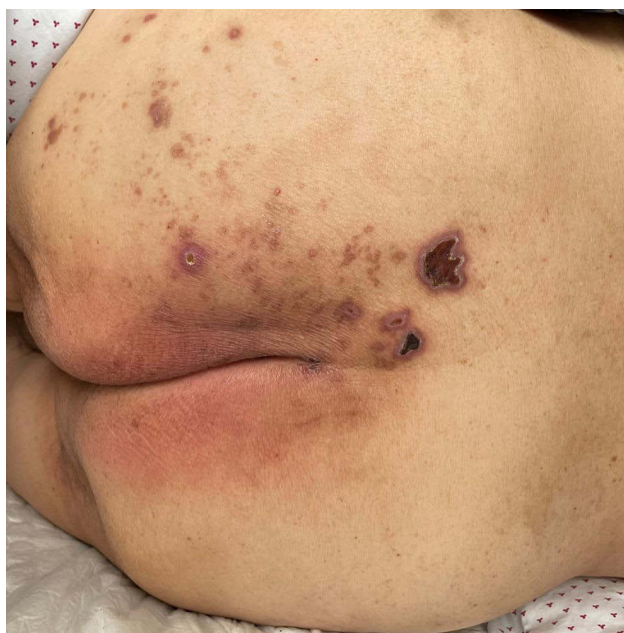**Keywords:** herpes zoster, acute urinary retention, spontaneous bladder rupture, sacral area

## Introduction

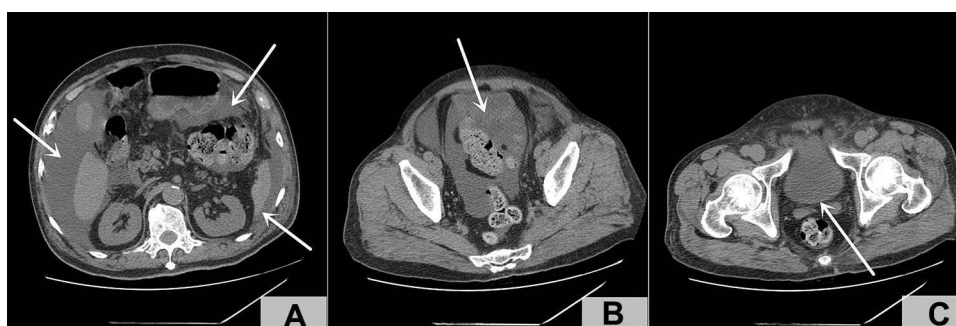
Herpes zoster, also known as shingles, is a skin infection caused by a reactivated latent varicella-zoster virus. Herpes zoster infection in the sacral area accounts for 8% of all herpes zoster infections, and can cause urinary system complications, particularly in elderly and immunocompromised patients.<sup>1-3</sup> Cases of acute urinary retention (AUR) and defecation difficulties caused by herpes zoster infection in the sacral area have been reported,<sup>4-6</sup> but the cases of spontaneous bladder rupture have not been clinically reported. A spontaneous bladder rupture is a rare emergency. Here, we describe a 77-year-old male patient with severe complications of spontaneous bladder rupture caused by herpes zoster-associated urinary retention. The patient underwent surgery to repair the bladder, completed herpes zoster treatment with antiviral drugs, and fully regained bladder function.

## Case Report

The patient was a 77-year-old man with a 10-year history of hypertension and type 2 diabetes. One week prior to admission, he received antiviral, analgesic and nutritional nerve treatment for herpes zoster infection in the sacral area. The patient was treated with 0.3 g of valacyclovir hydrochloride orally twice daily, 0.25 g of diflunisal dispersible tablets orally twice daily and 0.5 mg of methylcobalamin orally three times daily. Seven hours before admission, the patient experienced abdominal pain, obvious abdominal distention, slight shortness of breath, no convulsions, no fear of cold and fever, no cough and expectoration. He had difficulties voiding urine and defecating for 4 days, and had no prior history of trauma. His family brought him to the Emergency Department. On physical examination, he was afebrile, his abdomen was distended and painful, especially in the hypogastric area, with guarding and rebound tenderness, and massive ascites. Herpes was present in the sacral area and partial skin damage (Figure 1). A digital rectal examination revealed an enlarged prostate with no palpable nodule. The vital parameters were abnormal, with a heart rate of 136 beats/min, blood pressure of 170/99 mmHg, and respiratory rate of 22 breaths/min. Abdominal Computer Tomography (CT) revealed a large amount of effusion in the abdomen and pelvis, as well as a large amount of contents in the colon, and a suspected bladder breach (Figure 2A and B). Blood test revealed elevated inflammatory indexes, while blood gas analysis revealed hypoxemia and metabolic acidosis with hyperkalemia. Blood



**Figure 1** Classic shingles appearance in the S2–S4 distribution of the buttock.



**Figure 2** (A) A large amount of effusion in the abdomen (white arrow); (B) Suspected bladder breach (white arrow); (C) The median lobe of the prostate was not protruded into the bladder (white arrow).

biochemical analysis revealed potassium levels of 6.53 mmol/L, creatinine levels of 558  $\mu$ mol/L and D-dimer levels of 6.93 mg/L. The patient was admitted to the intensive care unit for stabilization of vital signs, potassium level reduction, and indwelling catheterization. Indwelling the catheter for 3 hours resulted in a continuous outflow of about 3300 mL bloody urine, thereby significantly relieving the patient's abdominal distension. After injecting the catheter with a diluent consisting 4 mL Methylene Blue injection and 100 mL 0.9% sodium chloride injection, a blue liquid was observed in the abdominal puncture. The bladder water injection test was positive as 500mL of 0.9% sodium chloride injection was injected into the catheter and 150mL of liquid was withdrawn. We decided on laparotomy combined with abdominal CT after considering the diagnosis of intraperitoneal bladder rupture. During the operation, a 2 cm laceration was discovered in the bladder wall, which was connected to the abdominal cavity, and the surrounding intestinal canal was found to be normal. Bladder repair and cystostomy were performed, and the urinary catheter was indwelling. 2 g of cefoperazone sulbactam sodium was administered every 8 hours following the operation. On the first day, the patient vented, and ate liquid food. The patient's renal function creatinine was normal on the 2nd day, the defecation was restored on at the 3rd day, the urinary catheter was removed on the 13th day, and the bladder fistula was removed on the 14th day. The patient's spontaneous micturition was normal. B-ultrasound examination revealed that the prostate measured about 2.5×4.9×3.7 cm. Ultrasonography confirmed that there was no residual urine in the bladder, which could be recovered and discharged smoothly.

## Discussion

Spontaneous bladder rupture is an extremely rare urological emergency that can be life-threatening. The mortality rate is about 50%, with the majority occurring in men.<sup>7</sup> The most common causes are malignant tumors, pelvic penetrating radiotherapy, chronic bladder infection or inflammation, neurogenic bladder, bladder diverticulum, and bladder outlet obstruction.<sup>7,8</sup> Susceptibility conditions are associated with weakening of the bladder wall and/or elevated intravesical pressure. In our case, it appears that the bladder rupture was caused by AUR resulting from a herpes zoster infection in the sacral area and an increase in bladder pressure. The spread of the virus infection into the peripheral nerves, including the sensory nerves that innervate the skin of the sacral area (S2–S4), the bladder, and the distal of the colon, and the parasympathetic motor neurons could explain AUR.<sup>1,9</sup> The patient had a history of benign prostatic hyperplasia (BPH), this was due to a previous physical examination. He had no symptoms of lower urinary tract obstruction and had never used a 5 $\alpha$  reductase inhibitor or  $\alpha$  receptor blocker. B-ultrasound revealed prostatic hyperplasia, but CT did not reveal median lobe protrusion to the bladder (Figure 2C). Therefore, we concluded that there was not significant correlation between BPH and AUR in this case. This spontaneous bladder rupture is often confused with BPH-related mechanical obstruction of the lower urinary tract. Diabetes may be a potential factor. Patients with diabetes often have hypotonic neurogenic bladder, which is mainly manifested by decreased bladder sensation and increased residual urine. After the patient resumed normal urination, a B-ultrasound examination of residual urine revealed that no residual urine remained in the bladder. However, due to diabetes, the patient's bladder sensation may decrease, and at the same time, due to neuralgia caused by herpes zoster, abdominal pain caused by AUR was ignored, resulting in bladder rupture. The patient's micturition and defecation function gradually returned to normal after 2–3 weeks of treatment for herpes zoster, and the recovery time was basically consistent with the time reported in the literature. This case report has the clinical implication of reminding urologists and dermatologists of the possibility of such adverse effects of herpes zoster infection.

## Conclusion

The risk of herpes zoster-associated urinary system dysfunction cannot be ignored. Urgent intervention is required for the acute urinary retention caused by herpes zoster infection in the sacral area.

## Abbreviations

AUR, acute urinary retention; CT, Computer Tomography; BPH, benign prostatic hyperplasia.

## Data Sharing Statement

All data of this study are included in this article. Further enquiries can be directed to the corresponding author.

## Ethics Approval and Patient Consent

Study was approved by Ethical Committee of Affiliated Xiaoshan Hospital, Hangzhou Normal University. The patient in this manuscript has given written informed consent to publication of his case details.

## Author Contributions

All authors made a significant contribution to the work reported, whether that is in the conception, study design, execution, acquisition of data, analysis and interpretation, or in all these areas; took part in drafting, revising or critically reviewing the article; gave final approval of the version to be published; have agreed on the journal to which the article has been submitted; and agree to be accountable for all aspects of the work.

## Disclosure

The authors declare that they have no conflicts of interest in relation to this work.

## References

1. He H, Tang C, Yi X, Zhou W. Herpes zoster-induced acute urinary retention: two cases and literature review. *Niger J Clin Pract.* 2018;21(4):534–537. doi:10.4103/njcp.njcp\_244\_16
2. Au VH, Kazi A, Bruha M, Weiss J. Herpes-zoster associated urinary retention in a 57-year-old immunocompromised male. *Urol Case Rep.* 2021;34:101498. doi:10.1016/j.eucr.2020.101498
3. Chen PH, Hsueh HF, Hong CZ. Herpes zoster-associated voiding dysfunction: a retrospective study and literature review. *Arch Phys Med Rehabil.* 2002;83(11):1624–1628. doi:10.1053/apmr.2002.34602
4. Acheson J, Mudd D. Acute urinary retention attributable to sacral herpes zoster. *Emerg Med J.* 2004;21(6):752–753. doi:10.1136/emj.2003.009928
5. Jakubovicz D, Solway E, Orth P. Herpes zoster: unusual cause of acute urinary retention and constipation. *Can Fam Physician.* 2013;59(3):e146–147.
6. Julia JJ, Chohan HJ. Herpes zoster-associated acute urinary retention: a case report. *Int Urogynecol J Pelvic Floor Dysfunct.* 2007;18(1):103–104. doi:10.1007/s00192-006-0066-1
7. Qiao P, Tian D, Bao Q. Delayed diagnosis of spontaneous bladder rupture: a rare case report. *BMC Womens Health.* 2018;18(1):124. doi:10.1186/s12905-018-0616-y
8. Oh SB, Ahn JH. Successful conservative management of a spontaneous intraperitoneal rupture of bladder diverticulum in a critical patient: a case report. A CARE-compliant article. *Medicine.* 2020;99(7):e19262. doi:10.1097/MD.00000000000019262
9. MacCraith E, Davis NF, Walsh K. Acute urinary retention and constipation precipitated by herpes zoster infection. *BMJ Case Rep.* 2017;2017:bcr–2017.

Infection and Drug Resistance

Dovepress

### Publish your work in this journal

Infection and Drug Resistance is an international, peer-reviewed open-access journal that focuses on the optimal treatment of infection (bacterial, fungal and viral) and the development and institution of preventive strategies to minimize the development and spread of resistance. The journal is specifically concerned with the epidemiology of antibiotic resistance and the mechanisms of resistance development and diffusion in both hospitals and the community. The manuscript management system is completely online and includes a very quick and fair peer-review system, which is all easy to use. Visit <http://www.dovepress.com/testimonials.php> to read real quotes from published authors.

Submit your manuscript here: <https://www.dovepress.com/infection-and-drug-resistance-journal>