

Trichosporon asahii Infection in an Extremely Preterm Infant in China

Na Wang^{1,*}, Jing-yi Tang^{2,*}, Zi Wang³, Liu-yao Wang⁴, Tian-tian Song⁵, Bei-bei Li⁵, Lin Wang⁵

¹Department of Pediatrics, Wuhan No. 1 Hospital, Wuhan, People's Republic of China; ²Department of Pharmacy, Wuhan No. 1 Hospital, Wuhan, People's Republic of China; ³Department of Dermatology, Wuhan Hospital of Traditional Chinese Medicine, Wuhan, People's Republic of China; ⁴Department of Pediatrics, Fuyong People's Hospital, Shenzhen, People's Republic of China; ⁵Department of Neonatology, Union Hospital Affiliated to Tongji Medical College, Huazhong University of Science and Technology, Wuhan, People's Republic of China

*These authors contributed equally to this work

Correspondence: Lin Wang, Department of Neonatology, Union Hospital, Tongji Medical College, Huazhong University of Science and Technology, Wuhan, 430022, People's Republic of China, Email wli1894@yeah.net

Abstract: *Trichosporon asahii* is an uncommon cause of fungal sepsis among neonates, but it is an important life-threatening opportunistic systemic pathogen. We report a case of *T. asahii* sepsis in a 980-g female baby born at 27 weeks of gestation. The extremely preterm initially presented with recurrent feeding intolerance and bloating; she subsequently developed oxygen saturation fluctuations, apnea, and a decreased heart rate. Blood culture was positive, and the causative agent was identified as *T. asahii* by matrix-assisted laser desorption/ionization time-of-flight mass spectrometry (MALDI-TOF MS). According to reported minimum inhibitory concentration (MIC) values, the infant received a high dose of fluconazole (FLC, 12 mg/kg, qod) and was successfully treated.

Keywords: preterm, *Trichosporon asahii*, fluconazole, voriconazole, China

Introduction

Trichosporon spp. yeasts are widely distributed in nature and are part of the normal microbiota of human skin, human gastrointestinal tract, and human respiratory tract.^{1,2} *Trichosporon asahii*, a basidiomycetous yeast, has been recognized as a pathogen able to cause invasive infections in neutropenic cancer patients as well as in critically ill patients undergoing invasive medical procedures and broad-spectrum antibiotic therapy.³ Serious outbreaks of *Trichosporon* spp. infections causing high mortality in extremely preterm infants in Europe, the United States and India have been reported.⁴⁻⁸ Early recognition and management of infections caused by these unusual pathogens in neonates are important because most of these pathogens have unpredictable antifungal susceptibility, and patients have a poor prognosis.⁵ We report a case of *T. asahii* infection that was successfully treated with fluconazole (FLC) in a preterm neonate.

Case Presentation

A 980-g female neonate was vaginally delivered at 27 weeks of gestation. She was one of a set of twins born after in vitro fertilization and embryo transfer (IVF-ET); the mother had gestational diabetes. Her Apgar scores were 5 and 6 at 1 and 5 min, respectively. The infant was transferred to the neonatal intensive care unit (NICU) and then intubated, and surfactant therapy was provided. Nasal intermittent positive pressure ventilation (NIPPV) was applied to assist with breathing. After admission, the neonate was successively given flucloxacillin and cefoperazone sulbactam empirically. As the newborn weighed less than 1 kg and did not respond well to broad-spectrum antibiotic treatment, she was given FLC (3 mg/kg, qod) to prevent candida infection on the 14th day. After the 6th day, the infant experienced recurrent abdominal distension, which was relieved by intermittent fasting and gastrointestinal decompression. However, intermittent

abdominal distension recurred when her daily milk intake was increased to 11 mL per day on the 27th day. NIPPV was applied again on the 38th day for respiratory support because of frequent fluctuations in oxygen saturation, a decreased heart rate, and intermittent apnea. However, there was no significant abnormality on the infant's chest radiograph. Peripherally inserted central catheter (PICC) tip, bone marrow and urine cultures were negative. On the 42nd day, the level of (1→3)- β -d-glucan (BDG) was 1010.9 pg/mL (normal reference range is 0–100.5 pg/mL). The infant underwent blood culture on the 43rd day, and the result was positive on the 46th day. The yeast was identified as *T. asahii* by matrix-assisted laser desorption/ionization time-of-flight mass spectrometry (MALDI-TOF MS). Chain spores and mycelia were observed by Gram staining (Figure 1), and conidia of the joint were observed by cotton blue staining (Figure 2). In vitro susceptibility to nine antifungal agents was analyzed using the broth microdilution-based Sensititre method (Thermo Fisher) (Table 1). Since the most reported MIC values for FLC in *T. asahii* are higher than 2 μ g/mL, we speculated that the strain was sensitive to FLC (MIC 0.5 mg/L). Accordingly, the FLC dose was adjusted to 12 mg/kg, qod to treat the infant's fungal infection. Blood, cerebrospinal fluid, and spinal cord cultures were performed again on the 47th day, and the laboratory reported that the culture results were negative 5 days later. On the 48th day, ultrasound revealed intracranial hemorrhage in the right subependymal area, with patellar echoes of 4.4 \times 2.2 mm. The leukocyte, platelet and hemoglobin levels in the infant decreased; the lowest values were 2.51 \times 10⁹/L for leukocytes, 0.64 \times 10⁹/L for

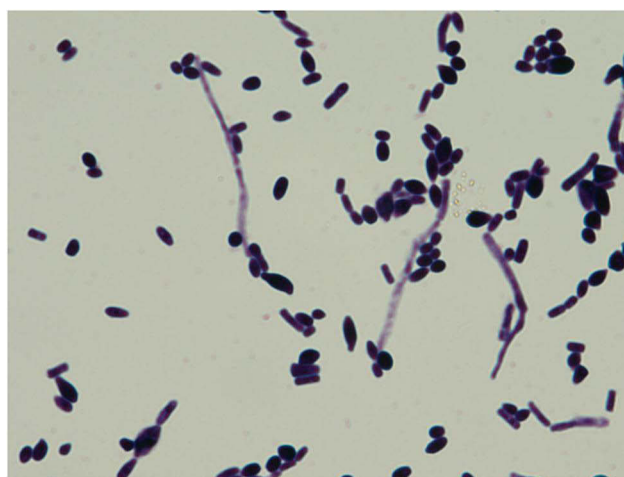


Figure 1 Specimen: Gram's stain (\times 1000, 24h).

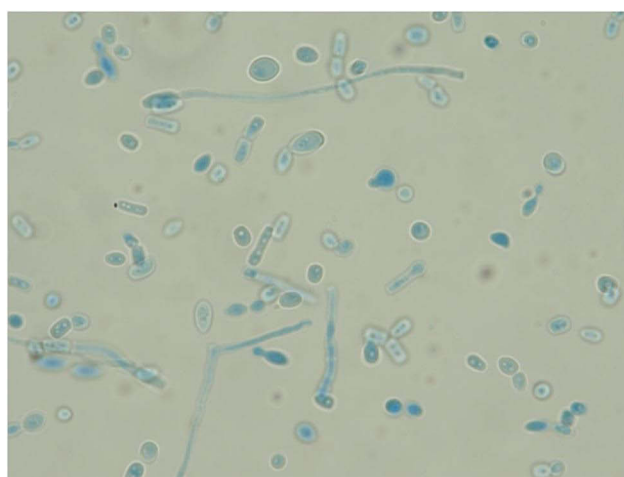


Figure 2 Specimen: lactophenol cotton blue stain (\times 1000, 24h).

Table 1 MICs ($\mu\text{g/mL}$) of Antifungal Agents for *T. asahii* Isolates

Antifungal Agent	MIC ($\mu\text{g/mL}$)
Amphotericin B	0.5
Fluconazole	0.5
Voriconazole	0.06
Itraconazole	0.25
Posaconazole	0.5
5-Flucytosine	8
Micafengin	>8
Carpofungin	>8
Anifengin	>8

Abbreviation: MIC, minimum inhibitory concentration.

neutrophils, 89 g/L for hemoglobin and $50 \times 10^9/\text{L}$ for platelets on the 47th day. Bone marrow biopsy revealed a low red blood cell, high eosinophilic ratio, megakaryocyte maturation disorder, and thrombocytopenia. During this period, the infant experienced a decrease in blood sodium concentration, with a minimum concentration of 119.1 mmol/L. Considering the symptoms and evidence of the pathogen, the infant was diagnosed with *T. asahii* sepsis, and high-dose FLC was continued. After four weeks of antifungal therapy and symptomatic support, the patient's blood culture turned negative, and the vital signs gradually improved. On the 82nd day, the infant was finally discharged. There were no significant abnormalities in her physical and neurological development observed at the one-year follow-up.

Discussion

Trichosporon asahii is a basidiomycetous yeast that is considered an emerging opportunistic pathogen causing disseminated nosocomial infections in neonatal intensive care units (NICUs).⁶ Difficulty in diagnosis, resistance to conventional antifungal drugs and high mortality rate are the main features of *Trichosporon* sepsis.⁵

Although voriconazole (VRC) is the preferred agent for the treatment of *Trichosporon* infection, FLC antifungal therapy based on the MIC was successful in this case. Data supporting susceptibility-guided antifungal therapy are scarce. A recent study found that 273 *T. asahii* isolates had FLC MIC₅₀ and MIC₉₀ values of 2 and 8 mg/L, respectively, while all species had VRC MIC₅₀ and MIC₉₀ values ≤ 0.25 mg/L.⁹ Another multicenter study showed that 108 *T. asahii* isolates had FLC MIC₅₀ and MIC₉₀ values of 4 and 8 mg/L, respectively, while the VRC geometric mean MIC was 0.09 mg/L (MIC₉₀ 0.25 mg/L).¹⁰ Based on the data from in vitro studies and case series,¹¹ it can be speculated that the strain in this case was sensitive to triazoles. Reported MIC_{50%} values for FLC range from 2 to 8 $\mu\text{g/mL}$, while those for VRC range from 0.03 to 1 $\mu\text{g/mL}$; however, the *T. asahii* strain in the blood of the newborn in this case had MIC values of 0.5 $\mu\text{g/mL}$ for FLC and 0.06 $\mu\text{g/mL}$ for VRC. As the MIC values were lower than the proposed epidemiological cutoff values (ECVs) and reported MIC_{50%} ranges, the strain was likely sensitive to both FLC and VRC. The current clinical guidelines recommend VRC for initial antifungal therapy, but FLC is also supported depending on the MIC.¹² Since early FLC antifungal treatment was effective and the isolated strain of *T. asahii* was susceptible, we decided to continue treatment with high-dose FLC (12 mg/kg, qod). After 19 days of treatment, the BDG test turned negative, and the vital signs gradually improved.

The infant in this case initially developed recurrent abdominal distension and feeding intolerance, followed by fluctuations in oxygen saturation, a decreased heart rate and apnea. These symptoms are not specific to any neonatal infectious disease, and a missed diagnosis is likely, resulting in a delay in effective treatment. Samples were collected from the air and surfaces of the neonatal intensive care unit (NICU) and the hands of medical staff to try and identify the source of infection in the environment, but the culture results were all negative. Clinicians should remain vigilant about *Trichosporon* spp. in low birth weight preterm infants with multiple risk factors for fungal infection, such as prolonged broad-spectrum antibiotic use, PICC placement, long-term intravenous nutrition, etc. In neonatal units with high rates (>10%) of invasive candidiasis, intravenous or oral FLC prophylaxis, at 3–6 mg/kg twice weekly for 6 weeks, in

neonates with birth weights <1000 g is recommended in the 2016 edition of the Infectious Diseases Society of America (IDSA) guidelines.¹³ Despite multiple risk factors for fungal infection, there was insufficient evidence to support prophylactic use of FLC in the newborn in the case. It is worth reflecting that long-term use of empirical antifungal therapy in the absence of etiological evidence may induce FLC resistance.

Conclusion

Extremely low birth weight infants with prolonged use of broad-spectrum antibiotics, PICC placement and intravenous nutrition should be considered at risk for *T. asahii* infection. VRC or FLC contingent on the MIC against *T. asahii* is still recommended.

Ethics Approval and Informed Consent

The newborn's family provided informed consent for this case report to be published. No ethical committee approval was required for this study, as the data were analyzed in a retrospective manner.

Author Contributions

All authors made a significant contribution to the work reported, whether that is in the conception, study design, execution, acquisition of data, analysis and interpretation, or in all these areas; took part in drafting, revising or critically reviewing the article; gave final approval of the version to be published; have agreed on the journal to which the article has been submitted; and agree to be accountable for all aspects of the work.

Funding

This research was supported by a grant from the Natural Science Foundation of Hubei Province (grant no: 2019CFB401); The Medical Research Project of Wuhan Municipal Health Commission (WX20Z35); and Project of Wuhan Pharmaceutical Association (WHPA2022000007).

Disclosure

No potential conflicts of interest are reported by the authors.

References

1. Cho O, Matsukura M, Sugita T. Molecular evidence that the opportunistic fungal pathogen *Trichosporon asahii* is part of the normal fungal microbiota of the human gut based on rRNA genotyping. *Int J Infect Dis.* 2015;39:87–88. doi:10.1016/j.ijid.2015.09.009
2. Colombo AL, Padovan AC, Chaves GM. Current knowledge of *Trichosporon spp.* and Trichosporonosis. *Clin Microbiol Rev.* 2011;24(4):682–700. doi:10.1128/CMR.00003-11
3. Padovan ACB, Rocha WPDS, Toti ACM, et al. Exploring the resistance mechanisms in *Trichosporon asahii*: triazoles as the last defense for invasive trichosporonosis. *Fungal Genet Biol.* 2019;133:103267. doi:10.1016/j.fgb.2019.103267
4. Foster CE, Edwards MS, Brackett J, et al. Trichosporonosis in pediatric patients with a hematologic disorder. *J Pediatric Infect Dis Soc.* 2018;7(3):199–204. doi:10.1093/jpids/pix031
5. Basu S, Tilak R, Kumar A. Multidrug-resistant *Trichosporon*: an unusual fungal sepsis in preterm neonates. *Pathog Glob Health.* 2015;109(4):202–206. doi:10.1179/2047773215Y.0000000019
6. Vashishtha VM, Mittal A, Garg A. A fatal outbreak of *Trichosporon asahii* sepsis in a neonatal intensive care Unit. *Indian Pediatr.* 2012;49(9):745–747. doi:10.1007/s13312-012-0137-y
7. Téllez-Castillo CJ, Gil-Fortuño M, Centelles-Sales I, et al. Infección fatal por *Trichosporon asahii* en una recién nacida de pretérmino [Trichosporon asahii fatal infection in a preterm newborn]. *Rev Chilena Infectol.* 2008;25(3):213–215. doi:10.4067/S0716-10182008000300015
8. Pereira DN, Nader SS, Nader P, et al. Disseminated *Trichosporon spp* infection in preterm newborns: a case report. *J Pediatr.* 2009;85(5):459–461. doi:10.2223/JPED.1923
9. Francisco EC, de Almeida Junior JN, de Queiroz Telles F, et al. Species distribution and antifungal susceptibility of 358 *Trichosporon* clinical isolates collected in 24 medical centres. *Clin Microbiol Infect.* 2019;25(7):909.e1–909.e5. doi:10.1016/j.cmi.2019.03.026
10. Guo LN, Yu SY, Hsueh PR, et al. Invasive infections due to trichosporon: species distribution, genotyping, and antifungal susceptibilities from a multicenter study in China. *J Clin Microbiol.* 2019;57(2):e01505–18. doi:10.1128/JCM.01505-18
11. Liao Y, Lu X, Yang S, Luo Y, Chen Q, Yang R. Epidemiology and outcome of *Trichosporon Fungemia*: a review of 185 Reported Cases From 1975 to 2014. *Open Forum Infect Dis.* 2015;2(4):ofv141. doi:10.1093/ofid/ofv141
12. Chen SC, Perfect J, Colombo AL, et al. Global guideline for the diagnosis and management of rare yeast infections: an initiative of the ECMM in cooperation with ISHAM and ASM [published correction appears in Lancet Infect Dis. 2021 Dec;21(12):e363]. *Lancet Infect Dis.* 2021;21(12):e375–e386. doi:10.1016/S1473-3099(21)00203-6
13. Pappas PG, Kauffman CA, Andes DR, et al. Clinical practice guideline for the management of candidiasis: 2016 update by the Infectious Diseases Society of America. *Clin Infect Dis.* 2016;62(4):e1–e50. doi:10.1093/cid/civ933

Infection and Drug Resistance

Dovepress

Publish your work in this journal

Infection and Drug Resistance is an international, peer-reviewed open-access journal that focuses on the optimal treatment of infection (bacterial, fungal and viral) and the development and institution of preventive strategies to minimize the development and spread of resistance. The journal is specifically concerned with the epidemiology of antibiotic resistance and the mechanisms of resistance development and diffusion in both hospitals and the community. The manuscript management system is completely online and includes a very quick and fair peer-review system, which is all easy to use. Visit <http://www.dovepress.com/testimonials.php> to read real quotes from published authors.

Submit your manuscript here: <https://www.dovepress.com/infection-and-drug-resistance-journal>