

# Promising Response to Dabrafenib Plus Trametinib in a Patient with Peritoneal Carcinomatosis from Non Small Lung Cancer Harboring *BRAF* V600E Mutation

Yuri Yagami<sup>1</sup>, Yoshiro Nakahara<sup>1</sup>, Hideaki Manabe<sup>1</sup>, Hiroki Yamamoto<sup>1</sup>, Sakiko Otani<sup>1</sup>, Takashi Sato<sup>1</sup>, Satoshi Igawa<sup>1</sup>, Masaru Kubota<sup>2</sup>, Jiichiro Sasaki<sup>3</sup>, Katsuhiko Naoki<sup>1</sup>

<sup>1</sup>Department of Respiratory Medicine, Kitasato University School of Medicine, Sagami-hara, Kanagawa, 252-0374, Japan; <sup>2</sup>School of Allied Health Sciences, Kitasato University, Sagami-hara, Kanagawa, 252-0374, Japan; <sup>3</sup>Research and Development Center for New Medical Frontiers, Kitasato University School of Medicine, Sagami-hara, Kanagawa, 252-0374, Japan

Correspondence: Yoshiro Nakahara, Department of Respiratory Medicine, Kitasato University School of Medicine, 1-15-1 Kitazato, Minami-ku, Sagami-hara, Kanagawa, 252-0374, Japan, Tel +81- 42-778-8506, Fax +81- 42-778-6412, Email md100062@kitasato-u.ac.jp

**Background:** The prognosis of peritoneal carcinomatosis in patients with lung cancer is poor. However, some cases of peritoneal carcinomatosis from lung cancer harboring specific gene alterations have responded to molecular targeted drugs. B-Raf proto-oncogene (*BRAF*) mutations occur in about 2–4% of NSCLCs, with about half of these cases having the *BRAF* V600E mutation. Concomitant inhibition of *BRAF* with dabrafenib and inhibition of the downstream mitogen-activated protein kinase with trametinib showed efficacy in NSCLC patients with the *BRAF* V600E mutation. Herein, we report a patient with peritoneal carcinomatosis from lung cancer with the *BRAF* V600E mutation who responded to dabrafenib plus trametinib.

**Case Presentation:** A 67-year-old Japanese male never-smoker was diagnosed with stage IA3 lung adenocarcinoma. He underwent thoroscopic left lower lobectomy but developed recurrence of the cancer with peritoneal carcinomatosis 33 months after the operation. An Oncomine Dx target test of the resected specimen was positive for the *BRAF* V600E mutation. He was started on dabrafenib 150 mg twice per day and trametinib 2 mg once per day. He had a good clinical response to dabrafenib/trametinib therapy with resolution of abdominal distention. He continued dabrafenib/trametinib treatment without disease progression for 7 months, with no severe adverse effects.

**Conclusion:** This case highlights the importance of assessing genetic alterations in lung cancer patients with peritoneal carcinomatosis and treating them with appropriate molecular targeted drugs.

**Keywords:** *BRAF* V600E mutation, dabrafenib, lung cancer, peritoneal carcinomatosis, trametinib

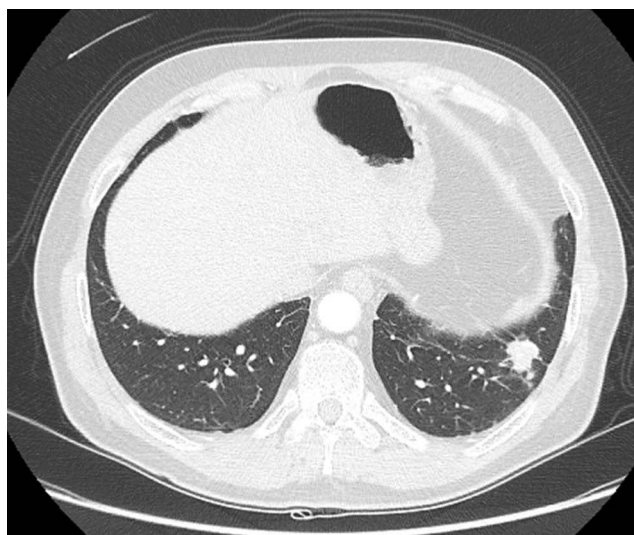
## Introduction

Lung cancer is one of the most frequent malignancies worldwide. About 35% of patients with lung cancer are diagnosed with distant metastases, with the lung, bone, liver, brain, and adrenal glands being the most common sites. Peritoneal carcinomatosis, defined as metastases to the peritoneum, is rare in patients with lung cancer, but may cause intestinal perforation and obstruction, and has been reported to have a poor prognosis.<sup>1,2</sup>

Various recently developed molecular targeted drugs have shown efficacy in treating peritoneal carcinomatosis from lung cancer in some patients.<sup>3–6</sup> Herein, we report the case of a lung cancer patient with peritoneal carcinomatosis harboring the V600E mutation in the B-Raf proto-oncogene (*BRAF*) who was treated effectively with dabrafenib plus trametinib.

## Case Report

A 67-year-old Japanese male never-smoker was diagnosed with stage IA3 lung adenocarcinoma of the left upper lobe (Figure 1). He had no relevant family history. He underwent thoroscopic left lower lobectomy. However, ascites accumulated 33 months

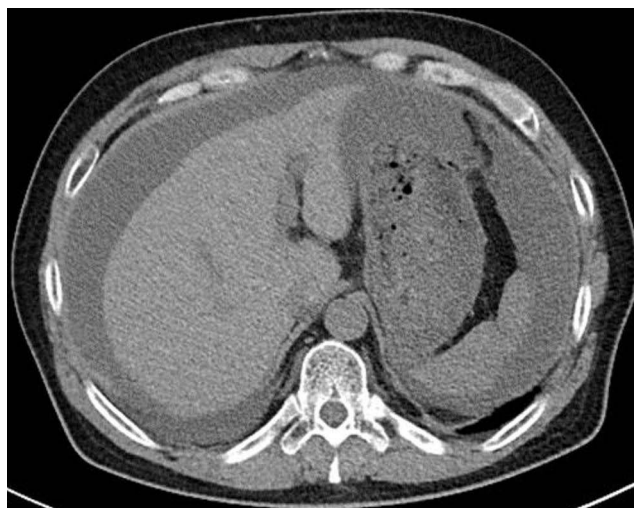


**Figure 1** Chest computed tomography showing a nodular shadow in the left upper lobe.

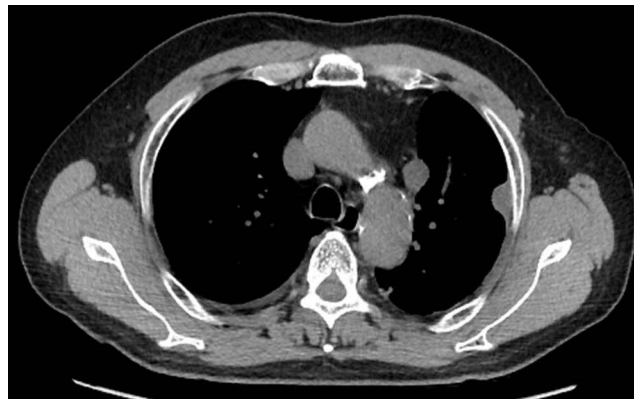
after the operation (Figure 2), paratracheal lymph node metastasis and pleural dissemination emerged (Figure 3), and positron emission tomography-computed tomography (CT) showed accumulation in the bronchial and axillary lymph nodes (Figure 4). Immunohistochemical examination of the peritoneal ascites was positive for napsin A and thyroid transcription factor-1, and he was accordingly diagnosed with postoperative recurrence of lung adenocarcinoma.

Epidermal growth factor receptor (*EGFR*) mutation and anaplastic lymphoma kinase (*ALK*) rearrangement analyses of resected lung tissue were both negative. Immunohistochemistry also revealed programmed death-ligand 1 expression of 20% (tumor-proportion score) and the patient was therefore started on carboplatin (5 area under the curve, day 1, every 3 weeks), pemetrexed (500 mg/m<sup>2</sup> day 1, every 3 weeks), and pembrolizumab (200 mg/body, day1, every 3 weeks). However, he developed a rash 2 weeks after the initiation of chemotherapy, which was considered to be an adverse event of the chemotherapy, and the treatment was therefore stopped. Two months after the discontinuation of chemotherapy, stomach bloating because of ascites appeared. The cytology from the ascites showed that the cause of the ascites is peritoneal carcinomatosis from lung cancer. The patient's ascites increased despite internal use of furosemide, and drainage of 3.0 L of ascites was carried out every 2 weeks to relieve the bloating.

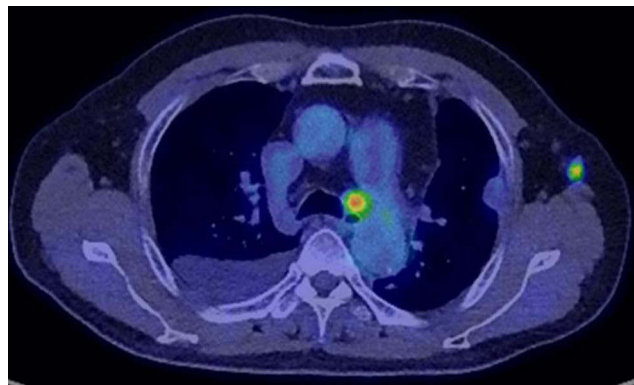
An Oncomine Dx target test of the resected specimen was positive for the *BRAF* V600E mutation. The patient was thus started on dabrafenib 150 mg twice per day and trametinib 2 mg once per day. Two days later, he developed a fever



**Figure 2** Chest computed tomography showing ascites 33 months after operation.



**Figure 3** Chest computed tomography showing paratracheal lymph node metastasis and pleural dissemination.

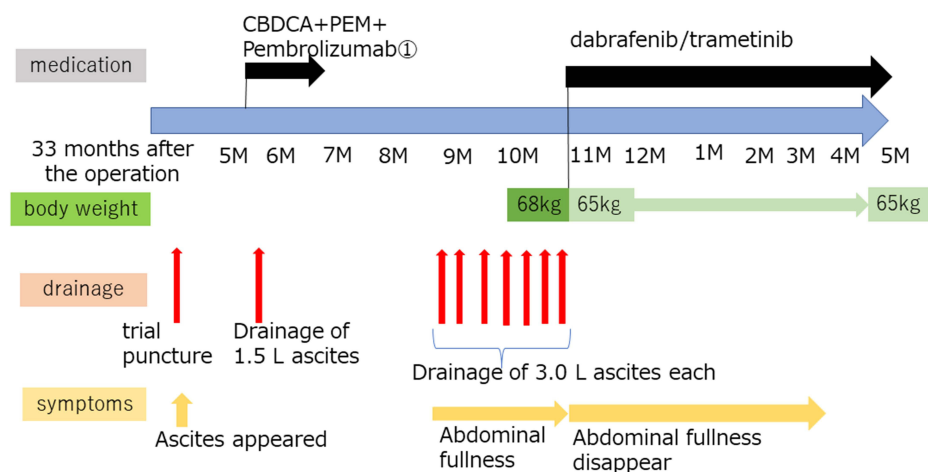


**Figure 4** Positron emission tomography-computed tomography showing accumulation in the bronchial and axillary lymph nodes.

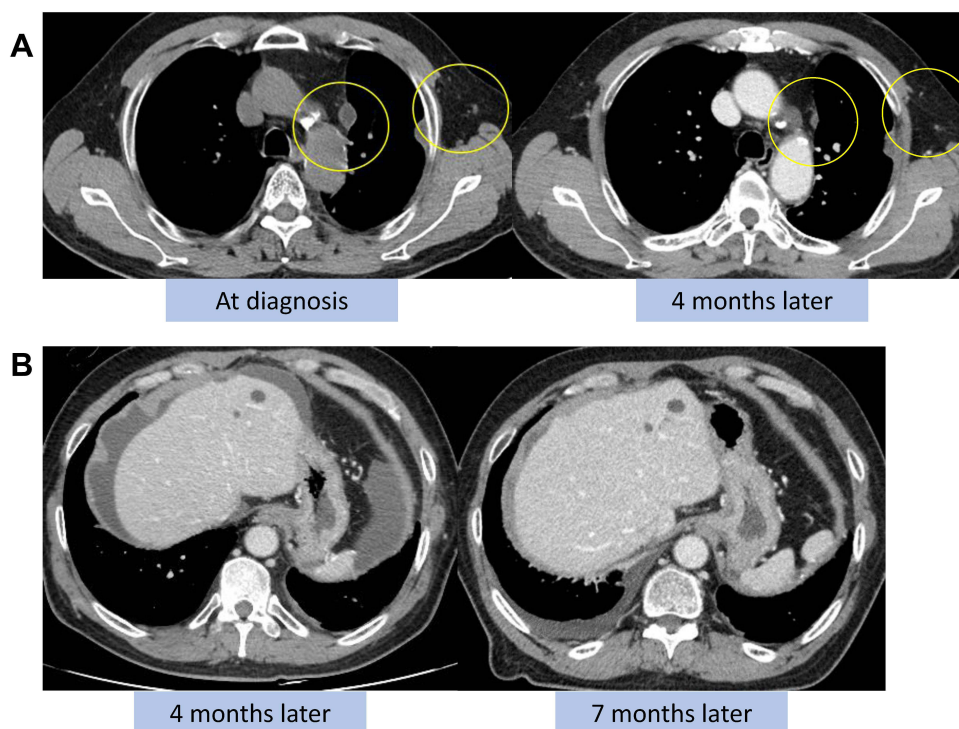
of 38°C, with no sign of infection, which disappeared the day after a withdrawal of the drugs. We considered that the fever was due to dabrafenib and trametinib therapy.

The drugs were restarted without dose reduction and the patient had a good clinical response to dabrafenib and trametinib therapy. His abdominal distention resolved, and drainage of peritoneal ascites was no longer required (Figure 5). Chest CT

### 【 Frequency of ascites drainage and progress of symptoms 】



**Figure 5** Clinical course of patient with peritoneal carcinomatosis of lung cancer.



**Figure 6** Chest computed tomography showing (A) shrinkage of paratracheal and axillary lymph nodes and (B) decreased peritoneal fluid after initiation of dabrafenib/trametinib therapy.

after the initiation of dabrafenib and trametinib therapy revealed reduced paratracheal and axillary lymph nodes (Figure 6A) and decreased peritoneal ascites (Figure 6B).

Dabrafenib and trametinib treatment were continued for 7 months with no disease progression or severe adverse events and even now continued oral administration. Institutional approval is not required for this case report.

## Discussion

Peritoneal carcinomatosis from lung cancer is relatively rare but its prognosis is poor, and novel treatment strategies are thus needed to improve patient outcomes. Satoh et al reported that only 1.2% of 1041 patients with advanced lung cancer developed peritoneal carcinomatosis during their clinical course, with a median survival time from the diagnosis of peritoneal carcinomatosis of 2 months.<sup>1</sup> Patil et al found that 8% (33/410) of lung cancer patients in their study developed peritoneal metastases during the course of their disease.<sup>2</sup>

Molecular targeted drugs have recently improved overall survival (OS) and progression-free survival (PFS) in lung cancer patients with specific gene alterations, such as *EGFR*, *ALK*, c-ros oncogene 1 (*ROS1*), and *BRAF*. Abbate et al reported that 60 patients with carcinomatous peritonitis from lung cancer included 11% of *EGFR*-positive, 9% of *ALK*-positive, and 1.5% of *ROS-1*-positive patients.<sup>3</sup> They also demonstrated better OS following treatment with an *EGFR*-tyrosine kinase inhibitor (TKI) in *EGFR*-mutated compared with *EGFR*-wild-type/unknown patients (8 months vs 3.5 months, respectively).<sup>3</sup> Tani et al reported that median OS rates in patients with peritoneal carcinomatosis from non-small cell lung cancer (NSCLC) treated with a cytotoxic agent and an *EGFR/ALK* TKI were 6.2 and 20.9 months, respectively (hazard ratio, 0.10; 95% confidence interval [CI], 0.042–0.25;  $P < 0.0001$ ).<sup>4</sup>

Kobayashi et al reported on a 61-year-old female never-smoker with peritoneal carcinomatosis of *EGFR*-mutation-positive lung adenocarcinoma.<sup>5</sup> Her peritoneal carcinomatosis improved after treatment with afatinib (20 mg once daily), with no symptomatic recurrence or disease exacerbation at 12 months after afatinib initiation.<sup>5</sup> Furthermore, Kazakova et al reported a 56-year-old man with peritoneal carcinomatosis of *ROS1*-rearranged lung adenocarcinoma who responded well to crizotinib, with no disease progression after 6 months.<sup>6</sup> These reports highlight the importance of molecular testing in patients with

carcinomatous peritonitis from lung cancer, and the potential ability of molecular targeted drugs to improve symptoms and extend survival in these patients.

*BRAF* mutations occur in about 2–4% of NSCLCs, with about half of these cases having the *BRAF* V600E mutation, which involves the substitution of glutamate for valine at codon 600 in exon 15 of the *BRAF* kinase domain.<sup>7</sup> The *BRAF* V600E mutation activates the Raf-extracellular signal-regulated kinase signaling pathway, promotes cell growth and proliferation, and inhibits apoptosis. Concomitant inhibition of *BRAF* with dabrafenib and inhibition of the downstream mitogen-activated protein kinase with trametinib thus showed efficacy in NSCLC patients with the *BRAF* V600E mutation.<sup>8</sup>

An open-level Phase 2 trial of dabrafenib plus trametinib in patients with *BRAF* V600E-mutant metastatic NSCLC found an overall response rate of 64% (95% CI, 46–79%) and median PFS of 10.9 months (95% CI, 7.0–16.6) in previously untreated patients.<sup>9</sup> Furthermore, patients with *BRAF* V600E-mutant metastatic NSCLC who received second-line or later treatment with dabrafenib plus trametinib showed an overall response rate of 63.2% (95% CI, 49.3–75.6%) and median PFS of 8.6 months (95% CI, 5.2–19.1).<sup>10</sup>

Vascular endothelial growth factor (VEGF) plays a significant role in the accumulation of malignant pleural effusion and ascites. Verheul et al reported malignant ascites and pleural effusion contained high levels of biologically active VEGF, and concluded that blockade of VEGF might benefit cancer patients with recurrent ascites or pleural effusion.<sup>11</sup> Furthermore, Hsu et al reported three lung cancer cases with malignant ascites who received the combination therapy with bevacizumab, and all of the patients showed a good and marked decrease in ascites.<sup>12</sup> Thus, we took cytotoxic chemotherapy with bevacizumab into consideration for the treatment of this patient. However, he had pulmonary artery thrombosis, we avoided bevacizumab, and chose dabrafenib plus trametinib.

The current patient showed a remarkable response to dabrafenib plus trametinib, with an improvement in the symptoms associated with peritoneal carcinomatosis. This highlights the importance of assessing the genetic alterations in lung cancer patients with peritoneal carcinomatosis and treating them with appropriate molecular targeted drugs.

## Conclusion

Conclusion, to the best of our knowledge, this is the first case report to show the efficacy of dabrafenib plus trametinib in a lung cancer patient with peritoneal carcinomatosis harboring the *BRAF* V600E mutation. This case indicates the need to assess the specific genetic alterations in patients with lung cancer with peritoneal carcinomatosis, and treat them with suitable molecular targeted drugs. These findings should be confirmed in future prospective clinical trials.

## Consent Statement

The patient provided consent for publication of this Case Report.

## Acknowledgments

We acknowledge the support of ASCA Corporation in the editing of a draft of this manuscript.

## Disclosure

Dr Yoshiro Nakahara reports personal fees from ONO PHARMACEUTICAL CO., LTD., Takeda Pharmaceutical Company Limited, Eli Lilly Japan K.K, Kyowa Kirin Co., Ltd., Boehringer Ingelheim GmbH, and AstraZeneca; grants, personal fees from Bristol-Myers Squibb, outside the submitted work. Dr Takashi Sato reports personal fees from Chugai Pharmaceutical, Bristol Myers Squibb, Boehringer Ingelheim, Ono Pharmaceutical, AstraZeneca, Nippon Kayaku, and Eli Lilly, outside the submitted work. Prof. Dr. Katsuhiko Naoki reports grants and/or personal fees from Chugai Pharmaceutical, ONO PHARMACEUTICAL, Nippon Boehringer Ingelheim, Taiho Pharmaceutical, Parexel International Inc, AstraZeneca, and Bristol-Myers Squibb, outside the submitted work. The authors report no other conflicts of interest pertaining to this work.

## References

1. Satoh H, Ishikawa H, Yamashita YT, et al. Peritoneal carcinomatosis in lung cancer patients. *Oncol Rep.* 2001;5:1305–1307. doi:10.3892/or.8.6.1305
2. Patil T, Aisner DL, Noonan SA, et al. Malignant pleural disease is highly associated with subsequent peritoneal metastasis in patients with stage IV non-small cell lung cancer independent of oncogene status. *Lung Cancer.* 2016;96:27–32. doi:10.1016/j.lungcan.2016.03.007

3. Abbate MI, Cortinovis DL, Tiseo M, et al. Peritoneal carcinomatosis in non-small-cell lung cancer: retrospective multicentric analysis and literature review. *Future Oncol*. 2019;15:989–994. doi:10.2217/fon-2018-0469
4. Tani T, Nakachi I, Ikemura S, et al. Clinical characteristics and therapeutic outcomes of metastatic peritoneal carcinomatosis in non-small-cell lung cancer. *Cancer Manag Res*. 2021;13:7497–7503. doi:10.2147/CMAR.S330103
5. Kobayashi H, Wakuda K, Takahashi T. Effectiveness of Afatinib in lung cancer with paralytic ileus due to peritoneal carcinomatosis. *Respirol Case Rep*. 2016;4:e00197. doi:10.1002/rcr2.197
6. Kazakova V, Velasco SVA, Perepletchikov A, et al. ROS1-rearranged lung adenocarcinoma with peritoneal carcinomatosis on initial presentation. *BMJ Case Rep*. 2020;13:e233864. doi:10.1136/bcr-2019-233864
7. Naoki K, Chen TH, Richards WG, et al. Missense mutations of the BRAF gene in human lung adenocarcinoma. *Cancer Res*. 2002;62:7001–7003.
8. Cardarella S, Ogino A, Nishino M, et al. Clinical, pathologic, and biologic features associated with BRAF mutations in non-small cell lung cancer. *Clin Cancer Res*. 2013;19:4532–4540. doi:10.1158/1078-0432.CCR-13-0657
9. Planchard D, Smit EF, Groen HJM, et al. Dabrafenib plus trametinib in patients with previously untreated BRAF V600E-mutant metastatic non-small-cell lung cancer: an open-label, phase 2 trial. *Lancet Oncol*. 2017;18:1307–1316. doi:10.1016/S1470-2045(17)30679-4
10. Planchard D, Besse B, Groen HJM, et al. Dabrafenib plus trametinib in patients with previously treated BRAF(V600E)-mutant metastatic non-small cell lung cancer: an open-label, multicentre phase 2 trial. *Lancet Oncol*. 2016;17:984–993. doi:10.1016/S1470-2045(16)30146-2
11. Verheul HM, Hoekman K, Jorna AS, et al. Targeting vascular endothelial growth factor blockade: ascites and pleural effusion formation. *Oncologist*. 2000;5(Suppl 1):45–50. doi:10.1634/theoncologist.5-suppl\_1-45
12. Hsu JF, Lee YL, Chang HL, et al. Clinical efficacy of concurrent bevacizumab for malignant ascites in nonsquamous cell carcinoma of the lung. *Asia Pac J Clin Oncol*. 2019;15:e126–e131. doi:10.1111/ajco.13131

## OncoTargets and Therapy

Dovepress

## Publish your work in this journal

OncoTargets and Therapy is an international, peer-reviewed, open access journal focusing on the pathological basis of all cancers, potential targets for therapy and treatment protocols employed to improve the management of cancer patients. The journal also focuses on the impact of management programs and new therapeutic agents and protocols on patient perspectives such as quality of life, adherence and satisfaction. The manuscript management system is completely online and includes a very quick and fair peer-review system, which is all easy to use. Visit <http://www.dovepress.com/testimonials.php> to read real quotes from published authors.

Submit your manuscript here: <https://www.dovepress.com/oncotargets-and-therapy-journal>