

# Displacement of Hyaluronic Acid Dermal Filler Mimicking a Cutaneous Tumor: A Case Report

Fabiano Nadson Magacho-Vieira <sup>1,2,\*</sup>, Aline Palitot Santana <sup>1,\*</sup>

<sup>1</sup>Magacho Institute for Health Education, Fortaleza, CE, Brazil; <sup>2</sup>Department of Clinical, Aesthetic and Surgical Dermatology, Batista Memorial Hospital, Fortaleza, CE, Brazil

\*These authors contributed equally to this work

Correspondence: Fabiano Nadson Magacho-Vieira, Clínica Magacho - Avenida Desembargador Moreira, 1300, Sala 1419 - Torre Norte, Fortaleza, CE, 60170-002, Brasil, Tel/Fax +55 85 3246 0829, Email [dr.fabiano@clinicamagacho.com.br](mailto:dr.fabiano@clinicamagacho.com.br)

**Abstract:** There has been considerable growth in the number of cosmetic injectable procedures in recent years. Consequently, physicians in general are seeing a greater number of patients who have previously had cosmetic implants. These patients often fail to mention or do not admit to having had previous cosmetic procedures, conditions that should be noted in their medical histories. In this article, the authors report a rare case of hyaluronic acid filler displacement resulting from injection in the nasal radix region that had been administered 10 months prior, which the patient failed to mention. The filler migration mimicked facial tumors, entangling an otherwise easy case and it was only recognized with the use of dermatological ultrasound. This serves as a warning and a reminder to include complications from cosmetic procedures in diagnostic hypotheses. Physicians need to be vigilant, question their patients' medical histories, and be familiar with diagnostic imaging options. The presence of dermal fillers should always be considered in cutaneous tumor lesions, since they can last for months to years, or be present in locations distant from the site of application.

**Keywords:** dermatology, filler migration, ultrasound, diagnosis

## Introduction

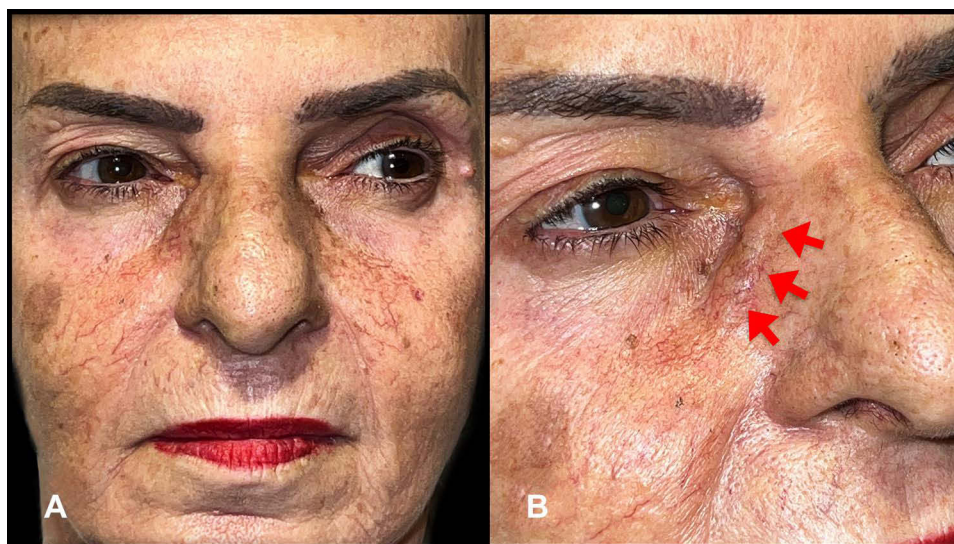Physicians are progressively receiving an increasing number of patients previously treated with cosmetic implants, who often fail to spontaneously report or even remember information about the procedure or the product used. Against this background, it is essential to include questions in the medical anamnesis about the existence of previous aesthetic procedures, in addition to also directing the physical examination for this purpose.<sup>1</sup>

Herein, we describe a rare case of migration by displacement of a hyaluronic acid filler, which was not reported by the patient and mimicked a rapidly growing tumor, in an unusual presentation with puzzling diagnostic hypotheses. Dermatological ultrasound suggested the presence of the dermal filler, allowing rapid diagnosis and avoiding more expensive, potentially invasive approaches, such as skin biopsy.

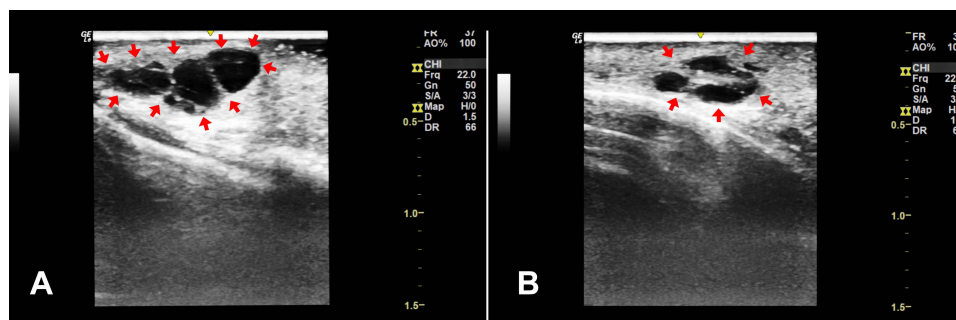
## Case Report

A 71-year-old female patient with significant facial photoaging and no previous comorbidities sought the dermatologist because of a tumor, measuring approximately 15 mm in its greatest axis, lateral to the nasal root on the right dorsal wall, beginning two weeks ago and growing rapidly (Figure 1). Given the nonspecificity of the lesion's characteristics and incongruity with the clinical history, the diagnostic hypotheses were inconsistent and included Merkel's carcinoma; facial granuloma; cutaneous lymphoma; pseudolymphoma; and basal cell carcinoma in nodular presentation.

The high-frequency ultrasound (LOGIQe 22MHz, GE Medical Systems, Jiangsu, China) examination revealed a capsulated, well-defined hypoechoic cylindrical structure in the subcutaneous layer, with inner echoes and few septa (Figure 2), suggesting a hyaluronic acid (mixed with lidocaine) filler pseudocyst.



**Figure 1** Photographs from the patient, shows the tumor lateral to the nasal root on the right dorsal wall. (A) Frontal view; (B) Zoomed oblique view (red arrows highlight the tumor).



**Figure 2** High-frequency ultrasound shows an anechoic cylindrical structure (red arrows) in the subcutaneous layer, with smooth margins, internal echoes and few septa, suggesting a hyaluronic acid pseudocyst. (A) Longitudinal view; (B) Axial view.

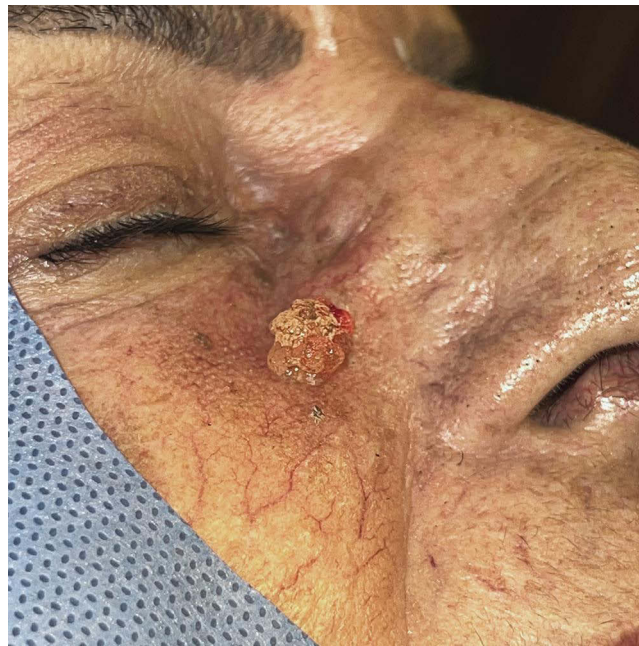When asked again, the patient recalled having hyaluronic acid filler in the nasal region, including the radix, about 10 months ago. She also reported repeated botulinum toxin treatments for the glabellar lines over the past years, but none over the last 6 months.

Given the dermal filler's superficiality and bolus disposition, the treatment was performed with an ultrasound-guided 18-gauge needle puncture, followed by lesion pressure that resulted in a hyaline gel extrusion (Figure 3). The patient was reevaluated in one week for follow-up, with a complete resolution of the condition.

## Discussion

Hyaluronic acid migration is a rare event and refers to the filler's presence at a site remote from the primary injection site. The pathogenesis of the filler's migration has different mechanisms: due to technical error (filler injected directly into the adjacent area, filler that overflows into the adjacent area due to the high volume injected, or filler that moves from the plane of least resistance due to injection under pressure); due to post procedure massage or to muscle activity (causing the filler to move to adjacent areas); due to gravity (downward movement of the material into the adjacent area occurs due to gravitational forces); pressure-induced (e.g., by injection of additional filler).<sup>2-4</sup> A nodule may not appear immediately, as in the case reported here, making it difficult to suspect its related to the dermal filler.

Patient history is enlightening as fillers rarely migrate from their original injection site. Our patient presents with a hyperdynamic glabella, and the proximal section of the nose is particularly subject to the activity of muscles such as the



**Figure 3** Hyaluronic acid extrusion after an ultrasound-guided needle puncture and gentle pressure applied the lesion.

corrugator supercilii and procerus. That strongly implies repeated muscle contractions as responsible for the displacement of the hyaluronic acid injected in the radix, even in the absence of further evidence, such as visualizing a anechoic “tunnel” connecting the two regions.

It is not uncommon to encounter facial fillers in imaging studies, either incidentally or to assess an associated complication,<sup>5</sup> and the use of complementary examinations is an important ally in the diagnostic context of skin-related conditions. Fillers are recognizable on ultrasound and generate different patterns of echogenicity and posterior acoustic artefact.<sup>6</sup> It is a low-cost, convenient, non-invasive, portable and quick test that can be performed at the bedside during the dermatological consultation.<sup>1,7,8</sup> The doppler mode visualizes anatomical changes in the vessels; identifies the presence of vascular involvement; and provides a guided procedure, offering more safety during the application.<sup>9</sup>

The patient described in this case had previously had hyaluronic acid injection in the nasal region, a three-dimensional and somewhat complex anatomical region.<sup>10</sup> The nose is composed of bony and cartilaginous structures, having five layers: skin (1st layer); subcutaneous fat (2nd layer); the nasal superficial musculoaponeurotic system—SMAS (3rd layer); a loose areolar layer that includes deep adipose tissue (4th layer); followed by the perichondrium, connected to the cartilage, or the periosteum, connected to the bone (5th layer).<sup>10–12</sup> The skin of the upper and middle thirds of the nose is thin and pliable, while the skin overlying the tip is thicker and more attached to the cartilaginous structure. The interspace between skin and bone/cartilage averages 4.0 mm, being broader at the nasal root. This also varies according to different races, genders, and ethnicities.<sup>7,10,11</sup>

The terms “liquid rhinoplasty” or “non-surgical rhinoplasty” are used to refer to the skin filling of the nasal region.<sup>13</sup> The procedure has been gaining space in the treatment of shape, correction of asymmetries, and nasal defects. It is a less invasive procedure, performed in an office setting with a brief recovery time and for a low cost, compared to the surgical procedure; thus, it has become very popular.<sup>13,14</sup> Hyaluronic acid is among the most used fillers, due to its safety and biocompatibility.<sup>14</sup>

The application of the filler is carried out with a needle or cannula; blunt cannulas are preferred due to the risk of vascular occlusion in the region. For the same reason, in order to avoid adverse events, administration of the product should be conducted under low pressure and low volume, preferably in the supraperiosteal or supraperichondrial planes.<sup>7,13,15,16</sup> Regarding this last recommendation, however, some authors advocate injecting subcutaneously or in multiple layers.<sup>17–20</sup> Anyway, even small 0.1 cc aliquots of filler can result in inconsistent placement in the

supraperiosteal layer and dispersal of product into other anatomic layers, despite the needle tip remaining in contact with the periosteum.<sup>21</sup>

Detailed clinical history and physical examination are valuable for an adequate approach to patients.<sup>2</sup> With the growing popularity of injectable aesthetic procedures, more and more physicians are receiving previously treated patients and not being provided detailed information about the procedure or the product used. Therefore, it is essential to include questions in the medical history about the existence of previous aesthetic procedures, in addition to directing the physical examination to this purpose.<sup>1</sup> Physicians in general – and dermatologists in particular – need to be aware of and recognize the usual presentations and possible complications of injectable aesthetic procedures, including these in the differential diagnosis of skin complaints.

## Conclusion

Doctors should be able to recognize the potential adverse events caused by invasive cosmetic procedures, identify their multiple presentations, and understand how to manage them. Also, take into account they can occur at sites other than the application site, mimicking severe clinical conditions.

The reported case serves as an alert regarding the inclusion of cosmetic treatments in the diagnostic hypotheses of unusual conditions and highlights the importance of explicit questioning about it. Alongside the high demand for dermal fillers for aesthetic purposes, displaced nodules or granulomas should be a differential diagnosis for recently, fast growing facial tumors. A clear understanding of facial anatomy, filler rheology and indications – as well as the potential complications – is paramount. The use of dermatologic ultrasound represents a safe, low-cost, and good-performance option for a conclusive diagnosis.

## Consent Statement

Written informed consent was obtained from the patient to have the case details and associated images published. Institutional approval was not required.

## Funding

The authors received no financial support for the research, authorship, and publication of this article.

## Disclosure

Dr F.N. Magacho-Vieira is a regular speaker and participates in advisory boards for Galderma. The authors report no other conflicts of interest in this work.

## References

1. Urdiales-Gálvez F, De Cabo-Francés FM, Bové I. Ultrasound patterns of different dermal filler materials used in aesthetics. *J Cosmet Dermatol*. 2021;20(5):1541–1548. doi:10.1111/jocd.14032
2. Kaczorowski M, Nelke K, Luczak K, Haloń A. Filler migration and florid granulomatous reaction to hyaluronic acid mimicking a buccal tumor. *J Craniofac Surg*. 2020;31(1):e78–e79. doi:10.1097/SCS.0000000000005928
3. Lin CH, Chiang CP, Wu BY, Gao HW. Filler migration to the forehead due to multiple filler injections in a patient addicted to cosmetic fillers. *J Cosmet Laser Ther*. 2017;19(2):124–126. doi:10.1080/14764172.2016.1248441
4. Jordan DR, Stoica B. Filler migration: a number of mechanisms to consider. *Ophthalmic Plast Reconstr Surg*. 2015;31(4):257–262. doi:10.1097/IOP.0000000000000368
5. Ginat DT, Schatz CJ. Imaging features of midface injectable fillers and associated complications. *AJNR Am J Neuroradiol*. 2013;34(8):1488–1495. doi:10.3174/ajnr.A3161
6. Wortsman X, Wortsman J, Orlandi C, Cardenas G, Sazunic I, Jemec GB. Ultrasound detection and identification of cosmetic fillers in the skin. *J Eur Acad Dermatol Venereol*. 2012;26(3):292–301. doi:10.1111/j.1468-3083.2011.04047.x
7. Alferthofer MG, Frank K, Ehrl D, et al. The layered anatomy of the nose: an ultrasound-based investigation. *Aesthet Surg J*. 2022;42(4):349–357. doi:10.1093/asj/sjab310
8. Schelke LW, Decates TS, Velthuis PJ. Ultrasound to improve the safety of hyaluronic acid filler treatments. *J Cosmet Dermatol*. 2018;17(6):1019–1024. doi:10.1111/jocd.12726
9. Kim H-J, Youn KH, Kim JS, et al. *Ultrasonographic Anatomy of the Face and Neck for Minimally Invasive Procedures: An Anatomic Guideline for Ultrasonographic-Guided Procedures*. Springer Nature; 2021.
10. Swift A, Remington K, Frank K, Cotofana S. Superficial nasal filler injections-how i do it. *Facial Plast Surg Clin North Am*. 2022;30(2):183–191. doi:10.1016/j.fsc.2022.01.012



11. Saad N, Stallworth CL. Liquid rhinoplasty. *Facial Plast Surg Clin North Am.* **2022**;30(3):357–364. doi:10.1016/j.fsc.2022.03.009
12. Neves JC, Zholtikov V, Cakir B, Coşkun E, Arancibia-Tagle D. Rhinoplasty dissection planes (Subcutaneous, Sub-SMAS, Supra-perichondral, and Sub-perichondral) and soft tissues management. *Facial Plast Surg.* **2021**;37(1):2–11. doi:10.1055/s-0041-1723825
13. Magacho-Vieira FN, Alfertshofer MG, Cotofana S. The deep columellar approach for liquid rhinoplasty - a case series of 511 procedures over 16 years. *Facial Plast Surg Clin North Am.* **2022**;30(2):193–203. doi:10.1016/j.fsc.2022.01.005
14. Bravo BSF, Bravo LG, Mariano Da Rocha C, De Souza SB, Lopes FL, Totti J. Evaluation and proportion in nasal filling with hyaluronic acid. *J Clin Aesthet Dermatol.* **2018**;11(4):36–40.
15. Rosengaus F, Nikolis A. Cannula versus needle in medical rhinoplasty: the nose knows. *J Cosmet Dermatol.* **2020**;19(12):3222–3228. doi:10.1111/jocd.13743
16. Humphrey CD, Arkins JP, Dayan SH. Soft tissue fillers in the nose. *Aesthet Surg J.* **2009**;29(6):477–484. doi:10.1016/j.asj.2009.09.002
17. Bertossi D, Malchiodi L, Albanese M, Nocini R, Nocini P. Nonsurgical rhinoplasty with the novel hyaluronic acid filler VYC-25L: results using a nasal grid approach. *Aesthet Surg J.* **2021**;41(6):NP512–NP520. doi:10.1093/asj/sjaa196
18. Han X, Hu J, Cheng L, Li F. Multiplane hyaluronic acid (EME) in female Chinese rhinoplasty using blunt and sharp needle technique. *J Plast Reconstr Aesthet Surg.* **2015**;68(11):1504–1509. doi:10.1016/j.bjps.2015.06.020
19. Redaelli A. Medical rhinoplasty with hyaluronic acid and botulinum toxin A: a very simple and quite effective technique. *J Cosmet Dermatol.* **2008**;7(3):210–220. doi:10.1111/j.1473-2165.2008.00391.x
20. Rivkin A. Nonsurgical rhinoplasty using injectable fillers: a safety review of 2488 procedures. *Facial Plast Surg Aesthet Med.* **2021**;23(1):6–11. doi:10.1089/fpsam.2020.0291
21. van Loghem JAJ, Humzah D, Kersch M. Cannula versus sharp needle for placement of soft tissue fillers: an observational cadaver study. *Aesthet Surg J.* **2017**;38(1):73–88. doi:10.1093/asj/sjw220

## Clinical, Cosmetic and Investigational Dermatology

Dovepress

### Publish your work in this journal

Clinical, Cosmetic and Investigational Dermatology is an international, peer-reviewed, open access, online journal that focuses on the latest clinical and experimental research in all aspects of skin disease and cosmetic interventions. This journal is indexed on CAS. The manuscript management system is completely online and includes a very quick and fair peer-review system, which is all easy to use. Visit <http://www.dovepress.com/testimonials.php> to read real quotes from published authors.

Submit your manuscript here: <https://www.dovepress.com/clinical-cosmetic-and-investigational-dermatology-journal>