

Choroidal Rupture in the Setting of Multi-Trauma

Jeremy Mathan , Ramin Odisho , Lewis Karapanos, Zelia K Chiu

Department of Ophthalmology, Alfred Hospital, Melbourne, VIC, Australia

Correspondence: Jeremy Mathan, Department of Ophthalmology, The Alfred Hospital, 55 Commercial Road, Melbourne, VIC, 3004, Australia, Tel +619076 2000, Fax +619076 2222, Email jeremy.mathan@eyeandear.org.au

Abstract: Herein the authors call attention to the importance of ophthalmic evaluation in the setting of multi-trauma, particularly with facial and orbital fractures. In institutions such as ours, a tertiary general hospital, where such fractures are initially managed by a non-ophthalmic team such as trauma or maxillofacial surgeons, we would advocate for prompt referral to the ophthalmology team for assessment as described by our case of a choroidal rupture in the setting of multi-trauma.

Keywords: choroidal rupture, multi trauma, facial fracture, orbital fracture, maxillofacial

Introduction

Choroidal rupture occurs as a result of damage to the structures of the eye including the choroid, retinal pigment epithelium and Bruch's membrane. This may occur following trauma involving the globe and possibly in the setting of multi-trauma.¹ Diagnosis can be made on dilated retinal examination in the emergency setting.

In some general hospital institutions, orbital fractures may initially be managed by a non-ophthalmic team. Particularly in the setting of multi-trauma, ophthalmic evaluation including a dilated retinal examination may be delayed as other conditions are managed. A young female patient was admitted with multi-trauma to a tertiary general hospital in Victoria following a motor vehicle accident. The injuries included facial fractures (left inferior orbital wall, medial orbital wall, lateral maxillary wall, frontozygomatic fractures and left pterygoid plate), base of skull fracture, traumatic subarachnoid hemorrhage and subdural hematoma, left scapula fracture, bilateral wrist fractures, left distal femoral and patella fractures.

Specific to the orbit, the patient proceeded to have an internal fixation of her left inferior orbital wall under the maxillofacial team. She had a revision fixation of the orbital floor due to ongoing significant defect post initial surgery. During the inpatient stay, the patient reported visual symptoms of diplopia, blurry vision and scotoma in the left eye and was referred for ophthalmological examination. She reported an ongoing "hair" in her left eye that obscured her vision which persisted despite lubricating eye drops. On examination, visual acuities were 6/6 and 6/30, intraocular pressures were 8mmHg in each eye, and her pupils were reactive with no relative afferent pupillary defect. Her ocular motility findings were significant for a left esodeviation in primary position and very limited abduction. Dilated retinal examination demonstrated a linear pale streak at the macula crossing the fovea (Figure 1). Ocular coherence tomography through the lesion demonstrated discontinuity and disorganization involving Bruch's membrane, RPE as well as the inner retinal layers (Figure 1). At her most recent visit, her visual acuities were 6/5 on the right and 6/36 on the left.

Choroidal rupture can occur following traumatic eye injuries involving a break in the choroid, Bruch's membrane and RPE, with a reportedly higher frequency in closed globe injuries rather than open globe injuries.² Our patient had a macula involving choroidal rupture which is presumed to have poorer visual prognosis.³ Improvement in vision, however, may occur years following surgery, over which time the patient will require ongoing monitoring for choroidal neovascular membrane which is a potential complication following choroidal rupture.² This case demonstrates the importance of ophthalmic evaluation, in particular a dilated retinal examination following facial/orbital trauma, especially in context of a concerning mechanism and multi-trauma where medical attention is diverted to multiple anatomical

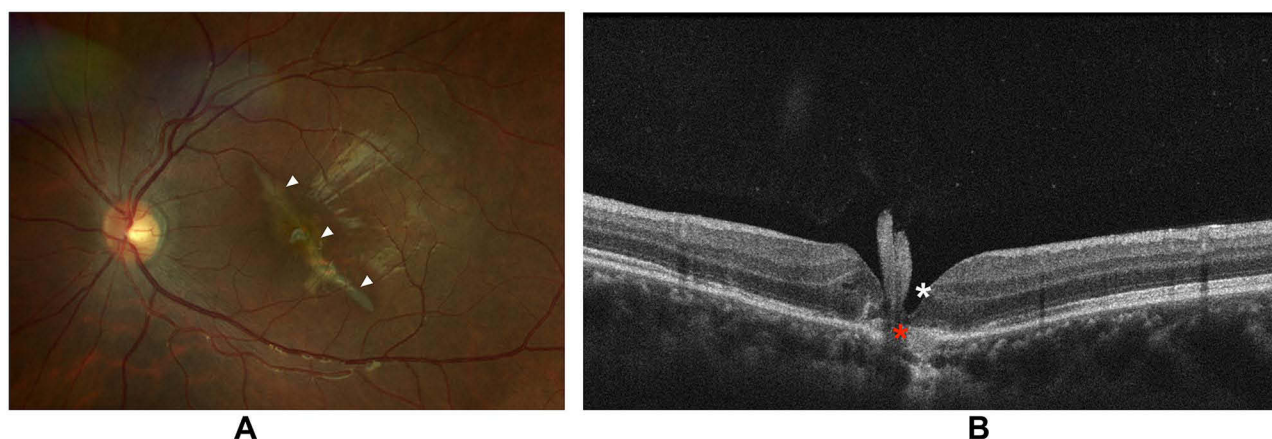


Figure 1 Choroidal rupture. (A) A color fundus photo of the left eye demonstrating an oblique pale streak as highlighted by white arrowheads. (B) Ocular coherence tomography demonstrating full thickness retinal discontinuity, as shown by a white asterisk, including the RPE hyperreflectance and disorganization, as shown by a red asterisk.

Abbreviation: RPE, retinal pigment epithelium.

sites of concern. Careful enumeration of sites affected by trauma is paramount and eye symptoms or concerning examination findings should be escalated in a timely fashion.

Consent for Publication

Written informed consent was obtained from the patient for publication of the details of their medical case and any accompanying images. The research was conducted ethically in accordance with the Declaration of Helsinki. This retrospective review of patient data did not require ethical approval in accordance with local guidelines.

Acknowledgments

The authors would like to acknowledge the Alfred Hospital Orthoptic department for assistance with ophthalmic imaging.

Disclosure

The authors report no conflicts of interest, no financial disclosures for this work.

References

1. Lupidi M, Muzi A, Castellucci G, et al. The choroidal rupture: current concepts and insights. *Surv Ophthalmol*. 2021;66(5):761–770. doi:10.1016/j.survophthal.2021.01.014
2. Patel MM, Chee YE, Elliott D. Choroidal rupture: a review. *Int Ophthalmol Clin*. 2013;53(4):69–78. doi:10.1097/IIO.0b013e31829ced74
3. Ament CS, Zacks DN, Lane AM, et al. Predictors of visual outcome and choroidal neovascular membrane formation after traumatic choroidal rupture. *Arch Ophthalmol*. 2006;124(7):957–966.

Open Access Emergency Medicine

Dovepress

Publish your work in this journal

The Open Access Emergency Medicine is an international, peer-reviewed, open access journal publishing original research, reports, editorials, reviews and commentaries on all aspects of emergency medicine. The manuscript management system is completely online and includes a very quick and fair peer-review system, which is all easy to use. Visit <http://www.dovepress.com/testimonials.php> to read real quotes from published authors.

Submit your manuscript here: <https://www.dovepress.com/open-access-emergency-medicine-journal>

<https://doi.org/10.2147/OAEM.S400513>