

# Extracorporeal Shock Wave Combined with Warm Acupuncture for External Humeral Epicondylitis: A Randomized Clinical Trial

Jingjun Xie<sup>1</sup>, Jinxia Li<sup>2</sup>, Qi Sun<sup>1</sup>

<sup>1</sup>Department of Acupuncture, The First People's Hospital of Huzhou, Zhejiang, 313000, People's Republic of China; <sup>2</sup>Department of Acupuncture, Huzhou Hospital of Traditional Chinese Medicine, Affiliated to Zhejiang Chinese Medical University, Zhejiang, 313000, People's Republic of China

Correspondence: Jinxia Li, Email lijinxia310@163.com

**Objective:** The purpose of this study was to evaluate the clinical efficacy of extracorporeal shock wave combined with warm acupuncture for external humeral epicondylitis.

**Methods:** Eighty-two patients with external humeral epicondylitis were randomly divided into an observation group and a control group. Patients in the control group were treated with extracorporeal shock waves while those in observation group with warm acupuncture on the basis of the control group. Patients in both groups were evaluated by Visual Analogue Scale (VAS), Mayo Elbow Performance Score (MEPS), Disabilities of the Arm, Shoulder and Hand questionnaire (DASH) before and after treatment. The inflammatory factors such as IL-6, IL-10, TNF- $\alpha$  and clinical outcomes were contrasted before and after treatment.

**Results:** There were statistically significant differences in VAS score, MEPS score and DASH score between the two groups before and after treatment ( $P < 0.05$ ), and the improvement of each score in the observation group was more obvious than that in the control group. After treatment, the inflammatory factors of the two groups were lower than those before treatment, and the difference was statistically significant ( $P < 0.05$ ). The decrease of inflammatory factors in the observation group was more obvious than that in the control group. The total effective rate of the observation group was higher than that of the control group, and the difference was statistically significant ( $P < 0.05$ ).

**Conclusion:** Extracorporeal shock wave combined with warm acupuncture could effectively improve the pain symptoms and dysfunction of external humeral epicondylitis and reduce the expression of inflammatory factors, and its effect may be better than that of extracorporeal shock wave treatment alone.

**Clinical Trial Registration:** ChiCTR2200066075.

**Keywords:** extracorporeal shock wave, warm acupuncture, external humeral epicondylitis, a randomized clinical trial

## Introduction

External humeral epicondylitis, also known as tennis elbow, is a sterile inflammatory condition caused by dorsiflexion of the wrist or excessive rotational movements of the forearm,<sup>1-3</sup> the main symptoms of which are elbow pain, weakness and restricted movement.<sup>4,5</sup> In daily life, it usually occurs more frequently in the 30–60 age group. There are many clinical approaches to this condition, such as non-steroidal anti-inflammatory drugs (NSAID), massage and physiotherapy (Including exercise, transcutaneous electric nerve stimulation, etc.), but the symptoms tend to recur after treatment.<sup>6</sup> Extracorporeal shock wave therapy (ESWT), a non-invasive treatment, has been shown to be effective in recent years for skeletal soft tissue disorders including epicondylitis of the humerus. In 2002, food and drug Administration (FDA) approved the use of shock wave in the treatment of lateral epicondylitis of the humerus. ESWT can accelerate the absorption of inflammation in the surrounding tissues when treating the lesion site. It can also promote the production of  $\beta$ -endorphin and inhibit the release of related pain factors such as prostaglandin E2 (PGE2) and 5-hydroxytryptamine (5-HT), thus achieving the purpose of pain relief.<sup>7,8</sup> In this study, warm acupuncture is one of the main methods used in Chinese medicine for the treatment of meridian diseases. The operation consists of inserting one needle around the lesion

and one needle in the center and then twisting it rapidly to make the needle sensation radiate in all directions. Warming acupuncture combined with acupuncture and moxibustion not only plays the role of acupuncture in dredging meridians and reconciling Yin and Yang, but also plays the advantages of moxibustion in warming and dredging meridians and activating blood and qi. Moxibustion on the needle can enhance the sensation of acupuncture, stimulate meridian qi, and play the role of promoting qi and blood circulation, dredging collaterality and relieving pain. A study had verified the effectiveness of acupuncture in treating external humeral epicondylitis, and warm acupuncture combined with the effect of moxibustion has a synergic effect.<sup>9</sup> Our main hypothesis is the complementary synergistic effect of body function mediated by the integration of two different alternative therapies. If this is the case, a combination of warm acupuncture and extracorporeal shock wave therapy in addition to usual care may improve clinical outcomes for patients with external humeral epicondylitis. To observe the clinical effect of integrated Chinese and western medicine in treating this disease, in this study, 82 patients with external humeral epicondylitis were studied retrospectively to determine the therapeutic effectiveness of extracorporeal shock wave mixed with warm acupuncture on external humeral epicondylitis.

## Materials and Methods

### Clinical Information

#### Sample Size Estimation

The sample size was tested by a two-sided hypothesis test, test criterion  $\alpha=0.05$  (two-sided), test validity  $\beta=0.10$ . After a small sample observation, based on the preliminary assessment that the effective rate of the treatment group was 95% and that of the control group was 66%, the minimum sample size required for each group was calculated as 34 cases. With the addition of 20% case prevention losses, there were 41 cases in each group for a total sample size of 82. A total of 82 subjects were recruited and divided into treatment and control groups in a 1:1 ratio to show statistical differences and observe extensibility.

### Sample Sources

Eighty-two patients (finally 1 case in the control group dropped out due to receiving other treatments that might affect the efficacy during the study) with external humeral epicondylitis attended the First People's Hospital of Huzhou from January 2022 to December 2022 were selected. This study was registered as a clinical trial in China (ChiCTR2200066075) and approved by the Ethics Committee of The First People's Hospital of Huzhou (2022KYLL089). The information of the participants about age, duration of the disease and the disease site was collected in Table 1.

### Research Design

A random number table is used to generate a random assignment sequence. Random numbers and grouping information for clinical participants were managed by the research team. Before clinical treatment, random numbers and grouping information were put into consecutively numbered envelopes. Subjects obtained the envelopes in the time sequence of inclusion and observation, and obtained corresponding random numbers and grouping information at the same time. It is difficult to blind patients, but the trial blinded care providers and scale evaluators.

**Table 1** Comparison of General Information Between the Two Groups of Patients

Group	N	Site of Disease		Age (Years $\bar{X} \pm S$ )	Duration of Illness (Months $\bar{X} \pm S$ )
		Left	Right		
Observation group	41	18	23	41.20 $\pm$ 5.63	3.54 $\pm$ 1.34
Control group	40	16	24	42.42 $\pm$ 4.55	3.25 $\pm$ 1.53
$t/\chi^2$ values		0.278		0.264	0.166
P-value		0.586		0.768	0.854

## Diagnostic Criteria

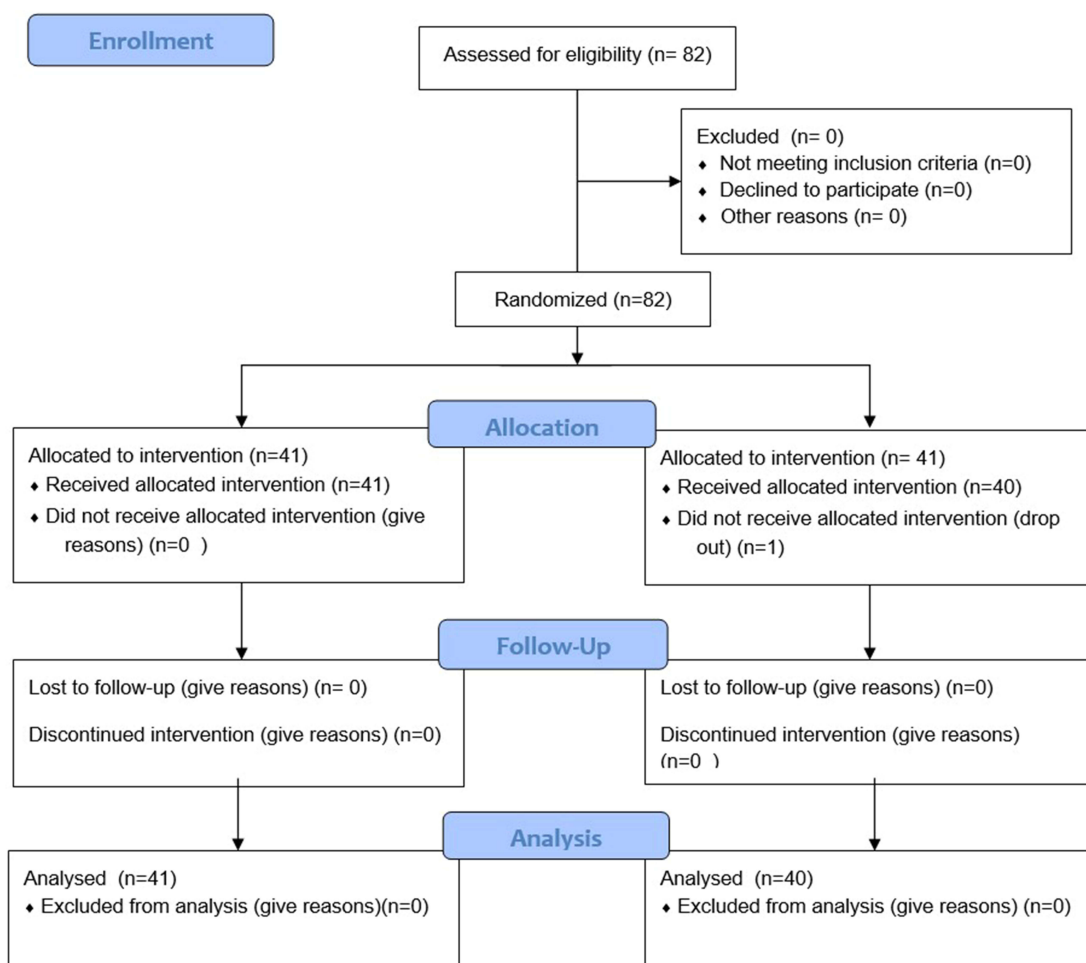
All patients met the diagnostic criteria of the People's Military Medical Publishing House, Practical Orthopaedics.<sup>10</sup> (i) History of chronic injury to the forearm extensor muscles; (ii) pressure pain on the lateral aspect of the elbow joint, and the pain could involve the forearm; (iii) positive tension test of the forearm extensor group and positive Mills sign; (iv) imaging of the elbow joint to exclude bony lesions.

## Inclusion and Exclusion Criteria

Inclusion criteria: ① meeting the above diagnostic criteria; ② duration of disease < 6 months, recurrent episodes; ③ 20–50 years; ④ participation in this study on a voluntary basis and execution of an informed consent form. Exclusion criteria: ① combined with rheumatism, rheumatoid or joint fracture or stiffness; ② combined with serious liver or kidney disease or psychiatric disease; ③ patients who are not treated as prescribed or lost in the middle of the study. The screening process for enrolled patients is detailed in Figure 1.

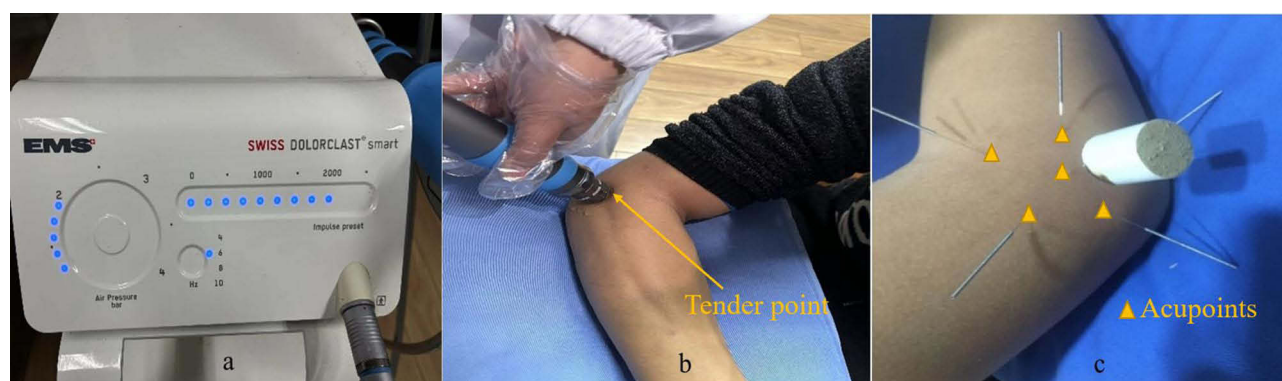
## Treatment Measures

The following models of extracorporeal shock wave devices were used for experimental treatment (Swiss Dolor Clast). The following parameters were used for the treatment: 15mm standard probe (parameter setting pressure 2–3 bar), frequency 4–6 Hz, pulse 1000–2000 times/cycle. An ultrasound gel was used as a coupling substance between the



**Figure 1** CONSORT flow diagram.

**Notes:** CONSORT figure adapted from Schulz KF, Altman DG, Moher D, CONSORT 2010 Statement: Updated Guidelines for Reporting Parallel Group Randomised Trials. *PLoS Med.* 2010;7(3): e1000251. Copyright: © 2010 Schulz et al. Creative Commons Attribution License.<sup>11</sup>



**Figure 2** (a) Extracorporeal shock wave apparatus and parameter settings, (b) Extracorporeal shock wave therapy, (c) Warming acupuncture therapy.

applicator and the patient's skin to reduce tissue resistance. The tender point near the lateral epicondyle of the humerus was selected, and the treatment was performed once a week for 4 weeks, a total of 4 times (Figure 2a and b).

The observation group was treated with warming acupuncture on the basis of the treatment of the control group. Acupuncture treatment was performed by a skilled acupuncturist with 10 years of experience in acupuncture orthopedic rehabilitation. Disposable stainless steel acupuncture needle (0.25×40mm, Suzhou Wuzhong Oriental Acupuncture Equipment Factory, China). (i) One needle was inserted straight at the center of the tenderness point, and the needle was inserted slightly after the arrival of Qi, with a depth of 20–30mm. (ii) A total of 5 needles were inserted at an Angle of 30 degrees around the tender point. The needle tip was aligned with the tender point, and the depth was 20–30 mm. (iii) The moxa sticks were ignited and inserted into the middle straight acupuncture needle, 1 stick each time. The needles were retained for 30min each time, once every other day, three times a week for a total of 4 weeks. (Figure 2c).

## Efficacy Observation

### Primary Outcome Indicator

Visual Analogue Scale (VAS):<sup>12</sup> Pain intensity was assessed by visual analogue scale (VAS) at 10 cm level after wrist dorsal extension, indicated by a score of 0–10, with 0 being no pain and 10 being the most severe pain that is unbearable.

### Secondary Outcome Indicators

1. Mayo Elbow Performance Score (MEPS):<sup>13</sup> includes assessment of elbow pain, range of motion and stability, with a total score of 100 points, excellent: 90 or above; good: 75–89 points; can: 60–74 points; bad: less than 60 points, the lower the score the more severe the dysfunction.
2. Disabilities of the Arm, Shoulder and Hand Scores (DASH)<sup>14</sup>: range from 0 (no disability) to 100 (most severe disability), the higher the score the less functional the score.
3. Inflammatory factor level: Fasting peripheral venous blood was drawn from patients before and immediately after treatment, and serum inflammatory factors such as interleukin 6 (IL-6), interleukin 10 (IL-10) and tumor necrosis factor alpha (TNF-α) were measured.

## Effectiveness Evaluation Indicator

Efficacy assessment criteria: Refer to the “Diagnostic Efficacy Criteria for Chinese Medical Evidence”<sup>15</sup> for assessment. Efficacy index is calculated by dividing the pre-treatment symptom score by the post-treatment symptom score, multiplied by 100%. Clinical control: The patient's symptoms and signs have disappeared or largely disappeared, and the efficacy index is  $\geq 90\%$ . Significantly effective: the patient's symptoms and signs improved significantly,  $70\% \leq$  efficacy index  $< 90\%$ . Effective: The patient's symptoms and signs have improved,  $30\% \leq$  efficacy index  $< 70\%$ . Ineffective: no significant improvement in symptoms and signs, efficacy index  $< 30\%$ . Total effective rate = (number of clinical control cases + number of apparently effective cases + number of effective cases)/total number of cases  $\times 100\%$ .

## Statistical Analysis

SPSS 22.0 software was used for analysis. All outcome measures were assessed at baseline before treatment, at the end of treatment, at 1-and 3-month follow-up. The normal distribution of the data was assessed using the Shapiro–Wilk test. Descriptive data were expressed as mean  $\pm$  standard deviation (SD), with confidence interval setting to be 95%. At baseline, chi-square tests were performed for categorical variables and unpaired *t*-tests were used for continuous variables. Repeated measure analysis of variance was used to analyze the differences in biomarker levels and functional outcomes between the two groups at different follow-up time points, and unpaired *t*-test was used to analyze the differences between the two groups. Missing values are managed using a mixed linear model.  $P < 0.05$  was considered statistically significant.

## Results

### General Information

82 patients (1 case dropped out) with external humeral epicondylitis enrolled in the study with 34 on the left side and 47 on the right side of the disease site. The minimum age was 21 years and the maximum age was 48 years, with a mean age of  $41.69 \pm 5.52$  (years). The duration of the disease was as short as 1 month and as long as 5 months, with a mean of  $3.46 \pm 1.32$  (months). Table 1 showed that there were no statistically significant difference ( $P > 0.05$ ) in the general information of patients between the two groups.

### Primary Outcome

#### Comparison of VAS Scores Between the Two Groups of Patients Before and After Treatment at Various Time Periods

As shown in Table 2, before treatment, there was no significant difference in VAS score, between the two groups ( $P > 0.05$ ). The VAS scores at each time point after treatment were significantly improved compared with that before treatment, and the difference was statistically significant ( $P < 0.05$ ). At each time point after treatment, the VAS scores of the observation group were significantly improved compared with that of the control group, and the difference was statistically significant ( $P < 0.05$ ).

### Secondary Outcome

#### Comparison of MEPS Score and DASH Score Between the Two Groups of Patients Before and After Treatment at Various Time Periods

As shown in Table 3, before treatment, there was no significant difference in MEPS scores, and DASH scores between the two groups ( $P > 0.05$ ). The MEPS score and DASH score at each time point after treatment were significantly improved compared with those before treatment, and the differences were statistically significant ( $P < 0.05$ ). At each time point after treatment, the MEPS score and DASH score of the observation group were significantly improved compared with those of the control group, and the differences were statistically significant ( $P < 0.05$ ).

**Table 2** Comparison of VAS Score Between the Two Groups of Patients Before and After Treatment (Points)

Group	N	Before Treatment	At the End of the Treatment	1 Month After Treatment	3 Months After Treatment
		VAS Score	VAS Score	VAS Score	VAS Score
Observation group	41	$5.2 \pm 0.8$	$2.2 \pm 0.9$	$1.9 \pm 0.9$	$1.9 \pm 0.9$
Control group	40	$5.1 \pm 0.9$	$3.6 \pm 1.3$	$3.1 \pm 1.2$	$3.1 \pm 1.3$
t-value		0.75	-5.915	-5.514	-4.653
P-value		0.456	0.001	0.001	0.001

**Table 3** Comparison of MEPS Score and DASH Score Between the Two Groups of Patients Before and After Treatment (Points)

Group	N	Before Treatment		At the End of the Treatment		1 Month After Treatment		3 Months After Treatment	
		MEPS	DASH	MEPS	DASH	MEPS	DASH	MEPS	DASH
Observation group	41	52.7±5.5	71.4±4.9	84.8±6.8	17.2±3.6	88.4±6.2	13.4±6.3	88.1±6.0	13.0±2.8
Control group	40	51.7±5.6	70.2±6.0	63.3±5.3	34.3±4.1	72.4±5.0	28.3±9.6	73.3±5.2	24.3±4.6
t-value		0.772	1.039	15.956	-20.002	12.791	-16.995	11.804	-13.302
P-value		0.443	0.302	0.001	0.001	0.001	0.001	0.001	0.001

**Table 4** Comparison of Inflammatory Factor Levels Between the Two Groups Before and After Treatment

Group	N	Before Treatment			At the End of the Treatment		
		IL-6 (ng/l)	IL-10 (ng/l)	TNF- $\alpha$ (ng/l)	IL-6 (ng/l)	IL-10 (ng/l)	TNF- $\alpha$ (ng/l)
Observation group	41	17.41±1.83	18.51±2.19	55.51±3.24	8.12±1.19	7.68±1.17	28.07±2.56
Control group	40	16.98±1.64	18.15±2.32	54.98±3.64	12.70±1.64	13.05±1.41	39.05±2.30
t-value		1.138	0.723	0.702	-15.010	-18.628	-20.278
P-value		0.259	0.472	0.485	0.001	0.001	0.001

**Table 5** Comparison of Clinical Outcomes Between the Two Groups [n (%)]

Group	N	Clinical Control	Visible Effect	Effective	Invalid	Total Effective Rate (%)
Observation group	41	19(46.3)	9(22.0)	10(24.4)	3(7.3)	92.7
Control group	40	11(27.5)	9(22.5)	10(25.0)	10(25.0)	75.0
$\chi^2$ values						4.699
P-value						0.03

### Comparison of Inflammatory Factor Levels Between the Two Groups Before and After Treatment

As shown in Table 4, There were no statistically significant differences in IL-6, IL-10, TNF- $\alpha$  and other inflammatory substances between the two groups before treatment ( $P>0.05$ ). After treatment, the improvement of inflammatory indicators in the two groups was better than that before treatment, and the difference was statistically significant ( $P<0.05$ ). At the same time, the improvement of inflammatory indicators in the observation group was better than that in the control group, and the difference was statistically significant ( $P < 0.05$ ).

## Effectiveness Evaluation Outcome

### Comparison of Clinical Outcomes Between the Two Groups of Patients

As shown in Table 5, it was statistically significant ( $P<0.05$ ) that the observation group's overall effective rate (92.7%, 38/41) was greater than the control group's (75.0%, 30/40).

## Discussion

Extracorporeal shockwave is a treatment method that produces acoustic pulses of varying energy and induces unique biophysical effects in human tissue, particularly in chronic tendinopathies.<sup>16–18</sup> In this study, patients treated with extracorporeal shock wave showed varying degrees of improvement in pain and joint mobility. Compared with traditional Chinese acupuncture treatment, extracorporeal shock wave has a more indirect stimulation effect on acupoints or tender points, and the selection of probe and energy delivery are relatively limited. Therefore, this study combined with warm acupuncture treatment, with one needle as the main and four needles as

the supplement, strengthened the acupuncture range and the amount of acupuncture stimulation, so that acupuncture can directly act on the tender points. Warm acupuncture plays the role of dredging channels and collaterals, harmonizing Yin and Yang, promoting health and dispelling evil.<sup>19</sup> So as to achieve an effect of “no unobstructed, no pain”. Therefore, this study uses the theory of “pain as acupuncture point” and the combination of extracorporeal shock wave and warm acupuncture therapy, which is a new combined Chinese and Western medicine treatment method.

In this study, we found that extracorporeal shock wave combined with warm acupuncture treatment and extracorporeal shock wave alone were both effective in the treatment of external humeral epicondylitis during the observation period (3 months), and the combined protocol was more effective in improving pain and dysfunction in external humeral epicondylitis compared to extracorporeal shock wave alone, and the combined protocol was also superior to extracorporeal shock wave alone in terms of inflammatory factor expression. This leads us to conclude that extracorporeal shockwave, mainly through the administration of pressure load, increases the rate of conversion of extracellular matrix, induces neovascularization and thus accelerates inflammation and catabolism, with the aim of relieving pain.<sup>20,21</sup> Warm acupuncture stimulates the meridians and channels, disperses cold and invigorates blood, and soothes the tendons and anxieties.<sup>22</sup>

External humeral epicondylitis is a chronic and injurious disease, mainly characterized by pain in the lateral aspect of the elbow joint, which can be radiated downwards along the forearm extensor muscles,<sup>23,24</sup> which affects the mobility of the elbow joint to vary degrees. The main mechanism is that extracorporeal shock waves can accelerate the absorption of inflammatory substances in the tissues surrounding the lesion, inhibit the release of relevant inflammatory factors, and significantly promote the healing and regeneration of muscles, bones, tendons, ligaments and other soft tissues, thus achieving pain relief and improving mobility.<sup>25–27</sup> In clinical practice, warm acupuncture is mainly used to treat meridian tendon disease and pressure points are the source of soft tissue pain. Combining the two can enhance local blood supply, improve metabolic disorders and eliminate inflammation. The results of this study showed that the combined protocol significantly reduced pain at the lesion site and improved limb movement function in patients with external humeral epicondylitis, which was further validated in the later follow-up and evaluation. Accordingly, the author believes that rapid pain relief is one of the key ways to improve the quality of life of patients with external humeral epicondylitis. Therefore, the long-term efficacy of the combined regimen for the treatment of external humeral epicondylitis was shown to be better through this study.

In summary, with the development of the concept of combining Chinese and Western medicine in the treatment of orthopaedic diseases, the ability to retain and inherit the advantages of traditional acupuncture and moxibustion treatment, while combining modern rehabilitation medicine techniques, can further improve the efficacy and is more acceptable to patients.

## Limitations

In this study, no multi-center trial was conducted with small sample size, no blank control group or sham temperature acupuncture group set. Only the effects of single external shock wave and warm acupuncture + extracorporeal shock wave therapy were compared. Thus, we thought that the interventions received by the control group would help overcoming the “Hawthorne effect”.

## Conclusions

This study shows that extracorporeal shock wave combined with warm needle can effectively improve the pain symptoms and dysfunction of external humeral epicondylitis, reduce the expression of inflammatory factors, and the effect is better than simple extracorporeal shock wave, which is easier to be accepted by patients and worthy of further clinical promotion. The team will conduct more rigorous prospective randomized trials on this topic in future studies to further confirm the current findings and provide more reliable scientific evidence.

## Registration

The study was registered in the Chinese Clinical Trial Registry (registration no. ChiCTR2200066075).

## Data Sharing Statement

The datasets generated and/or analyzed during the current study are available from the corresponding author on reasonable request.

## Ethics Statement

This study has been approved by the Ethics Committee of The First People's Hospital of Huzhou within which this study was undertaken. And that it conforms to the provisions of the Declaration of Helsinki. The treatment scheme adopted in this clinical study is simple and safe. The data obtained remain anonymous. The collection of research data complies with national laws, regulations, and social ethics.

## Funding

The work supported by The First People's Hospital of Huzhou.

## Disclosure

The authors declare that they have no competing interests.

## References

- Chen JX, Liu GH, Liu BZ, et al. Efficacy of centrifugal contraction training combined with extracorporeal shock wave therapy in the treatment of tennis elbow. *Chin J Phys Med Rehabil*. 2017;39(7):534–536.
- Zhao L, Kong LY, Ren YZ, et al. Advances in the study of humeral epicondylitis. *J Pract Orthod*. 2017;23(10):904–907.
- Krogh TP, Fredberg U, Stengaard-Pedersen K, et al. Treatment of lateral epicondylitis with platelet-rich plasma, glucocorticoid, or saline: a randomized, double-blind, placebo-controlled trial. *Am J of Sports Med*. 2013;41(3):625–635. doi:10.1177/0363546512472975
- Rabago D, Lee KS, Ryan M, et al. Hypertonic dextrose and Morrhuate sodium injections (Prolotherapy) for lateral epicondylitis (tennis elbow): results of a single-blind, pilot-level, randomized controlled trial. *Pm&R*. 2013;92(7):587–596.
- Li X, Zhou K, Zhang E, et al. Therapeutic effect of electro acupuncture, massage, and blocking therapy on external humeral epicondylitis. *J Tradit Chin Med*. 2014;34(3):261–266. doi:10.1016/S0254-6272(14)60088-1
- Wang F, Liu JF, Zhang JT. Clinical observation on the treatment of humeral epicondylitis with external shock wave combined with thermal acupuncture in the external epicondyle and infraspinatus of the humerus. *Chin J Phys Med Rehabil*. 2022;44(4):331–333.
- Xing CY. *Extracorporeal Shock Wave Therapy for Bone and Muscle Diseases*. 2nd ed. Beijing: People's Military Medical Press; 2007:1–4.
- Zhao D, Zhang F, Wang B, et al. Professional committee of shockwave medicine, Chinese society of research hospitals. guidelines for extracorporeal shock wave therapy for bone and muscle diseases in China (2019 edition). *Chin J Front Med*. 2019;11(4):1–10.
- Peng Z, Zhang M, Li Y, Feng Z. Treatment of lateral epicondylitis with acupuncture and glucocorticoid: a retrospective cohort study. *Medicine*. 2020;99(8):e19227. doi:10.1097/MD.00000000000019227
- Xu ST, Ge BF, Xu YK. *Practical Orthopaedics*. 4th ed. Beijing: People's Military Medical Publishing House; 2012:1919.
- Schulz KF, Altman DG, Moher D, CONSORT Statement: Updated Guidelines for Reporting Parallel Group Randomised Trials. *PLoS Med*. 2010;7(3):e1000251.
- Beyazal MS, Devrimel G. Comparison of the effectiveness of local corticosteroid injection and extracorporeal shock wave therapy in patients with lateral epicondylitis. *J Phys Ther Sci*. 2015;27(12):3755–3758. doi:10.1589/jpts.27.3755
- Dong PL, Tang XB, Wang J, et al. Efficacy of local injection of platelet-rich plasma in the treatment of humeral epicondylitis. *Chin J Joint Surg*. 2018;12(5):608–613.
- Fang ZY, Xiong L, Ch GA, et al. Clinical study of extracorporeal shock wave combined with muscle energy technique for the treatment of humeral epicondylitis. *China Rehabilitation*. 2016;31(5):362–364.
- State Administration of Traditional Chinese Medicine. *Diagnostic and Efficacy Criteria for Chinese Medicine Illnesses*. Nanjing: Nanjing University Press; 1994.
- Wang B, Wang YH, Li A, et al. Research progress of extracorporeal shock wave treatment for tendinopathy. *Chinese J Rehabilitation Med*. 2021;36(10):1332–1336.
- Yao G, Chen J, Duan Y, et al. Efficacy of extracorporeal shock wave therapy for lateral epicondylitis: a systematic review and meta-analysis. *Biomed Res Int*. 2020;2020:1–8. doi:10.1155/2020/4374801
- Rinella L, Marano F, Paletto L, et al. Extracorporeal shock waves trigger tenogenic differentiation of human adipose- derived stem cells. *Connect Tissue Res*. 2018;59(6):561–573. doi:10.1080/03008207.2018.1424147
- Li XW, Shao XM, Tan KP, et al. A preliminary investigation on the treatment of Meridian tendon disease by combining warm acupuncture with five tiger tacking acupuncture. *J Zhejiang Univ Tradit Chin Med*. 2012;36(7):818–819.
- Santamato A, Beatrice R, Micello MF, et al. Power Doppler ultra sound findings before and after focused extracorporeal shock wave therapy for Achilles tendinopathy: a pilot study on pain reduction and neovascularization effect. *Ultrasound Med Biol*. 2019;45(5):1316–1323. doi:10.1016/j.ultrasmedbio.2018.12.009
- Simplicio CL, Purita J, Murrell W, et al. Extracorporeal shock wave therapy mechanisms in musculoskeletal regenerative medicine. *J Clin Orthop Trauma*. 2020;11(Suppl3):S309–S318. doi:10.1016/j.jcot.2020.02.004
- Zhou CL, Gao H, Liang Y, et al. An analysis of Fang J Q's "Wu Hu Qin Yang" acupuncture method for treating Meridian tendon diseases. *Chin J Tradit Chin Med*. 2020;35(3):1316–1318.

23. Cao JJ, Du JJ. 57 cases of epicondylitis of the humerus treated with snap acupuncture. *Chinese Acupunc.* 2020;40(8):885–886.
24. Zhong CY, Hu XW. Efficacy of radiated shock wave combined with small needle knife Meridian-following treatment for recalcitrant external humeral epicondylitis. *Zhejiang J Integrat Chin West Med.* 2020;30(10):846–848.
25. Zhou DY, Tao HH, Yang YQ, et al. Anti-inflammatory and analgesic mechanism of extracorporeal shock wave on musculoskeletal pain. *J Pract Orthod.* 2017;23(7):618–21+625.
26. Yu B, Chen WH, Wang RW, et al. Efficacy of intraosseous patch combined with extracorporeal shock wave in the treatment of refractory external humeral epicondylitis. *Chin J Phys Med Rehabil.* 2016;38(5):381–383.
27. Reed JA. *Braddom's Physical Medicine and Rehabilitation Medicine*. 5th ed. Beijing: Science Press; 2018:322–324.

### Journal of Multidisciplinary Healthcare

Dovepress

### Publish your work in this journal

The Journal of Multidisciplinary Healthcare is an international, peer-reviewed open-access journal that aims to represent and publish research in healthcare areas delivered by practitioners of different disciplines. This includes studies and reviews conducted by multidisciplinary teams as well as research which evaluates the results or conduct of such teams or healthcare processes in general. The journal covers a very wide range of areas and welcomes submissions from practitioners at all levels, from all over the world. The manuscript management system is completely online and includes a very quick and fair peer-review system. Visit <http://www.dovepress.com/testimonials.php> to read real quotes from published authors.

Submit your manuscript here: <https://www.dovepress.com/journal-of-inflammation-research-journal>