

Pyomyositis Secondary to Localized Cellulitis in a Dermatomyositis Patient: A Case Report and Review of Infectious Complications in Dermatomyositis

Xingwei Zhang^{1,2}, Xiaoyan Lyu^{1,2}

¹Department of Dermatology, West China Hospital, Sichuan University, Chengdu, People's Republic of China; ²Laboratory of Dermatology, Clinical Institute of Inflammation and Immunology, Frontiers Science Center for Disease-Related Molecular Network, West China Hospital, Sichuan University, Chengdu, People's Republic of China

Correspondence: Xiaoyan Lyu, Department of Dermatology, West China Hospital, Sichuan University, 37 Guoxue Road, Chengdu, 610041, People's Republic of China, Tel +86 19938063616, Fax +86-028-85582994, Email lxiaoyan@scu.edu.cn

Abstract: Dermatomyositis (DM) is an autoimmune disorder characterized by proximal muscle weakness and distinct cutaneous features. Unfortunately, infection is a frequent and potentially life-threatening complication in patients with DM. Here, we present a case of pyomyositis in a patient with DM resulting from localized cellulitis. The patient also presented with subcutaneous calcification nodules and dermatomyositis-associated lipodermatosclerosis nodules. To our knowledge, there have been no reports of pyomyositis in patients with DM to date. Furthermore, we reviewed the infectious complications related to DM and polymyositis (PM). We found that idiopathic inflammatory myopathy (IIM) patients exhibit a considerable infection-related mortality rate, ranging from 4.3% to 7.2%. In IIM, infections were identified as the primary cause of mortality in a substantial proportion of cases, accounting for 22.0–83.3% of deaths. These findings have implications for the importance of identifying and managing infections in IIM patients and suggest the need for further research into infection-related complications in these patients.

Keywords: dermatomyositis, polymyositis, infection, mortality, case report

Introduction

Dermatomyositis is an autoimmune disease characterized by weakness in the proximal muscles and distinct skin manifestations. Pyomyositis is a subacute bacterial infection that primarily affects skeletal muscles and can arise from contiguous spread or hematogenous seeding. To date, there have been no documented cases of pyomyositis in individuals with DM. However, our case report suggests that pyomyositis may occur due to the presence of localized cellulitis in the muscles of patients with dermatomyositis. Early identification of pyomyositis is crucial for preventing muscle function loss or even death in patients with dermatomyositis. DM are associated with reduced long-term survival, particularly in cases of anti-MDA5+DM, with infections being a primary cause.¹ However, there is a lack of comprehensive reviews of IIM-related infections across different anatomical locations and microbial agents, and reports are scattered and sporadic. Thus, we reviewed the infectious complications related to dermatomyositis/polymyositis.

Case Report

A 49-year-old male with a history of dermatomyositis and long-term use of glucocorticoids presented to our hospital with a painful indurated swelling in the anteromedial aspect of his thigh and a low-grade fever (maximum temperature of 37.9 degrees) persisting for 12 days (Figure 1). He did not achieve remission with 11 days of ceftazidime in another hospital. Physical examination revealed the presence of multiple subcutaneous nodules, scar tissue with hyperpigmentation, and local swelling and induration with redness and mild fluctuation in anteromedial thigh (Figures 1 and 2). Empirical treatment with

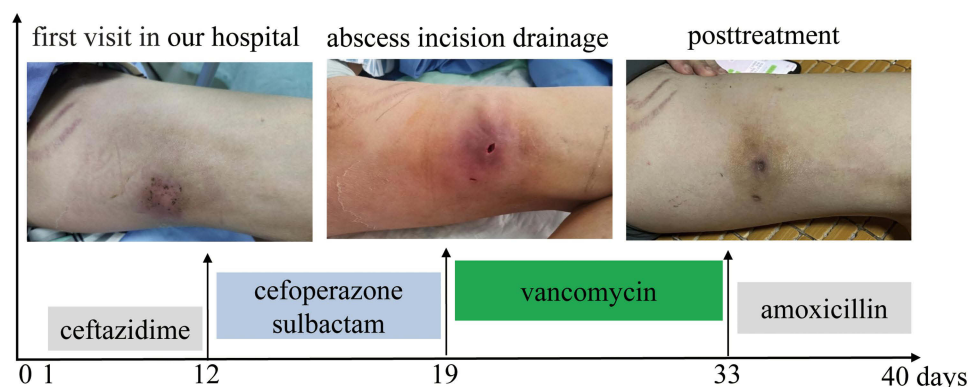


Figure 1 The time course of treatment and states of illness.

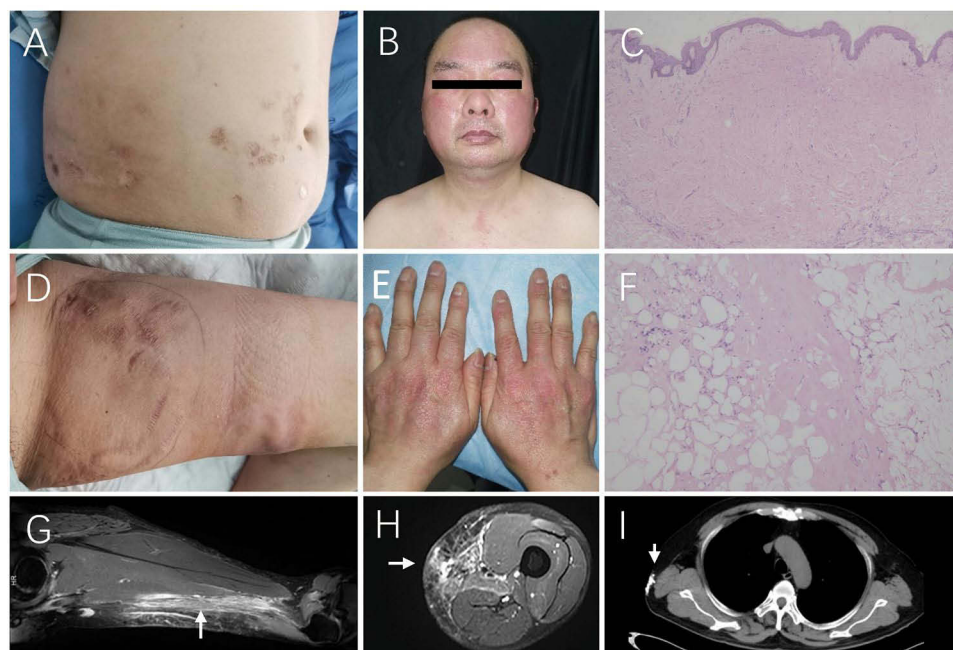


Figure 2 (A and D): The cicatrix, fibrocollagenous nodules and multiple calcifications in abdomen and thighs. (B and E): The characteristic features of dermatomyositis: Heliotrope sign, V sign and Gottron sign. (C) (HE×40) and (F) (HE×100): Biopsy of the subcutaneous firm nodules in the trunk revealed localized collagen hyperplasia in the dermis, accompanied by significant mucin deposition, as well as adipose septal fibrosis and hyalinization in the subcutaneous adipose tissue, featuring lipomatous cysts and membranous changes, with a minor infiltration of lymphocytes in the dermis and subcutaneous adipose tissue. (G and H): T1-weighted MR images revealed high signal intensity in sartorius muscle (white arrows) and intermuscular space. (I): The chest CT scan identified subcutaneous calcified nodules (white arrow).

cefoperazone-sulbactam was initiated, but the patient subsequently presented with crampy local pain and a “woody” texture of the anteromedial thigh muscle, making it difficult to straighten his left leg.

Laboratory studies showed lymphocytopenia (white blood cell count $11.69 \times 10^9/L$, with 88.8% neutrophils) and evidence of inflammation/infection (procalcitonin 0.08ng/mL, C-reactive protein 7.58mg/L, interleukin-6 7.10pg/mL). An enhanced CT scan demonstrated skin and subcutaneous tissue swelling with irregular enhancement, soft tissue gas, focal fluid accumulation, and multiple calcifications in the left thigh. T1-weighted MR images demonstrated high signal intensity within the sartorius muscle, and culture of the lesion revealed *Staphylococcus aureus*. The ultimate diagnosis is stage I pyomyositis, resulting from abscess extension of the cellulitis. The patient’s condition markedly improved following ultrasonographic-guided percutaneous drainage and a two-week course of vancomycin. He subsequently received a two-week course of amoxicillin (Figure 1).

Of note, the patient presented with two distinct types of subcutaneous nodules: fibrocollagenous nodules, confirmed by pathology, and multiple calcifications, demonstrated on enhanced CT imaging (Figure 2). The diagnosis of deep morphea was ruled out. The existence of fibrocollagenous nodules in dermatomyositis patients is insufficiently reported

and could represent the fibrotic/late phase of dermatomyositis panniculitis. This could be related to the presence of membranous cystic changes and mild lymphocytic inflammation in the adipose lobules of skin biopsy (Figure 2).

Discussion

This report describes a case of pyomyositis in a patient with dermatomyositis, which may be related to the long-term use of glucocorticoids. For a period of 5 years, the patient's condition of dermatomyositis was effectively managed with a combination of methylprednisolone and methotrexate. Methylprednisolone was initially prescribed at a daily dosage of 30mg and gradually tapered over time. In the last year leading up to admission, the dosage was reduced to 5mg once daily, and six months before admission, it was further decreased to 2.5mg once daily. The occurrence of pyomyositis can be observed in an immunosuppressed patient. This case is expected to be distinguished from necrotizing fasciitis and clostridial myonecrosis. Timely recognition and treatment of pyomyositis are crucial to prevent severe complications and mortality in patients with dermatomyositis. However, early identification can be challenging. Healthcare providers should be vigilant in monitoring and promptly identifying signs and symptoms of pyomyositis in this population.

In addition, we reviewed the clinical studies related to infection in patients with DM/PM. We conducted a comprehensive literature search on PubMed and Web of Science. For the literature screening process, two reviewers independently conducted the screening, and any disagreements were resolved through consensus. Figure 3 illustrates the literature screening flowchart employed in this study. Tuberculosis and COVID-19 were excluded from our study due to prior systematic reviews. Overlap

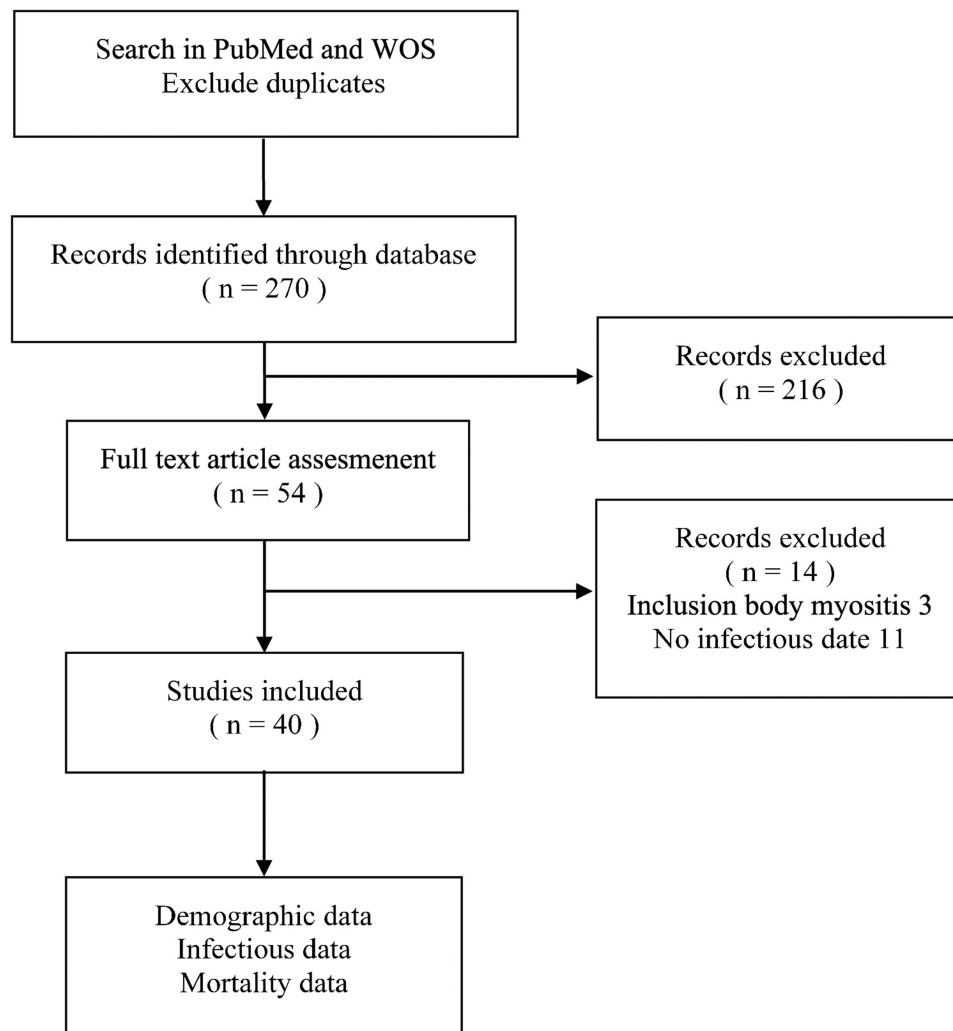


Figure 3 The literature screening flowchart.

syndrome is also ruled out. As of March 20th, 2023, this study has included a total of 40 studies and 10,694 patients. 33 (82.5%) of the studies are retrospective. The studies were predominantly retrospective in design and exhibited considerable variability in follow-up duration, with mean times ranging from 1 to 13 years. Although the heterogeneity in infection-related mortality was relatively low, the disparate timeframes precluded quantitative synthesis of the data. This literature review strengthens the evidence base and enhances understanding of the link between inflammatory myositis and infections.

Our review revealed a wide range of overall mortality proportions (4–45%) among patients with idiopathic inflammatory myopathy. Among these patients, infection-related mortality rates were identified to range from 2.2% to 7.2% (Table 1). Notably, a significant proportion of deaths (22.0–83.3%) in patients with idiopathic inflammatory myopathy were primarily attributed to infections. Our study also provides a summary of infection rates observed in different IIM subtypes and infection types (Table 2 and Table 3). The most common infection agents are cytomegalovirus, Herpes Simplex Virus/Varicella Zoster Virus, Candidiasis, pneumocystis Carinii pneumonia (Table 3). Among all patients, those with melanoma differentiation associated gene 5 antibody-positive dermatomyositis (Anti-MDA-5+DM) have the highest susceptibility to infections, with an infection rate ranging from 42.1 to 83.3% (Table 2).

Table 1 The Clinical Data and Mortality Rates in Patients with IIM

Diagnosis	Treatment	No. Patients	No. Deaths	No. Deaths (Infection)	Mean Age	Male%	Study	
IIM	GCs/ISD/BT	97	24	7(7.2%)	At diagnosis 40.5	25.8%	R	Marta 2016 ²
IIM	GCs/ISD/BT	479	114	26(5.4%)	At diagnosis 44.0	26.0%	R	Laura 2017 ³
IIM	GCs/ISD/BT	467	113	27(5.7%)	At diagnosis 41.1	26.0%	R	Laura 2017 ⁴
IIM	GCs/ISD/BT	90	13	4(4.4%)	At diagnosis 38.5	28.9%	R	Taborda 2014 ⁵
IIM	GCs/ISD/BT	370	118	26(7.0%)	–	–	R	Limaye 2012 ⁶
IIM	GCs/ISD	158	46	13(8.2%)	At diagnosis 40.8	22.8%	R	Francisca 2023 ⁷
DM	GCs/ISD/BT	100	6	5(5.0%)	In years 50.1	35.0%	R	Nicholas 2015 ⁸
DM	GCs+IVIG	91	9	2(2.2%)	At diagnosis 47.3	33.0%	R	Truzzi 2022 ⁹
DM/PM	GCs/ISD/BT	–	117	81(–)	–	–	R	Vieira 2019 ¹⁰
DM/PM	GCs/ISD/BT	23	2	1(4.3%)	In years 57.0	26.1%	R	Kenji 2007 ¹¹
DM/PM	GCs/ISD	554	36	20(3.6%)	In years 49.2	36.3%	R	Lao 2023 ¹²

Abbreviations: IIM, idiopathic inflammatory myositis; DM, dermatomyositis; PM, polymyositis; GCs, Glucocorticosteroid; ISD, Immunosuppressive drug; BT, Biologic therapy; IVIG, Intravenous immunoglobulin; R, Retrospective.

Table 2 The Clinical Data and Prevalence of Infections in Patients with Different IIM Subtypes

Diagnosis	Treatment	No. Patients	No. Infections	Mean Age	Male%	Study	
IIM	GCs/ISD/BT	1026	7(0.7%)	In years 61.8	33.4%	R	Shirley 2021 ¹³
	GCs/ISD/BT	214	121(56.5%)	At diagnosis 38.7	20.9%	Cohort study	Naveen 2021 ¹⁴
	CYC	14	7(50.0%)	In years 51.1	–	R	Sangmee 2018 ¹⁵
	GCs/ISD/BT	204	13(6.4%)	–	–	R	Redondo 2018 ¹⁶
	–	106	56(52.8%)	–	–	R	Xiao 2017 ¹⁷
	RTX	30	8(26.7%)	In years 52.5	30.0%	R	Marion 2011 ¹⁸
	RTX	30	3(10.0%)	In years 56.0	26.7%	R	Edoardo 2023 ¹⁹

(Continued)

Table 2 (Continued).

Diagnosis	Treatment	No. Patients	No. Infections	Mean Age	Male%	Study	
	CTX	11	2(18.2%)	–	–	Clinical Trial	Cronin 1989 ²⁰
	GCs/ISD/BT	97	32(33.0%)	At diagnosis 40.5	25.8%	R	Marta 2016 ²
	RTX/GCs/ISD/BT	20	2(10.0%)	In years 49.2	25.0%	R	Casals 2010 ²¹
	–	957	124(13.0%)	In years 59.0	43.0%	R	John 2017 ¹
	–	66	33(50.0%)	In years 49.5	31.8%	R	Lu 2023 ²²
DM	GCs/ISD/BT	89	58(65.2%)	At diagnosis 40	28.1%	Cohort study	Naveen 2021 ¹⁴
	GCs/ISD	105	22(21.0%)	At diagnosis 51.5	19.6%	R	Nuno 2019 ²³
	–	91	48(50.0%)	At diagnosis 47.3	33.0%	R	Truzzi 2022 ⁹
Juvenile DM	MMF+GCs	50	41(82.0%)	In years 12.2	24.0%	R	Kelly 2010 ²⁴
	GCs/ISD/BT	19	7(36.8%)	In years 12.5	42.1%	R	Shiva 2013 ²⁵
	GCs/ISD/BT	139	33(23.7%)	–	41.0%	Randomized trial	Nicolino 2016 ²⁶
	RTX	9	2(22.2%)	At onset 7.6	11.1%	P	Brigitte 2011 ²⁷
PM	GCs/ISD/BT	33	14(42.4%)	At diagnosis 38	27.3%	Cohort study	Naveen 2021 ¹⁴
	GCs/ISD	137	36(26.3%)	At diagnosis 56.1	30.0%	R	Nuno 2019 ²³
	GCs	115	21(18.3%)	At diagnosis 53.8	28.7%	R	Uchino 2012 ²⁸
PM/DM	GCs/ISD/BT	2270	628(27.7%)	In years 47.8	33.5%	Cohort study	Chung 2019 ²⁹
	IVIG	11	3(27.3%)	In years 55.6	46.6%	Clinical Trial	Cherin 1994 ³⁰
	RTX	19	7(36.8%)	In years 58	10.5%	R	Unger 2014 ³¹
	–	554	197(35.6)	In years 49.2	36.3%	R	Lao 2023 ¹²
OM/PM/DM	GCs/ISD/BT	332	96(28.9%)	At diagnosis 49.1	22.2%	R	Nuno 2019 ²³
PM/DM-ILD	TAC and GCs	25	19(76.0%)	In years 55.4	24.0%	Clinical trial	Kazuki 2019 ³²
ASS-ILD	GCs/ISD/BT	32	11(34.4%)	At diagnosis 55.8	34.4%	P	Tillie 2008 ³³
Anti-MDA-5 ⁺ DM	GCs+TAC or CYC vs GCs+other ISD	42	35(83.3%)	In years 54.8	29.5%	P	Tsuji 2020 ³⁴
	TOF+plasma exchange +RTX	33	24(72.7%)	In years 52.0%	18.2%	R	Shirai 2023 ³⁵
	–	19	8(42.1%)	At diagnosis 52.5	18.8%	R	Billet 2022 ³⁶
Anti-MDA5/ARS/TIFI- γ ⁺ DM	GCs/ISD/BT	33	17(51.5%)	At diagnosis 55.9	36.3%	R	Kazuki 2020 ³⁷
Cancer associated DM	GCs/ISD/BT	7	5(71.4%)	At diagnosis 53	14.3%	Cohort study	Naveen 2019 ¹⁴

Abbreviations: IIM, idiopathic inflammatory myositis; DM, dermatomyositis; PM, polymyositis; OM, overlap myositis; ASS, Antisynthetase syndrome; MDA5, melanoma differentiation associated gene 5; ARS, Anti-Aminoacyl-tRNA Synthetase; TIFI- γ , Transcription Intermediary Factor I Gamma; GCs, Glucocorticosteroid; ISD, Immunosuppressive drug; BT, Biologic therapy; IVIG, Intravenous immunoglobulin; RTX, Rituximab; MMF, mycophenolate mofetil; TOF, Tofacitinib; TAC, Tacrolimus; CYC, Cyclophosphamide; R, Retrospective; P, Prospective; ILD, interstitial lung diseases.

Table 3 The Clinical Data and Prevalence of Infections in Patients with Different Infection Types

Infectious Agents	Diagnosis	No. Patients	No. Infections	Mean Age	Male %	Study	
CMV	Anti-MDA5/ ARS/ TIFI γ DM	33	7	At diagnosis 55.9	36.3%	R	Kazuki 2020 ³⁷
	PM/DM	2270	18	In years 47.8	33.5%	Cohort study	Chung 2019 ²⁹
	Anti-MDA-5 ⁺ DM-ILD	42	28	In years 54.8	29.5%	P	Tsuji 2020 ³⁴
	IMM	204	3	–	–	R	Redondo 2018 ¹⁶
	DM/PM	554	24	In years 49.2	36.3%	R	Lao 2023 ¹²
CMV pneumonitis	PM/DM-ILD	25	1	In years 55.4	24.0%	Clinical trial	Kazuki 2019 ³²
Herpes-zoster	Anti-MDA5/ARS/ TIFI γ DM	33	5	At diagnosis 55.9	36.3%	R	Kazuki 2020 ³⁷
	PM/DM-ILD	25	1	In years 55.4	24.0%	Clinical trial	Kazuki 2019 ³²
	PM/DM	2270	377	In years 47.8	33.5%	Cohort study	Chung 2019 ²⁹
	ASS-ILD	32	8	At diagnosis 55.8	34.4%	P	Tillie 2008 ³³
	PM/ DM	2023	338	In years 45.9	32.8%	Cohort Study	Tsai 2015 ³⁸
	IMM	204	5	–	–	R	Redondo 2018 ¹⁶
	DM	91	11	At diagnosis 47.3	33.0%	R	Truzzi 2022 ⁹
HSV	PM/ DM	554	5	In years 49.2	36.3%	R	Lao 2023 ¹²
HSV/VZV	Anti-MDA5 ⁺ DM-ILD	42	4	In years 54.8	29.5%	P	Tsuji 2020 ³⁴
Candidiasis	PM/DM	2270	85	In years 47.8	33.5%	Cohort study	Chung 2019 ²⁹
	Anti-MDA5 ⁺ DM-ILD	42	20	In years 54.8	29.5%	P	Tsuji 2020 ³⁴
	IMM	204	2	–	–	R	Redondo 2018 ¹⁶
	DM/PM	554	38	In years 49.2	36.3%	R	Lao 2023 ¹²
PCP	PM/DM	2270	18	In years 47.8	33.5%	Cohort study	Chung 2019 ²⁹
	Anti-MDA5 ⁺ DM-ILD	42	5	In years 54.8	29.5%	P	Tsuji 2020 ³⁴
	PM/DM-ILD	25	1	In years 55.4	24.0%	Clinical trial	Kazuki 2019 ³²
	IMM	204	1	–	–	R	Redondo 2018 ¹⁶
	DM/PM	554	5	In years 49.2	36.3%	R	Lao 2023 ¹²
	–	214	22			R	Liu 2023 ³⁹
	Anti-MDA5 ⁺ DM	105	13	In years 53.7	24.8%	R	Li 2022 ⁴⁰
Aspergillus	PM/DM	2270	6	In years 47.8	33.5%	Cohort study	Chung 2019 ²⁹
	Anti-MDA-5 ⁺ DM-ILD	42	2	In years 54.8	29.5%	P	Tsuji 2020 ³⁴
	DM/PM	554	8	In years 49.2	36.3%	R	Lao 2023 ¹²
NTM Nocardiosis	PM/DM	2270	14	In years 47.8	33.5%	Cohort study	Chung 2019 ²⁹
	PM/DM-ILD	25	1	In years 55.4	24.0%	Clinical trial	Kazuki 2019 ³²
Cryptococcus	PM/DM	2270	9	In years 47.8	33.5%	Cohort study	Chung 2019 ²⁹

(Continued)

Table 3 (Continued).

Infectious Agents	Diagnosis	No. Patients	No. Infections	Mean Age	Male %	Study	
Salmonellosis	PM/DM	2270	30	In years 47.8	33.5%	Cohort study	Chung 2019 ²⁹
Parasites	IMM	204	4	–	–	R	Redondo 2018 ¹⁶
Upper respiratory infection	Juvenile DM	50	26	In years 12.2	24.0%	R	Kelly 2010 ²⁴

Abbreviations: IIM, idiopathic inflammatory myositis; DM, dermatomyositis; PM, polymyositis; ASS, Antisynthetase syndrome; MDA5, melanoma differentiation associated gene 5; ARS, Anti-Aminoacyl-tRNA Synthetase; TIF1- γ , Transcription Intermediary Factor 1 Gamma; R, Retrospective; P, Prospective; CMV, Cytomegalovirus; NTM, Non-tuberculosis mycobacteria; PCP, Pneumocystis carinii pneumonia; HSV, Herpes Simplex Virus; VZV, Varicella-Zoster Virus; ILD, interstitial lung diseases.

Conclusion

Our case report highlights the potential for pyomyositis as a complication of DM resulting from localized cellulitis, while our review underscores the importance of identifying and managing infections in reducing infection-related mortality in IIM patients. These findings have important implications for the clinical management of DM and IIM and underscore the need for further research into infection-related complications in these patient populations. A better understanding of the relationship between infections and DM/IIM could help inform the development of more targeted interventions aimed at improving patient outcomes.

Abbreviations

ARS, Anti-Aminoacyl-tRNA Synthetase; ASS, Antisynthetase syndrome; BT, Biologic therapy; CMV, Cytomegalovirus; CYC, Cyclophosphamide; DM, dermatomyositis; GCs, Glucocorticosteroid; HSV, Herpes Simplex Virus; IIM, idiopathic inflammatory myositis; ILD, interstitial lung diseases; ISD, Immunosuppressive drug; IVIG, Intravenous immunoglobulin; MDA5, melanoma differentiation associated gene 5; MMF, mycophenolate mofetil; NTM, Non-tuberculosis mycobacteria; OM, overlap myositis; P, Prospective; PCP, Pneumocystis carinii pneumonia; PM, polymyositis; R, Retrospective; RTX, Rituximab; TAC, Tacrolimus; TIF1- γ , Transcription Intermediary Factor 1 Gamma; TOF, Tofacitinib; VZV, Varicella-Zoster Virus.

Data Sharing Statement

The data that support the findings of this study are available from the corresponding author upon reasonable request.

Patient Perspective

The use of Vancomycin has been instrumental in my recovery, and I have noticed a significant improvement in my symptoms since starting the medication.

Ethical Approval and Consent to Participate

The Institutional Review Board (IRB) has approved our research application. The patient provided informed consent for the publication of their case.

Acknowledgments

No specific funding was received from any bodies in the public, commercial or not-for-profit sectors to carry out the work described in this article.

Author Contributions

All authors made a significant contribution to the work reported, whether that is in the conception, study design, execution, acquisition of data, analysis and interpretation, or in all these areas; took part in drafting, revising or critically

reviewing the article; gave final approval of the version to be published; have agreed on the journal to which the article has been submitted; and agree to be accountable for all aspects of the work.

Disclosure

The authors report no conflicts of interest in this work.

References

1. Svensson J, Holmqvist M, Lundberg IE, Arkema EV. Infections and respiratory tract disease as risk factors for idiopathic inflammatory myopathies: a population-based case-control study. *Ann Rheum Dis*. 2017;76(11):1803–1808. doi:10.1136/annrheumdis-2017-211174
2. Amaral Silva M, Cogollo E, Isenberg DA. Why do patients with myositis die? A retrospective analysis of a single-centre cohort. *Clin Exp Rheumatol*. 2016;34(5):820–826.
3. Nuño L, Joven B, Carreira P, et al. [Multicenter registry on inflammatory myositis from the Rheumatology Society in Madrid, Spain: descriptive analysis] Registro de pacientes con miopatía inflamatoria de la Sociedad Madrileña de Reumatología: análisis descriptivo. *Reumatol Clin*. 2017;13(6):331–337. Spanish. doi:10.1016/j.reuma.2016.07.010
4. Nuño-Nuño L, Joven BE, Carreira PE, et al. Mortality and prognostic factors in idiopathic inflammatory myositis: a retrospective analysis of a large multicenter cohort of Spain. *Rheumatol Int*. 2017;37(11):1853–1861. doi:10.1007/s00296-017-3799-x
5. Taborda AL, Azevedo P, Isenberg DA. Retrospective analysis of the outcome of patients with idiopathic inflammatory myopathy: a long-term follow-up study. *Clin Exp Rheumatol*. 2014;32(2):188–193.
6. Limaye V, Hakendorf P, Woodman RJ, Blumbergs P, Roberts-Thomson P. Mortality and its predominant causes in a large cohort of patients with biopsy-determined inflammatory myositis. *Intern Med J*. 2012;42(2):191–198. doi:10.1111/j.1445-5994.2010.02406.x
7. Guimarães F, Yildirim R, Isenberg DA. Long-term survival of patients with idiopathic inflammatory myopathies: anatomy of a single-centre cohort. *Clin Exp Rheumatol*. 2023;41(2):322–329. doi:10.55563/clinexpheumatol/486yh4
8. Johnson NE, Arnold WD, Hebert D, et al. Disease course and therapeutic approach in dermatomyositis: a four-center retrospective study of 100 patients. *Neuromuscul Disord*. 2015;25(8):625–631. doi:10.1016/j.nmd.2015.04.013
9. Truzzi NCC, Hoff LS, Borges IBP, de Souza FHC, Shinjo SK. Clinical manifestations, outcomes, and antibody profile of Brazilian adult patients with dermatomyositis: a single-center longitudinal study. *Adv Rheumatol*. 2022;62(1):41. doi:10.1186/s42358-022-00276-x
10. Sartori Vieira C, de Rezende RPV, Mendes Klumb E, Cardoso Mocarzel LO, Altenburg Gismondi R. Mortality profile related to the spectrum of systemic connective tissue diseases: a retrospective, population-based, case-control study. *Lupus*. 2019;28(12):1498–1500. doi:10.1177/0961203319876993
11. Tani K, Tomioka R, Sato K, et al. Comparison of clinical course of polymyositis and dermatomyositis: a follow-up study in Tokushima University Hospital. *J Med Invest*. 2007;54(3–4):295–302. doi:10.2152/jmi.54.295
12. Lao M, Ouyang H, Li N, et al. Clinical characteristics and associated factors for infection and in-hospital mortality in inpatients with polymyositis/dermatomyositis in China: a retrospective study. *Infect Drug Resist*. 2023;16:289–299. doi:10.2147/idr.S392585
13. Chan SCW, Chung HY, Lau CS, Li PH. Epidemiology, mortality and effectiveness of prophylaxis for Pneumocystis jirovecii pneumonia among rheumatic patients: a territory-wide study. *Ann Clin Microbiol Antimicrob*. 2021;20(1):78. doi:10.1186/s12941-021-00483-2
14. Naveen R, Rathore U, Agarwal V, Gupta L. Characteristics and outcomes of overlap myositis: a comparative multigroup cohort study in adults from the MyoCite cohort. *Rheumatol Int*. 2021;41(3):551–563. doi:10.1007/s00296-020-04779-y
15. Bae S, Charles-Schoeman C. Oral cyclophosphamide in treatment of patients with refractory idiopathic inflammatory myopathies: a retrospective observational study. *Clin Rheumatol*. 2018;37(8):2113–2123. doi:10.1007/s10067-018-4174-3
16. Redondo-Benito A, Curran A, Villar-Gomez A, et al. Opportunistic infections in patients with idiopathic inflammatory myopathies. *Int J Rheum Dis*. 2018;21(2):487–496. doi:10.1111/1756-185x.13255
17. Xiao Y, Luo H, Zhou B, et al. Comparison of soluble urokinase plasminogen activator receptor, soluble triggering receptor expressed on myeloid cells 1, procalcitonin and C-reactive protein in distinguishing concurrent bacterial infection from idiopathic inflammatory myopathy. *Rheumatol Int*. 2017;37(4):585–592. doi:10.1007/s00296-016-3609-x
18. Couderc M, Gottenberg JE, Mariette X, et al. Efficacy and safety of rituximab in the treatment of refractory inflammatory myopathies in adults: results from the AIR registry. *Rheumatology*. 2011;50(12):2283–2289. doi:10.1093/rheumatology/ker305
19. Conticini E, d'Alessandro M, Grazzini S, et al. Rituximab-induced hypogammaglobulinaemia in patients affected by idiopathic inflammatory myopathies: a multicentre study. *Clin Exp Rheumatol*. 2023;41(2):285–290. doi:10.55563/clinexpheumatol/790ihy
20. Cronin ME, Miller FW, Hicks JE, Dalakas M, Plotz PH. The failure of intravenous cyclophosphamide therapy in refractory idiopathic inflammatory myopathy. *J Rheumatol*. 1989;16(9):1225–1228.
21. Ramos-Casals M, García-Hernández FJ, de Ramón E, et al. Off-label use of rituximab in 196 patients with severe, refractory systemic autoimmune diseases. *Clin Exp Rheumatol*. 2010;28(4):468–476.
22. Cheng L, Li Y, Wu Y, et al. Risk of early infection in idiopathic inflammatory myopathies: cluster analysis based on clinical features and biomarkers. *Inflammation*. 2023;46:1036–1046. doi:10.1007/s10753-023-01790-w
23. Nuño-Nuño L, Joven BE, Carreira PE, et al. Overlap myositis, a distinct entity beyond primary inflammatory myositis: a retrospective analysis of a large cohort from the REMICAM registry. *Int J Rheum Dis*. 2019;22(8):1393–1401. doi:10.1111/1756-185x.13559
24. Rouster-Stevens KA, Morgan GA, Wang D, Pachman LM. Mycophenolate mofetil: a possible therapeutic agent for children with juvenile dermatomyositis. *Arthritis Care Res*. 2010;62(10):1446–1451. doi:10.1002/acr.20269
25. Prasad S, Misra R, Agarwal V, Lawrence A, Aggarwal A. Juvenile dermatomyositis at a tertiary care hospital: is there any change in the last decade? *Int J Rheum Dis*. 2013;16(5):556–560. doi:10.1111/1756-185x.12053
26. Ruperto N, Pistorio A, Oliveira S, et al. Prednisone versus prednisone plus ciclosporin versus prednisone plus methotrexate in new-onset juvenile dermatomyositis: a randomised trial. *Lancet*. 2016;387(10019):671–678. doi:10.1016/s0140-6736(15)01021-1
27. Bader-Meunier B, Decaluwe H, Barnerias C, et al. Safety and efficacy of rituximab in severe juvenile dermatomyositis: results from 9 patients from the French Autoimmunity and Rituximab registry. *J Rheumatol*. 2011;38(7):1436–1440. doi:10.3899/jrheum.101321

28. Uchino M, Yamashita S, Uchino K, et al. Long-term outcome of polymyositis treated with high single-dose alternate-day prednisolone therapy. *Eur Neurol*. 2012;68(2):117–121. doi:10.1159/000338474
29. Hsu CY, Ko CH, Wang JL, Hsu TC, Lin CY. Comparing the burdens of opportunistic infections among patients with systemic rheumatic diseases: a nationally representative cohort study. *Arthritis Res Ther*. 2019;21(1):211. doi:10.1186/s13075-019-1997-5
30. Cherin P, Piette JC, Wechsler B, et al. Intravenous gamma globulin as first line therapy in polymyositis and dermatomyositis: an open study in 11 adult patients. *J Rheumatol*. 1994;21(6):1092–1097.
31. Unger L, Kampf S, Lütke K, Aringer M. Rituximab therapy in patients with refractory dermatomyositis or polymyositis: differential effects in a real-life population. *Rheumatology*. 2014;53(9):1630–1638. doi:10.1093/rheumatology/keu024
32. Takada K, Katada Y, Ito S, et al. Impact of adding tacrolimus to initial treatment of interstitial pneumonitis in polymyositis/dermatomyositis: a single-arm clinical trial. *Rheumatology*. 2020;59(5):1084–1093. doi:10.1093/rheumatology/kez394
33. Tillie-Leblond I, Wislez M, Valeyre D, et al. Interstitial lung disease and anti-Jo-1 antibodies: difference between acute and gradual onset. *Thorax*. 2008;63(1):53–59. doi:10.1136/thx.2006.069237
34. Tsuji H, Nakashima R, Hosono Y, et al. Multicenter prospective study of the efficacy and safety of combined immunosuppressive therapy with high-dose glucocorticoid, tacrolimus, and cyclophosphamide in interstitial lung diseases accompanied by anti-melanoma differentiation-associated gene 5-positive dermatomyositis. *Arthritis Rheumatol*. 2020;72(3):488–498. doi:10.1002/art.41105
35. Shirai T, Machiyama T, Sato H, Ishii T, Fujii H. Intensive induction therapy combining tofacitinib, rituximab and plasma exchange in severe anti-melanoma differentiation-associated protein-5 antibody-positive dermatomyositis. *Clin Exp Rheumatol*. 2023;41(2):291–300. doi:10.55563/clinexprheumatol/8kulbf
36. Billet AC, Barba T, Coutant F, et al. Infection risk in patients with dermatomyositis associated with anti-MDA5 antibodies: a historical cohort study. *Biomedicine*. 2022;10(12). doi:10.3390/biomedicine10123176
37. Matsuda KM, Yoshizaki A, Kuzumi A, et al. Combined immunosuppressive therapy provides favorable prognosis and increased risk of cytomegalovirus reactivation in anti-melanoma differentiation-associated gene 5 antibody-positive dermatomyositis. *J Dermatol*. 2020;47(5):483–489. doi:10.1111/1346-8138.15274
38. Tsai SY, Lin CL, Wong YC, et al. Increased risk of herpes zoster following dermatomyositis and polymyositis: a nationwide population-based cohort study. *Medicine*. 2015;94(28):e1138. doi:10.1097/md.0000000000001138
39. Liu L, Zhang Y, Liu S, et al. Compound sulfamethoxazole improved the prognosis of dermatomyositis patients positive with anti-melanoma differentiation-associated gene 5. *Rheumatology*. 2023. doi:10.1093/rheumatology/kead034
40. Li J, Wang S, Zheng J, Li Q, Li J, Lu L. Clinical characteristics of and risk factors for *Pneumocystis jirovecii* pneumonia in anti-melanoma differentiation-associated gene 5 (Anti-MDA5) antibody-positive dermatomyositis patients: a single-center retrospective study. *Clin Rheumatol*. 2023;42(2):453–462. doi:10.1007/s10067-022-06403-9

Clinical, Cosmetic and Investigational Dermatology

Dovepress

Publish your work in this journal

Clinical, Cosmetic and Investigational Dermatology is an international, peer-reviewed, open access, online journal that focuses on the latest clinical and experimental research in all aspects of skin disease and cosmetic interventions. This journal is indexed on CAS. The manuscript management system is completely online and includes a very quick and fair peer-review system, which is all easy to use. Visit <http://www.dovepress.com/testimonials.php> to read real quotes from published authors.

Submit your manuscript here: <https://www.dovepress.com/clinical-cosmetic-and-investigational-dermatology-journal>