

Complaints of Men with Uncorrected Distal Hypospadias

Nicol Corbin Bush, Warren Snodgrass

The Hypospadias Specialty Center, The Colony, TX, USA

Correspondence: Nicol Corbin Bush, Email bush@hypospadias.com

Purpose: The few available reports regarding adults living with distal hypospadias give disparate views of the functional and aesthetic impact of this penile birth defect when it is not corrected. We reviewed symptoms and findings in consecutive men with unrepaired distal hypospadias and report those observations.

Material and Methods: Men with uncorrected hypospadias were queried regarding urinary symptoms, sexual dysfunction, and aesthetic concerns. Glans fusion around the meatus was measured. Penile curvature was confirmed by photographs of erections, and its degree objectively measured in those undergoing surgery.

Results: There were 51 men with a mean age of 42 years (18–63). None had glans fusion around the meatus, and the main symptom was urine spraying in 81%. Penile curvature was present in 33%. Painful sexual activity was reported by 34% due to penile curvature, exposed urethral mucosa, or a scrotal web. All but one man experienced functional problems. In addition, 60% were bothered by their abnormal appearance.

Conclusion: All but one of these men with uncorrected distal hypospadias had penile dysfunction, and 60% were additionally concerned about the atypical appearance of their penis. These results offer a different perspective than earlier reports which said that most men with uncorrected distal hypospadias were not bothered by their condition, and many were not aware of it.

Keywords: adult hypospadias, uncorrected hypospadias, urine spraying, sexual dysfunction

Introduction

Even though distal hypospadias is a common birth defect that is often surgically corrected, there is uncertainty regarding its impact when it is not repaired. Potential problems include urine spraying with difficulty standing to void, penile curvature and sexual dysfunction, and concerns regarding the appearance of the penis. Published data offer conflicting information as to how often men with uncorrected distal hypospadias experience these.

For example, one study reported that 10 of 16 men with coronal or subcoronal hypospadias were not even aware of their diagnosis, stating that all voided standing with a straight stream and had sexual intercourse without problems despite penile curvature in 1.¹ Another describing men with either uncorrected or unsuccessfully repaired hypospadias similarly found that a third of them were not aware of their condition. However, 36% reported urinary spraying or deviation, and 12% had “mild to moderate” penile curvature. Nevertheless, these men were not interested in surgery, which led the authors to conclude that many men with hypospadias adapt to their condition over time.²

In contrast, a web-based comparison between self-identified normal men and 37 with untreated distal hypospadias found no difference in sitting to urinate, which was the only query regarding urination, but reported the latter were less satisfied with the position and shape of the meatus and had more ventral penile curvature and difficulty with sexual intercourse.³ Another series of men with uncorrected hypospadias, primarily referred from other urologists to specialists, reported that urinary symptoms were present in over half of them, mostly straining to void with incomplete emptying or spraying with sitting to void. In addition, 5% had ventral penile curvature.⁴ Finally, a smaller study of 7 untreated adults with hypospadias found that 6 had voiding problems and 4 had penile curvature.⁵

Our practice is limited to hypospadias and accepts patients of all ages with that condition. Given the paucity of reports concerning uncorrected hypospadias in adults, the disparities between them, and the importance of better knowledge regarding the impact when reconstructive surgery has not been performed, we reviewed men presenting to our center with unoperated hypospadias to determine their functional and aesthetic concerns.

Materials and Methods

Distal hypospadias was defined as a urinary opening on the distal shaft to proximal glans. Consecutive Tanner V adults with unoperated distal hypospadias were identified from a prospectively maintained database. All were queried about the urinary stream, straightness of erections, sexual dysfunction, and aesthetic concerns. Each provided photographs of their penis showing the glans and meatus, and an erection in those who reported penile curvature.

Glans fusion, the distance from the ventral lip of the meatus to the corona, was determined from preoperative photographs and again assessed intraoperatively in those undergoing surgery (Figure 1). The extent of the reported ventral curvature was estimated from provided photographs of the erection and measured intraoperatively using a goniometer.

Statistical analysis was done by Fisher's exact test using an on-line calculator. This descriptive study had IRB approval by Pearl IRB committee (protocol #23-HYPO-101) with additional patient consent exemption given minimal risk on existing data. The study also conforms to the ethical principles of the Declaration of Helsinki. The abstract of this paper was presented at the American Urological Association annual meeting 2021 as an abstract presentation with interim findings. The poster's abstract was published in "Poster Abstracts" in The Journal of Urology [<https://doi.org/10.1097/JU.0000000000002068.08>].

Results

A total of 53 men presented with unoperated distal hypospadias from 2017 to 2021 at a mean age of 42 years (18–63; median 44) requesting information about their condition. The defect was classified as MIP (14), coronal (13), subcoronal (20), distal shaft, and not recorded in 1. Twenty-seven (51%) had been circumcised. Representative photographs are shown in Figure 2. None of the patients had measurable glans fusion around the meatus.

Of these, 41 of 50 (82%) with a recorded response experienced urine spraying (Figure 3). Seventeen of 53 (33%) had ventral or lateral² curvature that averaged 36° (15–65) in the 11 whose bending was objectively measured. That curvature made penetration difficult in 1 and caused discomfort to the sexual partner in 5. A total of 18 (34%) men reported painful sexual activity, 7 due to penile curvature, 8 from irritation of the exposed urethral mucosa, 2 whose scrotal webs chafed their wives, and 1 due to a tight partial foreskin. Thirty-two (60%) were additionally bothered by their abnormal appearance.

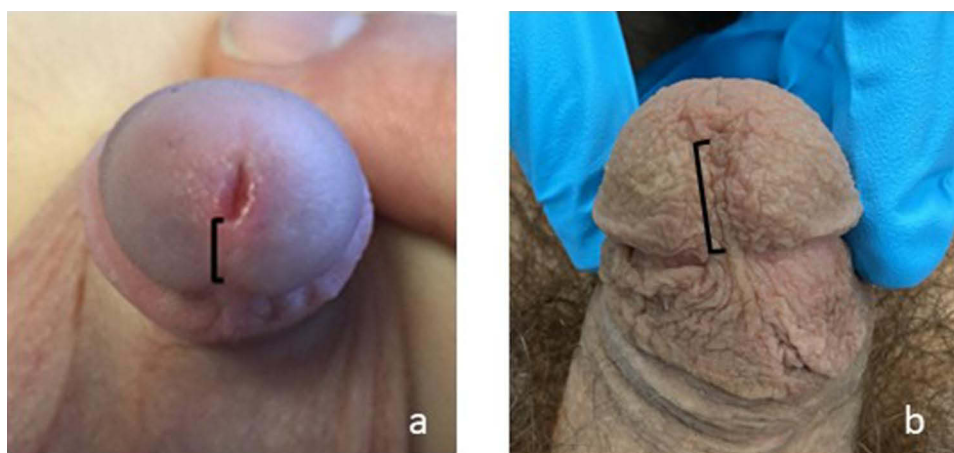


Figure 1 Normal glans fusion in a prepubertal patient (a) and a circumcised adult (b). The bracket indicates the distance from the lower lip of the meatus to the corona.

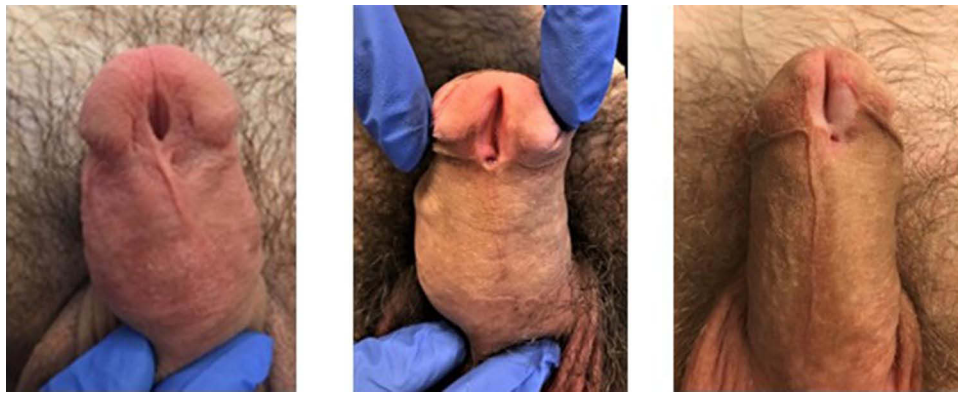


Figure 2 Three representative men with uncorrected hypospadias included in this report. Note that none have glans fusion.

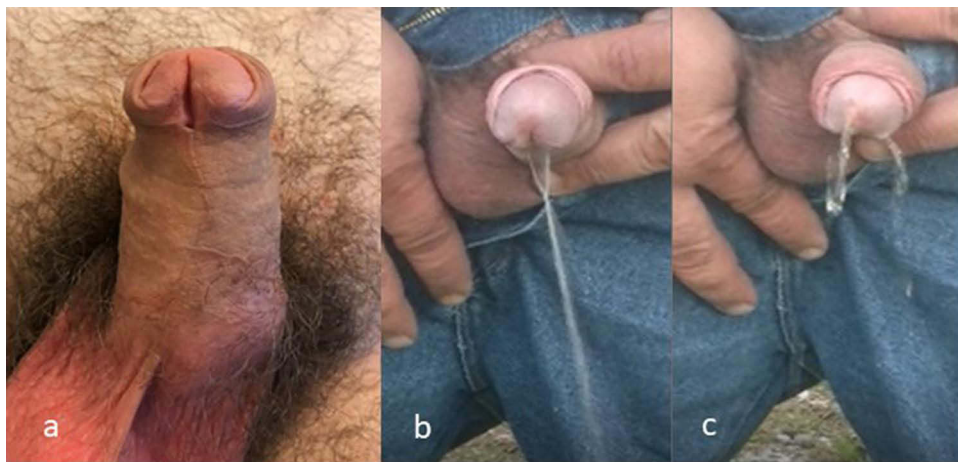


Figure 3 Still photograph in a patient with uncorrected hypospadias (a) and video capture of his deflected and splattering stream (b and c). The initial stream is deflected downwards and spreads into a fan shape (b). Near the end of voiding, the stream splatters (c).

A functional problem occurred in all but one man, whose interest in surgery was to improve the appearance of his penis. All others had an abnormal urinary stream and /or sexual dysfunction. Of these 53 men, 38 (72%) underwent hypospadias repair. Of the 15 who did not have surgery, 4 cancelled the scheduled operation without explanation, 1 had a medical condition that precluded repair, 3 had insurance problems, 2 were recently evaluated, and 5 never scheduled after their consultation.

There were no significant differences in the men who underwent repair versus those who did not in terms of mean age (42 vs 37 years), urine spraying (82% vs 80%), ventral curvature (30% vs 33%; mean 33° vs 34°), sexual dysfunction (33% vs 53%, $p=0.22$), or concerns for penile appearance (60% vs 63%).

Discussion

All but one of these 53 consecutive men with uncorrected distal hypospadias had penile dysfunction. Urine spraying was the most common complaint, occurring in 82%. Ventral or lateral penile curvature affected 33%, while 34% reported painful sexual activity for themselves and/or their partners. Sixty percent were also dissatisfied with the appearance of their penis. Rather than being unaware of their condition or becoming accustomed to it, these mostly middle-aged men wanted information about surgical correction of their birth defect and 72% of them had it repaired.

These observations regarding voiding differ from Fichtner et al¹ who stated that the men they evaluated all had a “single, forward directed” stream, but are similar to Dodd et al,² Leunenback et al and Ching et al⁵ who reported urinary symptoms, mostly spraying, in from 36% to 86%. Importantly, our patients expressed greater difficulty and

frustration related to urination than Fichtner et al and Dodd et al implied. Typically, they explained the stream was compact initially when it was most forceful but sprayed and splattered near the end of urination when pressure decreased or when they voided with an incompletely filled bladder. Several provided videos showing their abnormal stream, and pictures taken from one of those are seen in Figure 3. Furthermore, the variable nature of the stream added worry, since many could not reliably anticipate when it would spray and so they always had to take precautions to avoid splattering on themselves or others standing nearby. Some described first checking if a public toilet was empty before standing at a urinal, and using a stall when it was occupied. Others said they pressed abnormally close to the urinals to keep the stream inside them. Despite these measures accidents sometimes occurred, and one man related the embarrassment of having to call his wife from work to bring him a fresh pair of pants after his stream sprayed onto the pants he was wearing. These statements make clear that standing to void is not the same as voiding normally, and the simple question if a man urinates standing may not capture the real nature of his urination.

Persistent urine spraying is not typical of men with normal anatomy, with the urethral meatus enclosed by the glans as shown in Figure 1. This normal glanular anatomy was defined by Hutton and Babu⁶ in boys as glans fusion below the meatus averaging 4.7mm with a minimum of 2.3mm, and we have found that fusion in adults averages 10mm. Although Fichtner et al stated that 10% of normal men had a meatus on the proximal glans with no glans fusion, 2 subsequent studies disputed those results, finding that less than 1% of normal men or boys had a meatus on the proximal glans.^{7,8} None of our adult patients with uncorrected distal hypospadias had glans fusion around the meatus and 81% of them commonly sprayed. Similarly, 92% of men we previously evaluated after childhood repair who had no or subnormal glans fusion, either because the surgeon intentionally placed the neomeatus below the normal meatal location or glans dehiscence returned the meatus to an abnormal position, complained of urine spraying.⁹ This spraying was resolved after reoperation created normal glans fusion. These observations support a conclusion that the abnormal anatomy of distal hypospadias predisposes to abnormal urinary function, and that measuring glans fusion provides an objective means to determine who is likely to benefit from repair.

We also found that 33% of men with uncorrected distal hypospadias had penile curvature averaging 36° and ranging to 65°. Although the association between hypospadias and penile curvature is well known, its prevalence specifically in distal hypospadias is not well defined. We previously published that ventral and lateral curvature occurred in 11% and 2% of distal hypospadias patients, respectively, and that all ventral bending was less than 30°. ¹⁰ However, that underestimated the actual prevalence and likely its severity, since patients found to have more than 30° were considered to have a proximal hypospadias variant and were not included in the distal hypospadias database, and the degree of curvature was visually estimated rather than objectively measured. Another recent study similarly reported ventral curvature in 31% of distal hypospadias. ¹¹

In contrast to the comments by Fichtner et al and Dodds et al that men with hypospadias had no difficulties with sexual intercourse, ventral curvature in our series caused sexual dysfunction for a third of the affected men and their sexual partners. Some of the others not reporting dysfunction nevertheless said there were positions they avoided because of the curvature. A prior internet survey regarding uncorrected penile curvature also found that adult men with ventral bending as little as 20° reported difficulties with sexual intercourse and had more unhealthy mental days than did men who self-identified as having a straight penis. ¹²

Furthermore, 1 out of every 4 men in our series with uncorrected hypospadias and straight erections reported painful irritation of the exposed urethral mucosa during intercourse. Leunback et al found coital pain was the chief complaint in 8% of their patients and was especially likely in those with MIP who have a larger than normal meatus which exposes more urethral tissues. Two other men in our series said that the scrotal web extending up their penile shaft chafed their wives because of hair growth. Taken together, 34% of men in our report had bothersome intercourse related to their uncorrected hypospadias.

Both Fichtner et al and Dodds et al said that few men expressed concern regarding the appearance of their penis, and that from a third to half of them were not even aware of their hypospadias. Neither provided representative photographs of these men. In contrast, Leunback et al stated only one man was unaware of his hypospadias, and aesthetic concerns were the chief complaint in 17% of their patients. Even though all but one man in our series presented with functional problems that they wanted corrected, dissatisfaction with the appearance of the penis was an additional motivation to

consider surgery in 60% of them. Several commented that they delayed intimacy and had fewer sexual partners specifically from concern that a new lover would ask what was wrong with their penis.

Despite urinary spraying, penile curvature, sexual dysfunction, and dissatisfaction with their penile appearance affecting our patients, critics may object that these men are not representative of a larger pool of adults living with unoperated distal hypospadias. The potential size of such a pool is unknown and cannot be estimated since there is no standardized definition of hypospadias to accurately determine its prevalence and the number of distal repairs done in children is not reported. Nevertheless, selection bias could influence the observations we report.

However, even if some men with abnormal penile anatomy will grow into teens and adults without urinary symptoms, penile curvature or sexual dysfunction, or dissatisfaction with their penile appearance, our study, and the findings of others that we cite, undeniably indicate that distal hypospadias does cause penile dysfunction in at least some males born with it. Given that urine spraying is associated with subnormal glans fusion, and that as many as a third of patients with distal hypospadias may have penile curvature that can affect sexual function, careful examination of infants for these objective signs should help identify those likely to benefit from surgical repair. Certainly, our observations and similar ones made by others describing penile dysfunction in men with uncorrected distal hypospadias indicate the condition is potentially more than just a “cosmetic” concern.

Conclusions

We report symptoms in a series of men with uncorrected distal hypospadias, which included urine spraying, penile curvature and sexual dysfunction, and dissatisfaction with the appearance of their penis. Despite a median age of 44 years, these patients were sufficiently bothered to seek more information about their condition and 72% underwent hypospadias repair. These observations, and those of other recent studies, offer a different perspective than earlier reports which said that most men with uncorrected distal hypospadias were not bothered by their condition, and many were not aware of it.

Abbreviations

Glans, head of the penis; Meatus, urinary opening; MIP, megameatus intact prepuce hypospadias.

Disclosure

The authors report no conflicts of interest in this work.

References

1. Fichtner J, Filipas D, Mottrie AM, Voges GE, Hohenfellner R. Analysis of meatal location in 500 men: wide variation questions need for meatal advancement in all pediatric anterior hypospadias cases. *J Urol.* 1995;154(2):833. doi:10.1016/S0022-5347(01)67177-5
2. Dodds PR, Batter SJ, Shield DE, Serels SR, Garafola FA, Maloney PK. Adaptation of adults to uncorrected hypospadias. *Urology.* 2008;71(4):682. doi:10.1016/j.urology.2007.07.078
3. Schlomer B, Breyer B, Copp H, Baskin L, DiSandro M. Do adult men with untreated hypospadias have adverse outcomes? A pilot study using a social media advertised survey. *J Pediatr Urol.* 2014;10(4):672. doi:10.1016/j.jpuro.2014.01.024
4. Leunback TL, Skott M, Ernst A, Hvistendahl GM, Rawashdeh YF. Referral patterns, clinical features and management of uncorrected hypospadias in a series of adult men. *J Pediatr Urol Online Ahead of Print.* 2022;2:57.
5. Ching CB, Wood HM, Ross JH, Gao T, Angermeier KW. The Cleveland Clinic experience with adult hypospadias patients undergoing repair: their presentation and a new classification system. *BJU Int.* 2010;107(7):1142. doi:10.1111/j.1464-410X.2010.09693.x
6. Hutton KAR, Babu R. Normal anatomy of the external urethral meatus in boys: implications for hypospadias repair. *BJU Int.* 2007;100(1):161. doi:10.1111/j.1464-410X.2007.06798.x
7. Uygun MC, Ersoy E, Erol D. Analysis of meatal location in 1244 healthy men. Definition of the normal site justifies need for meatal advancement in pediatric anterior hypospadias cases. *Pediatr Surg Int.* 1999;15(2):119. doi:10.1007/s003830050530
8. Genc A, Taneli C, Oksel F, Balkan C, Bilgi Y. Analysis of meatal location in 300 boys. *Int Urol Nephrol.* 2001;133(4):663–664. doi:10.1023/A:1020570900143
9. Snodgrass W, Bush N. Do new complications develop during puberty after childhood hypospadias repair? *J Urol.* 2022;208(3):696. doi:10.1097/JU.0000000000002738
10. Snodgrass W, Bush N. Hypospadias. In: Wein A, editor. *Campbell's Urology.* 10. 2011.
11. Stojanovic B, Bizic M, Majstorovic M, Kojovic V, Djordjevic M. Penile curvature incidence in hypospadias: can it be determined? *Adv Urol.* 2011. doi:10.1155/2011/813205
12. Menon V, Breyer B, Copp HL, Baskin L, Disandro M, Schlomer BJ. Do adult men with untreated ventral penile curvature have adverse outcomes? *J Pediatr Urol.* 2016;12(1):31. doi:10.1016/j.jpuro.2015.09.009

Research and Reports in Urology**Dovepress****Publish your work in this journal**

Research and Reports in Urology is an international, peer-reviewed, open access journal publishing original research, reports, editorials, reviews and commentaries on all aspects of adult and pediatric urology in the clinic and laboratory including the following topics: Pathology, pathophysiology of urological disease; Investigation and treatment of urological disease; Pharmacology of drugs used for the treatment of urological disease. The manuscript management system is completely online and includes a very quick and fair peer-review system, which is all easy to use. Visit <http://www.dovepress.com/testimonials.php> to read real quotes from published authors.

Submit your manuscript here: <https://www.dovepress.com/research-and-reports-in-urology-journal>