



# Descemetic Deep Anterior Lamellar Keratoplasty versus Penetrating Keratoplasty in Advanced Keratoconus: Comparison of Visual and Refractive Outcomes

Leopoldo Spadea , Lucia Di Genova, Edoardo Trovato Battagliola , Stefano Scordari

Eye Clinic, Policlinico Umberto I, "Sapienza" University of Rome, Rome, Italy

Correspondence: Leopoldo Spadea, Head Eye Clinic, Policlinico Umberto I, "Sapienza" University of Rome Via Benozzo Gozzoli 34, Rome, 00142, Italy, Tel +39065193220, Fax +390688657818, Email leopoldo.spadea@uniroma1.it

**Purpose:** To assess and contrast the visual and refractive results of Descemetic deep anterior lamellar keratoplasty (DALK) and penetrating keratoplasty (PK) in the treatment of advanced keratoconus.

**Design:** Retrospective, comparative, interventional study.

**Methods:** This study enrolled eyes affected by keratoconus with preoperative mean keratometry  $\geq 60$  diopters (D) that were treated with either Descemetic DALK (30 eyes) or PK (29 eyes) by using always the same corneal diameters (8.00mm recipient; 8.25mm donor cornea) and the same suture technique (10–0 nylon double-running 12-bites continuous suture). The outcome measures were postoperative uncorrected distance visual acuity (UDVA), best-corrected distance visual acuity (CDVA), subjective refractive astigmatism (SRAst), and keratometric astigmatism at 3mm area (SimK), spherical equivalent (SEq).

**Results:** Postoperative visual acuity significantly improved in both groups. Mean CDVA was higher in the DALK group 3 months (DALK 0.61, PK 0.42,  $p < 0.05$ ), 6 months (DALK 0.69, PK 0.44,  $p < 0.05$ ), and 12 months (DALK 0.72, PK 0.45,  $p < 0.05$ ) postoperatively. However, 6 months after suture removal, CDVA was not statistically different between the two groups (DALK 0.71, PK 0.75,  $p > 0.05$ ). Final SRAst and SimK also were comparable between the two groups (respectively DALK 2.97, PK:2.81,  $p > 0.05$ ; DALK 3.91, PK 2.37,  $p > 0.05$ ). No significant statistical differences were noted for UCVA and SEq data during the entire follow-up period between the two groups.

**Conclusion:** Both methods of corneal transplantation resulted in a notable enhancement of visual and refractive outcomes in eyes afflicted by advanced keratoconus. Descemetic DALK demonstrated superior visual acuity before suture removal, whereas DALK and PK exhibited comparable results in terms of visual acuity, refractive correction, and keratometric astigmatism after suture removal.

**Keywords:** astigmatism, corneal topography, descemetic dalk, keratoconus, PK

## Introduction

Keratoconus is a condition characterized by progressive thinning and steepening of the cornea, resulting in irregular astigmatism and reduced visual acuity. Initially thought to be noninflammatory, recent research suggests a link with ocular inflammation.<sup>1</sup> It typically manifests in the second and third decades of life, affecting both sexes and all ethnicities. Prevalence ranges from 0.2 to 4790 per 100,000 individuals, with higher rates among 20- to 30-year-olds and certain ethnic groups, particularly those of Middle Eastern and Asian descent.<sup>2</sup> Histopathologically, progressive stromal thinning and ectasia of the central cornea are common findings. Risk factors include a family history of the condition, eye rubbing, eczema, asthma, and allergies. Early detection remains challenging, with corneal topography being the primary diagnostic tool. However, in early stages, additional measures such as corneal pachymetry and higher order aberration data are often necessary. Classification of keratoconus severity and progression involves morphological features, ocular signs, and index-based systems. Treatment varies depending on severity, ranging from spectacles for mild cases to scleral contact lenses for moderate ones. Severe cases

may require corneal surgery, while mild to moderate progressive keratoconus can often be managed with corneal cross-linking.<sup>2</sup>

Penetrating keratoplasty (PK) has been one of the main surgical treatment options for the management of keratoconus.<sup>3,4</sup> In long-term follow-up studies, PK has evidenced good results, irrespective of graft size.<sup>4</sup> However, 18 to 34% of patients develop an immunological rejection after PK, with consequent endothelial cell loss and graft failure.<sup>5,6</sup> Deep anterior lamellar keratoplasty (DALK) is a good alternative when the pathology is localized in the anterior stroma with an unaffected endothelium.<sup>7</sup> Even though DALK is generally a more time-consuming procedure compared to PK, it is considered to be associated with fewer intraoperative and postoperative complications. The risk for iris prolapse, suprachoroidal hemorrhage, choroidal effusion, endophthalmitis, or graft rejection is significantly lower.<sup>8–10</sup> Furthermore, as compared to PK, post-DALK globes are more resistant to blunt trauma, steroid treatments can be used for a shorter period, and sutures can be removed earlier, as the wound heals earlier.<sup>11</sup>

DALK can be defined as pre-Descemet (a small amount of posterior stroma is left together with Descemet's membrane) or Descemet (realizing separation to bare Descemet's membrane). Several dissection techniques have been described. These include the big bubble technique,<sup>12</sup> hydrodissection,<sup>13</sup> viscodissection,<sup>14</sup> or manual dissection.<sup>15</sup> However, as compared to PK, DALK is a longer procedure and has a steeper learning curve.<sup>16</sup>

Unfortunately, after a corneal transplantation, unsatisfactory refractive results can affect the clinical success of a clear graft.<sup>7,11,13</sup> This paper compares the visual and refractive outcomes after uneventful Descemet DALK and PK in patients with advanced keratoconus.

## Patients and Methods

The present study was performed in accordance with the principles stated in the Declaration of Helsinki. Ethical approval was obtained from the local Institutional Review Board (IRB) of the "Sapienza" University of Rome, Umberto I Hospital (Prot. #0285/2020). Informed consent was obtained from all patients before enrollment. This is a retrospective comparative interventional case series study conducted in a referral center for corneal pathologies. The population included subjects affected by advanced keratoconus ( $>60$  D) who were scheduled for a corneal transplant to improve their visual acuity. Only patients who had the following features at baseline were selected: age 18 and above, distance-corrected visual acuity (CDVA) with RGP lenses  $<3/10$  or RGP lenses intolerance, diagnosis of keratoconus stage IV (according to the Amsler-Krumeich classification).<sup>17,18</sup> Patients with other indications for corneal transplant, co-existing ocular disease (eg active uveitis, keratitis, corneal ulcer, or glaucoma, among others), or history of acute hydrops were excluded from the study. Patients who showed signs of graft failure or rejection during the follow-up were not included in the present study.

All patients underwent a comprehensive preoperative ophthalmological assessment. They were queried regarding the presence of bothersome visual symptoms such as photophobia and glare. The evaluation encompassed a thorough review of ocular and systemic medical history, slit-lamp examination of both the anterior and posterior segments, assessment of uncorrected distance visual acuity (UDVA), measurement of best-corrected distance visual acuity (CDVA), determination of subjective refractive astigmatism (SRAst), evaluation of keratometric astigmatism at a 3mm radius (SimK), determination of spherical equivalent (SEq), assessment of the highest keratometry value on anterior topography (Kmax), and measurement of minimum corneal thickness (MCT). The device used to measure the SimK and the corneal thickness was a Scheimpflug corneal tomographer (Pentacam HR, Oculus, Germany). Four tomographic images were obtained for each eye and the best image was chosen. Intraocular pressure was measured using the Goldmann applanation tonometer. The pre-operative evaluation also included refraction under cycloplegia and posterior segment examination.

## Power Size Determination and Statistical Analysis

The minimum number of subjects in each group was set at 28 to detect: a difference of 1.5D or more in keratometric/refractive astigmatism between the two groups, and a difference of 2 lines or more in CDVA. The calculations above were performed assuming an alpha error of 0.05 and a power of 80%. Statistical analysis was performed using SPSS v.21 (SPSS, Chicago, Illinois, USA). The quantitative data were described as mean  $\pm$  standard deviation and nominal data as frequencies. The independent samples *t*-test was used to compare each continuous variable between the two groups at baseline, then 1, 3, 6, and

12 months postoperatively, as well as 6 months following complete suture removal. Repeated-measures ANOVA was used to compare the same variable across the whole follow-up period. A p-value of  $<0.01$  was considered statistically significant.

## Surgical Technique and Post-Operative Care

DALK was the preferred technique in all patients. In the case of Descemet's membrane macro-perforation during dissection, PK was performed instead. A macro-perforation was defined as Descemet's membrane perforation and inability to maintain an anterior chamber after the injection of air or BSS. All surgeries were performed by the same experienced surgeon (LS). Both DALK and PK were always performed under general anesthesia. The donor corneas were preserved in Optisol medium (Chiron Ophthalmics, Irvine, CA). The initial step involved the preparation and punching of the donor tissue. Subsequently, the surgeon marked the center of the recipient cornea using a surgical pen, positioned a single-use adjustable trephine (Moria, France) over the cornea, and generated suction by pulling on the syringe. The host trephination diameter was 8mm and the corneal button size was 8.25mm for all patients. The use of a corneal button 0.25mm larger than the diameter of the host corneal opening was chosen to reduce excessive postoperative corneal flattening, the risk of secondary glaucoma and to enhance wound closure. A non-perforating trephination was performed; the anterior corneal surface was cut with a suction trephine set to a depth of about two-thirds of the corneal thickness (from 400 to 500  $\mu$ m). To complete the dissection of the stromal layers the "big-bubble technique" was used. Air was introduced through a specialized DALK cannula, capitalizing on the inherent virtual space between the posterior stroma and Descemet membrane (DM). Following this, a 30-gauge needle bent at a 30° angle 5mm from its tip, was carefully inserted with the bevel facing downward through the trephination groove. It traversed the paracentral corneal stroma in parallel to DM. In the case of a type 1 bubble, the air would initially flow through the central cornea and then extend outward radially, creating a separation between the pre-Descemet's layer and the overlying stroma. For a type 2 bubble, the air would first expand peripherally and then progress inward centripetally, resulting in a division between the pre-Descemet's layer and the Descemet membrane. If the air bubble failed to form, a manual dissection technique was employed. However, it's important to note that cases requiring this manual dissection approach were excluded from the present study. In fact, manually dissected DALK generally results in inferior visual outcomes compared to pneumatic dissection.<sup>19</sup>

A sharp 2.4mm pre-calibrated blade was then used to puncture the anterior wall of the bubble (posterior stromal) and blunt scissors were used to cut the stroma into quadrants and excise it within the trephination. The epithelium and anterior stroma were then removed. The formation of a peripheral paracentesis to reduce intraocular pressure was performed. The punched donor button was then prepared, using a dry Weck-cel sponge to detach the Descemet membrane and endothelium from the posterior stroma by using trypan blue to facilitate this step. The stromal surface must be smooth and regular to achieve the best optical quality of the graft-host interface. The cornea was then sutured in place, the first four 10-0 nylon cardinal sutures were placed at 12, 3, 6, and 9 positions. The placement of a 10-0 nylon 12-bites double-running continuous suture was performed.

In the case of DM's macro-perforation a PK was performed. The anterior chamber was filled with viscoelastic and the entire host cornea was removed. In all cases, a basal iridectomy was performed. Finally, the donor cornea was sutured using the same technique as described for DALK. The viscoelastic was then removed from the anterior chamber with the injection of a balanced salt solution at one opening in the graft host junction.

All patients received gentamicin sulfate, 20mg intramuscularly, methylprednisolone, 30mg intramuscularly, and ofloxacin 0.3% eye drops after surgery. All the eyes were patched until corneal epithelial defects healed. Patients were instructed to apply topical dexamethasone 0.1% and moxifloxacin 0.5% every three hours, for one month. The topical steroid regimen was tapered over 3 months. The sutures were removed in both groups 18 months postoperatively.

## Results

The enrollment period spanned between May 2018 and December 2020. A total of 59 subjects were enrolled. The study population was then divided into two arms according to the surgical procedure performed. Thirty (n=30) patients underwent the intended DALK procedure. The remainder twenty-nine patients (n=29) were converted to PK due to Descemet's membrane macro-perforation during dissection. Demographic characteristics and baseline values are outlined in Table 1. For all patients, the same surgical technique was used, using the same corneal diameters (8.00mm recipient; 8.25mm donor cornea) and the same suture technique (10-0 nylon double-running 12-bites continuous suture). (Figure 1)

**Table 1** Baseline Data

	DALK	PK	p-value
N. Subjects	30	29	
Age	37.2 ± 13	49.7 ± 15	> 0.01
UDVA	0.06 ± 0.05	0.03 ± 0.03	> 0.01
CDVA	0.19 ± 0.2	0.09 ± 0.1	> 0.01
SEq	-3.35 ± 4.97	-5.38 ± 6	> 0.01
SRAst	3.51 ± 3.2	3.42 ± 2.7	> 0.01
SimK	6.52 ± 5.8	8.48 ± 6.2	> 0.01
CCT	412.57 ± 84	341.53 ± 98	0.001
K Max (D)	67.0 ± 15.21	78.1 ± 21.43	> 0.01

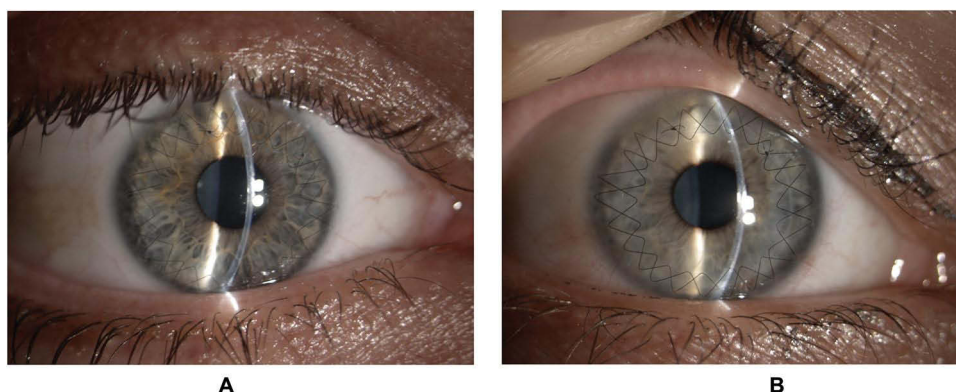**Notes:** Calculated across the central 3mm; CCT: minimum central corneal thickness (μm); K Max: highest pre-operative keratometry value on corneal topography. The independent samples t-test was used to compare each variable between the two groups.

**Abbreviations:** Age, years; UDVA, uncorrected distance visual acuity (Snellen); CDVA, corrected-distance visual acuity (Snellen); SEq, spherical equivalent (D); SRAst, subjective refractive astigmatism (D); SimK, keratometric astigmatism (D).

All the variables were measured at baseline, as well as 3, 6, and 12 months postoperatively, as well as 6 months following suture removal (final follow-up). Visual acuity measurements and refractions were performed by masked residents at every examination.

No intraoperative complications were evidenced in both groups. No adjustment of sutures was performed. Graft failure and rejection did not occur during the follow-up in any of the cases in the study groups. No cases of retransplantation were necessary.

Results during follow-up are reported in [Tables 2–6](#). Statistically significant differences emerged for preoperative pachymetry value and mean CDVA during the first postoperative year, which is before suture removal. In particular, it resulted that the mean baseline pachymetry value was lower in the PK group (PK 341.53μm, DALK 412.57μm,  $p=0.026$ ). Regarding visual acuity, the mean CDVA 3 months postoperatively was higher in the DALK group (DALK 0.61, PK 0.42,  $p=0.008$ ). The same result emerged for mean CDVA 6 months postoperatively (DALK 0.69, PK 0.44,  $p=0.01$ ), and 12 months postoperatively, which also resulted to be higher in the DALK group (DALK 0.72, PK 0.45,  $p=0.02$ ). This means that just before suture removal, in the DALK group, 50% of the subjects had a CDVA of 0.7 or better, while in the PK group half of the subjects had a CDVA of 0.4 or better. Statistically-significant differences in terms of CDVA were lost in the last follow-up, that is 6 months following complete suture removal (DALK 0.71, PK 0.75,  $p=0.770$ ). In both groups, half of the subjects finally had a comparable CDVA of 0.7 or better. ([Figure 2](#)) No statistically significant differences were noted for UCVA and spherical equivalent data between the two groups during the



**Figure 1** Slit lamp biomicroscopic images. **(A)** The right eye of a 28-years-old male patient after 12 months from Descemet's DALK. **(B)** The right eye of a 35-years-old female patient's eye after 6 months from PK. Both corneas are clear assessing the success of the transplant and a 10–0 nylon double-running 12 bites continuous suture is visible.

**Table 2** Outcome Variables 1 Month Post-Operatively

	DALK	PK	p-value
UCVA	0.13 ± 0.12	0.18 ± 0.23	> 0.01
CDVA	0.42 ± 0.2	0.31 ± 0.2	> 0.01
SEq	-2.1 ± 2.24	-2.09 ± 6.25	> 0.01
SRAst	2.37 ± 2.4	3.20 ± 2.5	> 0.01
SimK	5.54 ± 2.4	6.68 ± 3.8	> 0.01

**Notes:** calculated across the central 3mm. The independent samples t-test was used to compare each variable between the two groups.

**Abbreviations:** UDVA, uncorrected distance visual acuity (Snellen); CDVA, corrected-distance visual acuity (Snellen); SEq, spherical equivalent (D); SRAst, subjective refractive astigmatism (D); SimK, keratometric astigmatism (D).

**Table 3** Outcome Variables 3 Months Post-Operatively

	DALK	PK	p-value
UCVA	0.15 ± 0.23	0.17 ± 0.1	> 0.01
CDVA	0.61 ± 0.2	0.42 ± 0.2	0.005
SEq	-2.25 ± 2.82	-2.79 ± 5.53	> 0.01
SRAst	3.14 ± 1.9	3.41 ± 2.7	> 0.01
SimK	4.61 ± 2.7	6.49 ± 3.3	> 0.01

**Notes:** calculated across the central 3mm. The independent samples t-test was used to compare each variable between the two groups.

**Abbreviations:** UDVA, uncorrected distance visual acuity (Snellen); CDVA, corrected-distance visual acuity (Snellen); SEq, spherical equivalent (D); SRAst, subjective refractive astigmatism (D); SimK, keratometric astigmatism (D).

**Table 4** Outcome Variables 6 Months Post-Operatively

	DALK	PK	p-value
UCVA	0.13 ± 0.15	0.15 ± 0.08	> 0.01
CDVA	0.69 ± 0.3	0.44 ± 0.2	0.005
SEq	-1.84 ± 3.62	-1.29 ± 4.2	> 0.01
SRAst	3.37 ± 1.8	3.44 ± 1.7	> 0.01
SimK	4.45 ± 2.5	6.78 ± 3.7	> 0.01

**Notes:** calculated across the central 3mm. The independent samples t-test was used to compare each variable between the two groups.

**Abbreviations:** UDVA, uncorrected distance visual acuity (Snellen); CDVA, corrected-distance visual acuity (Snellen); SEq, spherical equivalent (D); SRAst, subjective refractive astigmatism (D); SimK, keratometric astigmatism (D).

**Table 5** Outcome Variables 12 Months Post-Operatively

	DALK	PK	p-value
UCVA	0.16 ± 0.26	0.20 ± 0.15	> 0.01
CDVA	0.72 ± 0.2	0.45 ± 0.3	0.005
SEq	-2.35 ± 2.1	-3.02 ± 5.61	> 0.01
SRAst	3.17 ± 2.4	2.90 ± 2.1	> 0.01
SimK	4.14 ± 2.2	4.31 ± 2.7	> 0.01

**Notes:** calculated across the central 3mm. The independent samples t-test was used to compare each variable between the two groups.

**Abbreviations:** UDVA, uncorrected distance visual acuity (Snellen); CDVA, corrected-distance visual acuity (Snellen); SEq, spherical equivalent (D); SRAst, subjective refractive astigmatism (D); SimK, keratometric astigmatism (D).

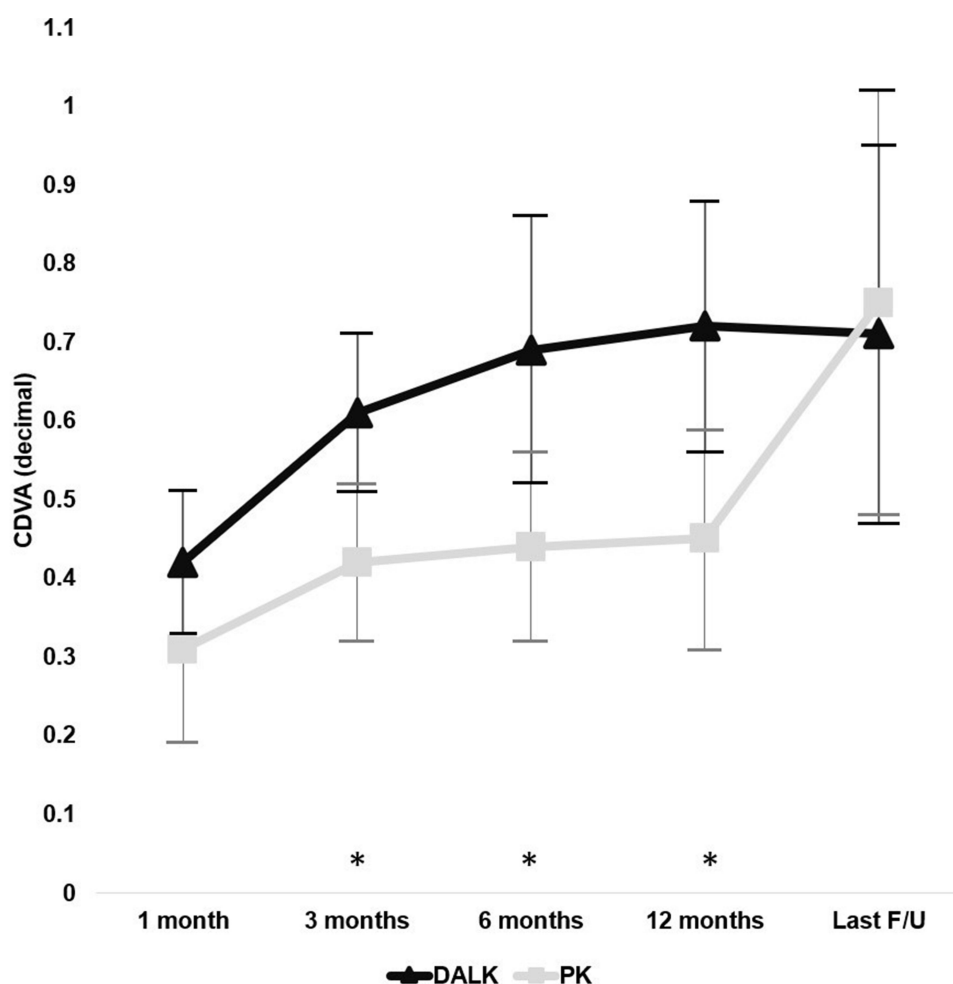
**Table 6** Outcome Variables 6 Months Following Suture Removal

	DALK	PK	p-value
Suture removal	530 ± 62	551 ± 71	> 0.01
UCVA	0.13 ± 0.06	0.17 ± 0.19	> 0.01
CDVA	0.71 ± 0.2	0.75 ± 0.2	> 0.01
SEq	-2.96 ± 3.11	-1.34 ± 3.44	> 0.01
SRAst	2.97 ± 1.8	2.81 ± 1.9	> 0.01
SimK	3.91 ± 2.3	2.37 ± 1.9	> 0.01

**Notes:** Suture removal: time elapsed since the sutures were removed (days). Calculated across the central 3mm. The independent samples t-test was used to compare each variable between the two groups.

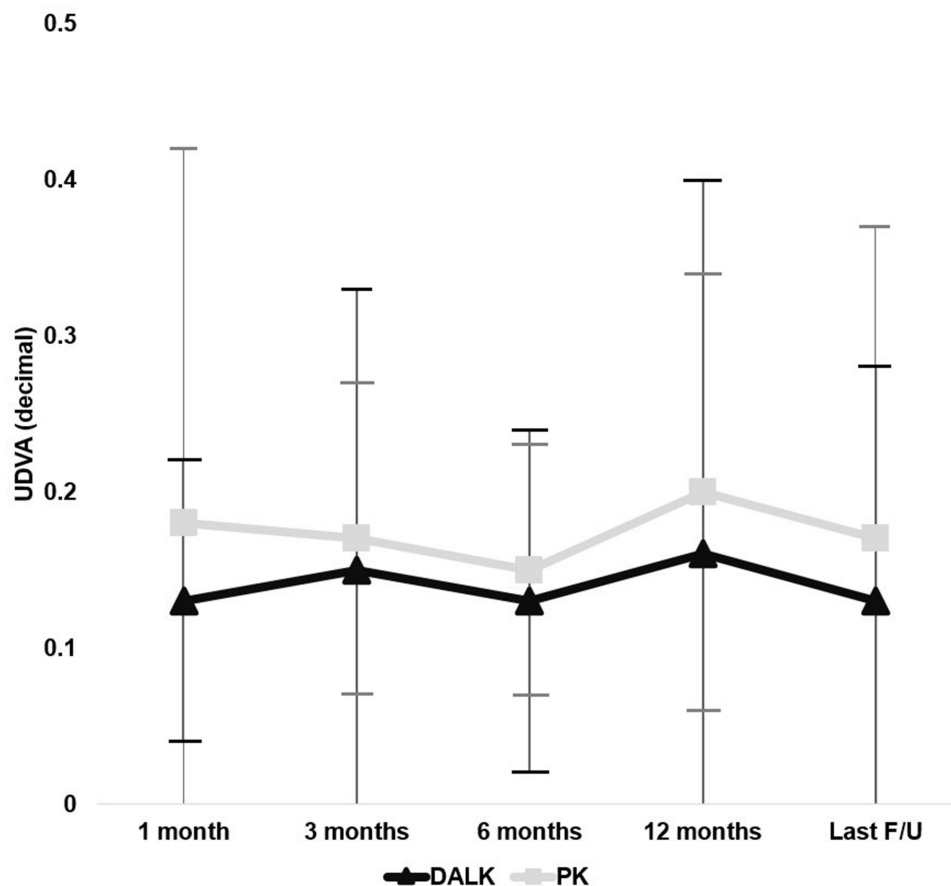
**Abbreviations:** UDVA, uncorrected distance visual acuity (Snellen); CDVA, corrected-distance visual acuity (Snellen); SEq, spherical equivalent (D); SRAst, subjective refractive astigmatism (D); SimK, keratometric astigmatism (D).

entire follow-up period. (Figures 3 and 4) At the last follow-up, no statistically significant differences in terms of subjective refractive astigmatism (DALK 2.97, PK 2.81,  $p=0.853$ ) and keratometric astigmatism (DALK 3.91, PK 2.37,  $p=0.853$ ) were observed. (Figures 5 and 6)



**Figure 2** Change in mean CDVA throughout the follow-up period. The asterisk indicates a statistically significant difference ( $p<0.05$ ) using the ANOVA test for repeated measures.

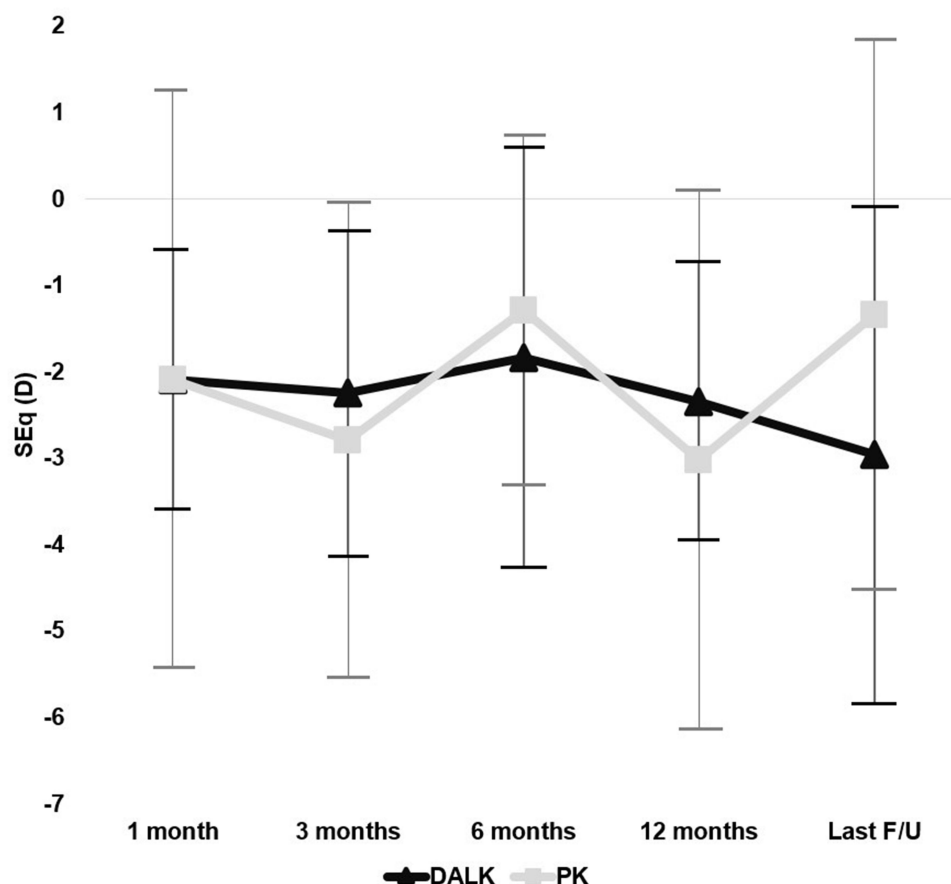




**Figure 3** Change in mean UDVA throughout the follow-up period. No statistically significant differences were noted between the two groups ( $p < 0.05$ ) using the ANOVA test for repeated measures.

## Discussion

In this study, the visual and refractive results of uneventful Descemet's DALK and PK in a large group of patients affected by advanced keratoconus were compared. To avoid any possible causes of bias the patients who showed signs of graft failure or rejection during the follow-up were not included in the present study. Both techniques of keratoplasty obtained a significant improvement in visual and refractive data without a statistical difference between the two groups at the final follow-up. These results were obtained in a single-center study where the same surgeon used always the same corneal diameters (8.00mm recipient; 8.25mm donor cornea) and the same suture technique (10-0 nylon double-running 12-bites continuous suture) in both groups. Our finding was consistent with the results of several other studies on the results of PK or DALK in advanced keratoconus.<sup>4,17-25</sup> There is substantial literature evidence that both DALK and PK lead to equivalent CDVA and refractive outcomes in patients with keratoconus 12 months postoperatively. In contrast, Shi et al reported that PK resulted in a more significant improvement in CDVA, with no discernible differences in refractive outcomes, but a higher incidence of rejection when compared to DALK.<sup>26</sup> Data from the Australian Corneal Transplant Registry, as published by Coster et al, revealed that a higher proportion of PK patients achieved a CDVA exceeding 6/12, while DALK showed poorer long-term survival outcomes.<sup>27</sup> These authors also found that DALK led to superior postoperative refractive astigmatism but detected no disparities in spherical equivalent or keratometric astigmatism between the two procedures. Factors that could potentially influence postoperative keratometric and refractive astigmatism include the size difference between the donor graft and the host bed, as well as the extent of preoperative ametropia.<sup>28,29</sup> Nevertheless, some argue that even substantial variations in trephine size may not be adequate to counteract postoperative myopia in keratoconus patients, suggesting that axial length might be a more influential factor in such cases.<sup>29-31</sup>

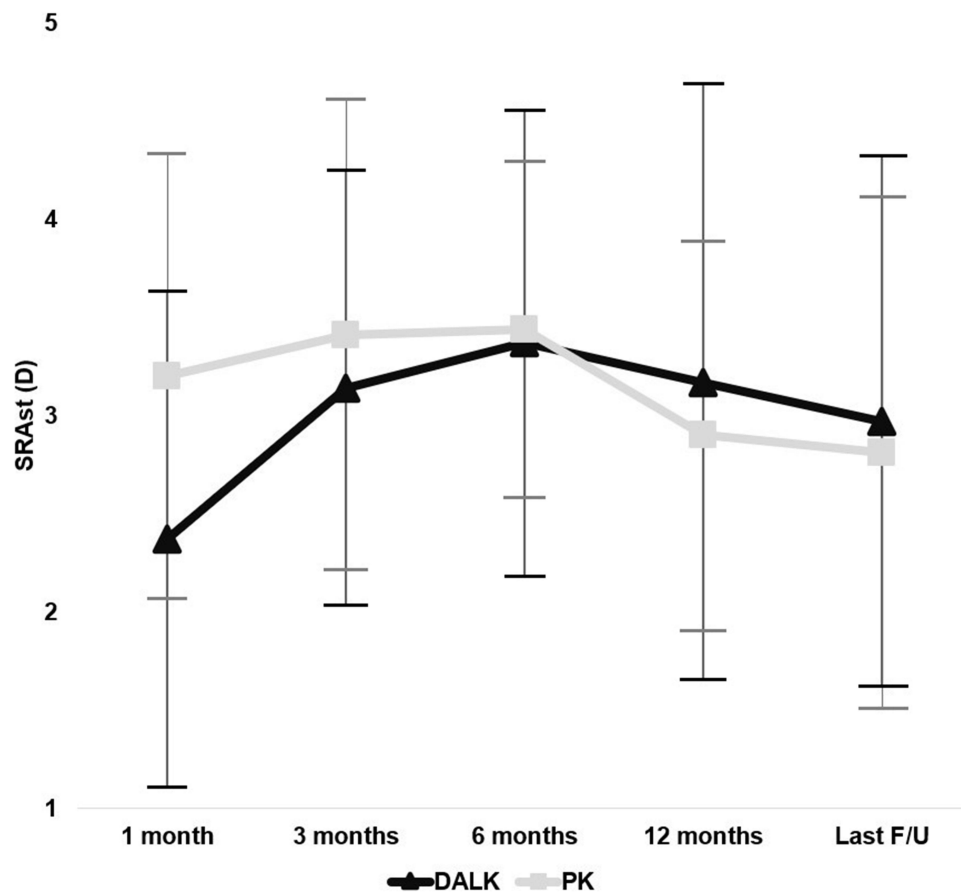


**Figure 4** Change in mean spherical equivalent throughout the follow-up period. No statistically significant differences were noted between the two groups ( $p < 0.05$ ) using the ANOVA test for repeated measures.

Non Descemet-baring techniques have been associated with the potential development of graft-host interface haze and inferior visual outcomes due to light scattering caused by the surgical interface. Ardjomand et al conducted a study revealing that DALK procedures leaving more than 80 $\mu$ m of residual host stromal thickness resulted in worse CDVA compared to PK.<sup>32</sup> However, two other studies reported that DM-baring DALKs achieved CDVA scores of 0 LogMAR or better in patients.<sup>33,34</sup> Furthermore, a randomized controlled trial (RCT) provided evidence that Anwar's "big bubble technique" (which preserves Descemet's membrane) and Melles' DALK (involving manual dissection for achieving the thinnest possible posterior corneal bed) produced similar visual acuity, refractive outcomes, and endothelial cell densities.<sup>35</sup> It has also been observed that keratoconus eyes with central curvatures exceeding 60D are more prone to developing Descemet membrane folds in the visual axis due to the discrepancy between the redundant recipient Descemet membrane and the posterior surface of the donor graft.<sup>36</sup> These visible folds at the center of the donor-recipient interface typically resolve over time and following suture removal. Even in cases where there are no clinically visible folds, microfolds in the surgical interface have been detected by confocal scanning two years after DALK.<sup>37</sup> For the present study, only cases of Descemetic DALK were included, following the formation of either a type 1 or type 2 bubble, which cleaves a plane between the pre-Descemet's layer and the overlying stroma.

In some studies, PK was found to yield superior visual outcomes compared to DALK, even when Descemet's membrane was successfully exposed. One plausible explanation for the better visual outcomes in PK could be attributed to improved donor graft quality. However, it's worth noting that this difference persisted even after adjusting for donor graft quality, supporting the findings of a prior study that established no significant correlation between donor quality and visual outcomes following DALK.<sup>38</sup> During DALK procedures, one of the primary intraoperative complications is the perforation of Descemet's membrane, with reported incidence rates ranging up to 50%. This occurrence varies depending





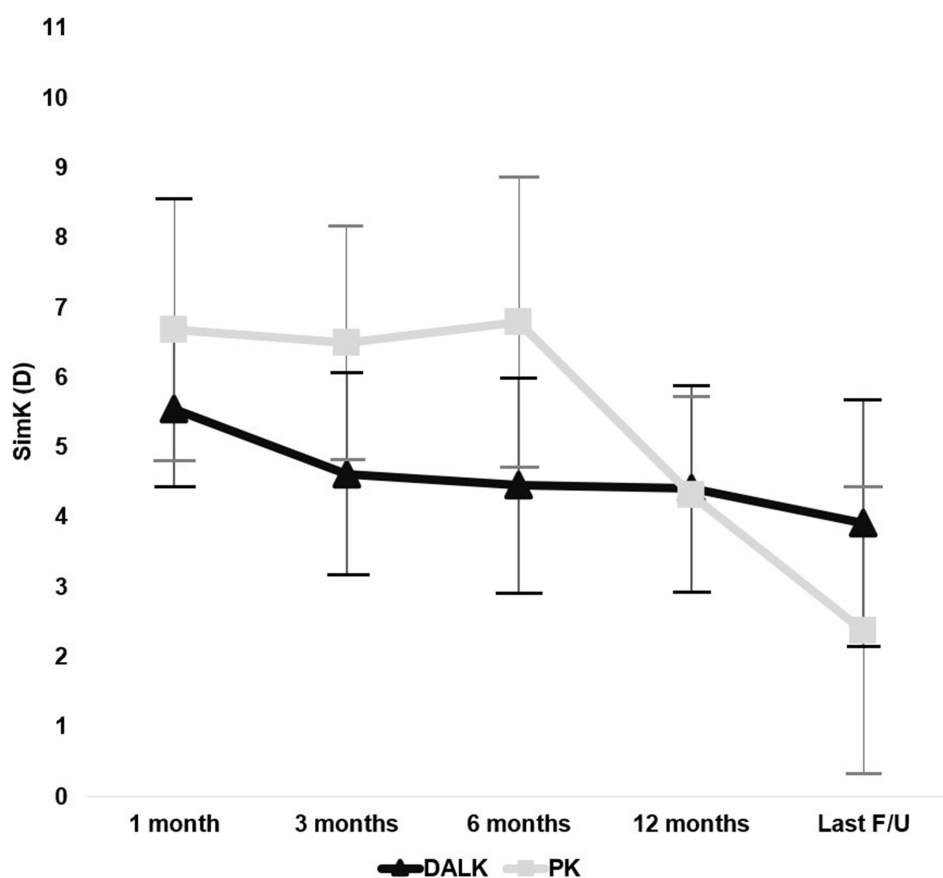
**Figure 5** Change in mean subjective refractive astigmatism throughout the follow-up period. No statistically significant differences were noted between the two groups ( $p < 0.05$ ) using the ANOVA test for repeated measures.

on factors such as the surgical technique employed, the surgeon's experience, and the severity of keratoconus.<sup>39</sup> Notably, extensive tears in Descemet's membrane that require conversion to PK are observed in 10% to 20% of DALK procedures for keratoconus, particularly in cases utilizing the big-bubble technique. This is often a consequence of the inherent weakness and fragility of Descemet's membrane in advanced keratoconus cases.

In addition to the identified risk factors of corneal scarring, manual dissection, occurrence of a type 2 bubble during pneumatic dissection, several other potential risk factors for intraoperative conversion from DALK to PK exist. These include preoperative corneal thickness, with thinner corneas posing challenges and increasing the risk of conversion. The severity of corneal ectasia, such as advanced keratoconus stages, may heighten the risk due to greater corneal thinning and structural weakness. The presence of corneal vascularization can complicate surgery and compromise wound healing, predisposing to conversion. Variations in surgical techniques, concurrent ocular pathology like glaucoma or cataracts, and patient-specific factors such as age and ocular surface health also contribute to the multifactorial nature of intraoperative complications.<sup>40</sup>

In the present study, statistically significant differences emerged for preoperative pachymetry value in the two groups: PK patients had a lower corneal thickness. This may indicate a greater severity of keratoconus and therefore justify a higher incidence of macro-perforations during surgery with the need to perform a penetrating keratoplasty.

Visual recovery is often believed to be more rapid following DALK when compared to PK, primarily due to quicker healing and earlier suture removal.<sup>41</sup> In our study, both groups had the same duration between keratoplasty and suture removal. However, it's worth noting that suture removal, even years after keratoplasty, has been shown to induce significant and unpredictable changes in keratometry.<sup>42</sup> As part of our standard practice, we typically remove all sutures 18 months after the surgery to minimize the risk of suture loosening, which is associated with a higher incidence of graft



**Figure 6** Change in mean keratometric astigmatism (calculated across the central 3mm) throughout the follow-up period in each group. No statistically significant differences were noted between the two groups ( $p < 0.05$ ) using the ANOVA test for repeated measures.

rejections. This precaution is particularly important because the recipient cornea often has a fragile Bowman layer and a thin stroma that may not withstand suture tension effectively.<sup>43</sup>

While this study sheds light on important aspects of the procedures under investigation, it is essential to acknowledge its limitations. Firstly, the retrospective nature of the study introduces limitations associated with such designs, potentially impacting the reliability and generalizability of the findings. Moreover, the exclusion of patients displaying signs of graft rejection or failure may inadvertently skew the results. Additionally, the exclusion of manually dissected DALK cases and the inclusion of patients who underwent intra-operative procedural changes from DALK to PK are elements to take into consideration.

## Conclusion

Both Descemet DALK and PK led to a significant improvement in the visual and refractive outcomes in eyes with advanced keratoconus. Descemet DALK resulted in better visual acuity before suture removal, while PK and DALK performed equally in terms of visual acuity, refractive and keratometric astigmatism after suture removal.

## Funding

This study did not receive financial support from any specific grant provided by public, commercial, or not-for-profit organizations.

## Disclosure

The authors report no conflicts of interest in this work.

## References

- Li X, Rabinowitz YS, Rasheed K, Yang H. Longitudinal study of the normal eyes in unilateral keratoconus patients. *Ophthalmology*. 2004;111(3):440–446. doi:10.1016/j.ophtha.2003.06.020
- Santodomingo-Rubido J, Carracedo G, Suzuki A, Villa-Collar C, Vincent SJ, Wolffsohn JS. Keratoconus: an updated review. *Cont Lens Anterior Eye*. 2022;45(3):101559. doi:10.1016/j.clae.2021.101559
- Williams KA, Roder D, Esterman A, Muehlberg SM, Coster DJ. Factors predictive of corneal graft survival: report from the Australian Corneal Graft Registry. *Ophthalmology*. 1992;99(3):403–414. doi:10.1016/S0161-6420(92)31960-8
- Javadi MA, Motlagh BF, Jafarinasab MR, et al. Outcomes of penetrating keratoplasty in keratoconus. *Cornea*. 2005;24(8):941–946. doi:10.1097/01.ico.0000159730.45177.cd
- Beckingsale P, Mavrikakis I, Al-Yousuf N, Mavrikakis E, Daya SM. Penetrating keratoplasty: outcomes from a corneal unit compared to national data. *Br J Ophthalmol*. 2006;90(6):728–731. doi:10.1136/bjo.2005.086272
- Thompson RW, Price MO, Bowers PJ, Price FW. Long-term graft survival after penetrating keratoplasty. *Ophthalmology*. 2003;110(7):1396–1402. doi:10.1016/S0161-6420(03)00463-9
- Kim MH, Chung TY, Chung ES. A retrospective contralateral study comparing deep anterior lamellar keratoplasty with penetrating keratoplasty. *Cornea*. 2013;32(4):385–389. doi:10.1097/ICO.0b013e318254be4e
- Anwar M, Teichmann KD. Deep lamellar keratoplasty: surgical techniques for anterior lamellar keratoplasty with and without baring of Descemet's membrane. *Cornea*. 2002;21(4):374–383. Comment in: *Cornea*. 2007;26(1):117. doi:10.1097/00003226-200205000-00009
- Melles GR, Remeijer L, Geerards AJ, Beekhuis WH. The future of lamellar keratoplasty. *Curr Opin Ophthalmol*. 1999;10(4):253–259. doi:10.1097/00055735-199908000-00006
- Reinhart WJ, Musch DC, Jacobs DS, Lee WB, Kaufman SC, Shtein RM. Deep anterior lamellar keratoplasty as an alternative to penetrating keratoplasty: a report by the American Academy of Ophthalmology. *Ophthalmology*. 2011;118(1):209–218. Comment in: *Ophthalmology*. 2011;118(11):2305–2306. *Ophthalmology*. 2011;118(11):2527/author reply 2527–2528. doi:10.1016/j.ophtha.2010.11.002
- Han DC, Mehta JS, Por YM, Htoon HM, Tan DT. Comparison of outcomes of lamellar keratoplasty and penetrating keratoplasty in keratoconus. *Am J Ophthalmol*. 2009;148(5):744–51.e1. Comment in: *Am J Ophthalmol*. 2009;148(5):629–631. doi:10.1016/j.ajo.2009.05.028
- Anwar M, Teichmann KD. Deep lamellar keratoplasty: surgical techniques for anterior lamellar keratoplasty with and without baring of Descemet's membrane. *Cornea*. 2002;21(4):374–383.
- Amayem AF, Hamdi IM, Hamdi MM. Refractive and visual outcomes of penetrating keratoplasty versus deep anterior lamellar keratoplasty with hydrodissection for treatment of keratoconus. *Cornea*. 2013;32(4):e2–5. doi:10.1097/ICO.0b013e31825ca70b
- Melles GR, Remeijer L, Geerards AJ, Beekhuis WH. A quick surgical technique for deep, anterior lamellar keratoplasty using visco-dissection. *Cornea*. 2000;19(4):427–432. doi:10.1097/00003226-200007000-00004
- Melles GR, Lander F, Rietveld FJ, et al. A new surgical technique for deep stromal, anterior lamellar keratoplasty. *Br J Ophthalmol*. 1999;83(3):327–333.
- Smadja D, Colin J, Krueger RR, et al. Outcomes of deep anterior lamellar keratoplasty for keratoconus: learning curve and advantages of the big bubble technique. *Cornea*. 2012;31(8):859–863. doi:10.1097/ICO.0b013e318242fd4e
- Krumeich JH, Daniel J, Knulle A. Live-epikeratophakia for keratoconus. *J Cataract Refract Surg*. 1998;24(4):456–463. doi:10.1016/S0886-3350(98)80284-8
- Naderan M, Shoar S, Kamaledin MA, Rajabi MT, Naderan M, Khodadadi M. Keratoconus clinical findings according to different classifications. *Cornea*. 2015;34(9):1005–1011. doi:10.1097/ICO.0000000000000537
- Panthagani J, Law EM, Chipeta C, Roberts H, Myerscough J. High Astigmatism After Conventional Diameter Deep Anterior Lamellar Keratoplasty in Keratoconus Can Be Successfully Managed With Repeat Wide Diameter Deep Anterior Lamellar Keratoplasty. *Cornea*. 2023;42(8):1057–1061. doi:10.1097/ICO.00000000000003298
- Feizi S, Javadi MA, Kheiri B. Effect of keratoconus severity on clinical outcomes after deep anterior lamellar keratoplasty. *Am J Ophthalmol*. 2019;202:15–22. doi:10.1016/j.ajo.2019.01.030
- Buzard KA, Fundingsland BR. Corneal transplant for keratoconus: results in early and late disease. *J Cataract Refract Surg*. 1997;23(3):398–406. doi:10.1016/S0886-3350(97)80184-8
- Liu Y, Seitz B, Langenbucher A, Nguyen NX, Naumann GO. Impact of preoperative corneal curvature on the outcome of penetrating keratoplasty in keratoconus. *Cornea*. 2003;22(5):409–412. doi:10.1097/00003226-200307000-00004
- Rocha G, Vieira BV, Mendes BMS, et al. Visual outcomes in advanced keratoconus using different strategies: scleral lens, intracorneal ring segment and lamellar keratoplasty. *Eur J Ophthalmol*. 2021;31(4):1563–1570. doi:10.1177/1120672121994731
- Li S, Wang T, Bian J, Wang F, Han S, Shi W. Precisely controlled side cut in femtosecond laser-assisted deep lamellar keratoplasty for advanced keratoconus. *Cornea*. 2016;35(10):1289–1294. doi:10.1097/ICO.0000000000000962
- Ozertürk Y, Sari ES, Kubaloglu A, Koytak A, Piñero D, Akyol S. Comparison of deep anterior lamellar keratoplasty and intrastromal corneal ring segment implantation in advanced keratoconus. *J Cataract Refract Surg*. 2012;38(2):324–332. doi:10.1016/j.jcrs.2011.08.033
- Liu H, Chen Y, Wang P, et al. Efficacy and safety of deep anterior lamellar keratoplasty vs. penetrating keratoplasty for keratoconus: a meta-analysis. *PLoS One*. 2015;10(1):e0113332. doi:10.1371/journal.pone.0113332
- Coster DJ, Lowe MT, Keane MC, Williams KA. Australian Corneal Graft Registry Contributors. A comparison of lamellar and penetrating keratoplasty outcomes: a registry study. *Ophthalmology*. 2014;121(5):979–987. doi:10.1016/j.ophtha.2013.12.017
- Perry HD, Foulks GN. Oversize donor buttons in corneal transplantation surgery for keratoconus. *Ophthalmic Surg*. 1987;18(10):751–752.
- Javadi MA, Feizi S, Rastegarpour A. Effect of vitreous length and trephine size disparity on post-DALK refractive status. *Cornea*. 2011;30(4):419–423. doi:10.1097/ICO.0b013e3181d4f8ff
- Shimmura S, Ando M, Ishioka M, Shimazaki J, Tsubota K. Same-size donor corneas for myopic keratoconus. *Cornea*. 2004;23(4):345–349. doi:10.1097/00003226-200405000-00006
- Keane M, Coster D, Ziaei M, Williams K. Deep anterior lamellar keratoplasty versus penetrating keratoplasty for treating keratoconus. *Cochrane Database Syst Rev*. 2014;22(7):CD009700.

32. Ardjomand N, Hau S, McAlister JC, et al. Quality of vision and graft thickness in deep anterior lamellar and penetrating corneal allografts. *Am J Ophthalmol*. 2007;143(2):228–235(e1). doi:10.1016/j.ajo.2006.10.043
33. Fontana L, Parente G, Tassinari G. Clinical outcomes after deep anterior lamellar keratoplasty using the big-bubble technique in patients with keratoconus. *Am J Ophthalmol*. 2007;143(1):117–124. doi:10.1016/j.ajo.2006.09.025
34. Han DC, Mehta JS, Por YM, Htoon HM, Tan DT. Comparison of outcomes of lamellar keratoplasty and penetrating keratoplasty in keratoconus. *Am J Ophthalmol*. 2009;148(5):744–751.e1.
35. Baradaran-Rafii A, Eslani M, Sadoughi MM, Esfandiari H, Karimian F. Anwar versus Melles deep anterior lamellar keratoplasty for keratoconus: a prospective randomized clinical trial. *Ophthalmology*. 2013;120(2):252–259. doi:10.1016/j.ophtha.2012.07.090
36. Li X, Zhao Y, Chen H, Li Y, Hong J, Xu J. Clinical properties and risk factors for Descemet membrane folds after deep anterior lamellar keratoplasty in patients with keratoconus. *Cornea*. 2019;38(10):1222–1227. doi:10.1097/ICO.0000000000002075
37. Feizi S, Javadi MA, Mohammad-Rabei H. An analysis of factors influencing quality of vision after big-bubble deep anterior lamellar keratoplasty in keratoconus. *Am J Ophthalmol*. 2016;162:66–73. doi:10.1016/j.ajo.2015.11.018
38. Feizi S, Javadi MA, Kanavi MR, Javadi F. Effect of donor graft quality on clinical outcomes after deep anterior lamellar keratoplasty. *Cornea*. 2014;33(8):795–800. doi:10.1097/ICO.0000000000000177
39. Parker JS, van Dijk K, Melles GR. Treatment options for advanced keratoconus: a review. *Surv Ophthalmol*. 2015;60(5):459–480. doi:10.1016/j.survophthal.2015.02.004
40. Myerscough J, Friehmann A, Bovone C, Mimouni M, Busin M. Evaluation of the risk factors associated with conversion of intended deep anterior lamellar keratoplasty to penetrating keratoplasty. *Br J Ophthalmol*. 2020;104(6):764–767. doi:10.1136/bjophthalmol-2019-314352
41. Bahar I, Kaiserman I, Srinivasan S, Ya-Ping J, Slomovic AR, Rootman DS. Comparison of three different techniques of corneal transplantation for keratoconus. *Am J Ophthalmol*. 2008;146(6):905–912. doi:10.1016/j.ajo.2008.06.034
42. Feizi S, Javadi MA, Behnaz N, Fani-Hanife S, Jafarinasab MR. Effect of suture removal on refraction and graft curvature after deep anterior lamellar keratoplasty in patients with keratoconus. *Cornea*. 2018;37(1):39–44. doi:10.1097/ICO.0000000000001443
43. Christo CG, van Rooij J, Geerards AJ, Remeijer L, Beekhuis WH. Suture-related complications following keratoplasty: a 5-year retrospective study. *Cornea*. 2001;20(8):816–819. doi:10.1097/00003226-200111000-00008

## Therapeutics and Clinical Risk Management

Dovepress

### Publish your work in this journal

Therapeutics and Clinical Risk Management is an international, peer-reviewed journal of clinical therapeutics and risk management, focusing on concise rapid reporting of clinical studies in all therapeutic areas, outcomes, safety, and programs for the effective, safe, and sustained use of medicines. This journal is indexed on PubMed Central, CAS, EMBASE, Scopus and the Elsevier Bibliographic databases. The manuscript management system is completely online and includes a very quick and fair peer-review system, which is all easy to use. Visit <http://www.dovepress.com/testimonials.php> to read real quotes from published authors.

Submit your manuscript here: <https://www.dovepress.com/therapeutics-and-clinical-risk-management-journal>