

Post-Traumatic Intracranial Pseudoaneurysm Presenting as Epistaxis

Ali M Hassan¹, Chad W Donley², Praveen Venkatachalam³

¹Department of Emergency Medicine, St. Elizabeth Hospital, Boardman, OH, USA; ²Department of Emergency Medicine, St. Elizabeth Hospital, Youngstown, OH, USA; ³Department of Interventional Neuro-Radiology, St. Elizabeth Hospital, Youngstown, OH, USA

Correspondence: Ali M Hassan, Email alihassan.kh@hotmail.com

Background: Epistaxis is a frequent presenting complaint in the Emergency Department (ED). Roughly 60% of the population will suffer from epistaxis in their lifetime. The most common causes of epistaxis include nose picking, facial trauma, foreign bodies, and coagulopathies. There are other causes that are much less common, such as intracranial pseudoaneurysms. There are multiple causes that precipitate intracranial pseudoaneurysm formation, with head trauma accounting for less than 1% of inciting events.

Case Report: A 24-year-old female with history of traumatic brain injury with associated skull fractures due to a gunshot wound to the head 6 months prior presented to the ED in hemorrhagic shock secondary to epistaxis. After stabilization with the administration of blood products, Computed Tomography with Angiography (CTA) imaging of the head and neck was obtained and revealed a $3.1 \times 2.2 \times 2.5$ cm pseudoaneurysm of the cavernous portion of the right internal carotid artery penetrating through the base of the skull into the ethmoidal sinus. The patient was taken for formal angiography by interventional radiology and a partially thrombosed daughter sac of the initial aneurysm was identified and believed to be the source of the hemorrhage. The aneurysm was successfully coiled and occluded using ONYX embolization. Postoperatively, the patient returned to her baseline mental status without any acute complaints. The patient was discharged back to her nursing home 2 days later with a 3-week follow-up CTA revealing persistent occlusion of the aneurysm and a patent internal carotid artery.

Conclusion: Awareness and consideration of intracranial vascular etiology for common complaints in the emergency room, such as Epistaxis, especially in patients with any history of head injury/trauma, known intracranial aneurysms or prosthetic devices from prior surgery may help guide decision-making in managing critically ill patients.

Keywords: epistaxis, hemorrhagic shock, ONYX embolization, pseudoaneurysm

Background

Nose bleeds, medically termed “Epistaxis”, occur in most individuals throughout their lifetime. Most Epistaxis cases originate anteriorly from the superior labial artery, greater palatine artery, anterior ethmoid artery, and posterior ethmoid artery. These are treated in the ED with an estimated 90% success rate, with only about 10% requiring ENT follow-up and intervention. Posterior bleeds originate from the sphenopalatine artery and its branches, and typically require more intensive care and ENT intervention. The more common causes of Epistaxis include blunt facial trauma, nose picking, and hot environmental climates, and social factors such as tobacco use. Less common causes include coagulopathies, intracranial neoplasms, hepatic disease, or vascular compromise such as intracranial pseudo-aneurysms.

Aneurysms can be categorized as true aneurysms, pseudoaneurysms or mixed type. True aneurysms refer to vasculature dilatation involving the tunica adventitia, intima and media without wall disruption. Pseudoaneurysms, statistically the less common type of aneurysm, occur due to a disruption in all 3 layers of the vessel wall with blood contained outside of the vessel forming a false lumen (Figure 1).¹ Mixed-type aneurysms occur when the walls of a true aneurysm are disrupted and a pseudoaneurysm subsequently emerges due to disruption of vessel wall layers.

Common causes of intracranial aneurysm formation include hereditary syndromes such as Ehlers–Danlos syndrome, family history of aneurysms without a hereditary syndrome, autosomal dominant polycystic kidney disease, or social

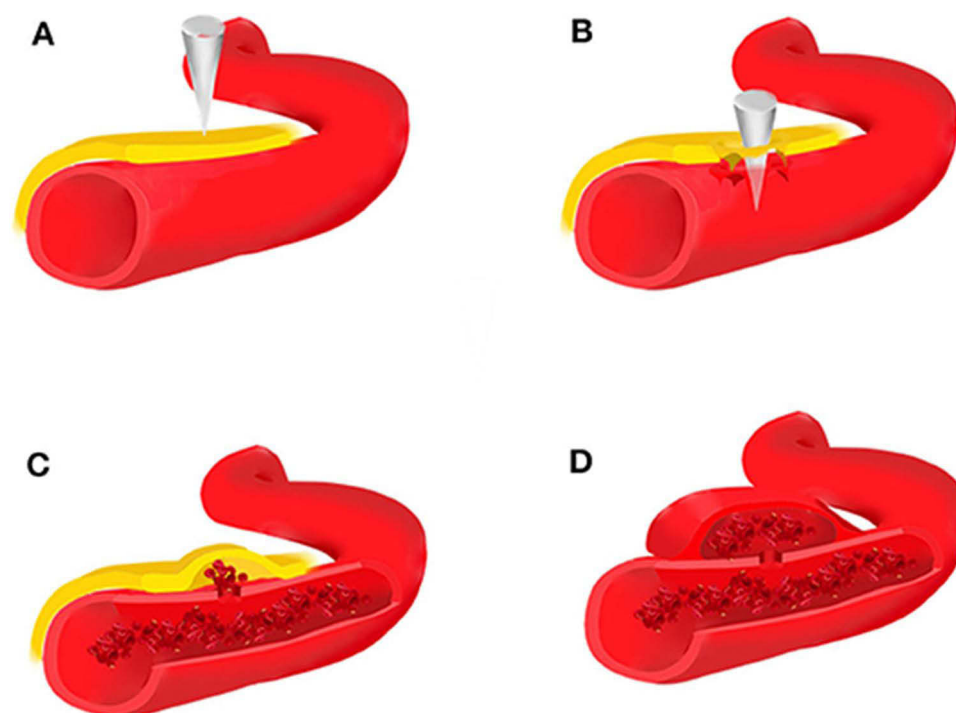


Figure 1 Brain trauma leads to rupture of the intima, media, and adventitia of the blood vessel (**A** and **B**), forming an organized hematoma cavity (**C**). When the hematoma forms outside the arterial wall, it continues to communicate with the injured vessel, thus predisposing it to re-bleeding (**D**).

Notes: Reprinted from Zheng Y, Lu Z, Shen J and Xu F (2020) Intracranial Pseudoaneurysms: Evaluation and Management. *Front. Neurol.* 11:582. Creative Commons.¹

factors such as tobacco use.² Head trauma accounts for less than 1% of causes inciting intracranial aneurysm formation.³ True aneurysms can form following direct blunt or penetrating injury to the head, due to road traffic accidents or sport-related injuries, amongst other causes. About 20% of these aneurysms involve the internal carotid artery, where there is an estimated 8% prevalence of vertebral artery involvement.⁴ About 30% of all traumatic intracranial aneurysms occur in patients younger than 18 years old, with a ratio of male-to-female incidence is 1:1, however in adults, male patients predominate with a ratio of about 4:1.⁵

Traumatic pseudoaneurysms, however, are much less common than true aneurysms. Penetrating, blunt, or blast injuries to the head and neck are often associated with injuries to the carotid and vertebral arteries.⁶ Pseudoaneurysm formation involving the common carotid artery after gunshot injury to the vessel is relatively rare and is identified in imaging as a hematoma contained by a fibrous layer, which – when ruptured – can cause severe epistaxis through sphenoid wall penetration or disruption, which is typically the disease process' hallmark.⁷ Its classic triad has been well defined as recent head trauma with skull fractures, profound epistaxis, and acute unilateral eye symptoms, commonly cranial nerve 6 palsy.⁸ This is due to the close anatomical relation of the cavernous portion of the carotid artery with the Abducens Nerve within the cavernous sinus (Figure 2).⁹

We present the case of a female patient with a history of penetrating trauma to the head by a missile fired from a gun who arrived to the ED with Epistaxis in hemorrhagic shock due to a cavernous carotid artery pseudoaneurysm rupture.

Case Report

A 24-year-old female presented to the ED from a local nursing home with right-sided Epistaxis. The patient had a spontaneous episode of large volume hemorrhage prior to transport. When the Emergency Medical Transport (EMT) team arrived to transport her to the hospital, they described her sitting in a pool of blood with an estimated 2 liters of blood loss. Her vitals were reportedly stable at the time. By the time the patient arrived to the hospital, the Epistaxis had stopped without any intervention. The patient had 2 prior episodes of Epistaxis, within the preceding 30 days which were not as severe, and therefore medical evaluation was not sought at the time.

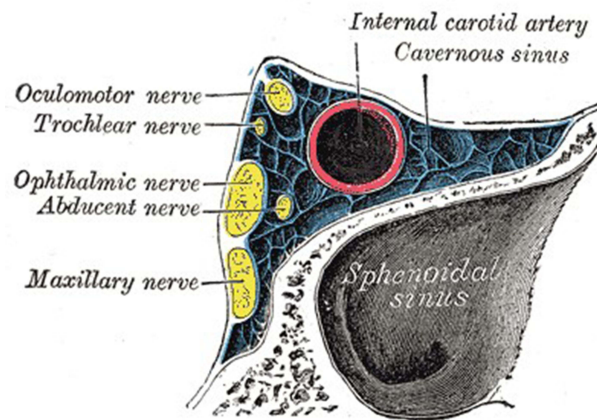


Figure 2 Coronal view of the cavernous sinus including its own contents and the adjacent sphenoidal sinus. This diagram has been reproduced from Gray's Anatomy 20th US edition which has now lapsed into the public domain.

Notes: Reprinted from Hacking C, Cavernous sinus (Gray's illustration). Case study, Radiopaedia.org. Available from <https://radiopaedia.org/cases/cavernous-sinus-grays-illustration>. Creative Commons.⁹

Her past medical and surgical history was significant for traumatic brain injury due to a gunshot wound to the head six months prior, with complete right-sided paralysis associated with left cerebral hemisphere injury. She was noted to have left-sided extracranial cerebral herniation in the area of impact (**Figure 3**), and a subarachnoid hemorrhage (**Figure 4**) in addition to a subdural hematoma on initial CT imaging. Given the severe impact, she also developed multiple skull base fractures on the right side including the sphenoid wall laterally (**Figure 5**: axial view) (**Figure 6**: sagittal view) and anteriorly (**Figure 7**), the medial wall of the maxillary sinus and the medial sphenoid septum (**Figure 8**). She subsequently underwent emergent decompression with left-sided craniectomy and subdural hematoma evacuation. Bullet fragments were left in their place in the left skull base and left frontal lobe and not extracted to the complexity of the injury. Prior to the gunshot wound, the patient had no medical-related history. A Ventriculo-peritoneal

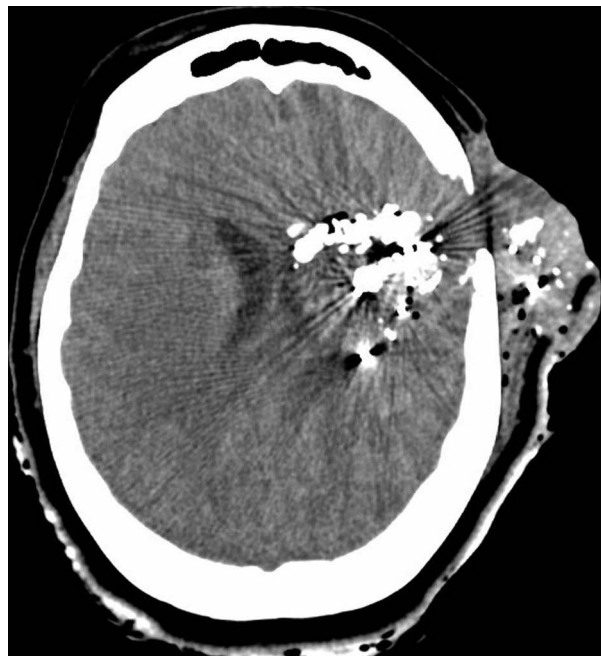

Figure 3 Axial view of the CT showing left-sided extracranial cerebral herniation and retained bullet fragments.

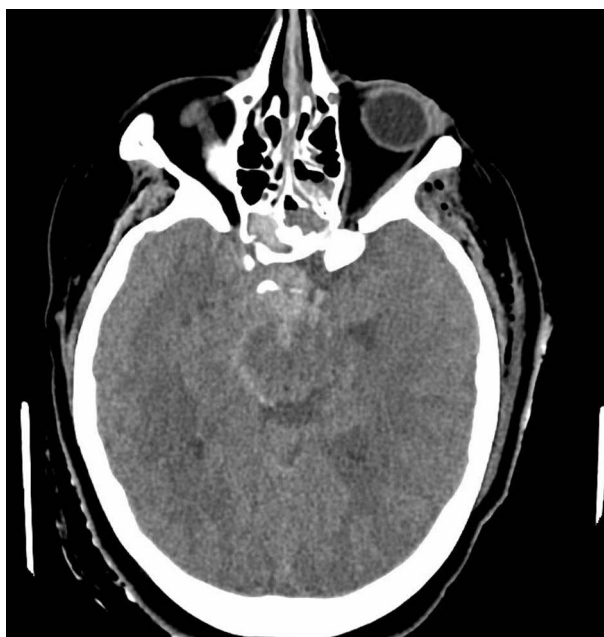

Figure 4 Axial view of the CT showing subarachnoid hemorrhage.

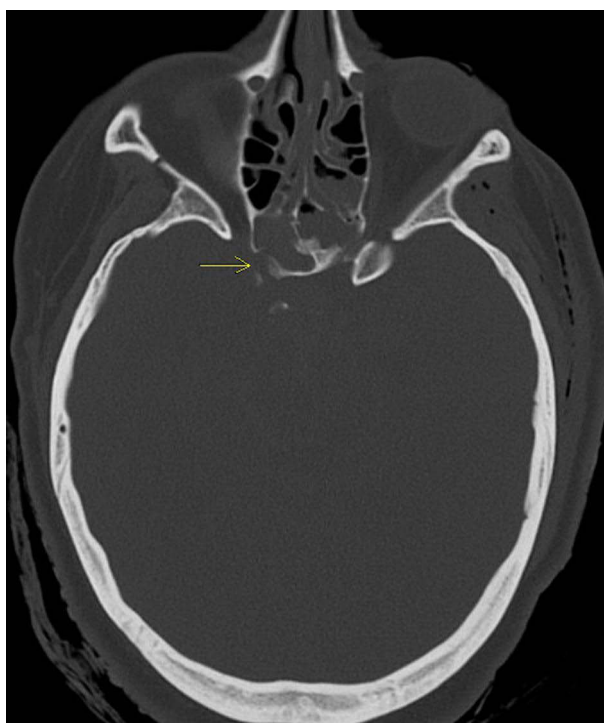


Figure 5 Axial view of the head CT. (Yellow arrow: right-sided lateral sphenoid wall fracture due to force of penetrating trauma).
Note: original CT imaging of the patient.

(VP) shunt placement a week later due to right-to-left cerebral herniation with a 13mm midline shift secondary to elevated intracranial pressures with dilated ventricles and no new hemorrhage (Figure 9).

On arrival to the ED, the patient was found to be in shock with a heart rate of 135 and a blood pressure of 74/48. Her temperature was 37 °C, she was tachypneic on her ventilator with a respiratory rate of 48 breaths per minute, saturating 100% on pulse oximetry, was pale and ill-appearing. She was unable to provide history due to tracheostomy-dependent

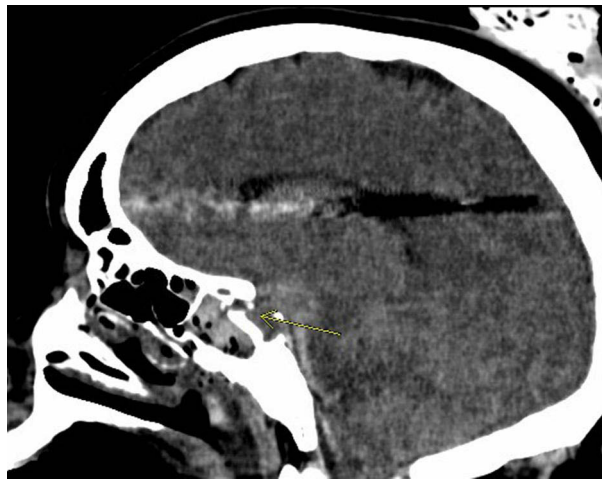


Figure 6 Sagittal view of the head CT. (Yellow arrow: right sided lateral sphenoid wall fracture due to force of penetrating trauma).
Note: original CT imaging of the patient.

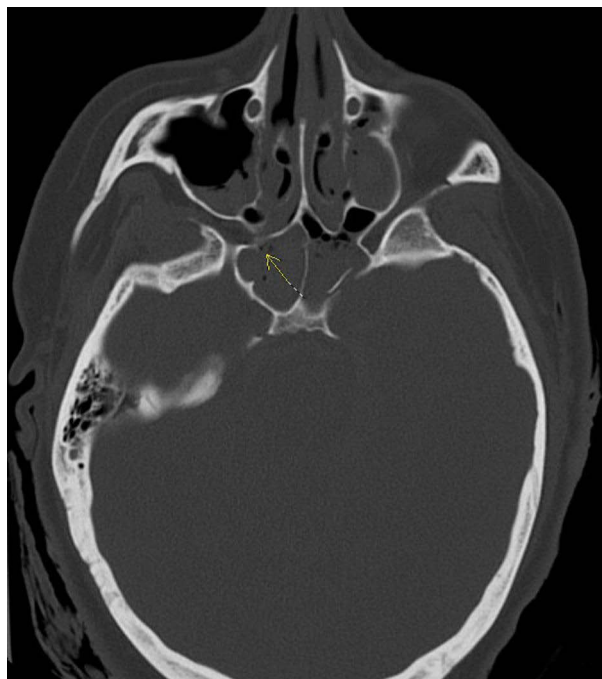


Figure 7 Axial view of the head CT. (Yellow arrow: right sided anterior sphenoid wall fracture due to force of penetrating trauma).
Note: original CT imaging of the patient.

status. The patient's clothes and bed sheets from transport were soaked in blood. She had physical evidence of a prior left-sided craniectomy on exam and had obvious neurologic deficits including paralysis of the right body, and left-sided eye misalignment. Upon inspection of both nares, no active hemorrhage was noted, and no potential source of bleed was found either. When evaluating the patient's oropharynx using a tongue depressor, the patient gagged and expelled about 300 mL of blood from her oral cavity. Her blood pressure was remeasured and was found to be 51/28, and the patient's heart rate had increased to 145 beats per minute.

A Cordis sheath introducer was inserted in the right femoral vein, and 2 units of uncrossed matched blood were administered. With the administration of blood products, the patient's hemodynamics began to stabilize, and the patient ceased to expel anymore blood. Within 10 minutes of stabilization, a computed tomography (CT) image of the head was

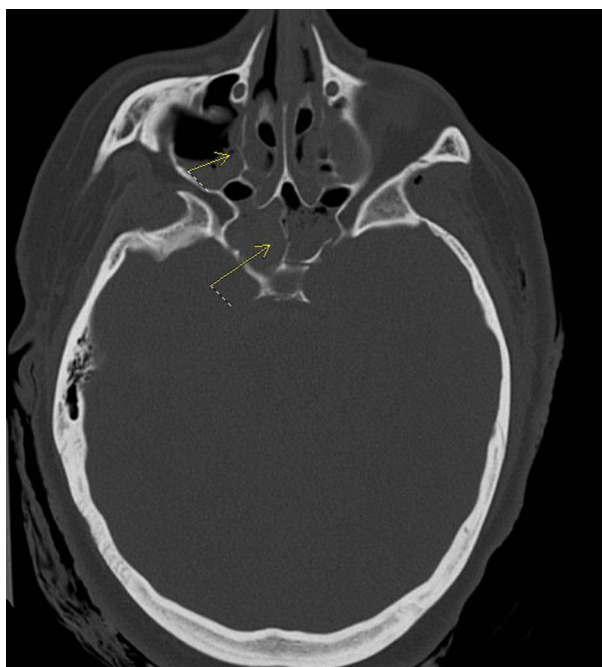


Figure 8 Axial view of the head CT. (Upper arrow: maxillary sinus medial wall fracture due to force of penetrating trauma) (Lower arrow: medial sphenoid septum fracture due to force of penetrating trauma).

Note: original CT imaging of the patient.

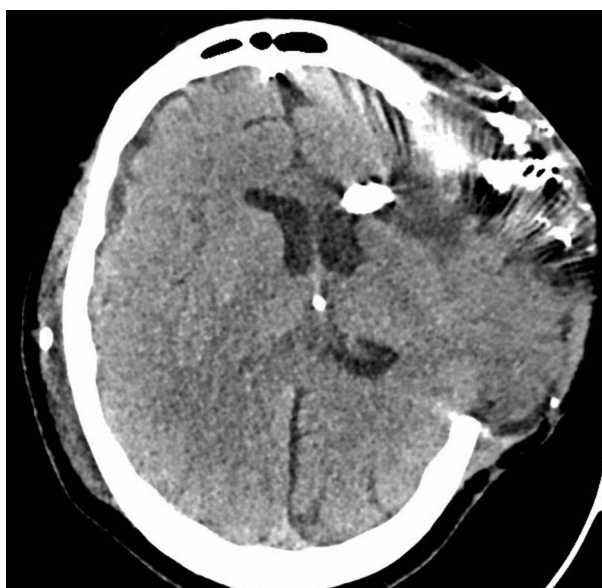

Figure 9 Axial view of the head CT showing VP shunt placement, right to left cerebral midline shift, and external brain herniation.

completed, which revealed a progressive, expansile heterogeneous density mass in the posterior right ethmoidal sinus measuring 4.4 cm in diameter (Figures 10 and 11). Due to lack of specialist coverage at the hospital providing initial care, Otolaryngology (ENT) and Emergency Medicine physicians were consulted at a nearby hospital, which the patient was transferred to for further management.

Initial lab work revealed a hemoglobin of 9.4 (g/dL) prior to administration of blood products (previously 10.4), Leukocyte count of 17.7 (k/uL), and a platelet count of 529 (k/uL). Her Prothrombin time was 15.3 (seconds), and international normalized ratio (INR) was 1.4.

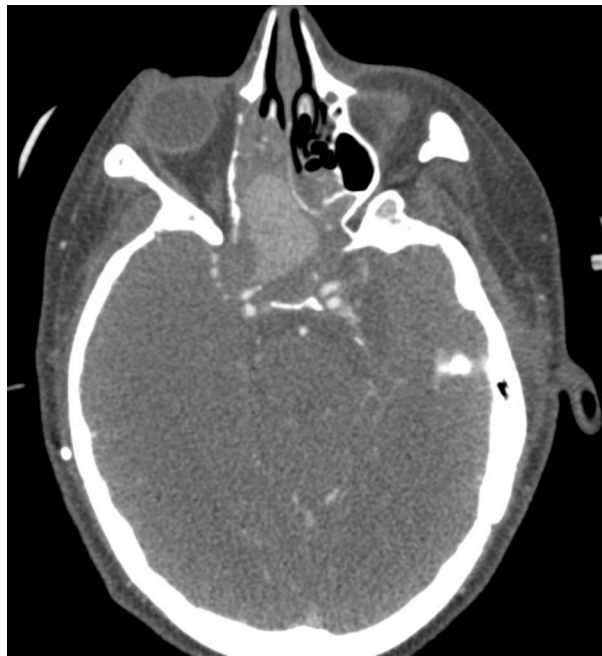

Figure 10 Axial view of the head CT with contrast showing a pseudoaneurysm of the cavernous portion of the right internal carotid artery protruding into the ethmoidal sinus.

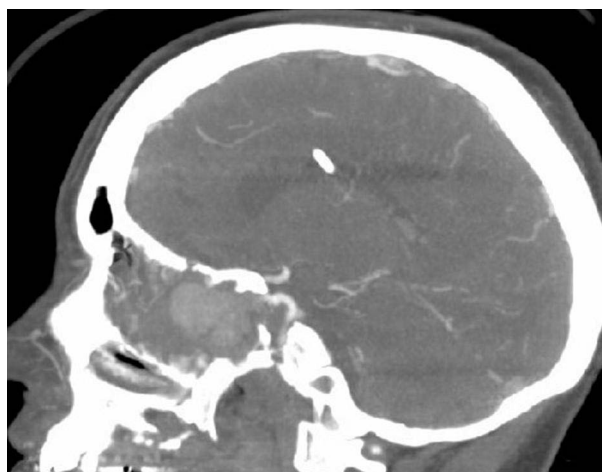

Figure 11 Sagittal view of the head CT with contrast showing a pseudoaneurysm of the cavernous portion of the right internal carotid artery protruding into the ethmoidal sinus.

The patient arrived to the receiving ED tachycardic with a heart rate of 122, but otherwise stable with a blood pressure of 106/69, respiratory rate of 20, saturating 100% on her standard ventilator settings. She remained afebrile. Otolaryngology was consulted immediately and performed nasal endoscopy at the bedside, which revealed a worrisome pulsating mass projecting into the nasal cavity posteriorly without active hemorrhage. Absorbable Sinufoam was placed in the right nares to prevent adhesion formation. A CTA of the head was obtained which illustrated the pseudoaneurysm of the cavernous portion of the internal carotid artery without evidence of contrast extravasation.

The new set of blood work at the receiving hospital revealed a hemoglobin of 11.7, increased from the initial 9.4 after blood product administration. Neurosurgery and endovascular neurology were emergently consulted and upon reviewing historical images when the trauma took place, the pseudoaneurysm was seen penetrating from the previously fractured right lateral sphenoid wall and area of other bony fractures. It was evident that the mobilization of the internal carotid

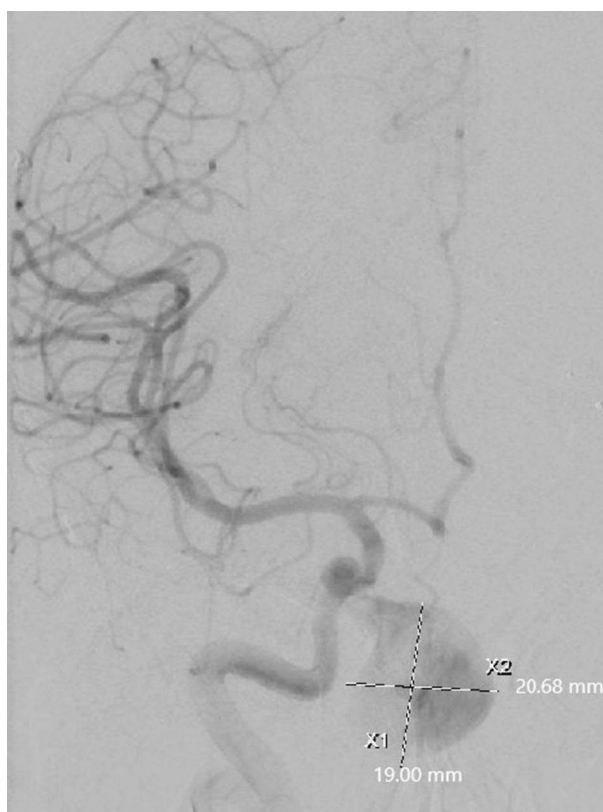


Figure 12 Cerebral angiogram showing large pseudoaneurysm of the cavernous portion of the internal carotid artery.

artery due to skull fractures near the cavernous sinus after penetrating trauma led to the pseudoaneurysm growth. Due to the severity of her illness, the decision was made to proceed with formal angiography and possible endovascular intervention.

The patient was taken to the operating room on the same day. Cerebral angiogram revealed the large pseudoaneurysm and confirmed its origin from the cavernous portion of the carotid artery (Figure 12). Given that the left cerebrum had severe dysfunction along with vascular compromise from the initial trauma, balloon occlusion testing of the right carotid artery was not performed as salvage therapy of the functional cerebral hemisphere was the main priority. The patient's aneurysmal sac was accessed using an SL10 microcatheter along with 014 Synchro soft wire. ONYX embolization was performed, followed by endovascular coiling with Raymond-Roy Occlusion Classification (RROC) grade I in case the Onyx was unsuccessful (Figure 13). During the procedure, there was a daughter sac measuring 6.5 mm that was found and felt to be the point of rupture causing hemorrhage. The patient returned to baseline after reversal of anesthesia, and no operative complications were noted. The patient had neurologic examinations performed every 1 hour which did not reveal any new positive findings and was discharged the next day back to nursing home. At her 1 month follow-up, repeat CT angiography revealed patency of the internal carotid artery and persistent occlusion of the pseudoaneurysm (Figure 14).

Discussion

Epistaxis is a common chief complaint in the ED and is usually treated successfully with nasal clips, vasoconstrictive medications such as Oxymetazoline, cauterization, and nasal packing if needed. Only about 10% of these patients will require ENT follow-up for large volume bleeds, persistence, or recurrence. When suspecting a posterior source of bleed, blood work is typically obtained which constitutes a complete blood count level, a metabolic panel, and a coagulation profile. Anti-staphylococcal antibiotics are usually started empirically due to the high risk of CNS infection. When managing active hemorrhage, hemostasis can be achieved by placing a posterior nasal packing, such as by inserting

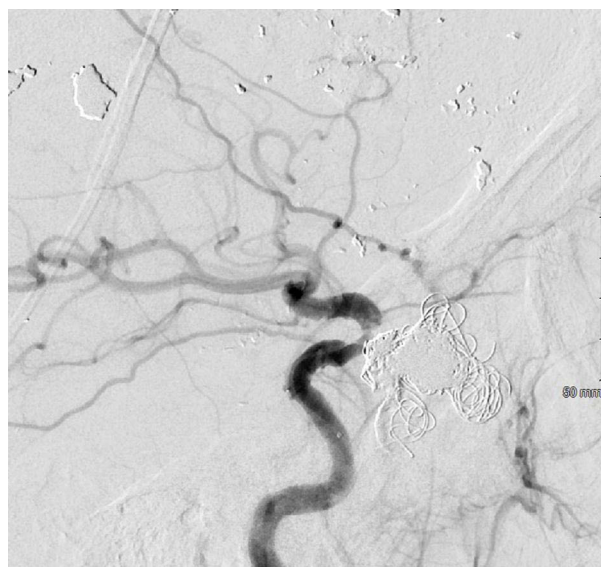


Figure 13 Cerebral angiogram showing ONYX embolization and endovascular coiling of pseudoaneurysm.

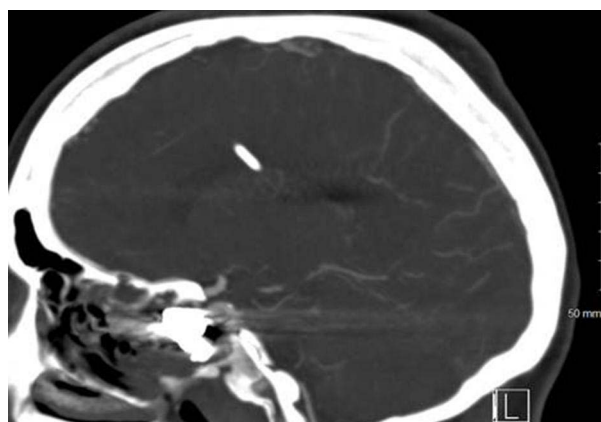


Figure 14 Sagittal view of the head CT showing persistent occlusion of the pseudoaneurysm and internal carotid artery patency.

a Foley catheter and blowing up the balloon and applying traction. However, consideration of context is imperative to the successful management of such patients.

Less than 1% of all causes of cerebral aneurysm formations are due to trauma to the head that leads to pseudoaneurysm formation, and literature surrounding this topic is limited. Therefore, consideration of less common causes of Epistaxis and a high index of suspicion is required when patients present critically ill due to the wide range of possible etiologies, including septal perforation, hereditary hemorrhagic telangiectasia, arteriovenous malformation, nasopharyngeal neoplasms, hepatic failure, or coagulopathies. This presents a complex challenge to physicians when formulating care plans for other common chief complaints in the ED, as multiple factors need to be considered in managing these emergencies. This is especially true with non-verbal patients or if no prior electronic medical records are available for review. In this case, posterior nasal packings were not placed prior to obtaining images of the head due to concerns for potential vascular compromise owing to the history of head trauma and intracranial surgeries. After the patient was transferred to the receiving facility, otolaryngology agreed with the avoidance of posterior nasal packings due to the high risk of further arterial rupture, which would have had a potentially fatal outcome.

Based upon available data, the average time from trauma inciting aneurysmal formation and rupture is around 21 days.³ The case presented is unique in that rupture was delayed about 6 months, significantly longer than the reported

average period. High mortality rates have been reported with rupture of these aneurysms, some reports citing up to a 50% mortality rate.¹⁰ The reason for this delayed presentation is unknown, however the patient did have multiple milder episodes of epistaxis in the preceding weeks, which could have been used as an indicator to an ongoing dangerous vascular process.

A single-center retrospective cohort study published in 2021 that illustrated the different therapeutic methods of traumatic intracranial aneurysms revealed that 85% of the 20 subjects included had localized lesions on the internal carotid artery.¹⁰ A report of 7 different internal carotid artery pseudoaneurysm cases published in 1997 highlighted that massive Epistaxis with associated hemorrhagic shock had a prevalence rate of 71% when involving the ICA or one of its branches, such as the ophthalmic artery.³ Other common manifestations of these anatomic-specific lesions include unilateral blindness, and skull base fractures.¹¹ Our subject presented with the classic triad of recent head trauma, unilateral deficits, and massive epistaxis. Another study published in 2010 that was conducted to investigate clinical efficacy of different treatment methods for traumatic pseudoaneurysms revealed a 100% prevalence rate of massive Epistaxis in lesions arising from the internal carotid arteries.¹²

A retrospective study published in 2008 which reviewed the results of different endovascular treatments revealed that one patient of the 13 that received intervention with bare stent placement and coiling had a growing pseudoaneurysm, therefore internal carotid artery occlusion with extracranial-intracranial bypass was needed.¹³ The remainder of the subjects had no complications. The biggest disadvantage of endovascular intervention, particularly if stents are placed, is placing the patient on an anticoagulant or antiplatelet therapy regimen to reduce the risk of thrombosis, which adversely places patients at an increased risk of bleed recurrence.

In this patient, onyx embolization, in addition to coiling, was the operative treatment of choice by interventional neuroradiology. This is largely due to the higher success rate and better outcomes when compared to other treatment modalities, including clipping, wrapping, or trapping with or without external carotid-internal carotid bypass, which were previously used in management of traumatic intracranial pseudoaneurysms prior to the development of endovascular techniques.^{11,14,15}

Conclusion

Although rarely seen, intracranial pseudoaneurysm formation due to trauma can occur and usually present as hemorrhages involving the subarachnoid space. This, however, does not rule out the possibility of these hemorrhages presenting in a variety of ways. It is important to take clinical context into consideration when managing critically ill patients with common chief complaints, as usual management modalities may cause worsening outcomes, which may have been seen in this case if the posterior nasopharynx was manipulated with posterior nasal packing. Onyx embolization is an uncommon technique to occlude intracranial pseudoaneurysms of the cavernous carotid artery, however its success in this case brings promise and may become a leading treatment strategy in the future.

Ethics and Consent Statements

Written informed consent from the patient and her family was obtained to write and publish this case, including all details and any accompanying images. No institutional approval was required.

Funding

This publication is funded entirely by Mercy Health.

Disclosure

The authors report no conflicts of interest in this work.

References

1. Zheng Y, Lu Z, Shen J, Xu F. Intracranial pseudoaneurysms: evaluation and management. *Front Neurol*. 2020;11:582. doi:10.3389/fneur.2020.00582
2. Taylor CL, Yuan Z, Selman WR, Ratcheson RA, Rimm AA. Cerebral arterial aneurysm formation and rupture in 20,767 elderly patients: hypertension and other risk factors. *J Neurosurg*. 1995;83(5):812–819. PMID: 7472548. doi:10.3171/jns.1995.83.5.0812

3. Larson PS, Reisner A, Morassutti DJ, Abdulhadi B, Harpring JE. Traumatic intracranial aneurysms. *Neurosurgical Focus FOC*. 2000;8(1):1–6. doi:10.3171/foc.2000.8.1.1829
4. Bhaisora KS, Behari S, Godbole C, Phadke RV. Traumatic aneurysms of the intracranial and cervical vessels: a review. *Neurol India*. 2016;64(S1):14–23. doi:10.4103/0028-3886.178032
5. Buckingham MJ, Crone KR, Ball WS, Tomsick TA, Berger TS, Tew JM. Traumatic intracranial aneurysms in childhood: two cases and a review of the literature. *Neurosurgery*. 1988;22(2):398–408. PMID: 3281054. doi:10.1227/00006123-198802000-00022
6. Witz M, Gepstein R, Paran H, et al. Endovascular treatment of an open cervical fracture with carotid artery tear. *Eur Spine J*. 2006;15(Suppl 5):650–652. PMID: 16858595; PMCID: PMC1602199. doi:10.1007/s00586-006-0182-0
7. Phuyal S, Pandey A, Bishokarma S, Lamsal R, Sedain G. Post-traumatic pseudoaneurysm of the internal carotid artery with intractable epistaxis: a case report. *JNMA J Nepal Med Assoc*. 2022;60(246):218–221. PMID: 35210651; PMCID: PMC9199992. doi:10.31729/jnma.5860
8. Ahmed O, Mahmood S, Aladham Y, Abdelnaby MM. Traumatic pseudoaneurysm of the cavernous carotid: a lethal complication of craniofacial trauma. *J Surg Case Rep*. 2020;2020(12):rjaa500. PMID: 33391640; PMCID: PMC7769192. doi:10.1093/jscr/rjaa500
9. Hacking C. Cavernous sinus (Gray's illustration). Case study, Radiopaedia.org. Available from: <https://radiopaedia.org/cases/cavernous-sinus-grays-illustration>. Accessed April 17, 2024.
10. Shi Y, Gao Y, Liu Y, et al. Treatment of traumatic intracranial pseudoaneurysms: a single-center experience. *Front Neurol*. 2021;12:690284. doi:10.3389/fneur.2021.690284
11. Bavinski G, Killer M, Knosp E, Ferraz-Leite H, Gruber A, Richling B. False aneurysms of the intracavernous carotid artery--report of 7 cases. *Acta Neurochir*. 1997;139(1):37–43. PMID: 9059710 (7). doi:10.1007/BF01850866
12. Zhang C, Xie X, You C, et al. Endovascular treatment of traumatic pseudoaneurysm presenting as intractable epistaxis. *Korean J Radiol*. 2010;11(6):603–611. PMID: 21076585; PMCID: PMC2974221. doi:10.3348/kjr.2010.11.6.603
13. Cohen JE, Rajz G, Itshayek E, Shoshan Y, Umansky F, Gomori JM. Endovascular management of traumatic and iatrogenic aneurysms of the pericallosal artery. Report of two cases. *J Neurosurg*. 2005;102(3):555–557. PMID: 15796396. doi:10.3171/jns.2005.102.3.0555
14. Redekop G, Marotta T, Weill A. Treatment of traumatic aneurysms and arteriovenous fistulas of the skull base by using endovascular stents. *J Neurosurg*. 2001;95(3):412–419. PMID: 11565861. doi:10.3171/jns.2001.95.3.0412
15. Van Rooij WJ, Van Rooij SBT. Endovascular treatment of traumatic pericallosal artery aneurysms: a case report. *Interventional Neuroradiol*. 2013;19(1):56–59. doi:10.1177/159101991301900108

Open Access Emergency Medicine

Dovepress

Publish your work in this journal

The Open Access Emergency Medicine is an international, peer-reviewed, open access journal publishing original research, reports, editorials, reviews and commentaries on all aspects of emergency medicine. The manuscript management system is completely online and includes a very quick and fair peer-review system, which is all easy to use. Visit <http://www.dovepress.com/testimonials.php> to read real quotes from published authors.

Submit your manuscript here: <https://www.dovepress.com/open-access-emergency-medicine-journal>