

Should an Incidental Meckel Diverticulum Be Resected? A Systematic Review

Vipul D Yagnik^{1,2}, Pankaj Garg³, Sushil Dawka⁴

¹Department of Surgery, Banas Medical College and Research Institute, Palanpur, GJ, India; ²Department of Surgical Gastroenterology, Nishtha Surgical Hospital and Research Centre, Patan, GJ, India; ³Department of Colorectal Surgery, Garg Fistula Research Institute, Panchkula, HR, India; ⁴Department of Surgery, SSR Medical College, Belle Rive, Mauritius

Correspondence: Vipul D Yagnik, Department of Surgery, Banas Medical College and Research Institute, at and PO: Moriya, Palanpur, GJ, India, Email vipul.yagnik@gmail.com

Background: Meckel Diverticulum [MD], a common congenital anomaly of the gastrointestinal tract, poses a dilemma when incidentally encountered during surgery. Despite historical descriptions and known complications of symptomatic MD, the decision to resect an incidental MD (IMD) lacks clear guidelines. This study aims to assess whether resecting IMDs is justified by synthesizing evidence from studies published between 2000 and 2023. Factors influencing this decision, such as demographic risks, surgical advancements and complications, are systematically examined.

Methods and Material: Following the PRISMA 2020 guidelines, this review incorporates 42 eligible studies with data on outcomes of asymptomatic MD management. Studies, both favoring and opposing resection, were analyzed.

Results: Considering complications, malignancy potential, and operative safety, the risk-benefit analysis presents a nuanced picture. Some authors propose conditional resection based on specific criteria, emphasizing patient-specific factors. Of 2934 cases analyzed for short- and long-term complications, the morbidity rate was 5.69%. Of 571 cases where mortality data were available, all 5 fatalities were attributed to the primary disease rather than IMD resection.

Conclusion: The sporadic, unpredictable presentation of IMD and the variability of both the primary disease and the patient make formulation of definitive guidelines challenging. The non-uniformity of complications reporting underscores the need for standardized categorization. While the balance of evidence leans towards resection of IMDs, this study acknowledges the individualized nature of this decision. Increased safety in surgery and anesthesia, along with better understanding and management of complications favor a judicious preference for resection, while taking into account patient characteristics and the primary disease.

Keywords: Meckel diverticulum, resection, surgery, incidental meckel, asymptomatic meckel

Introduction

It is surprising that despite the Meckel diverticulum (MD) being the most common congenital anomaly of the gastrointestinal tract, we are still unsure of what to do when we incidentally encounter one. Though first described by Fabricius Hildanus in the sixteenth century, it was a German anatomist Johann Friedrich Meckel (the younger) who, in 1809, explained its embryological origin as failure of the vitello-intestinal duct to obliterate completely.¹

MD is present in as much as 1.2% of the population,² but often remains quiescent throughout life. However, like any true diverticulum it is susceptible to complications like obstruction, hemorrhage, infection and perforation. It may also lead to intussusception, and heterotopic gastric mucosa may be a source of worrisome and confusing melena. Moreover, it may harbor a carcinoid or frankly malignant tumor. For these reasons, there is little controversy with regard to excision of a symptomatic MD.

However, the incidence of an MD as an incidental finding in laparotomy or laparoscopy done for other reasons is difficult to determine. Chen et al reported an incidence of 18.53% in the pediatric age-group³ while Blevrakis et al found it to be 0.56%.⁴ Whether an incidental MD (IMD) should be resected or left in situ has been a matter of the surgeon's own opinion or experience-based practice, and there are no definite guidelines. Attempts have been made to propose

evidence-based recommendations or formulate guidelines based on various criteria such as the demographic risk, the nature of the primary disease and the varying risk of surgery and anesthesia as well as the implications of the resection procedure itself. However, research has been hampered by the episodic nature of the discovery of an IMD and, presumably, the majority of IMDs are not captured in published research.

Recent studies have attempted to distill the gathered knowledge but no clear recommendations have emerged. However, the increased safety of surgery and anesthesia as well as a better understanding and a clearer quantification of the risks of complications in various age groups has led to a need for a re-assessment of the evidence and to provide surgeons who encounter an IMD with a clear recommendation supported by a background of current opinion. Therefore, the aim of this systematic review is to examine the relevant literature on the controversy of whether to resect an IMD and to examine whether rational summarization of the evidence allows the formulation of clear guidelines.

Methods and Materials

This systematic review was performed following the latest PRISMA, 2020 guidelines⁵ (Figure 1). The PubMed/MEDLINE, Scopus, and Cochrane library online databases were searched using the search terms “Meckel’s Diverticulum” AND “resection” AND “surgery” OR “Incidental meckel” OR “Asymptomatic meckel”. The search duration spanned 1/1/2000 to 1/10/2023. Studies reporting the management of asymptomatic diverticula in (or translatable to) English were included. Case reports, case series of under 5 patients, letters, editorials, and articles found unsuitable after abstract screening or not following inclusion criteria, were excluded. For each study, two authors independently screened the title and abstract, and any dispute was resolved by discussed consensus involving the third author. We selected and comprehensively read original articles, reviews, case series of more than five patients, and systematic reviews focusing on the management of IMD. All authors independently extracted data with regard to short- and long-term complications and mortality for IMD cases. Where these were not well-defined, the authors consented on the most appropriate categorization.

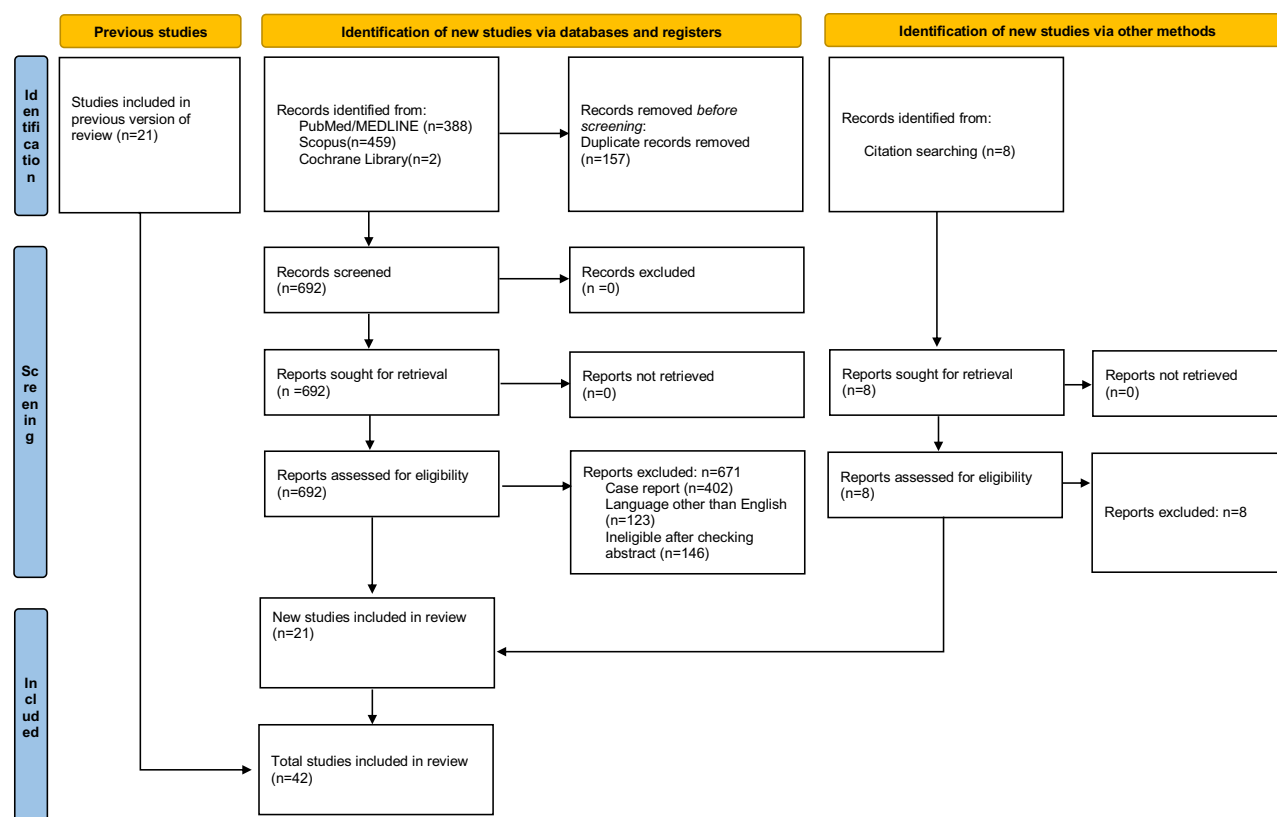


Figure 1 PRISMA 2020 flowchart of included studies.

Results

Initial search identified 849 studies of which 157 were duplicates. After analyzing the remaining studies, we found 42 studies eligible for inclusion in the review (Figure 1). Of these, 21 studies were new and had not been captured in the most recent published review, that of Rahmat et al.⁶

Our key data being the incidence of morbidity (expressed as short- and long-term postoperative complications) and clearly attributable mortality (if any), we trawled these studies' text and tables for case counts (Table 1). Only 24 studies

Table 1 Morbidity and Mortality Tally Available from Included Studies for IMD Resections

Author	Year	Short-term Complications	Long-term Complications	Mortality
Bani-Hani et al ⁹	2004	2/40	Not stated	0/40
Blevrakis et al ⁴	2011	0/25	Not stated	0/25
Blouhos et al ¹⁰	2018		Not stated	Not stated
Chen et al ³	2018	0/53	0/53	0/53
Demirel et al ¹¹	2019	Not stated	Not stated	Not stated
Felberbauer et al ¹²	2007	Not stated	Not stated	Not stated
Gezer et al ¹³	2015	1/8	0/8	0/8
Groebl et al ⁷	2001	6/67	0/67	0/67
Hansen et al ¹⁴	2018	Not stated	Not stated	Not stated
Karaman et al ¹⁵	2010	0/25	0/25	0/25
Kuru et al ¹⁶	2018	Not stated	Not stated	Not stated
Lequet et al ¹⁷	2017	Not stated	Not stated	Not stated
Levy et al ¹⁸	2004	Not stated	Not stated	Not stated
Lindeman ¹⁹	2020	Not stated	Not stated	Not stated
Loh et al ²⁰	2014	1/30	0/30	0/30
Lohsiriwat et al ²¹	2014	4/33	Not stated	3/33
Malderen et al ²²	2018	Not stated	Not stated	Not stated
Malik et al ²³	2009	Not stated	Not stated	Not stated
McKay ²⁴	2007	1/10	Not stated	0/10
Mora-Guzmán et al ²⁵	2019	0/36	0/36	0/36
Onen et al ²⁶	2003	9/39	Not stated	1/39
Park et al ²⁷	2005	14/69	Not stated	1/69
Pinero et al ²⁸	2002	6/34	Not stated	0/34
Poncet et al ²⁹	2011	Not stated	Not stated	Not stated
Prasad et al ³⁰	2006	0/2	Not stated	0/2
Rahmat et al ⁶	2020	Not stated	Not stated	Not stated
Robijn et al ³¹	2006	Not stated	Not stated	Not stated

(Continued)

Table 1 (Continued).

Author	Year	Short-term Complications	Long-term Complications	Mortality
Ruscher et al ³²	2011	Not stated	Not stated	Not stated
Sagar et al ³³	2006	Not stated	Not stated	Not stated
Saiprasad et al ³⁴	2007	1/10	Not stated	0/10
Shalaby et al ³⁵	2005	0/21	Not stated	0/21
Stone et al ³⁶	2004	3/35	Not stated	Not stated
Tartaglia et al ³⁷	2020	0/39	Not stated	0/39
Tauro et al ³⁸	2010	1/8	Not stated	Not stated
Thirunavukarasu et al ³⁹	2011		Not stated	Not stated
Tree et al ⁴⁰	2023	6/68	Not stated	Not stated
Ueberrueck et al ⁴¹	2005	18/188	Not stated	Not stated
Varcoe et al ⁴²	2004	3/44	Not stated	Not stated
Yahchouchy et al ⁸	2001	Not stated	Not stated	Not stated
Zani et al ²	2008	123/2304	Not stated	Not stated
Zulfikaroglu et al ⁴³	2008	2/40	Not stated	0/40
Zyluk et al ⁴⁴	2019	Not stated	Not stated	Not stated

Abbreviation: IMD, Incidental Meckel's Diverticulum.

provided data on the incidence of postoperative complications and only 7 divided this as short and long-term. We used data provided as absolute numbers, not percentages. As three included studies, those of Zani et al,² Groebli et al,⁷ and Yahchouchy et al⁸ were reviews that compiled data from several studies, we ensured that none of those studies were re-counted in the final tally.

From studies where counts were available, we tallied 5 deaths out of 571 cases. However, 3 were described as unrelated to MD,²¹ 1 not due to MD resection²⁷ and 1 was in the pediatric age group where “asymptomatic” included intussusception and volvulus caused by MD.²⁶ From the discussion, it was clear that no deaths could be directly attributed to the added effect of resecting an incidental and uncomplicated MD.

With regard to short- and long-term complications, the heterogeneity in their nomenclature and categorization across the few studies that quoted this data precluded compartmentalization; we, therefore, clubbed all post-operative morbidity in one count. Of 2934 cases, there were 167 complications giving a morbidity rate of 5.69%.

Discussion

Data with regard to complications have been extracted from all eligible studies. The problems encountered were that these studies have great heterogeneity with respect to the point of concern and they were obviously not standardized as to outcomes. Some studies list complications as short and long term, others simply list them (as they are generally so few) into infection or obstruction, and mention the rare case that required re-exploration or culminated in death. Indeed, few studies attempted to look at the Clavien-Dindo grading.^{20,25} In most cases, the authors have specified that, in their considered opinion, the severe complications or the mortality were not directly attributable to the added procedure of IMD resection.

Rahmat et al⁶ have taken an interesting approach to overcome the heterogeneity of these studies; they have pooled not data but opinions from the literature. However, closer perusal of these studies shows that, in some case, the opinions

expressed regarding the advisability of resecting an IMD are not derived from the preceding adduced evidence in an objective manner. Some authors have clearly expressed that theirs is a personal preference influenced, no doubt, by their own experience. They compiled data from 31 studies and concluded that there was a move towards resection based on risk factors and called for analysis and definition of these criteria.

In the absence of any weightage based on number of cases in each study, we feel this is somewhat subjective and we have attempted to go beyond this to the actual number of complications reported, with the proviso that there is no uniformity in the definition or severity of complications. We therefore intend to supplement this with a detailed discussion of the complications as reported to provide a context.

Complication Rates

Our analysis of IMD resection cases pooled from the recent literature shows that the complication rate was 5.69%. This is on par with complication rates for general surgery as studies quote a very wide range that reflect their heterogeneity. A prospective observational study at a tertiary care hospital in India reported that in patients undergoing elective or emergency surgery the incidence of postoperative complications was 31.5% [minor complications (Clavien-Dindo grades I and II) in 19.75% and major complications (Clavien-Dindo grades III and IV) in 8% of patients, overall postoperative mortality was 3.75%].⁴⁵ A review of 18 studies from 2013 reported an overall complication rate of 37% (3.9–43.5%).⁴⁶ Bolliger et al in a retrospective study of surgical complications in general surgery patients at an Austrian tertiary care hospital reported an incidence of 12.5%.⁴⁷ With the understanding that studies to assess complication rates will necessarily be epidemiologic and therefore non-standardizable, a complication rate of 5.69% seems reasonably within expected norms.

Against IMD Resection

Traditional conservatism has been based historically on a number of seminal studies that bear re-appraisal in the present day as their results are conflicting, misinterpreted and, therefore, illustrative of our thesis. Soltero and Bill (1976) reported a complication rate for resection of IMD as 8.9% (against a rate of complications of 4.2% (at birth) decreasing to 0% (in adults) if unresected and a complication rate of 11.1% for resection of symptomatic MD).⁴⁸ This study, though dated by half a century, has been the bulwark of the resistance to IMD resection. The authors calculated the risk of MD complications decreasing with age from 4.2% to near 0. Taking previously published data for morbidity and mortality for complicated Meckel diverticulum resection at 11.1% and 6–7%, respectively, and 8.9% and 0% for IMD resection they put forth the widely quoted observation that it would require 400 resections at birth (or 800 later in life) to prevent one death but at the cost of 36 complications. Their rationale is flawless and the postulate of operating solely to remove an asymptomatic MD is only intended to provide a context. Unfortunately, this implication that one would operate solely to remove an asymptomatic MD is untenable. The reality is that the morbidity of the primary surgery exists and we are considering whether the resection of an IMD would add significantly to the established risks. No one would seriously recommend operating solely for an IMD and, interestingly, even in this hypothetical scenario, the risk of complications would be at par with complication rates for all general surgery.

The more recent work of Zani et al (2008) reviewed 1975 cases of MD and reported a complication rate for resection of IMD as 5.3% against a rate of complications of 1.3% if unresected.² From seven autopsy studies, they calculated that the number of subjects with IMD that would have to have a resection to prevent one death was 758 (781–1111 as age increases). Again, their rationale is clear but the question is about the added risk due to the added procedure, not the risk attributable entirely to resection of an asymptomatic IMD. Moreover, mortality studies may be an overstatement of the risks as they represent the end of the spectrum where a primary cause may not be accurately identifiable.

Stone et al (2004) reported their experience of Meckel diverticulectomy in 47 adults, 35 (74.5%) of whom were incidental.³⁶ Based on post-operative complications (two wound infections and two anastomotic leaks requiring exploration) and the low risk of turning symptomatic, they recommend against incidental removal of asymptomatic MD, especially in women. Two patients had incidental tumors, an adenomyoma and a carcinoid.

For IMD Resection

Cullen et al (1994) in an epidemiologic population-based study that followed a resident population for over 4 decades reported a complication rate for resection of IMD as 2% (against a rate of complications of 6.4% if unresected and a complication rate of 12% for resection of symptomatic MD).⁴⁹ They also quote historical studies that put the incidence of adverse outcomes after IMD resection as ranging from 1% to 9%. They clearly consider the 6.4% lifetime risk of complications and the low rates of both short- and long-term postoperative complications from IMD resection as significant. They opine that since mortality was due to the primary disease and general health in most patients, and complications are not necessarily more in childhood, IMD resection is recommended at all ages.

Several other authors unequivocally favor resection of an asymptomatic MD. Mora Guzman et al (2019) comparing 30 symptomatic MD resections with 36 incidental resections, encountered major post-operative complications in 6.6% of the former group but none in the latter. Incidentally, three neuroendocrine malignancies were found, and their recommendation is based on this risk-benefit logic.²⁵ Tartaglia et al (2020) noting that incidental MD may harbor ectopic mucosa or tumor and given that stapled is low-risk, support diverticulectomy as a safe and effective for incidentally discovered MD.³⁷

Conditional Resection

Several studies endorse a criterion-based approach. Strong evidence comes from two systematic reviews: Sagar et al (2004) reviewed the literature but did not synthesize their results.³³ They secondarily recommended resection based variously on criteria suggested by other authors.

Felberbauer et al (2007) in a meta-analysis of contemporary large studies considered palpable foreign tissue, length greater than 2 cm, patient under 45 years, male gender as criteria favoring a decision for resection.¹² In an algorithmic flowchart, they also recommended against resection in cases with generalized peritonitis, planned implantation of prostheses, distended bowel or carcinomatosis as contraindications for resection of an asymptomatic MD, limiting surgery to resection of a vitelline band, if present. Supporting their counsel is their observation that in 1116 incidental MD resections, the morbidity and mortality were 3.67% and 0.18%, respectively, while for 502 symptomatic MD resections, the corresponding figures were 9.56% and 1.99%, a difference that was highly significant. Robijn et al (2006) devised a risk score weighted on male sex, age under 45 years, length over 2 cm and presence of a fibrous band.³¹ Notably, they did not include the known risk factor of ectopic tissue as they felt that external palpation was an unreliable indicator of its presence. Though mentioned by subsequent studies, this Risk Score has not been validated by other studies and remains empirical. They also emphasize that surgical morbidity is ever decreasing and the prevalence of minimal access procedures with the use of stapling devices have made resection of an incidental MD even more safe than historical data would suggest. Lindeman et al (2020) noting that MD usually remains asymptomatic advised that decisions be made on patient-specific factors.¹⁹ Park et al (2005), reporting the extensive Mayo clinic experience of 1476 patients over half a century, observed that of late the procedure had little risk and recommended resection for IMD if features associated with symptomatic MD were found.²⁷ These include male gender, age below 50 years, MD longer than 2 cm or with obvious abnormality, and they quantified the complication risk as 70% 42%, 25%. and 17% for all, three, two or one criteria, respectively.

Risk of Malignancy

Thirunavukarasu et al in a study of cancer in MD and ileal cancer described MD as a “hot-spot” or high-risk area with an adjusted risk at least 70 times higher than for any ileal site.³⁹ Noting that risk increases with age and the high possibility of curative resection with negligible operative mortality, they unequivocally recommend resection of IMD, though not for detection on imaging of IMD.

Operative Safety

The question has traditionally been whether an incidentally found Meckel diverticulum should be resected. Today, with the increased safety of anesthesia and surgery, in terms of laparoscopic access, stapled closure and overall reduction in

operating times, optimized post-operative protocols and better detection and management of complications, one needs to consider whether and, if so, how much the additional procedure would compromise the safety of the patient. It barely needs emphasis that resection of an IMD is not a primary procedure; no one is (yet) advocating removal of an IMD in a patient who has no other problem requiring surgical exploration. It is nigh impossible to separately quantify any perceived additional risk due to the resection, with perhaps an increased risk of leak or infection. Any study that attempts to do so must realize that leakage and infection are more likely to emanate from the diseased primary pathology site rather than the resected site of a quiescent MD.

Incidental Appendectomy

A parallel maybe drawn with removal of an appendix during non-appendiceal surgery. Despite much debate over decades, there are no guidelines and most surgeons go with their convictions based on their experience and specific patient-related factors. Studies confirm the increased time involved, the added expense and the slightly increased risk of infection, all features that apply to IMD resection. A recent review by Kumar et al (2023) noted that it was being phased out and should not be routine.⁵⁰ If performed, it should be based on patient specifics. A systematic review by Healy et al (2016) on pediatric incidental appendectomy emphasizes the need to consider the co-morbidity, the primary operation, the risk of appendiceal disease and its utility as a reconstructive conduit.⁵¹ However, there is one undeniable disadvantage unique to incidental appendectomy in that if present it may be used in reconstructive surgery such as ureteral interposition, Mitrofanoff appendico-vesicostomy for neuropathic bladder, and appendicostomy for the Malone antegrade continence enema. There is no known reconstructive utility of an MD.

Limitations

Data with regard to complications have been extracted from all eligible studies. Unfortunately, these studies have great heterogeneity with respect to the point of concern as they were obviously not standardized as to outcomes. This lack of uniformity and the anecdotal approach to reporting cases has been the greatest limitation of our study. Some studies that question the advisability of IMD resection seem biased towards the authors' predispositions, and their discussions seem stacked to bolster the authors' preconceived viewpoint. We have therefore limited ourselves to extracting raw complication and mortality counts (in actual case numbers), excluding rates or percentages where the denominator was unknown, and thus avoided merely echoing the authors' conclusions. Unfortunately, this has caused some attrition of case numbers and, potentially, loss of some useful information.

Some studies list complications as short and long term, others simply list them (as they are generally so few) into infection or obstruction, and mention the rare case that required re-exploration or culminated in death. In most cases, the authors have specified that, in their considered opinion, the severe complications or the mortality were not directly attributable to the added procedure of IMD resection. Given the episodic nature of an IMD encounter and the impossibility of having controls, we have attempted to present the current balance of evidence and tagged our conclusions as guarded and conditional, being more in the nature of suggestions, not guidelines.

Conclusion

The balance of evidence would appear to favor resection of an incidental MD. This is supported by increased safety of surgery and anesthesia, currently and going forward, as well as a better understanding of the risks of conservation and more efficacious management of complications. Moreover, unlike the appendix, an MD has no potential benefit in future reconstructive surgery.

Whether a 5.69% incidence of complications following resection of IMD is acceptable is moot as the widely varied situations in which an IMD may present preclude broad generalizations. More pertinently, it must be emphasized that these statistics merely indicative as it summarizes historical data and will most definitely decrease in the future. Given the sporadic incidence and consequent under-reporting of IMD, a controlled study is not feasible; any guidelines are likely to be more advisory than prescriptive. Ultimately, the fate of an IMD will depend upon the surgeon's reading of the on-table situation against the background of the patient's characteristics and primary disease. This decision will inevitably be influenced by the surgeon's clinical experience and operative predisposition, as well as personal track record of dealing

with MD. Therefore, the recommendation of this study, considering historical evidence and future trends, is an individualized patient-centric decision weighted towards resection.

Disclosure

The authors report no conflicts of interest in this work.

References

1. Meckel JF. Über die divertikel am darmkanal. *Arch Physiol*. 1809;9:421–453.
2. Zani A, Eaton S, Rees CM, et al. Incidentally detected Meckel diverticulum: to reset or not to resect? *Ann Surg*. 2008;247(2):276–281.
3. Chen Q, Gao Z, Zhang L, et al. Multifaceted behavior of Meckel's diverticulum in children. *J Pediatr Surg*. 2018;53(4):676–681. doi:10.1016/j.jpedsurg.2017.11.059
4. Blevrakis E, Partalis N, Seremeti C, Sakellaris G. Meckel's diverticulum in paediatric practice on Crete (Greece): a 10-year review. *Afr J Paediatr Surg*. 2011;8(3):279–282. doi:10.4103/0189-6725.91665
5. Page MJ, McKenzie JE, Bossuyt PM, et al. The PRISMA 2020 statement: an updated guideline for reporting systematic reviews. *Syst Rev*. 2021;10:89.
6. Rahmat S, Sangle P, Sandhu O, Aftab Z, Khan S. Does an incidental Meckel's diverticulum warrant resection? *Cureus*. 2020;12(9):e10307. doi:10.7759/cureus.10307
7. Groebli Y, Bertin D, Morel P. Meckel's diverticulum in adults: retrospective analysis of 119 cases and historical review. *Eur J Surg*. 2001;167(7):518–524. doi:10.1080/110241501316914894
8. Yahouchy EK, Marano AF, Etienne JC, Fingerhut AL. Meckel's diverticulum. *J Am Coll Surg*. 2001;192(5):658–662. doi:10.1016/s1072-7515(01)00817-1
9. Bani-Hani KE, Shatnawi NJ. Meckel's diverticulum: comparison of incidental and symptomatic cases. *World J Surg*. 2004;28(9):917–920. doi:10.1007/s00268-004-7512-3
10. Blouhos K, Boulas KA, Tsalis K, et al. Meckel's diverticulum in adults: surgical concerns. *Front Surg*. 2018;5:55. doi:10.3389/fsurg.2018.00055
11. Demirel BD, Hancioglu S, Bicakci U, Bernay F, Aritürk E. Complications of Meckel's diverticulum in children: a 10-years experience. *Exp Clin Med*. 2019;36(3):67–71. doi:10.5835/jecm.omu.36.03.001
12. Felberbauer F, Niederle B, Teleky B. The truth behind the “rule of twos” the Meckel diverticulum revised. *Eur Surg*. 2007;39:299–306. doi:10.1007/s10353-007-0341-5
13. Gezer HÖ, Temiz A, İnce E, Ezer SS, Hasbay B, Hiçsönmez A. Meckel diverticulum in children: evaluation of macroscopic appearance for guidance in subsequent surgery. *J Pediatr Surg*. 2016;51(7):1177–1180. doi:10.1016/j.jpedsurg.2015.08.066
14. Hansen CC, Søreide K. Systematic review of epidemiology, presentation, and management of Meckel's diverticulum in the 21st century. *Medicine (Baltimore)*. 2018;97(35):e12154. doi:10.1097/MD.00000000000012154
15. Karaman A, Karaman I, Çavuşoğlu YH, Erdoğan D, Aslan MK. Management of asymptomatic or incidental Meckel's diverticulum. *Indian Pediatr*. 2010;47(12):1055–1057. doi:10.1007/s13312-010-0176-1
16. Kuru S, Kismet K. Meckel's diverticulum: clinical features, diagnosis and management. *Rev Esp Enferm Dig*. 2018;110(11):726–732. doi:10.17235/reed.2018.5628/2018
17. Lequet J, Menahem B, Alves A, Fohlen A, Mulliri A. Meckel's diverticulum in the adult. *J Visc Surg*. 2017;154(4):253–259. doi:10.1016/j.jvisurg.2017.06.006
18. Levy AD, Hobbs CM. Meckel diverticulum: radiologic features with pathologic correlation. *Radiographics*. 2004;24(2):565–587. doi:10.1148/rg.242035187
19. Lindeman RJ, Søreide K. The many faces of Meckel's diverticulum: update on management in incidental and symptomatic patients. *Curr Gastroenterol Rep*. 2020;22(1):3. doi:10.1007/s11894-019-0742-1
20. Loh JC, Kruschewski M, Buhr HJ, Lehmann KS. Safety of resection of symptomatic and asymptomatic Meckel's diverticulum and literature review. *ZentralblChir*. 2014;139(4):452–459. doi:10.1055/s-0032-1327963
21. Lohsirawat V, Sirivech T, Laohapensang M, Pongpaibul A. Comparative study on the characteristics of Meckel's diverticulum removal from asymptomatic and symptomatic patients: 18-year experience from Thailand's largest university hospital. *J Med Assoc Thai*. 2014;97(5):506–512.
22. Malderen KV, Vijayvargiya P, Camilleri M, Larson DW, Cima R. Malignancy and Meckel's diverticulum: a systematic literature review and 14-year experience at a tertiary referral center. *United Eur Gastroenterol J*. 2018;6(5):739–747. doi:10.1177/2050640617752771
23. Malik AA, Shams-ul-Bari KA, Khaja AR. Meckel's diverticulum-revisited. *Saudi J Gastroenterol*. 2010;16(1):3–7. doi:10.4103/1319-3767.58760
24. McKay R. High incidence of symptomatic Meckel's diverticulum in patients less than fifty years of age: an indication for resection. *Am Surg*. 2007;73(3):271–275.
25. Mora-Guzmán I, Muñoz de Nova JL, Martín-Pérez E. Meckel's diverticulum in the adult: surgical treatment. *Acta Chir Belg*. 2019;119(5):277–281. doi:10.1080/00015458.2018.1503391
26. Onen A, Cigdem MK, Öztürk H, Otçu S, Dokucu AI. When to resect and when not to resect an asymptomatic Meckel's diverticulum: an ongoing challenge. *Pediatr Surg Int*. 2003;19(1–2):57–61. doi:10.1007/s00383-002-0850-z
27. Park JJ, Wolff BG, Tollefson MK, Walsh EE, Larson DR. Meckel diverticulum: the Mayo Clinic experience with 1476 patients (1950–2002). *Ann Surg*. 2005;241(3):529–533. doi:10.1097/01.sla.0000154270.14308.5f
28. Piñero A, Martínez-Barba E, Canteras M, Rodríguez JM, Castellanos G, Parrilla P. Surgical management and complications of Meckel's diverticulum in 90 patients. *Eur J Surg*. 2002;168(1):8–12. doi:10.1080/110241502317307508
29. Poncet G, Hervieu V, Walter T, et al. Neuroendocrine tumors of Meckel's diverticulum: lessons from a single institution study of eight cases. *J Gastrointest Surg*. 2011;15(1):101–109. doi:10.1007/s11605-010-1312-x
30. Prasad TR, Chui CH, Jacobsen AS. Laparoscopic-assisted resection of Meckel's diverticulum in children. *JSLs*. 2006;10(3):310–316.

31. Robijn J, Sebrechts E, Miserez M. Management of incidentally found Meckel's diverticulum a new approach: resection based on a Risk Score. *Acta Chir Belg.* 2006;106(4):467–470. doi:10.1080/00015458.2006.11679933
32. Ruscher KA, Fisher JN, Hughes CD, et al. National trends in the surgical management of Meckel's diverticulum. *J Pediatr Surg.* 2011;46(5):893–896. doi:10.1016/j.jpedsurg.2011.02.024
33. Sagar J, Kumar V, Shah DK. Meckel's diverticulum: a systematic review. *J R Soc Med.* 2006;99(10):501–505. doi:10.1177/014107680609901011
34. Sai Prasad TR, Chui CH, Singaporewalla FR, et al. Meckel's diverticular complications in children: is laparoscopy the order of the day? *Pediatr Surg Int.* 2007;23(2):141–147. doi:10.1007/s00383-006-1844-z
35. Shalaby RY, Soliman SM, Fawy M, Samaha A. Laparoscopic management of Meckel's diverticulum in children. *J Pediatr Surg.* 2005;40(3):562–567. doi:10.1016/j.jpedsurg.2004.11.032
36. Stone PA, Hofeldt MJ, Campbell JE, Vedula G, DeLuca JA, Flaherty SK. Meckel diverticulum: ten-year experience in adults. *South Med J.* 2004;97(11):1038–1041. doi:10.1097/01.SMJ.0000125222.90696.03
37. Tartaglia D, Cremonini C, Strambi S, et al. Incidentally discovered Meckel's diverticulum: should I stay or should I go? *ANZ J Surg.* 2020;90(9):1694–1699. doi:10.1111/ans.16189
38. Tauro LF, George C, Rao BS, Martis JJ, Menezes LT, Shenoy HD. Asymptomatic Meckel's diverticulum in adults: is diverticulectomy indicated? *Saudi J Gastroenterol.* 2010;16(3):198–202. doi:10.4103/1319-3767.65199
39. Thirunavukarasu P, Sathiaiah M, Sukumar S, et al. Meckel's diverticulum—a high-risk region for malignancy in the ileum. Insights from a population-based epidemiological study and implications in surgical management. *Ann Surg.* 2011;253(2):223–230. doi:10.1097/SLA.0b013e3181ef488d
40. Tree K, Kotecha K, Reeves J, et al. Meckel's diverticulectomy: a multi-centre 19-year retrospective study. *ANZ J Surg.* 2023;93(5):1280–1286. doi:10.1111/ans.18351
41. Ueberrueck T, Meyer L, Koch A, Hinkel M, Kube R, Gastinger I. The significance of Meckel's diverticulum in appendicitis—a retrospective analysis of 233 cases. *World J Surg.* 2005;29(4):455–458. doi:10.1007/s00268-004-7615-x
42. Varcoe RL, Wong SW, Taylor CF, Newstead GL. Diverticulectomy is inadequate treatment for short Meckel's diverticulum with heterotopic mucosa. *ANZ J Surg.* 2004;74(10):869–872. doi:10.1111/j.1445-1433.2004.03191.x
43. Zulfikaroglu B, Ozalp N, Zulfikaroglu E, Ozmen MM, Tez M, Koc M. Is incidental Meckel's diverticulum resected safely? *N Z Med J.* 2008;121(1282):39–44.
44. Żyluk A. Management of incidentally discovered unaffected Meckel's diverticulum - a review. *Pol PrzeglChir.* 2019;91(6):41–46. doi:10.5604/01.3001.0013.3400
45. Dharap SB, Barbaniya P, Navgale S. Incidence and risk factors of postoperative complications in general surgery patients. *Cureus.* 2022;14(11):e30975. doi:10.7759/cureus.30975
46. Tevis SE, Kennedy GD. Postoperative complications and implications on patient-centered outcomes. *J Surg Res.* 2013;181(1):106–113. doi:10.1016/j.jss.2013.01.032
47. Bolliger M, Kroehnert JA, Molineus F, Kandioler D, Schindl M, Riss P. Experiences with the standardized classification of surgical complications (Clavien-Dindo) in general surgery patients. *Eur Surg.* 2018;50(6):256–261. doi:10.1007/s10353-018-0551-z
48. Soltero MJ, Bill AH. The natural history of Meckel's Diverticulum and its relation to incidental removal. A study of 202 cases of diseased Meckel's Diverticulum found in King County, Washington, over a fifteen year period. *Am J.* 1976;132(2):168–173. doi:10.1016/0002-9610(76)90043-x
49. Cullen JJ, Kelly KA, Moir CR, Hodge DO, Zinsmeister AR, Melton LJ. Surgical management of Meckel's diverticulum An epidemiologic, population-based study. *Ann Surg.* 1994;220(4):564–568. doi:10.1097/00000658-199410000-00014
50. Kumar HR, Soma M, Saw MO. Incidental appendectomy-current management. *Asian J Med Health.* 2023;21(10):341–347. doi:10.9734/ajmah/2023/v21i10911
51. Healy JM, Olgun LF, Hittelman AB, Ozgediz D, Caty MG. Pediatric incidental appendectomy: a systematic review. *Pediatr Surg Int.* 2016;32(4):321–335. doi:10.1007/s00383-015-3839-0

Clinical and Experimental Gastroenterology

Dovepress

Publish your work in this journal

Clinical and Experimental Gastroenterology is an international, peer-reviewed, open access, online journal publishing original research, reports, editorials, reviews and commentaries on all aspects of gastroenterology in the clinic and laboratory. This journal is indexed on American Chemical Society's Chemical Abstracts Service (CAS). The manuscript management system is completely online and includes a very quick and fair peer-review system, which is all easy to use. Visit <http://www.dovepress.com/testimonials.php> to read real quotes from published authors.

Submit your manuscript here: <https://www.dovepress.com/clinical-and-experimental-gastroenterology-journal>