

Evaluating the Therapeutic Potential of Durvalumab in Adults with Locally Advanced or Metastatic Biliary Tract Cancer: Evidence to Date

Michael H Storandt¹, Zhaohui Jin², Amit Mahipal³

¹Department of Internal Medicine, Mayo Clinic, Rochester, MN, USA; ²Department of Medical Oncology, Mayo Clinic, Rochester, MN, USA;

³Department of Medical Oncology, University Hospitals Seidman Cancer Center, Case Western Reserve University, Cleveland, OH, USA

Correspondence: Amit Mahipal, University Hospitals Seidman Cancer Center, Case Western Reserve University, 11100 Euclid Ave, Cleveland, OH, 44106, USA, Tel +1 216-844-3951, Email Amit.mahipal@UHhospitals.org

Abstract: Advanced biliary tract cancers (BTCs) have historically been managed with chemotherapy but, in recent years, this treatment paradigm has begun to shift with the introduction of immune checkpoint inhibitors in addition to standard of care chemotherapy. The tumor microenvironment of BTC may be enriched with regulatory T lymphocytes and immune checkpoint expression in some patients. Durvalumab, an anti-programmed death ligand-1 (PD-L1) antibody, in combination with gemcitabine and cisplatin, has now received United States Food and Drug Administration approval for treatment of advanced BTC. Regulatory approval was based on the Phase III, randomized TOPAZ-1 trial that demonstrated survival benefit with addition of durvalumab to gemcitabine plus cisplatin compared to chemotherapy alone. The combination of chemotherapy and immunotherapy was well tolerated, and a subset of patients were able to achieve a durable response, with a 2-year overall survival rate of 23.6%. However, limitations remain in identifying which patients are most likely to benefit from immune checkpoint inhibition. Future study should aim to identify biomarkers predictive of substantial benefit, as well as the role of immune checkpoint inhibition in combination with targeted therapies and radiotherapy in the management of advanced BTC.

Keywords: durvalumab, immunotherapy, cholangiocarcinoma, bile duct cancers

Introduction

Biliary tract cancers (BTCs), arising from the biliary epithelium, include intra- and extra-hepatic cholangiocarcinoma (CCA), gallbladder carcinoma (GC), and ampullary carcinoma (AC). BTC has an incidence of 2.32 cases per 100,000 in the United States (US) and, globally, the highest incidence is found in Asia and South America.¹ In the US, the most common subtype is intrahepatic CCA, with an estimated incidence of approximately 1.5 cases per 100,000, followed by GC, extrahepatic CCA, and lastly, AC.² The incidence of BTCs is projected to increase in the coming years, with the largest contribution by intrahepatic CCA.^{3,4}

Historically, treatment of advanced BTC consisted of gemcitabine plus cisplatin based on ABC-02, which randomized patients with advanced or metastatic BTC to gemcitabine with or without cisplatin and demonstrated an improvement in median overall survival (mOS) with the combination regimen compared to single agent gemcitabine [11.7 vs 8.1 months, hazard ratio (HR) = 0.64, 95% confidence interval (CI) = 0.52–0.80, $p < 0.001$].⁵ Following this trial, subsequent studies failed to demonstrate the superiority of alternative regimens. SWOG 1815 failed to show a survival benefit with the addition of nab-paclitaxel to gemcitabine plus cisplatin.⁶ PRODIGE 38 AMEBICA, which randomized patients to FOLFIRINOX or gemcitabine plus cisplatin, failed to meet its primary endpoint of improved 6-month progression free survival (PFS).⁷ As such, gemcitabine plus cisplatin remained the standard of care for management of BTCs in the first line setting for over 10 years. Unfortunately, the prognosis for patients with advanced BTC remained poor, prompting the need for better options.

More recently, the role of immunotherapy in combination with standard chemotherapy has been evaluated in advanced BTC, including immune checkpoint inhibitors such as durvalumab and pembrolizumab. This is in line with recent changes in management of hepatocellular carcinoma, with first line options now including atezolizumab plus bevacizumab following the IMbrave150 trial, and the combination of tremelimumab plus durvalumab following the HIMALAYA trial.^{8,9} As of September 2022, durvalumab in addition to chemotherapy has received US Food and Drug Administration (FDA) approval for treatment of advanced or metastatic BTC in the first-line setting. This was followed by FDA approval for pembrolizumab plus chemotherapy in 2024. This review will aim to discuss the role of durvalumab in the treatment of advanced BTC and summarize the current evidence to date.

Tumor Micro-Environment of Biliary Tract Cancers

Before discussing the role of immunotherapy in BTC, it is important to understand the tumor microenvironment (TME) and how it may facilitate a response to immune checkpoint inhibition. The TME of BTC contains different cell populations, including regulatory T cells, cancer associated fibroblasts that secrete the extracellular matrix, myeloid-derived suppressor cells, and tumor associated macrophages, which all contribute to an immunosuppressive TME.¹⁰ Within BTC, there may be an increased number of regulatory T cells among tumor-infiltrating lymphocytes, with over-expression of programmed cell death protein 1 (PD-1) and cytotoxic T-lymphocyte associated protein 4 (CTLA-4), which function as immune checkpoints.¹¹

The liver, overall, is regarded as an immune tolerant environment, as facilitated by the cell populations listed above.¹² In the case of hepatocellular carcinoma and BTC, underlying liver inflammation related to chronic viral infection and steatohepatitis is common. In patients with Hepatitis B, blunting of NK and T cell responses through the release of IL-10 may reduce the capability of the immune system to target tumor cells, while the immunosuppressive environment in hepatitis C may be driven by a phenomenon referred to as T cell exhaustion, among other mechanisms.^{13,14} With alcoholic steatohepatitis, there may be immune evasion in the setting of increased granulocytic myeloid-derived suppressor cells within the liver.¹⁵

A study evaluating 198 intrahepatic CCAs in a training set and 368 tumors in a validation set reported four different microenvironment subsets based on the mechanism of immune evasion.¹⁶ These subsets included an “immune desert” phenotype in 46%, an inflammatory phenotype with increased immune cell infiltration and expression of immune checkpoint molecules in 13%, a myeloid-rich subtype in 19%, and a mesenchymal subtype with significant fibroblast activation in 22%. An additional study completed somatic profiling of BTCs, and found a subset of patients with heightened activity of the host immune system, but simultaneously high expression of immune checkpoint molecules.¹⁷ It was hypothesized that this subset of patients may be particularly responsive to immune checkpoint inhibition. A subsequent study found that some patients with intrahepatic CCA have defective HLA class I expression with elevated PD-L1 expression, allowing for immune evasion, and, again, supporting the hypothesis that immune checkpoint inhibition may play a role in the management of BTC.¹⁸

As such, these studies prompted exploration into immune checkpoint inhibition for management of BTC. An early retrospective analysis at a single institution compared patients with BTC who had received an immune checkpoint inhibitor, an immune checkpoint inhibitor plus chemotherapy, or chemotherapy alone, and found that those who had received chemo-immunotherapy had a longer median OS (mOS) compared to those who had received immunotherapy alone (HR = 0.37, 95% CI = 0.17–0.80, $p = 0.001$) and chemotherapy alone (HR = 0.63, 95% CI = 0.42–0.94, $p = 0.011$).¹⁹ While difficult to draw definitive conclusions from this retrospective analysis, it did suggest a role for combination therapy with immune checkpoint inhibition and chemotherapy in the management of BTC. Immune checkpoints of interest in BTC are depicted in Figure 1.

While immune checkpoint inhibitor monotherapy has been lacking in promise in BTC, the combination of chemotherapy and immunotherapy is of interest.²⁰ Evidence would suggest chemotherapy may increase the efficacy of immune checkpoint inhibition through various mechanisms, including the elimination of suppressive immune cells, increase of tumor antigen expression, and facilitation of penetration of immune cells into the tumor stroma.^{21,22} This provides the rationale for combination therapy for management of solid malignancies. Clinically, the combination of chemotherapy and immunotherapy has been successful in other malignancies including lung cancer and gastric cancer.

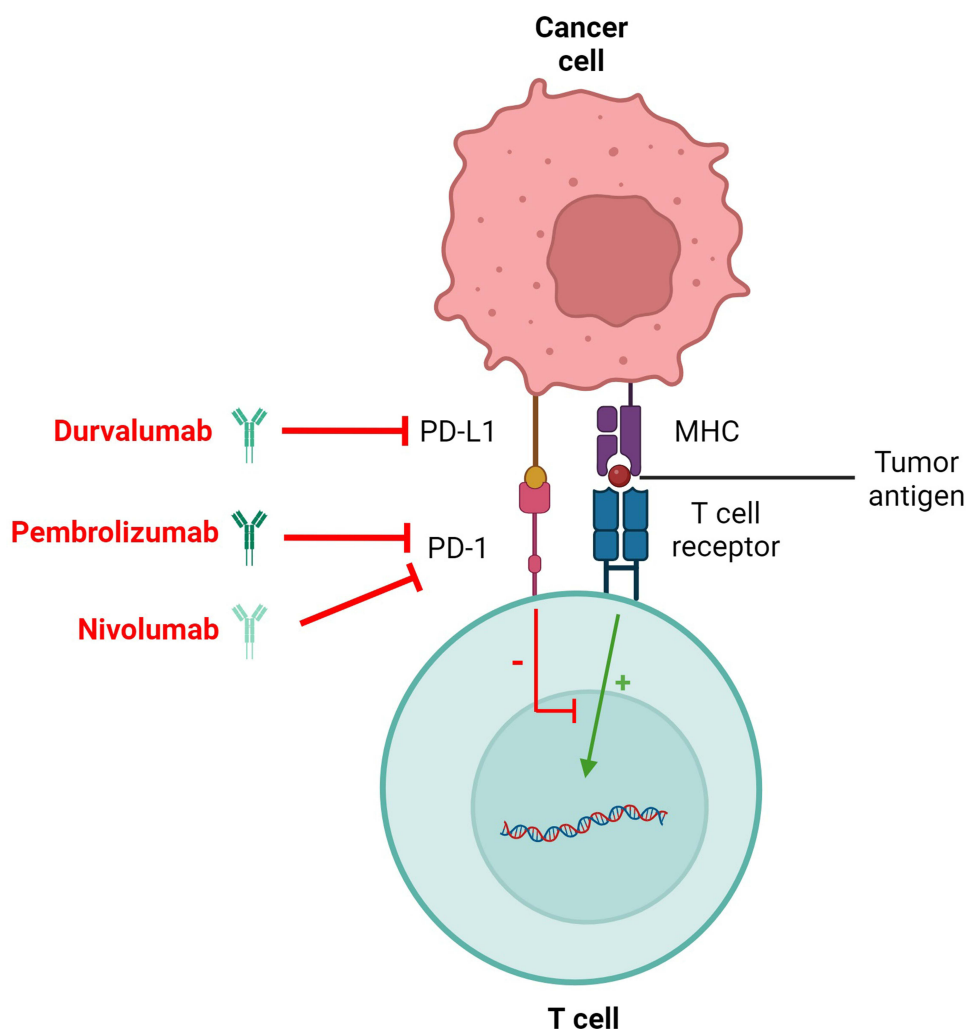


Figure 1 Immune checkpoints of interest in BTC.

Notes: Tumor antigen interacts with the T cell receptor, which may lead to activation of the T cell. However, PD-L1 on the tumor cell may bind with PD-1 on the T cell, leading to inhibition of this process. PD-1 and PD-L1 antagonists disinhibit T cell activation, allowing for activation of the immune system to target tumor cells. Image created using biorender.com.

Abbreviations: PD-L1, programmed death ligand-1; PD-1, programmed cell death protein-1; MHC, major histocompatibility complex.

Durvalumab in Advanced Biliary Tract Cancer

Durvalumab is an IgG antibody targeting programmed death-ligand 1 (PD-L1), inhibiting its interaction with PD-1, resulting in disinhibition of cytotoxic T cells.²³ It was evaluated in a small Phase 1 trial enrolling patients with various solid malignancies and demonstrated good tolerability with a disease control rate of 46%.²⁴

Efficacy in Biliary Tract Cancers

Durvalumab was first evaluated in BTC in an open label, single-center, Phase 2 trial conducted in South Korea, which enrolled treatment-naïve patients with unresectable or recurrent BTC.²⁵ Patients enrolled in the trial initially received gemcitabine (1,000 mg/m²) plus cisplatin (25 mg/m²) on day 1 and 8 of a 3-week cycle, and, beginning with cycle 2, would receive gemcitabine plus cisplatin in combination with durvalumab (1,200 mg) and tremelimumab (75 mg). The study was subsequently amended so that patients were randomized to receive gemcitabine and cisplatin plus durvalumab beginning on day 1 of cycle 1, or gemcitabine and cisplatin plus durvalumab and tremelimumab beginning on day 1 of cycle 1. The primary endpoint was an objective response rate (ORR), and ultimately 50% of patients in the chemotherapy followed by chemotherapy with durvalumab and tremelimumab arm, 72% in the chemotherapy plus durvalumab initially arm, and 70% in

the chemotherapy plus durvalumab and tremelimumab initially arm achieved an objective response. Looking at the chemotherapy plus durvalumab initially arm, three of 47 patients achieved a complete response (CR) and 31 achieved a partial response (PR), with a disease control rate (DCR) of 100%. Median PFS (mPFS) in the durvalumab arm was 11.8 months (95% CI = 6.9–16.6 months) and mOS was 20.2 months.

Based on the encouraging results of combination immunotherapy and chemotherapy, the TOPAZ-1 trial was designed, which was a double-blind, placebo-controlled, Phase 3 study that enrolled 685 patients with previously untreated, unresectable or metastatic BTC.²⁶ Patients were randomized to receive gemcitabine (1,000 mg/m²) plus cisplatin (25 mg/m²) on days 1 and 8 in 21-day cycles, with durvalumab (1,500 mg) or placebo on day 1 of each cycle, for up to eight cycles, followed by durvalumab or placebo monotherapy every 4 weeks. The study achieved its primary endpoint of improved overall survival, with mOS of 12.8 months in the durvalumab group versus 11.5 months in the placebo group (HR = 0.80, 95% CI = 0.66–0.97, *p* = 0.021). Additionally, patients in the durvalumab arm manifested a longer mPFS of 7.2 months versus 5.7 months in the placebo arm (HR = 0.75, 95% CI = 0.63–0.89, *p* = 0.001). Response rates were also improved with the addition of durvalumab (27% vs 19%) to chemotherapy, with complete responses seen in 2.1% of the patients receiving durvalumab.

The authors of this study note that, of 333 patients with known microsatellite instability status, only 1.5% had a microsatellite instability-high (MSI-H) tumor, which suggested that the survival benefit seen with the addition of durvalumab was not due to a benefit in only a small subpopulation of patients with MSI-H tumors. In addition, PD-L1 was not a good biomarker that could predict responses or survival benefit. In the subgroup analysis, there was no particular subgroup identified that did not benefit from the combination of immunotherapy and chemotherapy. However, patients with locally advanced disease, extrahepatic disease, and extrahepatic cholangiocarcinoma seem to derive a greater benefit with the addition of durvalumab to chemotherapy.

As a result of TOPAZ-1, durvalumab received FDA approval for treatment of advanced BTC in the first line setting in combination with gemcitabine and cisplatin. Following the trial, a retrospective analysis of patients with advanced BTC in a real world setting demonstrated similar outcome measures when compared to TOPAZ-1.²⁷

The updated analysis of TOPAZ-1 with additional follow-up data was presented at ESMO 2022, which reported a similar OS benefit as initially reported in the primary analysis.²⁸ At 2-years, the OS rate was 23.6% with combination therapy compared to 11.5% with chemotherapy alone. Moreover, a 2-year OS rate of 40.6% was even more remarkable in patients achieving a response to treatment with chemoimmunotherapy. Subgroup analysis by genomic alterations did not identify any particular alteration including KRAS, TP53, CDKN2A, ARID1A, IDH1, and FGFR that would predict a response or lack of benefit to durvalumab treatment.²⁹

Toxicity Profile

In TOPAZ-1, 99.4% of patients in the durvalumab arm experienced an adverse event (AE), with 75.7% experiencing a grade 3 or 4 AE, while 98.8% in the control arm experienced an AE, with 77.8% experiencing a grade 3 or 4 AE.²⁶ The profile of AEs between each arm was similar. Most common AEs in the durvalumab arm included anemia (48.2%), nausea (40.2%), constipation (32.0%), and neutropenia (31.7%). Most common grade 3/4 AEs included anemia (23.7%), neutrophil count decrease (21.0%), neutropenia (20.1%), and platelet count decrease (9.8%). Any grade immune-mediated AEs occurred in 12.7% of patients, with grade 3 or 4 events in 2.4%. The most common immune-mediated AEs of any grade included hypothyroid events (12.7%), dermatitis/rash (3.6%), hepatic events, and adrenal insufficiency (1.2% each). A real-world analysis reported grade 3 or 4 AEs in 35.2%, with immune-related grade 3 or greater AEs in 2.1%, which is lower than rates reported in TOPAZ-1, and may be explained, to some extent, by limitations of retrospective analysis.²⁷ That being said, these results are reassuring that adverse events experienced in a real-world population were not more common or severe than those seen in the initial trial.

Additionally, a subsequent analysis of the TOPAZ-1 trial analyzed time to deterioration via patient reported outcomes using multiple quality-of-life questionnaires.³⁰ The study found that the addition of durvalumab to gemcitabine plus cisplatin did not result in a significant difference in time to deterioration with regards to patient quality-of-life or function. Overall, this demonstrates that the addition of durvalumab was well tolerated.

Financial Implications

Since approval of durvalumab for use in the first line setting, multiple studies have been undertaken to determine the cost efficacy of durvalumab. A study conducted in China found that the addition of durvalumab to gemcitabine plus cisplatin resulted in an incremental cost-effectiveness ratio (ICER) of \$159,644 per quality-adjusted life year (QALY) for patients receiving charity care, and \$696,571/QALY for patients not receiving charity care.³¹ A subsequent analysis of US payers reported an ICER of \$381,864/QALY for those receiving durvalumab with gemcitabine plus cisplatin compared to those receiving gemcitabine plus cisplatin.³² These studies do demonstrate limitations for treatment based on cost, especially in developing countries.

Other Immune Checkpoint Inhibitors in Biliary Tract Cancers

Pembrolizumab

Pembrolizumab, an anti-PD-1 antibody, was first assessed in BTC as monotherapy in patients with advanced BTC that had progressed on first line therapy.³³ Evaluating multiple early phase trials, pembrolizumab monotherapy in the second line setting demonstrated an underwhelming response, with an ORR of 13.0% among 24 patients with PD-L1 expressing tumors in KEYNOTE-028 and an ORR of 5.8% among 104 patients in KEYNOTE-158, which included 58.7% of patients with PD-L1 expression.³³

Subsequently, pembrolizumab was evaluated in combination with gemcitabine and cisplatin in the randomized, double-blind, placebo controlled, phase 3 trial, KEYNOTE-966.³⁴ In this trial, patients with previously untreated, advanced BTC were randomized to receive gemcitabine (1,000 mg/m²) and cisplatin (25 mg/m²) on days 1 and 8 of a 21 day cycle with pembrolizumab (200 mg) or placebo every 3 weeks. After eight cycles, patients could continue pembrolizumab with or without gemcitabine. This study achieved its primary endpoint of improved overall survival, with patients in the pembrolizumab arm manifesting an mOS of 12.7 months versus 10.9 months in the placebo arm (HR = 0.83, 95% CI = 0.72–0.95, $p = 0.0034$). The response rate of 29% was similar in both arms. Rates of grade 3 or 4 adverse events were comparable between the pembrolizumab and placebo arm, at 75% and 70%, respectively.

Based on the results of KEYNOTE-966, pembrolizumab, in combination with gemcitabine and cisplatin, received FDA approval for treatment of locally advanced or unresectable BTC in the first line setting.

Nivolumab

Nivolumab was evaluated in a phase 1 trial conducted in Japan, which enrolled patients with unresectable or recurrent BTC that had progressed on a gemcitabine-based regimen and were assigned to receive nivolumab (240 mg) every 2 weeks, as well as treatment-naïve patients with unresectable or recurrent BTC, who were assigned to receive nivolumab (240 mg) every 2 weeks in combination with gemcitabine (1,000 mg/m²) and cisplatin (25 mg/m²).³⁵ In the cohort of patients receiving nivolumab in combination with chemotherapy, 11 of 30 patients had an objective response, with a mOS of 15.4 months.

Nivolumab was then evaluated in a phase 2, open-label, single arm trial in which patients received gemcitabine (1,000 mg/m²) and cisplatin (25 mg/m²) with nivolumab (3 mg/kg) in 3 week cycles, for up to six cycles, followed by maintenance gemcitabine and nivolumab in patients who had stable disease or a response after 6 weeks.³⁶ Twenty-seven patients were evaluable for response, among which 55.6% had an objective response and 92.6% had disease control.

Nivolumab was subsequently evaluated in BILT-01, which was a multicenter, phase 2 study in which patients with treatment-naïve, advanced BTC were randomized to receive nivolumab (360 mg) on day 1 in combination with gemcitabine (1,000 mg/m²) plus cisplatin (25 mg/m²) on days 1 and 8 of a 21-day cycle for a period of 6 months, followed by nivolumab monotherapy, versus nivolumab (240 mg) every 2 weeks with ipilimumab (1 mg/kg) every 6 weeks until progression or intolerability.³⁷ The primary endpoint of the study was 6-month progression free survival, and patients with the nivolumab plus chemotherapy arm had a 6-month PFS rate of 59.4% while patients in the nivolumab plus ipilimumab arm had a rate of 21.2%. Median OS for the nivolumab plus chemotherapy group was 10.6 months and in the nivolumab plus ipilimumab arm it was 8.2 months. The study authors concluded that this survival was not different than a historical control of patients receiving chemotherapy, although there are limitations to this study design.

Select trials evaluating immunotherapy in BTC are summarized in [Table 1](#).

Table I Select Trials Evaluating Immune Checkpoint Inhibition in Combination with Chemotherapy for Management of BTC

Drug	Trial Name	Study Arm	Control Arm	Trial Phase	Cohort	Patient Number	Primary Endpoint(s)	ORR	mPFS (Months)	HR, 95% CI (mPFS)	p (mPFS)	mOS (Months)	HR, 95% CI (mOS)	p (mOS)
Durvalumab	Oh et al ²⁵	Gemcitabine + cisplatin with durvalumab + tremelimumab beginning cycle 2	N/A	2	Treatment naïve unresectable BTC	30	ORR	50%	12.8	N/A	N/A	15.0	N/A	N/A
		Gemcitabine + cisplatin + durvalumab				47		72%	11.8			20.2		
		Gemcitabine + cisplatin + durvalumab + tremelimumab				47		70%	12.3			18.7		
	TOPAZ-1 ²⁶	Gemcitabine + cisplatin + durvalumab for 8 cycles followed by durvalumab monotherapy	Gemcitabine + cisplatin + placebo for 8 cycles followed by placebo monotherapy	3	Treatment naïve unresectable or metastatic BTC	685	OS	26.7%	7.2 vs 5.7	0.75, 0.63–0.89	0.001	12.8 vs 11.5	0.80, 0.66–0.97	0
Pembrolizumab	KEYNOTE-966 ³⁴	Gemcitabine (no max # of cycles) + cisplatin (max of 8 cycles) + pembrolizumab (max of 35 cycles)	Gemcitabine (no max # of cycles) + cisplatin (max of 8 cycles) + placebo (max of 35 cycles)	3	Treatment naïve unresectable or metastatic BTC	1069	OS	29%	6.5 vs 5.6	0.86, 0.75–1.00	0.023	12.7 vs 10.9	0.83, 0.72–0.95	0
Nivolumab	Feng et al ³⁶	Gemcitabine + cisplatin +nivolumab for 6 cycles followed by gemcitabine + nivolumab	N/A	2	Unresectable or metastatic BTC with progression on prior therapy	32	ORR	55.6%	6.1	N/A	N/A	8.5	N/A	N/A
	BIT-01 ³⁷	Gemcitabine + cisplatin +nivolumab for 6 months followed by nivolumab monotherapy	N/A	2	Treatment naïve unresectable or metastatic BTC	35*	6-month PFS	22.9%	6.6	N/A	N/A	10.6	N/A	N/A
		Nivolumab plus ipilimumab	N/A			33		3.0%	3.9			8.2		

Notes: *75 patients were initially randomized.
Abbreviations: ORR, objective response rate; mPFS, median progression free survival; HR, hazard ratio; 95% CI, 95% confidence interval; mOS, median overall survival; BTC, biliary tract cancer; #, number.

Limitations of Immune Checkpoint Inhibition in Biliary Tract Cancers

The use of immune checkpoint inhibition in BTC does have limitations. First and foremost, it is difficult to predict which patients will respond to immunotherapy, as there is significant heterogeneity in the TME among patients with BTC.^{10,38} Evidence at this point would suggest that those with MSI-H tumors or tumors with high tumor mutation burden (TMB-H) may have better response to immunotherapy, however, these markers may be seen in a minority of patients.^{39–43} In fact, MSI-H and/or deficient mismatch repair (dMMR) may be seen in 2–2.5% of BTCs and TMB-H may be seen in <5% of BTCs.^{43,44} Expression of PD-L1 may be most common, seen in approximately 25% of tumors.⁴³ In TOPAZ-1, in patients with PD-L1 tumor area positivity $\geq 1\%$, those who received durvalumab had numerically longer survival compared to those who received placebo with chemotherapy, although did not achieve statistical significance (HR = 0.79, 95% CI = 0.61–1.00).²⁶ Similarly, in KEYNOTE-966, those with PD-L1 combined positive score ≥ 1 who received pembrolizumab trended towards longer overall survival compared to those who received placebo but, again, did not reach statistical significance (HR = 0.85, 95% CI = 0.72–1.00).³⁴ At this point, more information is needed to determine which patients most benefit from the addition of immunotherapy to treatment.

In addition, the development of resistance to immunotherapy is well recognized, with mechanisms including increased expression of alternative immune checkpoints by the tumor cell.⁴⁵ In TOPAZ-1 and KEYNOTE-966, mPFS was 7.2 and 6.5 months, respectively.^{26,34} This demonstrates a need to better understand methods to prevent the development of resistance.

Lastly, it is important to note that the mOS with the combination of chemotherapy and immunotherapy in TOPAZ-1 and KEYNOTE-966 were very similar.^{26,34} In the TOPAZ-1 trial, patients had to stop chemotherapy after eight cycles and continue with durvalumab monotherapy or placebo. In contrast, KEYNOTE-966 allowed continuation of gemcitabine at the discretion of the treating physician in addition to pembrolizumab or placebo after eight cycles. The results of these two trials suggests that continuation of chemotherapy after eight cycles does not provide additional benefit. The updated analysis from TOPAZ-1 does suggest that almost one of four patients survives 2-years or longer with chemoimmunotherapy, and it is possible that we may observe long-term survival with the addition of durvalumab similar to that seen with immunotherapy in other malignancies. There is a great need to identify which patients will receive greatest benefit with the addition of durvalumab.

Future Directions

As alluded to previously, one of the most important aspects of immune checkpoint inhibition in BTC going forward is identification of which patients will benefit.⁴⁶ As mentioned, dMMR/MSI-H and TMB-H are predictive of response but are only found in a minority of patients. A phase 2 study evaluating nivolumab in treatment refractory BTC found that PD-L1 expression, CD8+ T cell infiltration, and high ratio of CD8+ T cells to regulatory T cells in the TME were predictive of longer PFS in patients receiving nivolumab.⁴⁷ An additional study found that certain somatic mutation profiles may predict response to immunotherapy including TP53 and KRAS co-mutation in CCA, but this was not seen in the TOPAZ-1 trial.^{29,48} Future studies should aim to discover other markers predictive of response, and develop models to determine which patients may benefit most from immunotherapy.

An additional area of interest includes evaluation of immune checkpoint inhibition in combination with targeted therapies.^{49,50} Multiple targets of interest have been identified in BTC, including mutated isocitrate dehydrogenase-1 (mIDH-1), human epidermal growth factor receptor 2 (HER2) amplification/overexpression, and fibroblast growth factor receptor 2 (FGFR2) fusion, among others.^{51–53} A recent study evaluated 22 patients with advanced or metastatic BTC, in which patients would receive gemcitabine, oxaliplatin, and sintilimab (an anti-PD-1 antibody), in combination with lenvatinib (tyrosine kinase inhibitor targeting VEGFR1-3, PDGFR α , FGFR, KIT, and RET) for patients who did not undergo next generation sequencing (NGS) or had no targetable alteration on NGS, or a targeted therapy based on an actionable mutation detected via NGS.^{54,55} Among all enrolled patients, an ORR of 45.5% was observed, with a DCR of 86.4%. When looking at five patients with targetable mutations who received chemo-immunotherapy plus a targeted therapy (targets included IDH2, EGFR, FGFR2, PDGFRA/KIT, and BRCA2), an ORR of 80% was observed with a DCR of 100%. While this study was small, it does demonstrate the importance for further evaluation of combination therapy.

Multiple other early phase studies and retrospective analyses have also shown promise in combination of lenvatinib with immune checkpoint inhibition in the management of BTC.^{56–59}

Dual immune checkpoint inhibition and immunotherapy in combination with radiotherapy is also a point of study. Durvalumab has been evaluated in combination with tremelimumab (anti-CTLA-4 antibody) in multiple small early phase trials, showing tolerability, although with modest response.^{60,61} Radiation therapy has also been shown to induce an immune response and increase expression to tumor antigen, which may be further enhanced by immune checkpoint inhibition.⁶² Ongoing studies as of January 2024 evaluating durvalumab in advanced or metastatic BTC are listed in Table 2.

Table 2 Planned, Recruiting, or Active Trials Listed on Clinicaltrials.gov Evaluating the Role of Durvalumab in Management of Advanced Biliary Tract Cancer as of January 2024

NCT	Phase	Study Population	Intervention	Control	Location
03046862	2	Chemo-naïve patients with advanced BTC	Durvalumab/Tremelimumab with gemcitabine + cisplatin	N/A	South Korea
04781192	1/2	Chemo-refractory advanced BTC	Durvalumab + regorafenib	N/A	USA
05924880	3	Chemo-naïve patients with advanced BTC	Durvalumab + gemcitabine-based chemotherapy followed by durvalumab ± gemcitabine	N/A (single arm study)	China
03482102	2	Advanced or metastatic HCC or BTC without prior immune therapy on second-line or beyond, with a radiotherapy naïve lesion	Durvalumab + tremelimumab + radiation	N/A	USA
04238637	2	Locally advanced or limited metastatic intrahepatic BTC not a candidate for curative intent treatment	Durvalumab + tremelimumab + Y-90 SIRT	N/A	Germany
05935579	2	Treatment-naïve patients with advanced BTC	Durvalumab and lenvatinib ± chemotherapy	N/A	China
04301778	2	Locally advanced, unresectable iCCA	Durvalumab + CSF-1R inhibitor (SNDX-6532) following chemo or radio-embolization	N/A	USA
05222971	2	Advanced BTC with somatic or germline mutation in a DNA damage repair gene who received platinum-based chemotherapy	Maintenance olaparib ± durvalumab	N/A	South Korea
04298008	2	Advanced BTC with prior immunotherapy in the second- or third-line setting	AZD6738 plus durvalumab	N/A	South Korea
03704480	2	Recurrent or metastatic BTC with failure of prior platinum-based chemotherapy	Durvalumab and tremelimumab ± weekly paclitaxel	N/A	France
05771480	3	Treatment naïve advanced or metastatic BTC	8 different combinations of gemcitabine-based chemotherapies with durvalumab	Durvalumab plus gemcitabine-based chemotherapy	USA
05327582	1/2	Unresectable BTC or pancreas cancer in patients who may have received prior treatment	PLENA regimen including durvalumab, lenvatinib, and Nab paclitaxel	N/A	China
04298021	2	Advanced BTC with progression on first-line chemotherapy	AZD6738 plus durvalumab or AZD6738 plus olaparib	N/A	South Korea

(Continued)

Table 2 (Continued).

NCT	Phase	Study Population	Intervention	Control	Location
05451043	2	BTC arm: treatment naïve advanced BTC not amenable to curative intent or local therapy	Gemcitabine with cisplatin plus durvalumab in addition to continuous propranolol (tremelimumab give with cycle 1, and may be repeated at progression)	N/A	Canada
06074029	1/2	Advanced BTC	Develop a predictive model for efficacy of immunotherapy in BTCs	N/A	China
03937830	2	BTC arm: Advanced BTC w/ progression on prior therapy not amenable to curative intent local treatment	Durvalumab, tremelimumab, and bevacizumab or durvalumab, tremelimumab, bevacizumab, and TACE	N/A	USA
03257761	1	BTC arm: Advanced or metastatic CCA or gallbladder carcinoma with progression on at least 1, but no more than 2 prior lines of systemic therapy	Guadecitabine plus durvalumab	N/A	USA
05655949	2	Treatment naïve patients with advanced or metastatic iCCA	Gemcitabine, cisplatin, and durvalumab with Y-90	N/A	USA
04301778	2	Unresectable iCCA who may have received prior treatment	SNDX-6352 plus durvalumab following chemo- or radio-embolization	N/A	USA
03473574	2	Treatment naïve patients with advanced CCA or gallbladder carcinoma	5 arms with various combinations of durvalumab, tremelimumab, gemcitabine, and cisplatin	N/A	Germany
05712356	2	CCA arm: Treatment naïve unresectable or metastatic CCA or gallbladder cancer	LSTAI with durvalumab, gemcitabine, and cisplatin	Placebo plus durvalumab, gemcitabine, and cisplatin	USA

Abbreviations: BTC, biliary tract cancer; iCCA, intrahepatic cholangiocarcinoma.

Due to high rates of recurrence after resection in patients with BTC, there is an increased interest in evaluation of neoadjuvant therapy. The triple chemotherapeutic regimen of gemcitabine, cisplatin, and nab-paclitaxel is being tested in this setting.⁶³ The response rate of 27–30% with chemoimmunotherapy seems similar to this triplet chemotherapeutic regimen and, therefore, chemoimmunotherapy could be considered as a neoadjuvant regimen for patients with BTC who have risk of recurrences or who initially have anatomically unresectable disease. In the TOPAZ-1 trial, patients with locally advanced disease seemed to benefit more with the addition of durvalumab to chemotherapy compared to those with distant metastatic disease, demonstrating the utility of chemoimmunotherapy in earlier stage disease. Durvalumab could also be evaluated in the adjuvant setting to eliminate micrometastatic disease in conjunction with chemotherapy.

Conclusions

Recent evidence has shown survival benefit with the addition of durvalumab, an immune checkpoint inhibitor, to cytotoxic chemotherapy in the management of advanced BTC, altering the treatment paradigm for this malignancy. However, the benefit of immunotherapy has been modest, and demonstrates further need to improve how we treat BTC. It is possible that the addition of immunotherapy may translate to long-term survival in a small proportion of patients. Important going forward will be determining which patient populations receive benefit from immune checkpoint inhibition and how immune checkpoint

inhibitors may work synergistically with targeted therapies, other immune checkpoint inhibitors, or radiotherapy to improve patient outcomes.

Abbreviations

BTC, biliary tract cancer; PD-L1, programmed death ligand-1; CCA, cholangiocarcinoma; GC, gallbladder carcinoma; AC, ampullary carcinoma; OS, overall survival; TME, tumor microenvironment; PD-1, programmed cell death protein 1; CTLA-4, cytotoxic T-lymphocyte associated protein 4; PFS, progression free survival; ICER, incremental cost-effectiveness ratio; QALY, quality-adjusted life year; MSI-H, high microsatellite instability; dMMR, deficient mismatch repair; TMB-H, high tumor mutation burden.

Author Contributions

All authors made a significant contribution to the work reported, whether that is in the conception, study design, execution, acquisition of data, analysis and interpretation, or in all these areas; took part in drafting, revising or critically reviewing the article; gave final approval of the version to be published; have agreed on the journal to which the article has been submitted; and agree to be accountable for all aspects of the work.

Funding

There is no funding to report.

Disclosure

Zhaohui Jin reports advisory board for Novartis, QED therapeutics, Lilly, GlaxoSmithKlein, Daiichi Sankyo/Astra Zeneca, Exelixis, and Elevar Therapeutics. Amit Mahipal reports speakers bureau, advisory board for AstraZeneca; speakers bureau for Exelixis; advisory board for Taiho Oncology and Elevar Therapeutics; and research funding from Pfizer. The authors report no other conflicts of interest in this work.

References

- Baria K, De Toni EN, Yu B, et al. Worldwide incidence and mortality of biliary tract cancer. *Gastro Hep Adv*. 2022;1(4):618–626. doi:10.1016/j.gastha.2022.04.007
- Ellington TD, Momin B, Wilson RJ, et al. Incidence and mortality of cancers of the biliary tract, gallbladder, and liver by sex, age, race/ethnicity, and stage at diagnosis: United States, 2013 to 2017. *Cancer Epidemiol Biomarkers Prev*. 2021;30(9):1607–1614. doi:10.1158/1055-9965.EPI-21-0265
- Jiang Y, Jiang L, Li F, et al. The epidemiological trends of biliary tract cancers in the United States of America. *BMC Gastroenterol*. 2022;22(1):22. doi:10.1186/s12876-022-02094-3
- Tella SH, Wiecezorek M, Hodge D, et al. A glimpse into the future of cholangiocarcinoma: predicting the future incidence based on the current epidemiological data. *J Clin Oncol*. 2023;41(4_suppl):616. doi:10.1200/JCO.2023.41.4_suppl.616
- Valle J, Wasan H, Palmer DH, et al. Cisplatin plus gemcitabine versus gemcitabine for biliary tract cancer. *N Engl J Med*. 2010;362:1273–1281.
- Shroff RT, Guthrie KA, Scott AJ, et al. SWOG 1815: a Phase III randomized trial of gemcitabine, cisplatin, and nab-paclitaxel versus gemcitabine and cisplatin in newly diagnosed, advanced biliary tract cancers. *J Clin Oncol*. 2023;41(4_suppl):LBA490–LBA490. doi:10.1200/JCO.2023.41.4_suppl.LBA490
- marc PJ, Desrame J, Edeline J, et al. Modified FOLFIRINOX Versus CISGEM chemotherapy for patients with advanced biliary tract cancer (PRODIGE 38 AMEBICA): a Randomized Phase II study. *J Clin Oncol*. 2022;40(3):262–271. doi:10.1200/JCO.21.00679
- Finn RS, Qin S, Ikeda M, et al. Atezolizumab plus bevacizumab in unresectable hepatocellular carcinoma. *N Engl J Med*. 2020;382(20):1894–1905. doi:10.1056/NEJMoa1915745
- Abou-Alfa GK, Chan SL, Kudo M, et al. Phase 3 randomized, open-label, multicenter study of tremelimumab (T) and durvalumab (D) as first-line therapy in patients (pts) with unresectable hepatocellular carcinoma (uHCC): HIMALAYA. *J Clin Oncol*. 2022;40(4_suppl):379. doi:10.1200/JCO.2022.40.4_suppl.379
- Greten TF, Schwabe R, Bardeesy N, et al. Immunology and immunotherapy of cholangiocarcinoma. *Nat Rev Gastroenterol Hepatol*. 2023;20(6):349–365. doi:10.1038/s41575-022-00741-4
- Zhou G, Sprengers D, Mancham S, et al. Reduction of immunosuppressive tumor microenvironment in cholangiocarcinoma by ex vivo targeting immune checkpoint molecules. *J Hepatol*. 2019;71(4):753–762. doi:10.1016/j.jhep.2019.05.026
- Llovet JM, Castet F, Heikenwalder M, et al. Immunotherapies for hepatocellular carcinoma. *Nat Rev Clin Oncol*. 2022;19(3):151–172. doi:10.1038/s41571-021-00573-2
- Dunn C, Peppas D, Khanna P, et al. Temporal analysis of early immune responses in patients with acute hepatitis B virus infection. *Gastroenterology*. 2009;137(4):1289–1300. doi:10.1053/j.gastro.2009.06.054
- Dustin LB. Innate and adaptive immune responses in chronic HCV infection. *Curr Drug Targets*. 2017;18(7):826–843. doi:10.2174/1389450116666150825110532

15. Gao M, Huang A, Sun Z, et al. Granulocytic myeloid-derived suppressor cell population increases with the severity of alcoholic liver disease. *J Cell Mol Med*. 2019;23(3):2032–2041. doi:10.1111/jcmm.14109
16. Job S, Rapoud D, Dos Santos A, et al. Identification of four immune subtypes characterized by distinct composition and functions of tumor microenvironment in intrahepatic cholangiocarcinoma. *Hepatology*. 2020;72(3):965–981. doi:10.1002/hep.31092
17. Nakamura H, Arai Y, Totoki Y, et al. Genomic spectra of biliary tract cancer. *Nat Genet*. 2015;47(9):1003–1010. doi:10.1038/ng.3375
18. Sabbatino F, Villani V, Yearley JH, et al. PD-L1 and HLA Class I Antigen Expression and Clinical Course of the Disease in Intrahepatic Cholangiocarcinoma. *Clin Cancer Res*. 2016;22(2):470–478. doi:10.1158/1078-0432.CCR-15-0715
19. Sun D, Ma J, Wang J, et al. Anti-PD-1 therapy combined with chemotherapy in patients with advanced biliary tract cancer. *Cancer Immunol Immunother*. 2019;68(9):1527–1535. doi:10.1007/s00262-019-02386-w
20. Ricci AD, D'alessandro R, Rizzo A, et al. Durvalumab in advanced cholangiocarcinoma: is someone knocking down the door? *Immunotherapy*. 2023;15(7):477–486. doi:10.2217/imt-2022-0301
21. Apetoh L, Ladoire S, Coukos G, et al. Combining immunotherapy and anticancer agents: the right path to achieve cancer cure? *Ann Oncol off J Eur Soc Med Oncol*. 2015;26(9):1813–1823. doi:10.1093/annonc/mdv209
22. Fournier C, Rivera Vargas T, Martin T, et al. Immunotherapeutic properties of chemotherapy. *Curr Opin Pharmacol*. 2017;35:83–88. doi:10.1016/j.coph.2017.05.003
23. Stewart R, Morrow M, Hammond SA, et al. Identification and Characterization of MEDI4736, an Antagonistic Anti-PD-L1 Monoclonal Antibody. *Cancer Immunol Res*. 2015;3(9):1052–1062. doi:10.1158/2326-6066.CIR-14-0191
24. Lutzky J, Antonia SJ, Blake-Haskins A, et al. A phase 1 study of MEDI4736, an anti-PD-L1 antibody, in patients with advanced solid tumors. *J Clin Oncol*. 2014;32(15_suppl):3001. doi:10.1200/jco.2014.32.15_suppl.3001
25. Oh DY, Lee KH, Lee DW, et al. Gemcitabine and cisplatin plus durvalumab with or without tremelimumab in chemotherapy-naïve patients with advanced biliary tract cancer: an open-label, single-centre, phase 2 study. *lancet Gastroenterol Hepatol*. 2022;7(6):522–532. doi:10.1016/S2468-1253(22)00043-7
26. D-Y O, Ruth A, Qin S, et al. Durvalumab plus gemcitabine and cisplatin in advanced biliary tract cancer. *NEJM Evid*. 2022;3:1.
27. Rimini M, Fornaro L, Lonardi S, et al. Durvalumab plus gemcitabine and cisplatin in advanced biliary tract cancer: an early exploratory analysis of real-world data. *Liver Int*. 2023;43(8):1803–1812. doi:10.1111/liv.15641
28. D-Y O, He AR, Qin S, et al. Updated overall survival (OS) from the phase III TOPAZ-1 study of durvalumab (D) or placebo (PBO) plus gemcitabine and cisplatin (+ GC) in patients (pts) with advanced biliary tract cancer (BTC). *Ann Oncol*. 2022;33:S1462–S1463. doi:10.1016/j.annonc.2022.10.114
29. Valle JW, Qin S, Antonuzzo L, et al. Impact of mutation status on efficacy outcomes in TOPAZ-1: a phase III study of durvalumab (D) or placebo (PBO) plus gemcitabine and cisplatin (+GC) in advanced biliary tract cancer (BTC). *Ann Oncol*. 2022;33:S1457. doi:10.1016/j.annonc.2022.10.104
30. Burris III HA, Okusaka T, Vogel A. Patient-reported outcomes for the phase 3 TOPAZ-1 study of durvalumab plus gemcitabine and cisplatin in advanced biliary tract cancer. *J Clin Oncol*. 2022;40(16_suppl):4070. doi:10.1200/JCO.2022.40.16_suppl.4070
31. Zhao Q, Xie R, Zhong W, et al. Cost-effectiveness analysis of adding durvalumab to chemotherapy as first-line treatment for advanced biliary tract cancer based on the TOPAZ-1 trial. *Cost Eff Resour Alloc*. 2023;21(1):21. doi:10.1186/s12962-023-00430-2
32. Ye ZM, Xu Z, Li H, et al. Cost-effectiveness analysis of durvalumab plus chemotherapy as first-line treatment for biliary tract cancer. *Front Public Health*. 2023;11:2.
33. Piha-Paul SA, Oh DY, Ueno M, et al. Efficacy and safety of pembrolizumab for the treatment of advanced biliary cancer: results from the KEYNOTE –158 and KEYNOTE –028 studies. *Int J Cancer*. 2020;147(8):2190–2198. doi:10.1002/ijc.33013
34. Kelley RK, Ueno M, Yoo C, et al. Pembrolizumab in combination with gemcitabine and cisplatin compared with gemcitabine and cisplatin alone for patients with advanced biliary tract cancer (KEYNOTE-966): a randomised, double-blind, placebo-controlled, phase 3 trial. *Lancet*. 2023;401(10391):1853–1865. doi:10.1016/S0140-6736(23)00727-4
35. Ueno M, Ikeda M, Morizane C, et al. Nivolumab alone or in combination with cisplatin plus gemcitabine in Japanese patients with unresectable or recurrent biliary tract cancer: a non-randomised, multicentre, open-label, phase 1 study. *lancet Gastroenterol Hepatol*. 2019;4(8):611–621. doi:10.1016/S2468-1253(19)30086-X
36. Feng K, Liu Y, Zhao Y, et al. Efficacy and biomarker analysis of nivolumab plus gemcitabine and cisplatin in patients with unresectable or metastatic biliary tract cancers: results from a phase II study. *J Immunother Cancer*. 2020;8(1):e000367. doi:10.1136/jitc-2019-000367
37. Sahai V, Griffith KA, Beg MS, et al. A randomized phase 2 trial of nivolumab, gemcitabine, and cisplatin or nivolumab and ipilimumab in previously untreated advanced biliary cancer: biT –01. *Cancer*. 2022;128(19):3523–3530. doi:10.1002/cncr.34394
38. Beri N. Immune checkpoint inhibitors in cholangiocarcinoma. *Immunotherapy*. 2023;15(7):541–551. doi:10.2217/imt-2022-0288
39. Maio M, Ascierto PA, Manzyuk L, et al. Pembrolizumab in microsatellite instability high or mismatch repair deficient cancers: updated analysis from the phase II KEYNOTE-158 study. *Ann Oncol off J Eur Soc Med Oncol*. 2022;33(9):929–938. doi:10.1016/j.annonc.2022.05.519
40. Ahn S, chan LJ, Shin DW, et al. High PD-L1 expression is associated with therapeutic response to pembrolizumab in patients with advanced biliary tract cancer. *Sci Rep*. 2020;10(1):10. doi:10.1038/s41598-019-56089-4
41. Liddell SS, Chakrabarti S, Wintheiser GA, et al. Tumor mutational burden is a potential predictive biomarker for response to immune checkpoint inhibitors in patients with advanced biliary tract cancer. *JCO Precis Oncol*. 2022;6:2.
42. Rizzo A, Ricci AD, Brandi G. PD-L1, TMB, MSI, and other predictors of response to immune checkpoint inhibitors in biliary tract cancer. *Cancers*. 2021;13(3):1–11. doi:10.3390/cancers13030558
43. Frega G, Cossio FP, Banales JM, et al. Lacking immunotherapy biomarkers for biliary tract cancer: a comprehensive systematic literature review and meta-analysis. *Cells*. 2023;12(16):2098. doi:10.3390/cells12162098
44. Weinberg BA, Xiu J, Lindberg MR, et al. Molecular profiling of biliary cancers reveals distinct molecular alterations and potential therapeutic targets. *J Gastrointest Oncol*. 2019;10(4):652–662. doi:10.21037/jgo.2018.08.18
45. Zhou B, Gao Y, Zhang P, et al. Acquired resistance to immune checkpoint blockades: the underlying mechanisms and potential strategies. *Front Immunol*. 2021;12:12.
46. Rizzo A, Ricci AD, Brandi G. Durvalumab: an investigational anti-PD-L1 antibody for the treatment of biliary tract cancer. *Expert Opin Investig Drugs*. 2021;30(4):343–350. doi:10.1080/13543784.2021.1897102

47. Kim DW, Kim Y, Kovari BP, et al. Biomarker analysis from a phase II multi-institutional study of nivolumab in patients with advanced refractory biliary tract cancer. *Eur J Cancer*. 2022;176:171–180. doi:10.1016/j.ejca.2022.09.014
48. Chen X, Wang D, Liu J, et al. Genomic alterations in biliary tract cancer predict prognosis and immunotherapy outcomes. *J Immunother Cancer*. 2021;2:9.
49. Lo JH, Agarwal R, Goff LW, et al. Immunotherapy in biliary tract cancers: current standard-of-care and emerging strategies. *Cancers*. 2023;16(1):15. doi:10.3390/cancers16010015
50. Merters J, Lamarca A. Integrating cytotoxic, targeted and immune therapies for cholangiocarcinoma. *J Hepatol*. 2023;78(3):652–657. doi:10.1016/j.jhep.2022.11.005
51. Storandt MH, Kurniali PC, Mahipal A, et al. Targeted therapies in advanced cholangiocarcinoma. *Life*. 2023;13(10):2066. doi:10.3390/life13102066
52. Zhang W, Shi J, Wang Y, et al. Next-generation sequencing-guided molecular-targeted therapy and immunotherapy for biliary tract cancers. *Cancer Immunol Immunother*. 2021;70(4):1001–1014. doi:10.1007/s00262-020-02745-y
53. Demols A, Bucalau A-M, Mans L. The path to personalized treatment in advanced and metastatic biliary tract cancers: a review of new targeted therapies and immunotherapy. *Curr Opin Oncol*. 2022;34(4):403–411. doi:10.1097/CCO.0000000000000850
54. Dong X, Zhang Z, Zhang Q, et al. Triple therapy in biliary tract cancers: gemOX plus immune checkpoint inhibitor in combination with lenvatinib or NGS-guided targeted therapy. *J Cancer Res Clin Oncol*. 2023;149:1917–1927. doi:10.1007/s00432-022-04166-z
55. Zhang W, Xiang D, Lu C, et al. GemOX plus immune checkpoint inhibitor in combination with lenvatinib or NGS-guided targeted therapy in patients with biliary tract cancers. *J Clin Oncol*. 2022;40(16_suppl):e16133–e16133. doi:10.1200/JCO.2022.40.16_suppl.e16133
56. Zhang Q, Liu X, Wei S, et al. Lenvatinib plus PD-1 inhibitors as first-line treatment in patients with unresectable biliary tract cancer: a single-arm, open-label, phase II study. *Front Oncol*. 2021;3:11.
57. Lin J, Yang X, Long J, et al. Pembrolizumab combined with lenvatinib as non-first-line therapy in patients with refractory biliary tract carcinoma. *Hepatobiliary Surg Nutr*. 2020;9(4):414–424. doi:10.21037/hbsn-20-338
58. Shi C, Li Y, Yang C, et al. Lenvatinib plus programmed cell death protein-1 inhibitor beyond first-line systemic therapy in refractory advanced biliary tract cancer: a real-world retrospective study in China. *Front Immunol*. 2022;2:13.
59. Zhu C, Xue J, Wang Y, et al. Efficacy and safety of lenvatinib combined with PD-1/PD-L1 inhibitors plus Gemox chemotherapy in advanced biliary tract cancer. *Front Immunol*. 2023;2:14.
60. Doki Y, Ueno M, Hsu CH, et al. Tolerability and efficacy of durvalumab, either as monotherapy or in combination with tremelimumab, in patients from Asia with advanced biliary tract, esophageal, or head-and-neck cancer. *Cancer Med*. 2022;11(13):2550–2560. doi:10.1002/cam4.4593
61. Boileve A, Hilmi M, Gougis P, et al. Triplet combination of durvalumab, tremelimumab, and paclitaxel in biliary tract carcinomas: safety run-in results of the randomized IMMUNOBIL PRODIGE 57 phase II trial. *Eur J Cancer*. 2021;143:55–63. doi:10.1016/j.ejca.2020.10.027
62. Elias C, Zeidan YH, Boufferra Y, et al. A phase II single arm study of Nivolumab with stereotactic Ablative radiation Therapy after induction chemotherapy in CHOLangiocarcinoma (NATCHO). *BMC Cancer*. 2022;22(1). doi:10.1186/s12885-022-10373-1
63. Maithel SK, Keilson JM, Cao HST, et al. NEO-GAP: a single-arm, phase II feasibility trial of neoadjuvant gemcitabine, cisplatin, and nab-paclitaxel for resectable, high-risk intrahepatic cholangiocarcinoma. *Ann Surg Oncol*. 2023;30(11):6558–6566. doi:10.1245/s10434-023-13809-5

OncoTargets and Therapy

Dovepress

Publish your work in this journal

OncoTargets and Therapy is an international, peer-reviewed, open access journal focusing on the pathological basis of all cancers, potential targets for therapy and treatment protocols employed to improve the management of cancer patients. The journal also focuses on the impact of management programs and new therapeutic agents and protocols on patient perspectives such as quality of life, adherence and satisfaction. The manuscript management system is completely online and includes a very quick and fair peer-review system, which is all easy to use. Visit <http://www.dovepress.com/testimonials.php> to read real quotes from published authors.

Submit your manuscript here: <https://www.dovepress.com/oncotargets-and-therapy-journal>