

Vedolizumab Safety During Pregnancy and Lactation in a Patient with Ulcerative Colitis: A Case Report

Fernanda Patrícia Jeronymo Pinto ¹, Renata de Medeiros Dutra ¹, Livia Cafundo Almeida ¹,
Marcela Maria Silvino Craveiro ², Julio Pinheiro Baima ¹, Rogerio Saad-Hossne ², Ligia Yukie Sassaki ¹

¹Department of Internal Medicine, São Paulo State University (Unesp), Medical School, Botucatu, São Paulo State, Brazil; ²Department of Surgery, São Paulo State University (Unesp), Medical School, Botucatu, São Paulo State, Brazil

Correspondence: Ligia Yukie Sassaki, Department of Internal Medicine, São Paulo State University (Unesp), Medical School, Botucatu, São Paulo State, 13618-687, Brazil, Tel +551438801171, Email ligia.sassaki@unesp.br

Background: Inflammatory bowel disease (IBD) affects young adults of reproductive age, and questions related to pregnancy and breastfeeding are common in clinical practice. Most medications used to treat IBD are considered safe during pregnancy, except methotrexate and small molecules such as tofacitinib. Despite few studies regarding vedolizumab (VDZ) safety, it appears to be safe during pregnancy. Therefore, this study aimed to report the management of ulcerative colitis in pregnant patient refractory to anti-tumor necrosis factor (TNF) agents using VDZ.

Case Report: A female, 38 years old, with ulcerative colitis was refractory to conventional treatment with mesalazine, sulfasalazine, and azathioprine. She was hospitalized at six weeks of gestation with severe acute colitis requiring the use of infliximab (IFX) to induce remission. She had a spontaneous abortion at nine weeks of gestation after the second dose of IFX. Since there was no endoscopic improvement after six months of IFX treatment, VDZ treatment was initiated. During the VDZ infusion period, the patient discovered that she was pregnant with twins, leading to the discussion of the risks and benefits of continuing the VDZ. The patient presented with disease clinical remission with the use of VDZ, and the babies were born at 34 weeks of gestation without complications. Breastfeeding was also performed without complications.

Conclusion: Continued VDZ medication is safe during pregnancy and breastfeeding, with adverse events similar to anti-TNF therapy.

Keywords: gestation, biological therapy, safety, inflammatory bowel disease

Introduction

Inflammatory bowel disease (IBD) affects young patients, with a peak incidence between the 3rd and 4th decade of life.^{1,2} IBD frequently affects women of childbearing age, which can have implications for and fear during pregnancy.³ Despite some peculiarities with IBD patients, women with IBD have fertility similar to that of the general population, except for patients with active disease or those who underwent ileal pouch-anal anastomosis (IPAA) surgery, whose fertility appears to be lower.⁴

Ulcerative colitis (UC) management during pregnancy is challenging, and awareness of the main side effects of each medication and the risk of medications during pregnancy is of fundamental importance. In general, patients with UC can be treated with 5-ASA derivatives; immunosuppressants such as azathioprine and corticosteroids; immunobiological therapy with anti-tumor necrosis factor (TNF), anti-integrin, or anti-interleukin agents; or with small molecules such as tofacitinib.⁵ The Food and Drug Administration (FDA)⁶ classifies drugs into categories based on their risks to the fetus. According to the FDA, the medications indicated for IBD treatment are classified into: Category B (mesalazine, sulfasalazine, infliximab (IFX), adalimumab, certolizumab, golimumab, vedolizumab (VDZ), and prednisone), Category C (tofacitinib, hydrocortisone, cyclosporine), Category D (azathioprine), and Category X (methotrexate).

There is limited discussion on the use of vedolizumab during pregnancy, but its use appears to be safe.^{7–13} Despite the evidence, more studies are needed to prove the safety of the medication during pregnancy and lactation. Therefore, the objective of this case report was to describe the management of UC in a pregnant patient using VDZ and discuss its safety during pregnancy and lactation.

Case Presentation

Female, 38 years-old, without comorbidities, non-smoker. In 2001, at 17 years of age, the patient experienced bloody liquid diarrhea (approximately 15 episodes per day), abdominal pain, and weight loss. Ileocolonoscopy revealed acute colitis of the colon with a proximal predominance, with lesions suggestive of UC. The patient was treated with sulfasalazine and a clinical response was observed. The patient presented one episodic of disease flare in 2002 treated with corticosteroid.

The patient remained in clinical and endoscopic remission for 3 years. In 2006, the patient developed sulfasalazine-induced hepatitis, and the medication was changed to mesalazine (3.2g/day). Colonoscopy performed on the same year showed endoscopic remission of the disease. In 2017, after 11 years of clinical and endoscopic remission, the patient presented with clinical and endoscopic relapse and treatment with azathioprine 100 mg/day was initiated. However, the medication was suspended after six months owing to gastric intolerance. The patient was lost to follow-up for three years and was sporadically treated with prednisone during UC activity.

In December 2020, the patient was admitted to the hospital's maternity ward as a six-week pregnant woman with bloody liquid diarrhea (10 episodes/day), abdominal pain, fever, and a previous history of miscarriage (6 months before hospital admission). Examination results for *Clostridioides difficile* were negative. Colonoscopy revealed pancolitis with severe endoscopic activity according to the Mayo endoscopic classification 3 (Figure 1). After a shared decision with the patient and an evaluation of the risk-benefit of medications in the first trimester of pregnancy, IFX (5 mg/kg) was chosen. After the first dose of IFX, the patient showed significant clinical improvement and was discharged. She received a second dose of IFX in two weeks, without any complications. Unfortunately, between the second and third IFX doses, the patient experienced a spontaneous abortion at nine weeks of gestation. However, she continued infusions with IFX,

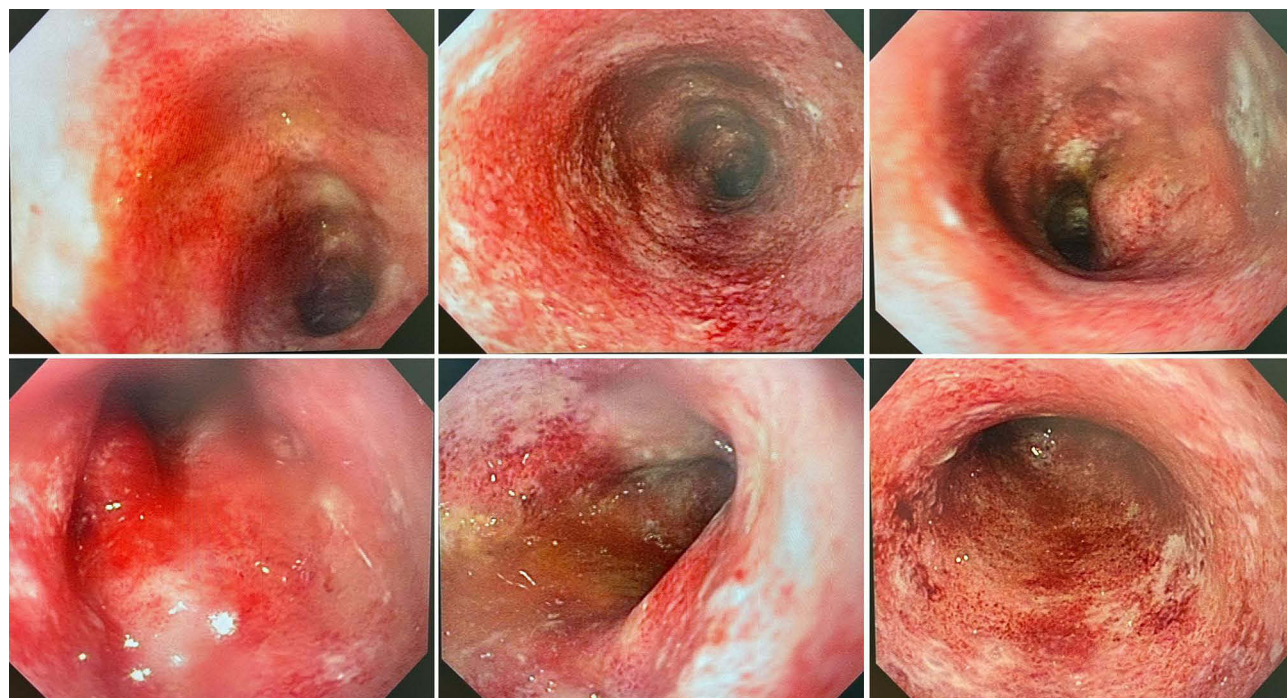


Figure 1 Colonoscopy images showing transverse, descending, sigmoid, and rectum with enanthema, friability, fibrin-covered erosion, and spontaneous bleeding, consistent with colitis in severe endoscopic activity, which is representative of endoscopic Mayo score 3.

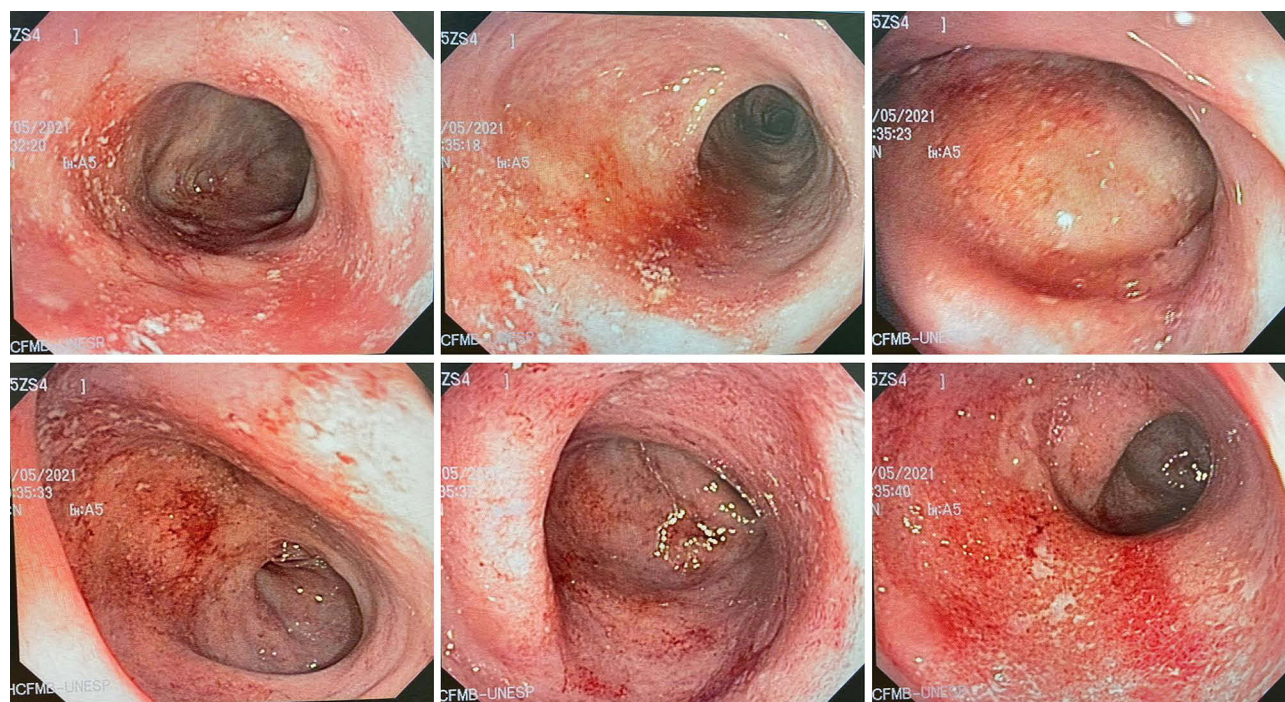


Figure 2 Colonoscopy images showing enanthema, friability, and fibrin-covered erosions throughout the colon, consistent with colitis in moderate activity, which is representative of endoscopic Mayo score 2.

with anti-drug antibody levels at 13.4 AU/mL and serum IFX levels <20 $\mu\text{g/mL}$ at week six, without abnormalities. The patient presented with an acute infusion reaction with a skin rash and itching on the back and abdomen after six months of treatment, with recurrence, even with the use of prophylactic antihistamines. Colonoscopy after six months of treatment revealed UC with endoscopic activity representative of an endoscopic Mayo grade of 2 (Figure 2). Given the lack of endoscopic improvement associated with the infusion reaction, a decision was made together with the patient to exchange IFX for VDZ. Despite instructions to avoid pregnancy during the induction period with VDZ, the patient discovered a pregnancy with identical twins (gestational age, seven weeks, and six days). During pregnancy, the patient presented with clinical remission of UC on maintenance therapy with VDZ without clinical or gestational complications. The patient did not undergo an endoscopic examination during pregnancy. At the end of 2022, she underwent cesarean section at 34 weeks of gestation for the birth of twins without complications. Guidance was provided on starting breastfeeding and maintaining treatment with VDZ, in addition to advice on postponing attenuated vaccines for babies for six months. The patient continued treatment with VDZ in maintenance therapy and in clinical remission of UC, and the babies maintained adequate developmental growth for their age.

Discussion

We reported a case of a pregnant woman with severe colitis, refractory to conventional treatment and IFX, who became pregnant while undergoing induction therapy with VDZ. The patient showed clinical improvement with the treatment and the pregnancy progressed without complications. Here we discuss the impact of the disease on women's fertility, from preconception to breastfeeding, emphasizing the interference of medications on pregnancy.

Women with IBD who want to become pregnant worry about the impact of the disease on their pregnancy and how pregnancy will affect their health. Combined with this factor, there is fear that their children could develop the disease. The hereditary risk of IBD in children is 10.4% when one of the parents has IBD, especially in women with Crohn's disease. This risk increases to 33–36% when both parents are affected by the disease.⁴ According to the IOIBD consensus,¹⁴ patients with IBD should be advised to consider breastfeeding, avoiding the use of antibiotics in the first years of the baby's life and smoking cessation during pregnancy aiming to reduce the risk of IBD in the offspring. All

couples in the fertile period, in which at least one has IBD, must be educated on fertility, pregnancy, and medication safety to promote better outcomes during pregnancy.^{4,7}

The fertility of women with IBD is similar to that of women not affected by IBD.¹³ However, we must highlight two exceptions: women with active IBD appear to have reduced fertility due to reduced levels of anti-Müllerian hormones and those with ileal pouch-anal anastomosis (IPAA) due to deep pelvic dissection, formation of fibrotic tissue, presence of adhesions, and increased post-procedural dyspareunia.^{4,7} Laparoscopic surgery reduces the risk of infertility.⁷ Most medications indicated for IBD treatment do not appear to interfere with fertility, except for sulfasalazine, which can cause reversible oligospermia,⁷ and methotrexate which is teratogenic,⁶ which was not the case of our patient.

IBD activity during the preconception period is the factor most associated with worse clinical outcomes during pregnancy.³ The best time to become pregnant is when the disease is in remission for at least to 3–6 months.⁵ Therefore, it is essential that all women with IBD in their fertile period undergo joint monitoring by gastroenterologists, obstetricians, gynecologists, nutritionists, coloproctologists, and fetal medicine doctors.⁵ During the preconception period, guidance should be provided regarding the need for a Pap smear; updating the vaccination record; quitting smoking; avoiding illicit drugs, alcohol, and opioids; and starting vitamin supplementation, especially folic acid, for individuals using sulfasalazine.^{4,7} In the reported case, the patient was without medical follow-up, in disease activity, which may have contributed to the reported pregnancy losses, highlighting the importance of pre-conception counseling and pregnancy planning.

Therapy with aminosalicylates, biologics, or immunomodulators is considered safe and should be continued during pregnancy and breastfeeding.^{5,7,13} Corticosteroids can be used as adjuvant treatment in patients with IBD activity but should be avoided as maintenance therapy because of the increased risk of preterm pregnancy, low birth weight, and gestational diabetes.⁵ Despite safety recommendations regarding the use of corticosteroids, data from the PIANO registry¹⁵ shows that the use of corticosteroids during pregnancy was associated with the risk of premature birth (OR 1.79, 95% CI, 1.18–2.73), low birth weight (OR 1.76, 95% CI, 1.07–2.88), and admission to an intensive care unit (OR 1.54, 95% CI, 1.03–2.30). Corticosteroid use in the second and/or third trimester of pregnancy is associated with serious infections in babies aged 9–12 months. Furthermore, a higher incidence of orofacial malformations was observed in the group exposed to corticosteroid than the group that was unexposed,¹⁵ but more studies are necessary to confirm these data. Considering the potential adverse events associated with corticosteroid use during pregnancy, anti-TNF agents are preferred for treating active diseases during pregnancy,⁷ as occurred in the case report.

Antibiotics should only be reserved for the treatment of pouchitis or perianal diseases.⁵ Azathioprine therapy during pregnancy is not recommended because of the risk of side effects and the late onset of action of the medication.⁷ Other guidelines include avoiding the use of antidiarrheals, suspending methotrexate three months before pregnancy, and avoiding the use of small molecules such as JAK inhibitors (tofacitinib, filgotinib, upadacitinib) or S1P receptor modulators (ozanimod).^{5,7,16}

Regarding biological therapy, anti-TNF therapy is considered safe during pregnancy, both as a maintenance therapy and to induce remission.^{7,13} Discontinuation of therapy in the third trimester must be individualized and discussed with the patient, and the decision must be based on several factors such as disease activity and severity, time of remission before pregnancy, and gestational age.⁷ Regarding all biologics, the ECCO consensus recommends maintaining therapy until the end of pregnancy for women with active disease just before or during pregnancy or women with difficult-to-treat disease.⁷ Discontinuation is not recommended for patients in disease remission because of the risk of relapse and unfavorable pregnancy outcomes. However, if the patient is in prolonged remission and wishes to discontinue anti-TNF therapy before the third trimester, resuming its administration soon after delivery is recommended.⁷ For pregnant women in remission receiving VDZ or ustekinumab, the decision to maintain or discontinue therapy must be individualized, considering the risk of relapse and limited data on fetal exposure to medications.⁷ Despite few studies, the use of VDZ appears to be safe, both in induction and maintenance therapies.^{7–13} Based on these studies and based on the severity of the disease and previous pregnancy losses, we discuss the risks and benefits of continuing VDZ with our patient. The decision was to continue the medication throughout the pregnancy, with periodic monitoring of maternal and fetal health.

VDZ is a humanized monoclonal antibody that specifically binds to the $\alpha 4\beta 7$ integrin, which is expressed, preferentially, in helper T lymphocytes present in the intestine. By binding to integrin $\alpha 4\beta 7$ on certain lymphocytes,

VDZ inhibits the adhesion of these cells to the mucosal addressin cell adhesion molecule-1 (MAdCAM-1), but not to the vascular cell adhesion molecule-1 (VCAM-1).^{3,12} MAdCAM-1 is mainly expressed in intestinal endothelial cells and plays a critical role in the accommodation of T lymphocytes in gastrointestinal tract tissues.³ Currently, there is still fear among health professionals regarding the use of VDZ during pregnancy due to the small number of studies on this biological therapy, in addition to concerns about the theoretical risk of early miscarriage, since MAdCAM-1 is expressed in the placenta during the first trimester of pregnancy.³

The largest study on VDZ in pregnant women was the CONCEIVE study.¹² The authors compared unfavorable outcomes in pregnancy and in the first year of the child's life between three groups of pregnant women: those exposed to VDZ, those exposed to anti-TNF agents, and women who were not using immunobiological or immunosuppressants. A low risk of adverse events during pregnancy was observed in the three groups studied. The number of miscarriages was similar (excluding patients with disease activity) and the risk of congenital anomalies was low and similar between the groups. No cases of neoplasms were reported during the first year of life, and the risk of infection was not significantly different between groups. This study is a major milestone in the understanding VDZ safety in pregnant women with IBD, as it demonstrated similar outcomes in the use of VDZ during pregnancy in patients with IBD compared with pregnant women using anti-TNF agents or those not exposed to biological therapy.¹²

A sub analysis of the PIANO evaluated 62 patients exposed to VDZ and 43 exposed to ustekinumab compared to the control group, composed by IBD patients not exposed to medications.¹⁷ There was no increase of negative pregnancy outcomes in the medication group. Furthermore, there was no adverse effects among infants between VDZ or ustekinumab-treated patients and the controls, including congenital malformations, need of neonatal intensive care or infections rate.¹⁷

Notably, VDZ has lower serum levels in newborns than in mothers.^{8,18} This contrasts with the higher levels of anti-TNF, suggesting that VDZ undergoes less placental transfer.⁸ Furthermore, serum levels of VDZ were not detected in newborns 15 days postpartum in one study,¹⁹ and in 15 and 16 weeks of age in 12 infants in another observational study,¹⁸ indicating that it was cleared more quickly than anti-TNF drugs. Unfortunately, we do not have commercial kits for measuring VDZ serum levels to be applied in clinical practice, which made it impossible to dose VDZ in the newborn.

Breastfeeding reduces the incidence of respiratory and gastrointestinal infections, asthma, and type 1 diabetes mellitus, in addition to reducing the early development of IBD by up to 30%.⁴ Most medications except for methotrexate, cyclosporine, allopurinol, and tofacitinib,^{4,20} are safe during breastfeeding. However, many women with IBD have concerns about breastfeeding on IBD treatment regime, especially regarding the safety of biological therapy for their children, leading many to avoid unnecessary breastfeeding. Moreover, data on the vaccination of infants exposed to VDZ are scarce. Inactivated viruses are safe for children exposed in utero to biological or non-biological therapy. However, caution should be exercised when administering live viral vaccines to infants exposed in utero to anti-TNF agents (apart from certolizumab, which has minimal placental transfer). For this group, it is recommended to wait 6–12 months for an attenuated viral vaccination.^{4,20} Due to the greater intestinal selectivity of VDZ, vaccination may be safer.⁴ Despite the apparent safety, we chose to recommend starting the vaccination with attenuated vaccines after 6 months of the babies' life.

Conclusions

Despite few studies on the use of VDZ during pregnancy in women with IBD, its use appears to be safe and effective. The risks associated with maintaining biological therapy throughout pregnancy must be considered on a case-by-case basis. Disease activity is the main factor involved in unfavorable pregnancy outcomes such as miscarriage, premature birth, low birth weight, and infections. Therefore, monitoring by a multidisciplinary team comprising gastroenterologists, coloproctologists, obstetricians, pediatricians, nurses, nutritionists, and psychologists is recommended. Future research directions could include larger, multicenter studies or registries to monitor outcomes in infants exposed to VDZ in utero or through breastfeeding.

Data Sharing Statement

The datasets used and/or analyzed during the current study are available from the corresponding author on reasonable request.

Ethics Approval and Informed Consent Statement

The study was approved by the local Research Ethics Committee, Botucatu Medical School (CAAE: 66688522.1.0000.5411). Written informed consent was obtained from the patient for publication of this case report and any accompanying images.

Consent for Publication

Written informed consent was obtained from the patient for publication of this case report and any accompanying images.

Author Contributions

All authors made a significant contribution to the work reported, whether that is in the conception, study design, execution, acquisition of data, analysis and interpretation, or in all these areas; took part in drafting, revising or critically reviewing the article; gave final approval of the version to be published; have agreed on the journal to which the article has been submitted; and agree to be accountable for all aspects of the work.

Funding

This research did not receive any specific grant from funding agencies in the public, commercial, or not-for-profit sectors.

Disclosure

The authors report no conflicts of interest in this work.

References

- Torres J, Mehandru S, Colombel JF, et al. Crohn's disease. *Lancet*. 2017;389:1741–1755. doi:10.1016/S0140-6736
- Ungaro R, Mehandru S, Allen PB, et al. Ulcerative colitis. *Lancet*. 2017;389:1756–1770. doi:10.1016/S0140-6736
- Gisbert JP, Chaparro M. Safety of new biologics (vedolizumab and ustekinumab) and small molecules (Tofacitinib) during pregnancy: a review. *Drugs*. 2020;80(11):1085–1100. PMID: 32562207. doi:10.1007/s40265-020-01346-4
- Laube R, Paramsothy S, Leong RW. Review of pregnancy in Crohn's disease and ulcerative colitis. *Therap Adv Gastroenterol*. 2021;14:17562848211016242. PMID: 34046084; PMCID: PMC8135214. doi:10.1177/17562848211016242
- Mahadevan U, Robinson C, Bernasko N, et al. Inflammatory bowel disease in pregnancy clinical care pathway: a report from the American gastroenterological association IBD parenthood project working group. *Inflamm Bowel Dis*. 2019;25(4):627–641. PMID: 30821832. doi:10.1093/ibd/izz037
- U.S. Food & drug administration. Available from: <https://www.fda.gov/>. Accessed May 15, 2023.
- Torres J, Chaparro M, Julsgaard M, et al. European crohn's and colitis guidelines on sexuality, fertility, pregnancy, and lactation. *J Crohns Colitis*. 2023;17(1):1–27. PMID: 36005814. doi:10.1093/ecco-jcc/jjac115
- Mitrova K, Pipek B, Bortlik M, et al.; Working Group. Safety of ustekinumab and vedolizumab during pregnancy-pregnancy, neonatal, and infant outcome: a prospective multicentre study. *J Crohns Colitis*. 2022;16(12):1808–1815. PMID: 35708729. doi:10.1093/ecco-jcc/jjac086
- Wils P, Seksik P, Stefanescu C, et al. PREGNANCY-GETAID study group. Safety of ustekinumab or vedolizumab in pregnant inflammatory bowel disease patients: a multicentre cohort study. *Aliment Pharmacol Ther*. 2021;53(4):460–470. PMID: 33345331. doi:10.1111/apt.16192
- Chaparro M, Donday MG, Abad-Santos F, et al. The safety of drugs for inflammatory bowel disease during pregnancy and breastfeeding: the DUMBO registry study protocol of GETECCU. *Therap Adv Gastroenterol*. 2021;14:17562848211018097. PMID: 34158835; PMCID: PMC8182220. doi:10.1177/17562848211018097
- Mahadevan U, Long MD, Kane SV, et al. Crohn's colitis foundation clinical research alliance. pregnancy and neonatal outcomes after fetal exposure to biologics and thiopurines among women with inflammatory bowel disease. *Gastroenterology*. 2021;160(4):1131–1139. PMID: 33227283; PMCID: PMC7956164. doi:10.1053/j.gastro.2020.11.038
- Moens A, van der Woude CJ, Julsgaard M, et al. Pregnancy outcomes in inflammatory bowel disease patients treated with vedolizumab, anti-TNF or conventional therapy: results of the European CONCEIVE study. *Aliment Pharmacol Ther*. 2020;51(1):129–138. PMID: 31692017. doi:10.1111/apt.15539
- Nielsen OH, Gubatan JM, Juhl CB, Streett SE, Maxwell C. Biologics for inflammatory bowel disease and their safety in pregnancy: a systematic review and meta-analysis. *Clin Gastroenterol Hepatol*. 2022;20(1):74–87.e3. PMID: 32931960. doi:10.1016/j.cgh.2020.09.021
- Ananthakrishnan AN, Kaplan GG, Bernstein CN, et al.; International Organization for Study of Inflammatory Bowel Diseases. Lifestyle, behaviour, and environmental modification for the management of patients with inflammatory bowel diseases: an International Organization for Study of Inflammatory Bowel Diseases consensus. *Lancet Gastroenterol Hepatol*. 2022;7(7):666–678. PMID: 35487235. doi:10.1016/S2468-1253(22)00021-8

15. Odufalu FD, Long M, Lin K, Mahadevan U. PIANO Investigators from the Crohn's and Colitis Foundation (CCF) Clinical Research Alliance recruited patients for their respective centers for participant enrollment. Exposure to corticosteroids in pregnancy is associated with adverse perinatal outcomes among infants of mothers with inflammatory bowel disease: results from the PIANO registry. *Gut*. 2022;71(9):1766–1772. PMID: 34686575. doi:10.1136/gutjnl-2021-325317
16. Brondfield MN, Mahadevan U. Inflammatory bowel disease in pregnancy and breastfeeding. *Nat Rev Gastroenterol Hepatol*. 2023;20(8):504–523. PMID: 37002407. doi:10.1038/s41575-023-00758-3
17. Chugh R, Long MD, Jiang Y, et al. Maternal and neonatal outcomes in vedolizumab and ustekinumab exposed pregnancies: results from the PIANO registry. *Am J Gastroenterol*. 2023. PMID: 37796648. doi:10.14309/ajg.0000000000002553
18. Flanagan E, Gibson PR, Wright EK, et al. Infliximab, Adalimumab and vedolizumab concentrations across pregnancy and vedolizumab concentrations in infants following intrauterine exposure. *Aliment Pharmacol Ther*. 2020;52(10):1551–1562. PMID: 32981127. doi:10.1111/apt.16102
19. Laube R, Paramsothy S, Leong RW. Use of medications during pregnancy and breastfeeding for Crohn's disease and ulcerative colitis. *Expert Opin Drug Saf*. 2021;20(3):275–292. PMID: 33412078. doi:10.1080/14740338.2021.1873948
20. Shmidt E, Dubinsky MC. Inflammatory bowel disease and pregnancy. *Am J Gastroenterol*. 2022;117(10S):60–68. PMID: 36194035. doi:10.14309/ajg.0000000000001963

Clinical and Experimental Gastroenterology

Dovepress

Publish your work in this journal

Clinical and Experimental Gastroenterology is an international, peer-reviewed, open access, online journal publishing original research, reports, editorials, reviews and commentaries on all aspects of gastroenterology in the clinic and laboratory. This journal is indexed on American Chemical Society's Chemical Abstracts Service (CAS). The manuscript management system is completely online and includes a very quick and fair peer-review system, which is all easy to use. Visit <http://www.dovepress.com/testimonials.php> to read real quotes from published authors.

Submit your manuscript here: <https://www.dovepress.com/clinical-and-experimental-gastroenterology-journal>