


Modification of Ertl Operation for Short Stump

Viktor Ivanovych Shevchuk , Yurii Bezsmertnyi, Olexander Yuriyovych Bezsmertnyi, Olexander Yuriyovych Branitsky

Scientific Department, Scientific and Research Institute of Rehabilitation of National Pirogov Memorial Medical University, Vinnytsia, Ukraine

Correspondence: Viktor Ivanovych Shevchuk, Email shevchukndiri@gmail.com

Background: Despite a sufficient number of papers on the technique of transtibial amputations, the technique of Ertl-type reamputation in short tibial stump remains unreported.

Aim: To propose a modification of the Ertl operation in the proximal tibia.

Case Presentation: The technique of bone bridge creation in a patient with a malformed stump in the upper third of the tibia at the expense of the regenerate formed after corticotomy of the tibial remnant and dosed distraction of the graft by the Ilizarov apparatus is described. Radiological, ultrasound and MRI methods were used to control the regenerate. The follow-up period was 36 months. At 3.5 months, a synostosis was formed, which allowed primary and then permanent prosthesis with a full-contact prosthesis. At 36 months, the organotypic remodelling of the regenerate was completed. The patient works, uses the prosthesis for 15–16 hours a day, and walks on average 8–10 km.

Conclusion: The use of the proposed method makes it possible to obtain tibial synostosis without their shortening with elimination of valgus deviation of the fibula stump and the possibility of early functional loading. Synostosis formation occurs within 3.5 months after surgery. Organotypic bone remodelling occurs during primary and then permanent prosthetics. The formed bone bridge has a large support area, which is maintained during the whole follow-up period of 36 months and allows to perform full-contact prosthetics with maximum load on the residual limb end.

Keywords: Ertl reamputation, distraction, regeneration, prosthesis

Introduction

Transtibial amputations allow you to get a stump, providing the maximum possible restoration of the function of the lost limb. This is especially true for young and middle-aged people. Depending on the pathology, the nature of tissue damage, the surgeon's qualification and the possibilities of technical support, modified methods of Burgess and Ertl are used for stump formation.^{1–3} Myoplastic amputation according to Burgess is technically simpler and more frequently used. In some cases, it fails to prevent balloting and valgus deviation of the fibula, peroneal nerve irritation, soft tissue compression by the end surface of the bones,^{3,4} and full-contact prosthesis.^{2,3,5} Ertl-type osteomyoplasty is technically more complex. Initially, its essence was to form a tibial synostosis by means of an osseous periosteal tube from the tibia fixed to the fibula.³ Due to the technical complexity,⁴ they modified the operation by using a whole graft from the fibula to be removed on a muscular pedicle, placing it between the truncated bones and fixing it with sutures. Other authors⁶ used a graft from the tibia. Cortical screws, tensioned rope, Arthren cord, nonabsorbable suture, and Ilizarov apparatus were used for graft fixation.^{6,7} The advantages of the Ertl operation include prevention of peroneal residual limb balloting and peroneal nerve irritation, creation of a wide stable platform with an increased possibility of residual limb loading, significant peak hip power, control of rotational movements in the prosthesis, and a higher probability of return to work.^{8–11} Given a certain technical complexity, most authors point to the expediency of performing these operations in reconstructions in specialised clinics. The disadvantages of the operation are the probability of graft displacement, non-union, suppuration.^{12–15} A number of researchers^{16,17} pay attention to the impossibility of performing the Ertl operation in the proximal third of the tibia due to the necessity of significant shortening of the bone arm of the residual limb. To eliminate this disadvantage, we have developed an operation of bone bridge formation without bone shortening.

The functionality of the stump depends on its shape, the condition of the surrounding truncus muscles, and the nature of the relationship between the bone stump and the surrounding soft tissues. Unfortunately, this functionality is not always achievable due to improper sleeve fit and pressure distribution at the interface between the sleeve and residual limb.^{18,19} Uneven pressure on the residual limb causes pain and tissue damage, pistoning and cyclic “displacement”. In this regard, the research of the authors,¹⁸ who designed a replaceable pneumatic reconfigured socket for the tibial stump, which positively affects both the functional capabilities of the stump and the mechanical abilities of the soft tissues¹⁹ and the distribution of pressure between the stump and the socket, is of considerable interest.

Case Presentation

A 36-year-old patient came to the hospital with complaints of inability to use a prosthesis due to pain on the outer surface of the right tibia stump and ulcerations on the end and in the area of the tibial crest. The primary amputation due to a mine blast wound was performed 5 months before the patient’s visit to our clinic. After wound healing, a primary prosthesis was performed.

Objective status: moderately tapered stump of the right tibia in the proximal third. Movement in the knee joint in full. The anterior and partially end surfaces are covered with extensive ulcerating scars fused to the bone. The tibial ends are contoured under the skin, which is retracted between them. The tibial crest protrudes sharply beneath the scar. The fibula is excessively mobile in the frontal and sagittal planes with an amplitude of 4–4.6 cm. There is a bursa of doughy consistency on the external-posterior surface under its end. At percussion in the area of peroneal nerve projection, pain intensification and paresthesias. The muscles of the anterior and posterior groups are of sufficient length, fused into the skin. The posterior skin flap is in good condition, sagging in the dorsal direction. Radiographs show moderate osteoporosis of the tibia and fibula, valgus deviation of the fibula remnant. Bone closure plates on the end surface of the bones are not formed.

Due to the impossibility of shortening the bone arm of the residual limb, we developed a reconstructive operation to form a synostosis, which involves the formation of a bone bridge using a distraction regenerate formed after L-shaped corticotomy of the tibial remnant and dosed distraction of the resulting non-free bone graft to fill the interosseous gap. The scheme of the operation is shown in Figure 1.

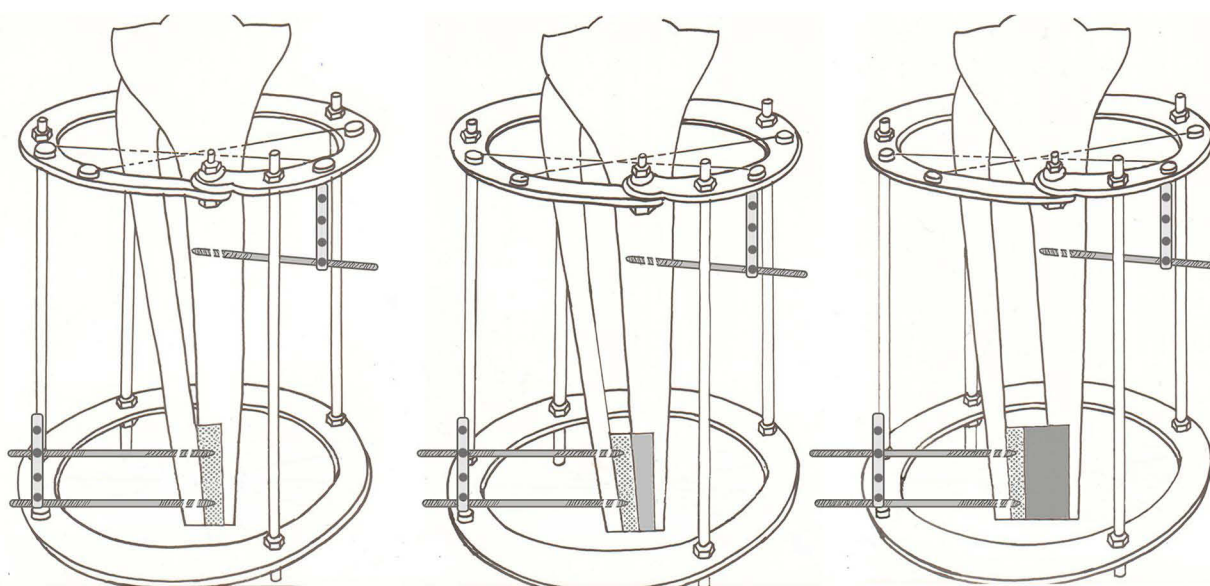


Figure 1 Schematic diagram of the operation.

Surgical Technique

The surgery was carried out under general anesthesia. The surgical site was processed twice with betadine solution. In the proximal metaepiphysis of the tibia and fibula perpendicular to the axis of the limb, without stitching the muscles and considering the passage of the peroneal nerve, a pair of crossed needles and a 5.5 mm self-tapping rod were inserted 4 cm below in the sagittal plane perpendicular to the planum tibia. The spokes and rod were fixed in the Ilizarov apparatus ring. Thus, the proximal base of the apparatus was formed. Flap incision of the skin, subcutaneous tissue, fascia with excision of the old scar. The stumps of the tibia and fibula were isolated. Vascular ligation. The tibial, superficial and deep peroneal, and posterior cutaneous nerves were identified and shortened. The tibial crest was cut down. The intertidal area was separated. At a distance of 5 cm from the end of the tibial stump, an L-shaped incision of the periosteum was made along its posterior-external surface. The latter was displaced 0.2 cm proximally. A transverse cut of the tibia up to half its diameter was made with an oscillating saw. A sharp chisel was used to make a flap of the future graft from the end without penetrating the bone marrow canal. Two self-tapping rods d 3.5 mm were passed through the distal end of the fibula and the cortical layer of the tibia graft in parallel at a distance of 2 cm from each other, which were fixed in the apparatus ring. Compression between the maternal bone of the graft and the fibula. After receiving the regenerate of the planned width, the apparatus was set for fixation for 2 months. Examinations by X-ray. The rings of the Ilizarov apparatus were connected by threaded rods. Muscle plastic surgery with fixation of the tibialis anterior and calf muscles to the bone. Layered wound closure. Drainage.

Compression of the detached graft with the maternal bone was performed for 4 days. Distraction began on the 5th day after surgery at a rate of 1 mm per day (0.25 mm in 4 steps) and continued for 36 days. After obtaining the regenerate of the planned width, the device was placed for fixation for 2 months. The sutures were removed on the 10th day. The condition of tissues at the entry and exit points of the spokes and rods was monitored daily for the first 10 days, and subsequently - as indicated. To ensure the possibility of early functional loading on the residual limb, an artificial foot was attached to the Ilizarov apparatus on external rods (Figure 2). The patient was allowed to stand and walk on the 4th day after surgery.

Polyposition radiography was performed once every 10–14 days in the period of distraction and once a month in the period of fixation. The radiographs were used to determine the osteotomy consistency, the amount of interfragmental diastasis, the nature of the course of osteogenesis, and dynamic structural changes, including the degree of organotypic rearrangement of the bone regenerate during fixation.

Ultrasound examinations were performed on a VOLUSON-730 PRO (Austria) using linear and convex transducers at 7.5 MHz. The state of the regenerate, the nature of diastasis, the homogeneity of the echogenic substrate, the presence of endosteal and periosteal bone formation and hypoechogenic areas were visually assessed. The echoplasticity index (PEEK integumentary unit) was determined in sersoscale mode. The intact area of the proximal tibia of a healthy limb was taken as a control. The presence of vessels in the distraction zone and in the surrounding soft tissues was assessed in the colour Doppler mapping and energy Doppler modes.

MRI study was performed on a MAGNETOM Symphony syngo MR Siemens (Germany) magnetic resonance tomograph with a magnetic field strength of 1.5 Tc with postprocessing of the obtained data on the Leonardo expert class multimodal station. Three planes were used (axial, frontal, sagittal), slice thickness 3–4 mm, interval between slices 5 mm. The cross-sectional area of the tibial and fibula stumps before surgery, the cross-sectional area of the bone residual limb after removal of the device and 36 months after surgery were studied.

Results

X-ray examination on the 7th day of distraction (11th day after surgery) revealed bone trabeculae in the diastasis, directed along the course of fragment displacement. On the 14th day of distraction on control radiographs the size of the regenerate corresponded to the pace and rhythm of distraction. There were cloud-like shadows of medium intensity over the entire area of the regenerate. After 36 days of distraction, the planned regenerate size was achieved. The apparatus was transferred to fixation. Radiologically, the interfragmentary diastasis (3.6 cm) was filled with a normoplastic type regenerate. After 1 month of fixation (day 71 after surgery), homogeneous shadows of high intensity were determined radiologically. A continuous cortical lamina began to form along the posterior surface. A bone callus was determined at

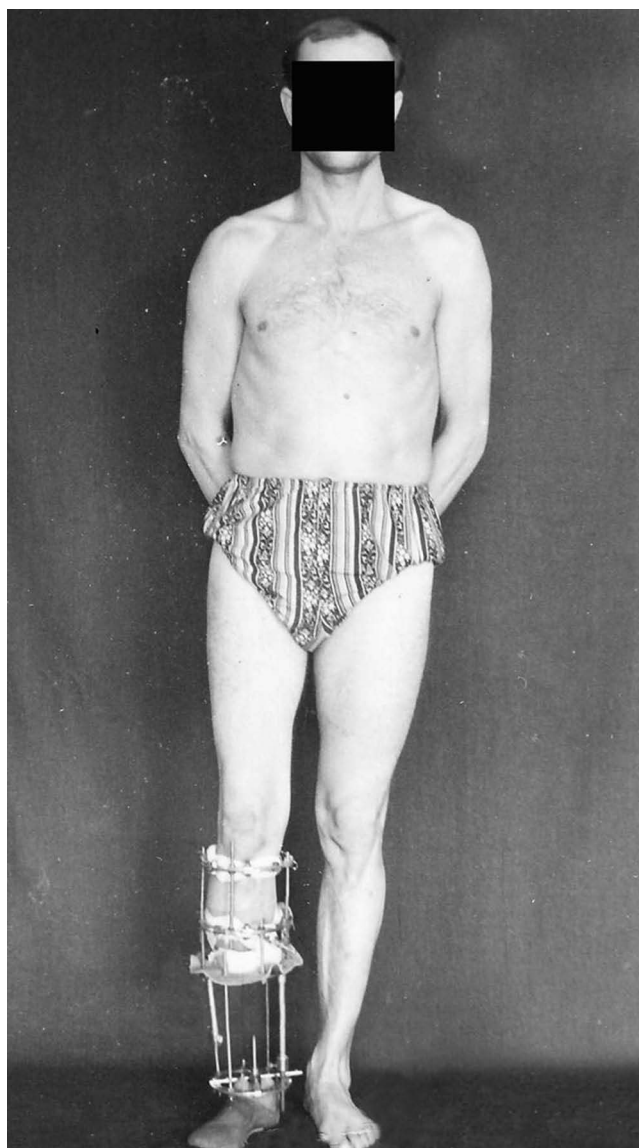


Figure 2 Patient with functional load device (15.02.2020).

the place of contact of the graft with the fibula. After 2 months of fixation before the apparatus removal the regenerate had a homogeneous structure (Figure 3). In terms of density, it approached the adjacent areas of the mother bone. Osteoporosis of the residual limb bones did not progress.

During standard mode scanning, early appearance of linear hyperechogenic structures in the area of diastasis, pronounced endosteal reaction, accelerated narrowing of the echopositive zone of the regenerate within 30 days, formation of hyperechogenic fragments along the edge of the parent bone, and decreased ultrasound penetration depth were characteristic. Areas with different osteogenesis activity (echo density index from 135 to 148 units) were determined in the distraction zone. Scanning of the regenerate in different modes revealed single vessels in soft tissues at the beginning of distraction. By the end of distraction, vessels with a diameter of 0.09 to 0.16 cm were visualised in the intermedial zone of the regenerate. After 60 days of fixation, polyposition scanning and 3D reconstruction scans in all scanned planes revealed a continuous contour of the cortical plate and separate areas of vessels localised in the intermedial zone of the regenerate. When the sound conductivity of the regenerate was preserved, vessels with a diameter of 0.15–0.26 cm with peripheral indices $PJ=3.4$ and $PJ=1.7$ were visualised between the newly formed

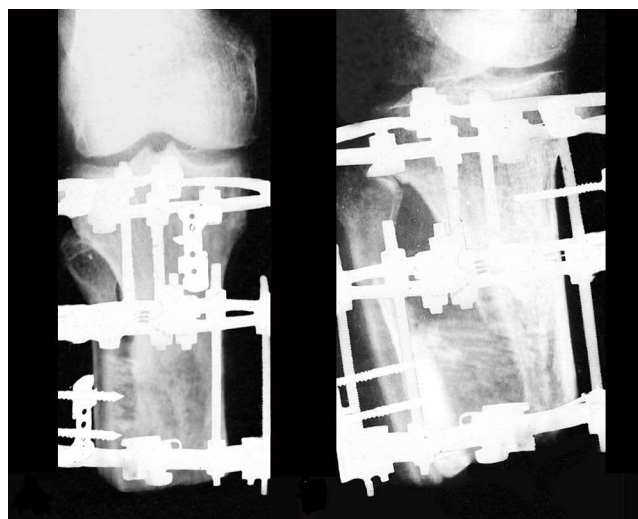


Figure 3 Radiographs of the residual limb in 2 projections 3 months after surgery (17.05.2020).

bone trabeculae, which corresponded to sufficient maturity of the regenerate and pronounced vascularisation and indicated primary angiogenic osteogenesis.

The preoperative cross-sectional area of the tibia and fibula was 5.012 and 1.235 cm², respectively, according to MRI data. At 3 months after surgery, the cross-sectional area of the bones together with the synostosis was 15.268 cm², and at 36 months – 15.485 cm². A primary prosthesis was fabricated after removal of the appliance and a permanent prosthesis was fabricated 8 months later. At the follow-up examination after 36 months, the organotypic remodelling of the regenerate, detached flap and parent bone was completed (Figure 4).

Maximum load on the residual limb end, full contact between the residual limb and the prosthesis socket, free rotation of the knee joint and no pain syndrome are noted. The prosthesis quality index – The Locomotor Capabilities Index (LCI) as part of the Prosthetic Profile of the Amputee questionnaire (Canada, 1993) – before the operation was 24, and 3 years after the operation and re-prosthetics, its value amounted to 55. The patient uses the half limb without additional support for 15–16 hours a day. He works as a railway station attendant. He walks an average of 8–10 kilometres per day.

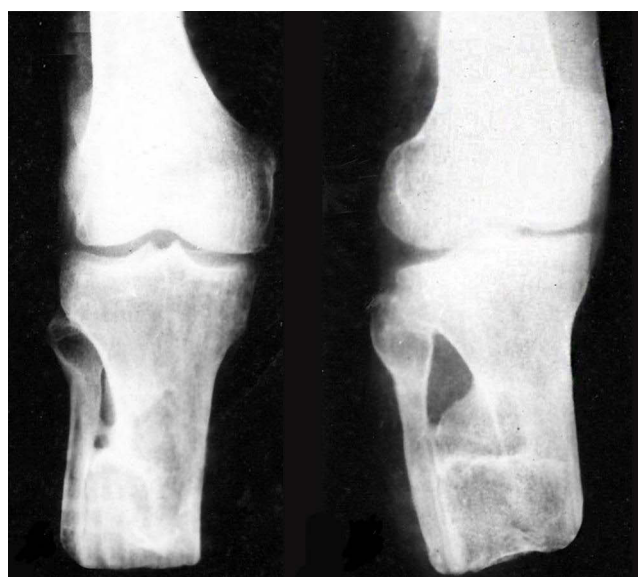

Figure 4 Radiographs of the residual limb 3 years after amputation (20.05.2023).

Discussion

The disadvantage of the well-known modifications of the Ertl operation is the need for significant shortening of the bony vagel. Therefore, they are used in primary amputations. In the presence of a short tibia stump, this operation is not feasible because it requires shortening not only of the bony lever, but also the presence of soft tissue reserve. In addition, the use of screws, ropes, Arthren cord for graft fixation is fraught with complications (danger of graft displacement, non-union, suppuration) and requires repeated surgery for their removal. The suggestion of synostosis of the lower leg bones due to a shaped graft from the tibia with fixation by the Ilizarov apparatus also requires shortening of the bone arm.

The advantage of the proposed modification of Ertl's operation is the possibility of preserving the existing length of the stump, to get synostosis of the tibia stump bones without shortening the bone lever, eliminating valgus deviation of the fibula, increasing the area of the supporting surface, and the possibility of using a full-contact prosthesis with maximum load on the stump end.

The proposed method is developed on the basis of the regularity of tissues revealed by Ilizarov²⁰ to respond to the tensile stress arising in them by growth and regeneration. In contrast to the tibialisation²¹ previously used to replace the tibial defect, in our case the task was to obtain a transversely oriented regenerate after longitudinal dissection of the tibial stump, which had not been performed before. In order to shorten the period of graft fusion with the fibula, the latter was brought and pressed to the graft during the operation. Distraction of the graft was carried out in conditions of its close fixation to the inner surface of the fibula. As a result, by the end of distraction a bone callus was formed between the graft and the fibula. The interosseous gap was filled with the distraction regenerate and the displaced non-free graft undergoing further organotypic rearrangement.

The source of regenerate growth is osteogenic elements of the periosteum and endosteum of the parent bone and the displaced fragment.²² According to the data,²¹ the middle part of the regenerate contains the growth zone of the distraction regenerate, which provides active osteogenesis during the entire period of distraction and gradually ossifies during the fixation period. Transversely oriented collagen fibres were formed in the middle part of the regenerate growth zone, on the basis of which osteoid, osteoid-bone and bone beams were formed. By 30 days of fixation (70 days after surgery), the formation of a moderately pronounced cortical plate of the regenerate was already observed. Increasing tension during distraction led to periosteal detachment and stimulation of osteogenesis. Rapid periosteal bone formation developed, contributing to the thickening of the regenerate and bone stump.

By the end of the distraction period, the bone sections of the regenerate coming from the mother bed and the fragment became equal in width. Modelling of the vascular network of the distraction regenerate identical to the blood supply of the adjacent bone fragments was revealed by the end of the two-month fixation period. Similar data were obtained for limb segment lengthening.^{22–24}

Specialists are aware of the rapid development of osteoporosis of the bone stump.²⁵ This is caused by impaired blood circulation and, consequently, osteogenesis, as well as lack of loading. Therefore, when performing osteotomy and other manipulations, maximum sparing of the periosteum and bone marrow was sought. Taking into account the previous studies,^{26,27} indicating the maximum jump in the level of metabolic processes and mineralisation under loading during a month, we used dosed functional loading from the 4th day after surgery by fixing the semi-finished foot to the structure of the Ilizarov apparatus. This explains insignificant progression of osteoporosis and rapid mineralisation of the newly formed bone. A significant, almost 3-fold increase in the area of bone filing is important for prosthetics.

The inclusion criteria are a defective short tibial stump of traumatic genesis with or without valgus deviation of the fibula, age 18–60 years.

Limitations to the operation include stumps after amputation due to thrombotic vascular disease, pustular skin inflammation, insufficient mastery of the external fixation apparatus, a somewhat long period of time to obtain synostosis, and the need for skin care near the stumps.

Conclusions

The use of the proposed method makes it possible to obtain tibial synostosis without shortening them, eliminating valgus deviation of the fibula stump and the possibility of early functional loading.

Synostosis formation occurs within 3.5 months after surgery. Organotypic bone remodelling occurs during primary and then permanent prosthetics. The formed bone bridge has a large support area, which is maintained during the entire follow-up period of 36 months and allows full-contact prosthetics with maximum load on the residual limb end.

Ethics Approval

The authors declare that no human or animal experiments were conducted as part of this study.

Consent for Publication

Written informed consent was provided by the patient to have the case details and any accompanying images published. Institutional permission was not required to publish details of the case.

Author Contributions

All authors made a significant contribution to the work reported, whether that is in the conception, study design, execution, acquisition of data, analysis and interpretation, or in all these areas; took part in drafting, revising or critically reviewing the article; gave final approval of the version to be published; have agreed on the journal to which the article has been submitted; and agree to be accountable for all aspects of the work.

Funding

The authors did not receive support from any organization for the submitted paper. The study was conducted within the framework of the research work «To develop reconstructive and restorative operations on lower limb residual limb stumps after amputations as a result of mine blast injuries» (registration number 0123U100169), funded by the Ministry of Health of Ukraine with the state budget.

Disclosure

The authors report no conflicts of interest in this work.

References

- Burgess EM, Romano RL, Zettl JH, Schrock RD Jr. Amputations of the leg for peripheral vascular insufficiency. *J Bone Joint Surg Am.* 1971;53(5):874–890. [PMID: 4934074]. doi:10.2106/00004623-197153050-00003
- Taylor BC, Poka A. Osteomyoplastic transtibial amputation: the Ertl technique. *J Am Acad Orthop Surg.* 2016;24(4):259–265. PMID: 26881327. doi:10.5435/JAAOS-D-15-00026.
- Felder JM 3rd, Skladman R. Translating technique into outcomes in amputation surgeries. *Mo Med.* 2021;118(2):141–146. [PMID: 33840857; PMID: PMC8029626]. doi:10.1016/j.apmr.2007.11.005
- Pinzur MS, Beck J, Himes R, Callaci J. Distal tibiofibular bone-bridging in transtibial amputation. *J Bone Joint Surg Am.* 2008;90(12):2682–2687. PMID: 19047714; PMID: PMC3076214. doi:10.2106/JBJS.G.01593.
- Chang BL, Kleiber GM. Evolution of amputee care. *Orthop Surg.* 2023;12:1–14. ISSN 2666-769X. doi:10.1016/j.orthop.2023.05.001.
- Shevchuk VI, Bezsmertnyi YO, Jiang Y, Bezsmertna HV, Dovgalyuk TV. Reamputation stumps below knee. *Med Glas.* 2021;18(2):479–486. doi:10.17392/1374-21
- Bosse MJ, Morshed S, Reider L, et al.;METRC. Transtibial amputation outcomes study (TAOS): comparing transtibial amputation with and without a tibiofibular synostosis (Ertl) procedure. *J Orthop Trauma.* 2017;31(Suppl 1):S63–S69. PMID: 28323804. doi:10.1097/BOT.0000000000000791
- Keeling JJ, Shawen SB, Forsberg JA, et al. Comparison of functional outcomes following bridge synostosis with non-bone-bridging transtibial combat-related amputations. *J Bone Joint Surg Am.* 2013;95(10):888–893. PMID: 23677355. doi:10.2106/JBJS.L.00423.
- Firth GB, Masquijo JJ, Kontio K. Transtibial Ertl amputation for children and adolescents: a case series and literature review. *J Child Orthop.* 2011;5(5):357–362. PMID: 23024727; PMID: PMC3179536. doi:10.1007/s11832-011-0364-0.
- Ferris AE, Christiansen CL, Heise GD, Hahn D, Smith JD. Biomechanical analysis of curb ascent in persons with Ertl and non-Ertl transtibial amputations. *Prosthet Orthot Int.* 2020;44(1):36–43. PMID: 31713462.0. doi:10.1177/0309364619885717.
- Attinger C, Kleiber G. BKA with TMR are changing the options in limb salvage. In: Hong JP, Suh H, editors. *Diabetic Foot Reconstruction*. Singapore: Springer; 2022. doi:10.1007/978-981-16-9816-3_10.
- Nizamli FM. Quality of life among Syrian patients with war-related lower limb amputation at the military hospital in Lattakia. *Int J Nurs Sci.* 2020;7(3):297–302. PMID: 32817852; PMID: PMC7424144. doi:10.1016/j.ijnss.2020.05.001.
- Song H, Israel EA, Gutierrez-Arango S, et al. Agonist-antagonist muscle strain in the residual limb preserves motor control and perception after amputation. *Commun Med.* 2022;2(1):97. doi:10.1038/s43856-022-00162-z
- Godwin Y, Almaqadma A, Abukhoussa H, Obaid M. Stump-plasty: an operation born of necessity in Gaza. *Strateg Trauma Limb Reconstr.* 2021;16(2):102–109. PMID: 34804226; PMID: PMC8578240. doi:10.5005/jp-journals-10080-1526.

15. Ihmels WD, Miller RH, Esposito ER. Residual limb strength and functional performance measures in individuals with unilateral transtibial amputation. *Gait Posture*. 2022;97:159–164. PMID: 35961133. doi:10.1016/j.gaitpost.2022.07.257.
16. Gordon W, Balsamo L, Talbot M, et al. Amputation: evaluation and treatment. *Mil Med*. 2018;183(suppl_2):112–114. PMID: 30189055. doi:10.1093/milmed/usy075.
17. Esfandiari E, Yavari A, Karimi A, Masoumi M, Soroush M, Saeedi H. Long-term symptoms and function after war-related lower limb amputation: a national cross-sectional study. *Acta Orthop Traumatol Turc*. 2018;52(5):348–351. PMID: 30082112; PMCID: PMC6205055. doi:10.1016/j.aott.2017.04.004.
18. Mollae S, Fuentes-Aguilar RQ, Huegel JC, Budgett DM, Taberner AJ, Nielsen PMF. A pneumatic reconfigurable socket for transtibial amputees. *Int J Numer Method Biomed Eng*. 2024;40(2):e3801. PMID: 38185908. doi:10.1002/cnm.3801.
19. Mirjavadi SS, Taberner AJ, Nash MP, Nielsen PMF. Characterising the soft tissue mechanical properties of the lower limb of a below-knee amputee: a review. In: Miller K, Wittek A, Nash M, Pmf N, editors. *Computational Biomechanics for Medicine*. Cham: Springer; 2021. doi:10.1007/978-3-030-70123-9_8.
20. Shevtsov VI. The contribution of G.A. Ilizarov and the school created by him into the development of transosseous osteosynthesis method. *Genius of Orthop*. 2011;2:12–19.
21. Martel CAY II. Transposition of fibula fragments according to the Ilizarov method in the rehabilitation of the injured persons with “acute” diaphyseal tibial defects. *Genius of Orthop*. 2012;1:5–10.
22. Larionov A, Smotrova LA. Vascularisation of the tibia at the defect replacement by Ilizarov’s fragment extension (experimental study). *Orthop Traumatol Prosthet*. 1990;10:25–32.
23. Barabash A, Petrovskaya N, Bahlikov Y. Thickening of the tibia diaphysis by Ilizarov in conditions of preservation of the intraosseous vascular network. Theoretical and clinical aspects of distraction osteosynthesis: Proceedings of the Sverdlov Research Institute of Osteosynthesis. Leningrad. 1982. 24–28.
24. Possibilities of percutaneous osteosynthesis according to Ilizarov in elimination of shortening in adults and children. Experimental-theoretical and clinical aspects of the method of percutaneous osteosynthesis being developed in KNIIEKOT: Proceedings of the All-Union symposium with participation of foreign specialists. Kurgan, 1984. 177–181.
25. Baumgartner R, Botta P. Amputation und Prothesenversorgung der unteren Extremität. *Ferdinand Enke Verlag Stuttgart*. 1995;486.
26. Popkov A, Osipenko A. Tissue regeneration in limb lengthening. *Moscow GEOTAR-Media*. 2008;240 c.
27. Sveshnikov A. Radionuclide methods used to assess the functional state of the limb at percutaneous osteosynthesis. *Med.radiology*. 1986;8:63–72.

Orthopedic Research and Reviews

Dovepress

Publish your work in this journal

Orthopedic Research and Reviews is an international, peer-reviewed, open access journal that focusing on the patho-physiology of the musculoskeletal system, trauma, surgery and other corrective interventions to restore mobility and function. Advances in new technologies, materials, techniques and pharmacological agents are particularly welcome. The manuscript management system is completely online and includes a very quick and fair peer-review system, which is all easy to use. Visit <http://www.dovepress.com/testimonials.php> to read real quotes from published authors.

Submit your manuscript here: <https://www.dovepress.com/orthopedic-research-and-reviews-journal>