

Infective Endocarditis Caused by *Neisseria Sicca* Species 10 Years After Mechanical Aortic Valve Implantation

Qiqi Cheng¹, Xiaolin Zhou¹, Peng Wang², Rong Liu³, Qiang Liu¹

¹Department of Infectious Disease, Yichang Central People's Hospital, The First College of Clinical Medical Science, China Three Gorges University, Yichang, Hubei, 443000, People's Republic of China; ²Department of Clinical Laboratory, Yichang Central People's Hospital, The First College of Clinical Medical Science, China Three Gorges University, Yichang, Hubei, 443000, People's Republic of China; ³Department of Ultrasound, Yichang Central People's Hospital, The First College of Clinical Medical Science, China Three Gorges University, Yichang, Hubei, 443000, People's Republic of China

Correspondence: Qiang Liu, Department of Infectious Disease, Yichang Central People's Hospital, The First College of Clinical Medical Science, China Three Gorges University, Yichang, Hubei, 443000, People's Republic of China, Tel +86 13720181669, Email liuqiang@ctgu.edu.cn

Abstract: We report a rare case of mechanical aortic valve infective endocarditis caused by *Neisseria sicca*. A 44-year-old man, with a history of aortic valve replacement, presented to the hospital with a 10-day history of fever. Investigations revealed that the blood cultures grew *Neisseria sicca*. Although the transthoracic echocardiogram (TTE) was negative, a transesophageal echocardiogram showed a 0.5 cm × 0.3 cm piece of vegetation attached to the aortic valve. After eight weeks of therapy, according to the antibiotic susceptibility test, the patient's blood cultures were negative, and repeat TTE showed no vegetation. This report can offer valuable insights for clinical diagnosis and treatment of *Neisseria sicca* endocarditis, particularly when selecting sensitive antibiotics.

Keywords: infective endocarditis, *Neisseria sicca*, aortic valve, bacteremia

Introduction

Neisseria mucosa/sicca, a gram-negative diplococcus of the *Neisseria* (*N.*) genus, is typically regarded as a nonpathogenic species that inhabits the oropharyngeal mucosa of healthy individuals. Usually, infective endocarditis (IE) is caused by gram-positive pathogens, gram-negative organisms, including HACEK group bacilli, are rarely reported. IE caused by gram-negative organisms is rare, especially for other *Neisseria* species, except for *N. meningitidis* and *N. gonorrhoeae*.¹ Here, we report a rare case of *Neisseria sicca* mechanical aortic valve infective endocarditis, offering valuable insights for clinical diagnosis and treatment.

Case Presentation

A 44-year-old man was admitted to our department after experiencing a 10-day history of fever (highest temperature 39.0°C) accompanied by chills and headache. He denied cough, sputum production, hemoptysis, or any other discomfort. He had a history of aortic stenosis, had received mechanical aortic valve replacement 10 years prior, and had taken warfarin as an anticoagulant. The patient denied any history of hypertension, diabetes, needle-sharing, intravenous drug use, or other systemic diseases.

On admission, the patient was febrile with a temperature of 38.7°C, a heart rate of 102 beats per minute, a blood pressure of 100/70 mmHg, a respiratory rate of 21 breaths per minute, and an oxygen saturation of 97% in room air. A physical examination revealed poor dentition and a holosystolic murmur at the right sternal border without radiation. Janeway's lesions, Osler's nodes, Roth's spots, and conjunctival hemorrhage were not observed. Laboratory examination showed the following: white blood cell, $12.74 \times 10^9/L$ (normal: $4-10 \times 10^9/L$) with a neutrophil rate of 89.3%, hemoglobin level of 129 g/L (normal: 120–160 g/L), and platelet count of $303 \times 10^9/L$ (normal: $100-300 \times 10^9/L$). Blood chemistry showed an erythrocyte sedimentation rate (ESR) of 15 mm/h (normal <20 mm/h), C-reactive protein (CRP) was

45.93 mg/L (normal <20 mg/L), procalcitonin (PCT) was 9.19 ng/mL (normal <0.05 ng/mL). His chest, abdomen, and head CT showed no abnormalities. And his vascular ultrasound also showed no abnormalities. Transthoracic echocardiography (TTE) revealed a slight increase in the forward flow rate of the mechanical valve after the aortic mechanical valve replacement. No significant perivalvular leakage was observed (Figure 1).

After blood cultures were drawn, the patient was started on empirical antimicrobial therapy with vancomycin, gentamicin, and rifampicin. However, the patient showed no signs of recovery after the application of antibiotics, in terms of temperature and inflammatory markers. By 48 h of culture, two aerobic bottles in the BACTEC system (Becton Dickinson) grew gram-negative diplococci with dry and wrinkled colonies on chocolate agar, which were later identified as *Neisseria mucosa/sicca* using VITEK MS (Biomérieux). Further evaluation with a transesophageal echocardiogram (TEE) revealed a 0.5 cm × 0.3 cm piece of vegetation attached to the aortic valve and a mild increase in regurgitant flow through the prosthetic aortic valve compared with TTE (Figure 2). The patient was evaluated by cardiothoracic surgery but refused surgical intervention. The therapy was then switched to ceftriaxone and rifampicin. However, the patient temperature and biological parameters have not yet been alleviated. A further antibiotic susceptibility test (AST) for *Neisseria mucosa/sicca* was performed in the clinical laboratory (Table 1). Because there were no antimicrobial breakpoints for *Neisseria mucosa/sicca*, we used the antimicrobial breakpoint of the Clinical and Laboratory Standards Institute (CLSI) for *Neisseria meningitidis* as a reference. The results indicated that meropenem, TMP-SMX, chloramphenicol, and minocycline were susceptible, penicillin, azithromycin, ciprofloxacin, and cefotaxime were resistant or unsusceptible, and rifampicin was intermediate. Therefore, treatment was switched to meropenem and minocycline. Thereafter, the patient's condition rapidly improved. Two weeks later, the patient's biological parameters recovered, and reinspection blood cultures were negative; however, a repeat TTE still revealed an increase in the size of the aortic valve vegetation (0.7 cm × 0.2 cm). Rifampicin was added to synergize the anti-infective effects of meropenem and minocycline. After six weeks of therapy, the patient's biological parameters had almost returned to normal, repeat blood cultures were negative, and a repeat TTE revealed smaller vegetation. The patient was discharged with oral treatment of rifampicin, TMP-SMX, and minocycline. After eight weeks of therapy, the patient's blood cultures remained negative, and a repeat TEE (Figure 3) showed no vegetation. Therefore, the antibiotic therapy was discontinued. After

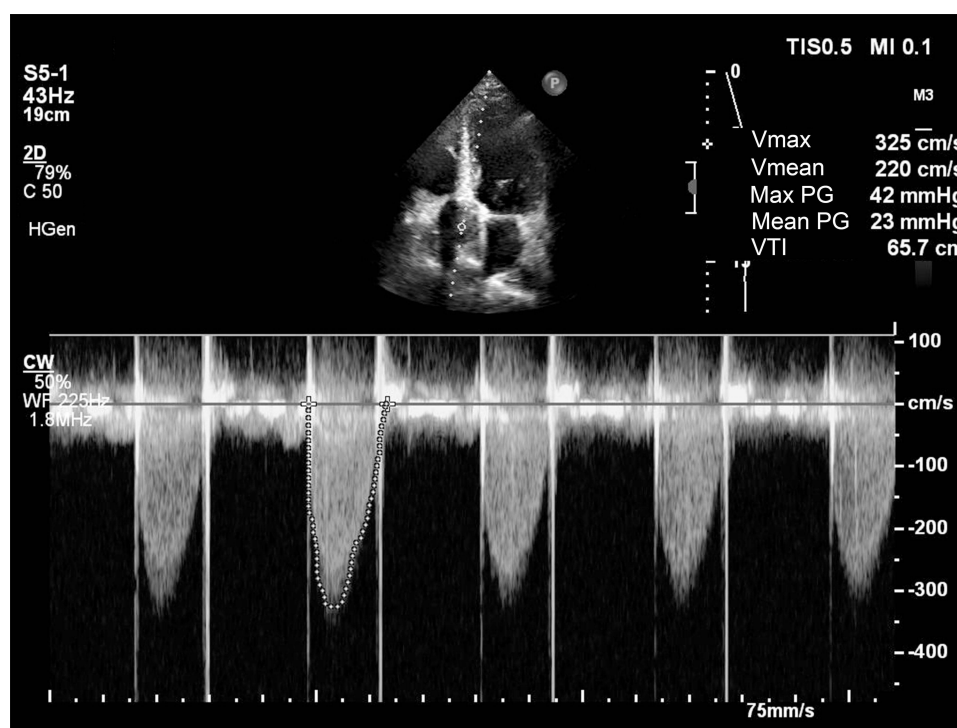


Figure 1 Transthoracic echocardiogram revealed a slight increase in the forward flow rate of the mechanical valve after aortic mechanical valve replacement.

Abbreviations: Vmax, maximum speed; Vmean, average speed; Max PG, maximum pressure gradient; Mean PG, average pressure gradient; VTI, velocity-time integral.

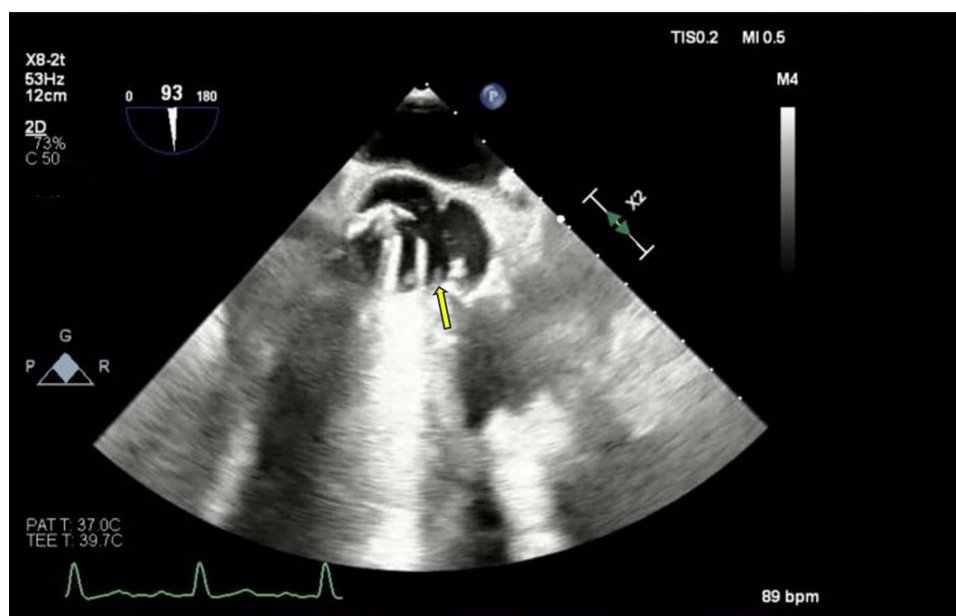


Figure 2 Transesophageal echocardiogram showed a 0.5*0.3cm vegetation attached to the aortic valve (yellow arrow) complicated by mild aortic regurgitation.

more than one year of follow-up, the patient remained in good condition, and the patient's TTE was negative (Figure 4). Here we made a timeline of patient events and treatment decisions to facilitate readers to better inform the diagnosis and treatment process (Table 2).

Discussion

In the genus *Neisseria*, *N. meningitidis* and *N. gonorrhoeae* are the only species that cause serious infectious diseases. *N. gonorrhoeae* infections can also cause infective endocarditis. *N. meningitidis* is the main cause of bacterial meningitis, but rarely causing infective endocarditis. Worldwide, infective endocarditis caused by commensal *Neisseria* (such as

Table 1 Antibiotic Susceptibility Test for *Neisseria Mucosa/Sicca*

Antibiotic	Diameter/MIC	Susceptibility ^c
Penicillin	3 ^a	R
Azithromycin	6 ^b	US
Ciprofloxacin	25 ^b	R
Cefotaxime	28 ^b	US
Rifampicin	22 ^b	I
Meropenem	35 ^b	S
TMP-SMX	34 ^b	S
Chloramphenicol	32 ^b	S
Minocycline	28 ^b	S

Notes: ^aE-test minimal inhibitory concentration (MIC) method. ^bUsing disk diffusion method; ^cSusceptibility takes the MIC breakpoint of the Clinical and Laboratory Standards Institute (CLSI) for *Neisseria meningitidis* as reference: S (susceptible), I (intermediate), R (resistant), and US (unsusceptible).

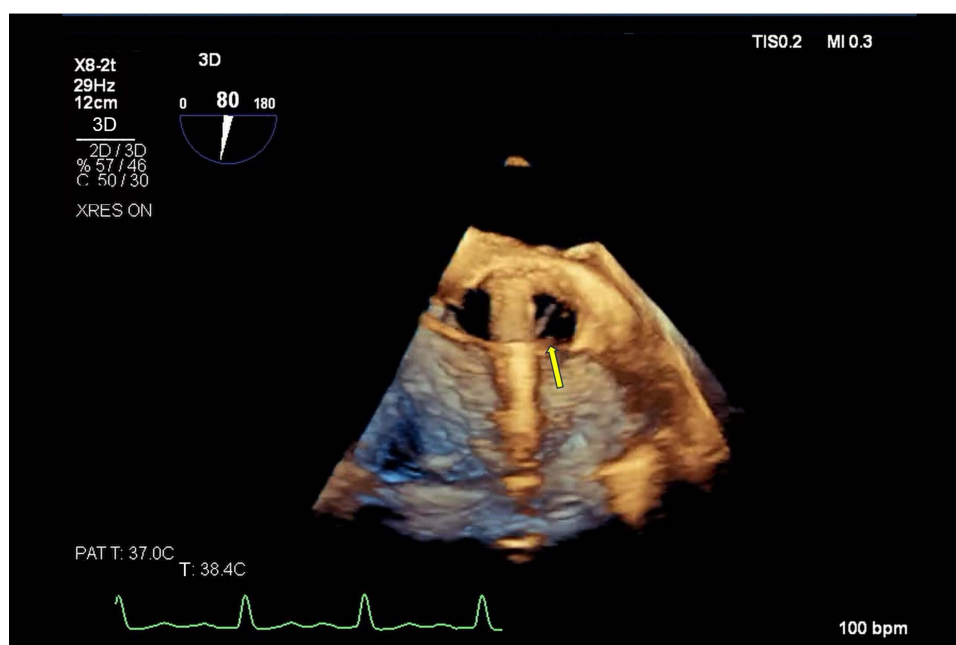


Figure 3 Three-dimensional transesophageal echocardiography showed no vegetation attached to the aortic valve (yellow arrow).

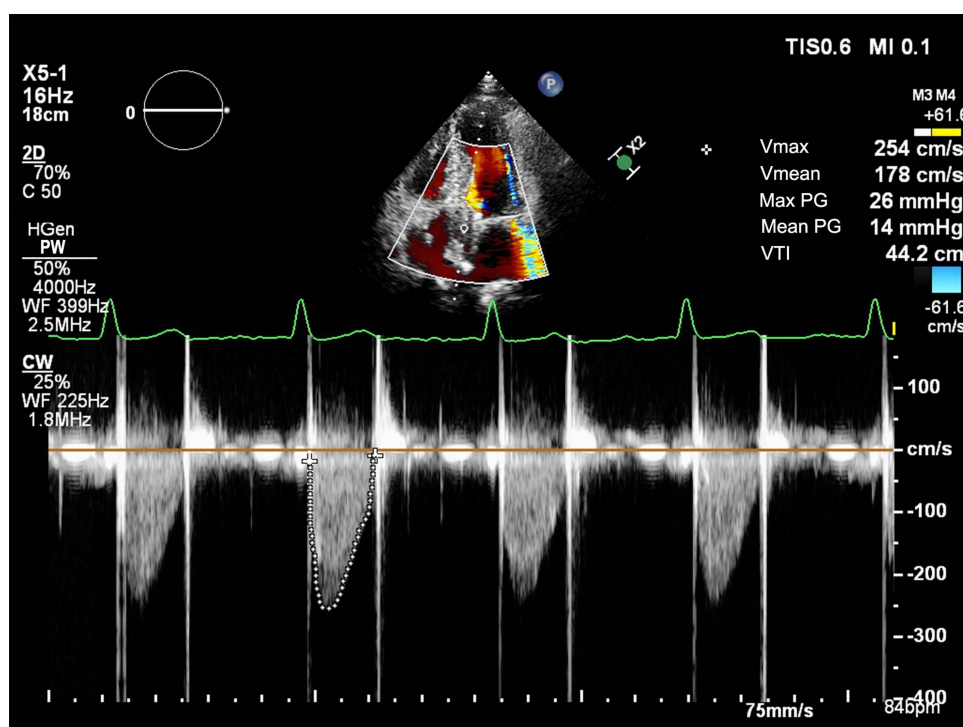


Figure 4 Transthoracic echocardiogram showed no vegetation attached to the aortic valve, and the forward flow rate of the mechanical valve after aortic mechanical valve replacement is normal.

Abbreviations: Vmax, maximum speed; Vmean, average speed; Max PG, maximum pressure gradient; Mean PG, average pressure gradient; VTI, velocity-time integral.

N. elongata, *N. subflava*, *N. lactamica*, *N. cinerea*, *N. skkuensis*, or *N. mucosa*) is rare.² Among these, *N. elongate* was the most common cause of IE (38.4% of the patients described in the literature), followed by *N. mucosa* (36.4%).² *N. sicca* is phenotypically similar to *N. mucosa* and is thought to be a variant of *N. mucosa*.³ However, it is difficult to identify these two species using phylogenetic taxonomic methods. In our case, we observed dry and wrinkled colonies on

Table 2 The Timeline of Events and Therapeutic Decisions

Symptom	Day0	Day3	Day5	Day7	Day14	Day42	Day56
	Chills, Fever	Chills, Fever	Chills, Fever	None	None	None	None
WBC ($10 \times 10^9/L$)	12.74	12.82	13.05	6.24	6.66	36.2	3.82
CRP (mg/L)	45.93	126.51	145.21	36.90	38.70	3.31	2.57
PCT (ng/mL)	9.19	3.44	4.31	0.52	0.21	<0.05	<0.05
Cr ($\mu\text{mol/L}$)	93	70	72	75	74	69	82
TTE/TEE	TTE: no vegetation	TEE: vegetation (0.5 cm \times 0.3 cm)	None	None	TTE: vegetation (0.7 cm \times 0.2 cm)	TTE: no vegetation	TTE: no vegetation
Blood cultures	None	<i>Neisseria mucosa/sicca</i>	None	None	None	Negative	Negative
Therapy	Vancomycin, gentamicin and rifampicin	Ceftriaxone and rifampicin	Meropenem and minocycline	Meropenem and minocycline	Meropenem, Minocycline and rifampicin	Rifampicin, TMP/SMX and minocycline	Antibiotic therapy was discontinued
Supplement	None	Patient refused surgical intervention	Antibiotic susceptibility test result return	None	None	None	None

Abbreviations: WBC, white blood cell; CRP, C-reactive protein; PCT, procalcitonin; TTE, transthoracic echocardiography; TEE, transesophageal echocardiogram; TMP-SMX, trimethoprim-sulfamethoxazole.

chocolate agar and identified them as *N. mucosa/sicca* using VITEK MS (Biomérieux). Thus, we hypothesized that the organism in our case was *N. sicca* based on colony morphology. However, our results may need to be carefully verified as we did not conduct whole-genome sequencing or biochemical tests on these bacteria. Furthermore, these two species typically exhibit variable phenotypic characteristics.

Only 26 cases of *N. sicca* endocarditis have been previously reported.⁴⁻⁶ All patients except one (96.1%) received β -lactam based therapy: penicillin (n = 4), penicillin and gentamicin (n = 9), penicillin and streptomycin (n = 2), penicillin and netilmicin (n = 1), ceftriaxone (n = 2), ceftriaxone and gentamicin (n = 3), ceftriaxone and gentamicin and ciprofloxacin (n = 3), ceftriaxone and gentamicin and rifampicin (n = 1), and ciprofloxacin (n = 1). There is no resistance to β -lactam in these patients. Death was reported in 23.1% of cases (6/26) after therapy.⁴⁻⁷ Most reports have described intravenous drug abuse, underlying heart disease, poor dentition, and prosthetic valves as the main risk factors of *N. sicca* endocarditis.⁷ In our case, poor dentition and prosthetic valves made the patient susceptible to infection with this organism. Typically, *N. sicca* causes severe endocarditis of the mitral valve.⁸ Our case showed aortic valve vegetation. To our knowledge, endocarditis involving this valve usually causes fatal outcomes and poor prognosis. Approximately 90% of the literature reports that *N. sicca* causes severe endocarditis with embolic events.⁹ In this patient, embolic phenomena did not occur in the skin, conjunctives, or other main organs.

Echocardiographic positivity is a major clinical criterion for IE diagnosis. Transesophageal echocardiography commonly has a higher rate of valve vegetation detection than transthoracic echocardiography (96–100% vs 77%).¹⁰ The initial transthoracic echocardiography for the patient described did not show valve vegetation, but a repeat transesophageal echocardiogram (TEE) revealed a 0.5 cm \times 0.3 cm aortic valve vegetation. Thus, a repeat TEE is warranted if there remains high suspicion of IE even the initial TTE is negative. Blood culture and excised valve tissue culture are other major clinical criteria for IE. In our case, two separate aerobic bottles grew *N. sicca* in 48h after culture, excluding contamination. However, *N. sicca* is not a typical IE bacterium according to the modified Duke criteria, which has made it difficult to definitively diagnose IE.

In our case, an antibiotic susceptibility test (AST) for *Neisseria mucosa/sicca* was performed. Because there was no antimicrobial breakpoint for this strain, we used the antimicrobial breakpoint of CLSI for *Neisseria meningitidis* as a reference. The results showed *Neisseria mucosa/sicca* has different antibiotic susceptibilities to *Neisseria meningitidis*; meropenem, TMP-SMX, chloramphenicol, and minocycline were susceptible, whereas penicillin, azithromycin, ciprofloxacin,

and cefotaxime were resistant or unsusceptible, and rifampicin was intermediate. Few studies have reported the antibiotic susceptibility of *Neisseria mucosa/sicca*. A previous study reported that the strain was susceptible to penicillin in high-dose treatment; however, they found that the mitral valve mass increased in size after penicillin treatment.¹¹ Our patient's vegetation decreased after receiving intravenous rifampicin, meropenem, and minocycline followed by oral rifampicin, TMP-SMX, and minocycline. No vegetation was observed after eight weeks of therapy.

The current European Society of Cardiology (ESC) and American Association for Thoracic Surgery (AATS) guidelines suggest that surgical intervention for IE should be considered in patients with congestive heart failure, uncontrolled infection, repeated embolic events, or right-sided IE.¹² According to the literature, approximately half of IE patients with *Neisseria* species infection undergo surgical replacement.¹³ Although the patient we reported had no symptoms of heart failure and the aortic valve vegetation did not exceed 10 mm in size, he had surgical indications that IE was triggered by an extensively resistant *N. sicca*. Upon Discussion with the patient, he refused surgical therapy. We could only add rifampicin to synergize the anti-infective effects of meropenem and minocycline when the repeat TTE showed an increased vegetation size. Several studies have shown that *Neisseria* species cause IE with a high degree of destruction of the native valve.¹⁴ And death have been reported in a patient with aortic valve IE due to *N. sicca*.⁹ Therefore, early surgical therapy may be a rational choice for such patients.

Conclusion

This report presents a rare case of infective endocarditis of the mechanical aortic valve caused by *Neisseria sicca*. There is insufficient clinical experience in the diagnosis and treatment of *Neisseria sicca* endocarditis, particularly when selecting sensitive antibiotics. Patients with IE should consider *Neisseria* strain infection when primary empirical anti-infectious treatment is ineffective, especially when the following high-risk factors are present: intravenous drug abuse, underlying heart disease, poor dentition, or prosthetic valves. Although the reported mortality of the *Neisseria* strain is low, vegetation of the aortic valve may cause a fatal outcome. Early surgical therapy may still be a rational choice for *N. sicca* causing IE, because this strain exhibits extensive resistance to antibiotics.

Data Sharing Statement

The original contributions of this study are as follows. Further inquiries can be directed to the corresponding authors.

Ethical Statement and Informed Consent

No specific ethics committee approval was required for this study.

Consent for Publication

We confirm that the patient agreed to the publication of his personal and clinical details, along with any identifying images. Written informed consent was signed by himself.

Acknowledgments

The authors thank the patient for their cooperation in the diagnostic process.

Author Contributions

All authors made a significant contribution to the work reported, whether in the conception, study design, execution, acquisition of data, analysis, and interpretation, or in all these areas, took part in drafting, revising, or critically reviewing the article, approved the final version of the manuscript, agreed on the journal to which the article has been submitted, and agreed to be accountable for all aspects of the work.

Funding

This project was supported by the Key Scientific Research Project of the Department of Education, Hubei Province (D20201204), Hubei Provincial Natural Science Foundation (grant no.2022CFB037), Hubei Provincial Administration of Traditional Chinese Medicine (grant no. ZY2023M039), and Yi Chang Scientific and Technological Bureau (grant nos. A22-2-017).

Disclosure

None of the authors have any conflicts of interest.

References

1. Jin Y, Xu H, Yao Q, et al. Confirmation of the need for reclassification of *Neisseria mucosa* and *Neisseria sicca* using average nucleotide identity blast and phylogenetic analysis of whole-genome sequencing: hinted by clinical misclassification of a *Neisseria mucosa* strain. *Front Microbiol*. 2022;12:780183. doi:10.3389/fmicb.2021.780183
2. Walsh L, Clark SA, Derrick JP, Borrow R. Beyond the usual suspects: reviewing infections caused by typically-commensal *Neisseria* species. *J Infect*. 2023;87(6):479–489. doi:10.1016/j.jinf.2023.09.007
3. Bennett JS, Jolley KA, Earle SG, et al. A genomic approach to bacterial taxonomy: an examination and proposed reclassification of species within the genus *Neisseria*. *Microbiology*. 2012;158(Pt 6):1570–1580. doi:10.1099/mic.0.056077-0
4. Kirlew C, Wilmot K, Salinas JL. *Neisseria sicca* endocarditis presenting as multiple embolic brain infarcts. *Open Forum Infect Dis*. 2015;2(3):ofv105. doi:10.1093/ofid/ofv105
5. Locke M, Smith A, Epstein LM, Niknam N, Boparai R. Pacemaker lead-related endocarditis with *Neisseria sicca*. *BMJ Case Rep*. 2022;15(7):e249795. doi:10.1136/bcr-2022-249795
6. Szendrey JA, Asghar A, Mokraoui N, Walker D. A case of native tricuspid valve *Neisseria mucosa/sicca* species infective endocarditis complicated by septic pulmonary emboli. *IDCases*. 2023;33:e01850. doi:10.1016/j.idcr.2023.e01850
7. Pilimis B, Lefort A, Lecuit M, et al. Endocarditis due to *Neisseria mucosa*: case report and review of 21 cases: a rare and severe cause of endocarditis. *J Infect*. 2014;68(6):601–604. doi:10.1016/j.jinf.2014.02.007
8. Aronson PL, Nelson KA, Mercer-Rosa L, Donoghue A. *Neisseria sicca* endocarditis requiring mitral valve replacement in a previously healthy adolescent. *Pediatr Emerg Care*. 2011;27(10):959–962. doi:10.1097/PEC.0b013e3182309e95
9. Sommerstein R, Ramsay D, Dubuis O, Waser S, Aebersold F, Vogt M. Fatal *Neisseria sicca* endocarditis. *Infection*. 2013;41(3):747–749. doi:10.1007/s15010-012-0393-8
10. Reynolds HR, Jagen MA, Tunick PA, Kronzon I. Sensitivity of transthoracic versus transesophageal echocardiography for the detection of native valve vegetation in the modern era. *J Am Soc Echocardiogr*. 2003;16(1):67–70. doi:10.1067/mje.2003.43
11. Epelbaum S, Laurent C, Morin G, Laurans G, Piussan C. Endocardite à *Neisseria mucosa* compliquée d'anévrysmes intracérébraux [*Neisseria mucosa* endocarditis complicated by intracerebral aneurysm]. *Arch Fr Pediatr*. 1993;50(3):231–233. French.
12. Iaccarino A, Barbone A, Basciu A, et al. Surgical challenges in infective endocarditis: State of the Art. *J Clin Med*. 2023;12(18):5891. doi:10.3390/jcm12185891
13. Jeurissen A, Stroy JP, Wielenga RP, Andriesse GI. Severe infective endocarditis due to *Neisseria sicca*: case report and review of literature. *Acta Clin Belg*. 2006;61(5):256–258. doi:10.1179/acb.2006.043
14. Brouqui P, Raoult D. Endocarditis due to rare and fastidious bacteria. *Clin Microbiol Rev*. 2001;14(1):177–207. doi:10.1128/CMR.14.1.177-207.2001

Infection and Drug Resistance

Dovepress

Publish your work in this journal

Infection and Drug Resistance is an international, peer-reviewed open-access journal that focuses on the optimal treatment of infection (bacterial, fungal and viral) and the development and institution of preventive strategies to minimize the development and spread of resistance. The journal is specifically concerned with the epidemiology of antibiotic resistance and the mechanisms of resistance development and diffusion in both hospitals and the community. The manuscript management system is completely online and includes a very quick and fair peer-review system, which is all easy to use. Visit <http://www.dovepress.com/testimonials.php> to read real quotes from published authors.

Submit your manuscript here: <https://www.dovepress.com/infection-and-drug-resistance-journal>