

# Safety and Efficacy of Gefitinib Administration After Osimertinib-Induced Interstitial Lung Disease: A Six-Case Series

Kaoruko Shimbu<sup>1</sup>, Kakeru Hisakane<sup>1</sup>, Naohiro Kadoma<sup>1</sup>, Shunichi Nishima<sup>1</sup>, Kenichiro Atsumi<sup>1</sup>, Masahiro Seike<sup>2</sup>, Takashi Hirose<sup>1</sup>

<sup>1</sup>Department of Pulmonary Medicine and Medical Oncology, Nippon Medical School, Tama Nagayama Hospital, Tokyo, 206-8512, Japan; <sup>2</sup>Department of Pulmonary Medicine and Oncology, Graduate School of Medicine, Nippon Medical School, Tokyo, 113-8603, Japan

Correspondence: Kakeru Hisakane, Department of Pulmonary Medicine and Medical Oncology, Nippon Medical School, Tama Nagayama Hospital, 1-7-1 Nagayama, Tama-shi, Tokyo, 206-8512, Japan, Tel +81-42-371-2111, Email hisa079kane@nms.ac.jp

**Purpose:** Osimertinib, a third-generation epidermal growth factor receptor (EGFR) tyrosine kinase inhibitor, is the standard treatment for patients with non-small cell lung cancer harboring EGFR mutations. Although the frequency of osimertinib-induced interstitial lung disease (osi-ILD) is high, the optimal cancer treatment after osi-ILD has not been established. This time, we focused on the safety and efficacy of gefitinib following osi-ILD.

**Case Presentation:** We experienced six cases (five women and one man; median age: 74 years) in which gefitinib was administered after osi-ILD. All six cases had grade 2 or higher osi-ILD and required steroid treatment. The computed tomography imaging pattern of osi-ILD revealed organizing pneumonia in three cases, diffuse alveolar damage in two cases, and hypersensitivity pneumonia in one case. Eastern Cooperative Oncology Group performance status was 1 in four cases, 2 in one case, and 3 in one case. EGFR mutation status was exon 19 deletion in two cases and exon 21 L858R in four cases. Only one patient experienced recurrence of ILD after receiving gefitinib. The best response to gefitinib was partial response in two cases and stable disease in three cases; one case was not evaluable. The median progression-free survival after treatment with gefitinib was 190 days (95% confidence interval: 33–328).

**Conclusion:** The treatment with gefitinib after the development of osi-ILD was safe and effective. Gefitinib may be a promising option for patients who recovered from severe osi-ILD.

**Keywords:** chemotherapy, epidermal growth factor receptor kinase inhibitor, non-small cell lung cancer, steroid

## Introduction

Osimertinib, a third-generation epidermal growth factor receptor tyrosine kinase inhibitor (EGFR-TKI), is recommended as a first-line treatment for patients with advanced non-small cell lung cancer harboring EGFR mutations.<sup>1</sup> Drug-induced interstitial lung disease (ILD) is a common adverse event of osimertinib. The reported probability of developing osimertinib-induced interstitial lung disease (osi-ILD) is 3.6%.<sup>1</sup> In the Japanese population, this probability ranges 12.3–18.3%.<sup>2,3</sup> In a real-world setting in Japan, the reported rate of osi-ILD was 6.8–17.7%.<sup>4,5</sup>

Several successful cases of treatment with osimertinib or other EGFR-TKIs after osi-ILD have been reported.<sup>6–13</sup> A retrospective study evaluated the efficacy and safety of continued administration or re-administration of osimertinib after osi-ILD; however, most of these cases had grade 1 osi-ILD.<sup>14</sup> Thus far, few large-scale studies investigated the re-administration of EGFR-TKIs other than osimertinib after osi-ILD. Moreover, the optimal cancer treatment for patients who recovered from severe osi-ILD remains unclear. At our hospital, osimertinib was administered to 95 patients between June 1, 2016 and September 30, 2023. Thirteen patients developed osi-ILD, and six of those received gefitinib after osi-ILD; this report focuses on those six patients. In this article, we discuss the safety and efficacy of gefitinib based on the course of six cases. The date of data cut-off was March 31, 2024.

## Case Presentation

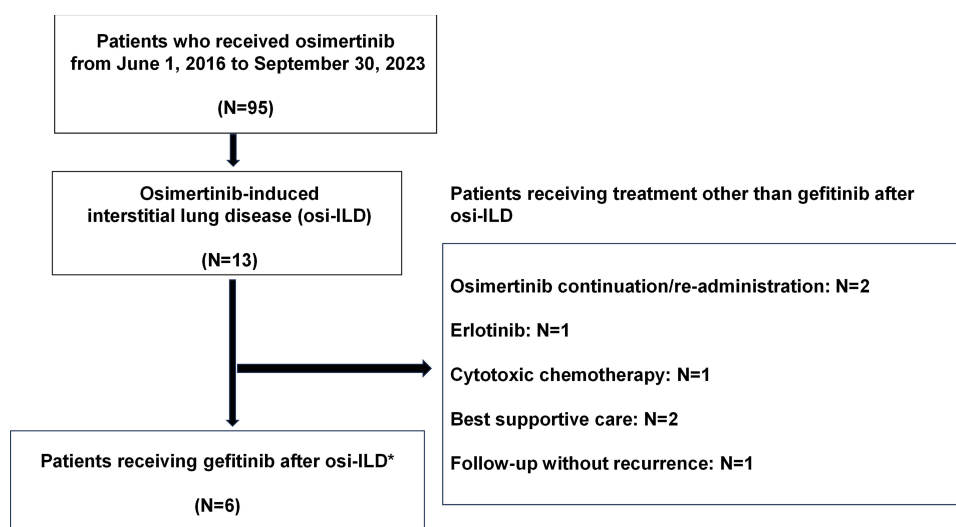
The patient inclusion flowchart is illustrated in Figure 1.

### Case 1

A 62-year-old Japanese woman with no history of smoking was diagnosed with stage IVB (cT4N3M1c) lung adenocarcinoma harboring the EGFR exon 19 deletion. Administration of osimertinib 80 mg daily was initiated as first-line treatment. However, osi-ILD occurred after 69 days, and treatment with osimertinib was discontinued. After administration of methylprednisolone 1000 mg for 3 days, post-therapy with prednisolone 40 mg was initiated. The patient had grade 3 osi-ILD, the maximal oxygen dose was 3 L with cannula, and computed tomography (CT) imaging showed an organizing pneumonia (OP) pattern (Figure 2). While discontinuing osimertinib, pleural effusion and lung metastasis increased. Therefore, after tapering the dose of prednisolone to 5 mg daily, administration of gefitinib 250 mg daily was initiated as second-line therapy. Following the initiation of treatment with gefitinib, the patient did not experience any recurrence of ILD. However, her general condition worsened due to progression of the lung cancer and infection with coronavirus disease-2019. On day 33 of treatment with gefitinib, she was unable to receive the medication and expired.

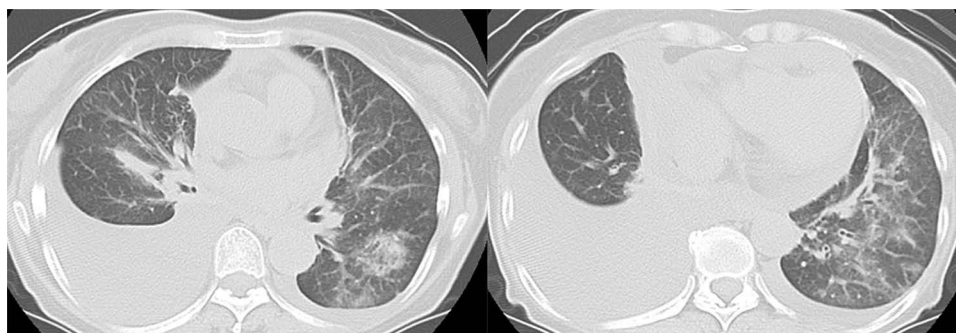
### Case 2

An 82-year-old Japanese woman with no history of smoking was diagnosed with stage IVB (cT4N2M1c) lung adenocarcinoma harboring the EGFR exon 19 deletion. Administration of osimertinib 80 mg daily was initiated as first-line treatment. However, osi-ILD occurred after 7 days, and osimertinib was discontinued. Following the administration



**Figure 1** Patient inclusion flowchart.

**Notes:** \* One case in which osimertinib was re-administered prior to gefitinib administration.

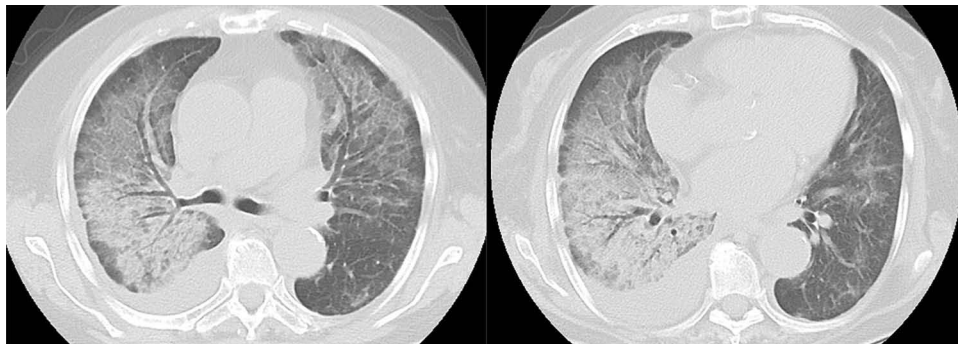


**Figure 2** Computed tomography imaging of osimertinib-induced interstitial lung disease in case 1 showing an organizing pneumonia pattern.

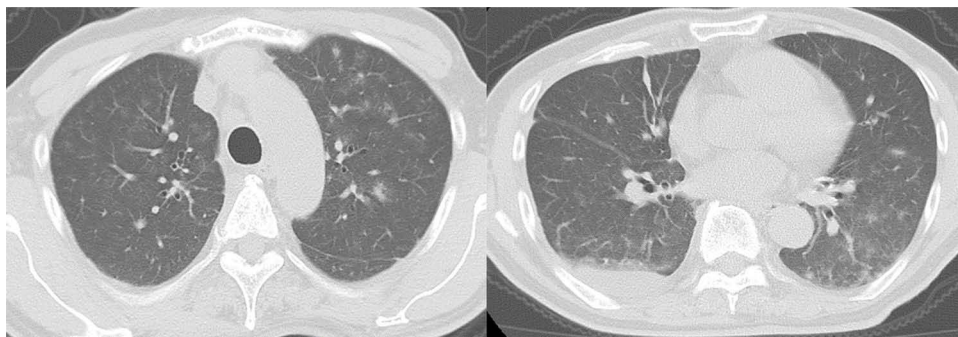
of methylprednisolone 1000 mg for 3 days, post-therapy with prednisolone 50 mg daily was initiated. She had grade 3 osi-ILD, maximal oxygen dose was 4 L with cannula, and CT imaging showed a diffuse alveolar damage (DAD) pattern (Figure 3). The dose of prednisolone was tapered to 15 mg daily, and administration of gefitinib 250 mg daily was initiated as second-line therapy due to worsening of cancerous lymphangiopathy, while treatment with osimertinib was discontinued. At the time of this report, treatment with gefitinib is continued with no recurrence of ILD. Moreover, the dose of prednisolone was tapered to 5 mg daily, and treatment with this agent is ongoing.

### Case 3

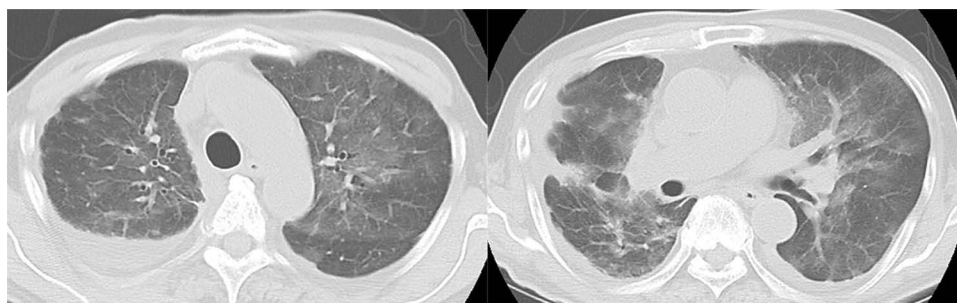
A 77-year-old Japanese man with a history of smoking 10 to 15 cigarettes per day until 40 years of age was diagnosed with stage IVA (cT1bN2M1a) lung adenocarcinoma harboring the EGFR exon 21 L858R mutation. Administration of osimertinib 80 mg daily was initiated as first-line treatment. However, osi-ILD occurred after 91 days, and treatment with osimertinib was discontinued. Administration of prednisolone 30 mg daily was initiated. After tapering the dose and finishing treatment with prednisolone, administration of osimertinib 40 mg daily was re-initiated. Seven days later, osi-ILD recurred and treatment with osimertinib was discontinued again. He had grade 2 osi-ILD, and CT imaging showed an OP pattern (Figure 4). Administration of prednisolone 15 mg daily was initiated. While tapering the dose of prednisolone, pleural effusion increased, and chemotherapy other than EGFR-TKI was selected as second- and third-line treatments. Subsequently, new bone metastases appeared, and gefitinib 250 mg daily was initiated as fourth-line treatment. However, gefitinib-induced interstitial lung disease (gefi-ILD) occurred after 18 days, and the administration of gefitinib was discontinued. The patient had grade 3 gefi-ILD, the maximal oxygen dose was 3 L with cannula, and CT imaging showed a hypersensitivity pneumonia (HP) pattern (Figure 5). Following the administration of methylprednisolone 1,000 mg for 3 days, post-therapy with prednisolone 50 mg daily was initiated. The dose of prednisolone was tapered and administration was finished. Nonetheless, new lung metastases appeared. Fifth-line chemotherapy using agents other than EGFR-TKIs was performed; however, his general condition worsened and best supportive care (BSC) was provided.



**Figure 3** Computed tomography imaging of osimertinib-induced interstitial lung disease in case 2 showing a diffuse alveolar damage pattern.



**Figure 4** Computed tomography imaging of osimertinib-induced interstitial lung disease in case 3 showing an organizing pneumonia pattern.



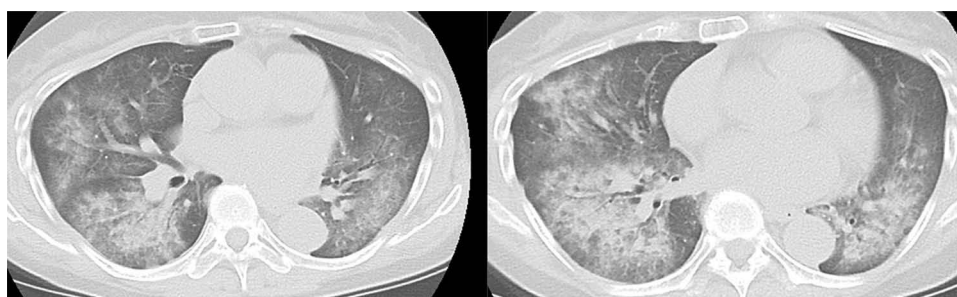
**Figure 5** Computed tomography imaging of gefitinib-induced interstitial lung disease in case 3 showing a hypersensitivity pneumonia pattern.

## Case 4

A 70-year-old Japanese woman with no history of smoking was diagnosed with stage IIIC (cT3N2M0) lung adenocarcinoma harboring the EGFR exon 21 L858R mutation. Chemoradiotherapy was performed as first-line treatment, and durvalumab was administered as maintenance treatment. After 26 cycles of treatment with durvalumab, new lung metastases appeared. Therefore, osimertinib 80 mg daily was initiated as second-line treatment. However, osi-ILD occurred after 62 days, and treatment with osimertinib was discontinued. After administration of methylprednisolone 1000 for 3 days, post-therapy with prednisolone 60 mg daily was initiated. The patient had grade 3 osi-ILD. The maximal oxygen dose was 6 L with mask; and CT imaging showed a DAD pattern (Figure 6). The dose of prednisolone was tapered, and administration was finished. However, left hilar lymph node and lung metastases were increased. Therefore, administration of gefitinib 250 mg daily was initiated as third-line therapy. The patient was treated with gefitinib for 328 days without recurrence of ILD. Left hilar lymph node and lung metastases were increased, and treatment with gefitinib was discontinued. Thereafter, chemotherapy with agents other than EGFR-TKIs was selected as fourth- to sixth-line treatments. However, new liver and bone metastases appeared. Subsequently, her general condition worsened, and BSC was provided. The patient transitioned to home care.

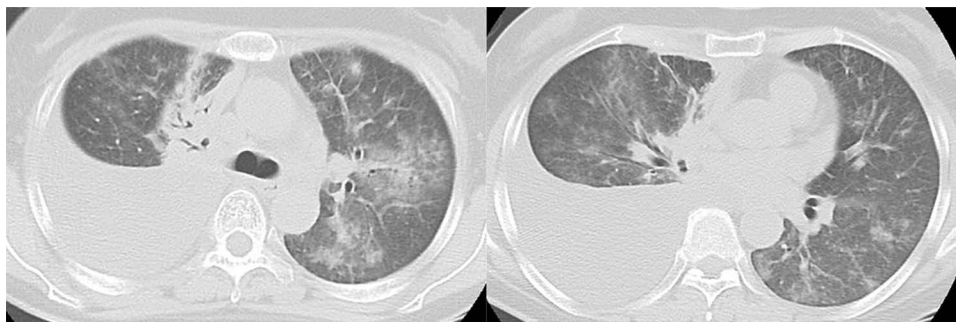
## Case 5

A 57-year-old Japanese woman with no history of smoking was diagnosed with stage IIIB (cT1cN3M0) lung adenocarcinoma harboring the EGFR exon 21 L858R mutation. Chemoradiotherapy was performed as first-line treatment, and durvalumab was administered as maintenance treatment. After five cycles of treatment with durvalumab, the tumor and mediastinal lymph nodes were enlarged, and right pleural effusion appeared. Therefore, administration of osimertinib 80 mg daily was initiated as second-line treatment. However, osi-ILD occurred 15 days later, and treatment with osimertinib was discontinued. Methylprednisolone 500 mg was administered for 3 days, followed by administration of methylprednisolone 250 mg for another 3 days; subsequently, prednisolone 40 mg daily was initiated as post-therapy. The patient had grade 2 osi-ILD, and CT imaging showed an OP pattern (Figure 7). While discontinuing osimertinib, pleural effusion increased. Therefore, the dose of prednisolone was tapered to 30 mg daily, and administration of gefitinib 250 mg daily was initiated as third-line therapy. After tapering the dose of prednisolone to 2.5 mg daily, she continued



**Figure 6** Computed tomography imaging of osimertinib-induced interstitial lung disease in case 4 showing a diffuse alveolar damage pattern.





**Figure 7** Computed tomography imaging of osimertinib-induced interstitial lung disease in case 5 showing an organizing pneumonia pattern.

receiving treatment with gefitinib for 164 days. After initiating treatment with gefitinib, the patient did not experience any recurrence of ILD. The administration of gefitinib was discontinued due to tumor growth and an increase in right pleural effusion. The patient selected BSC and transitioned to home care.

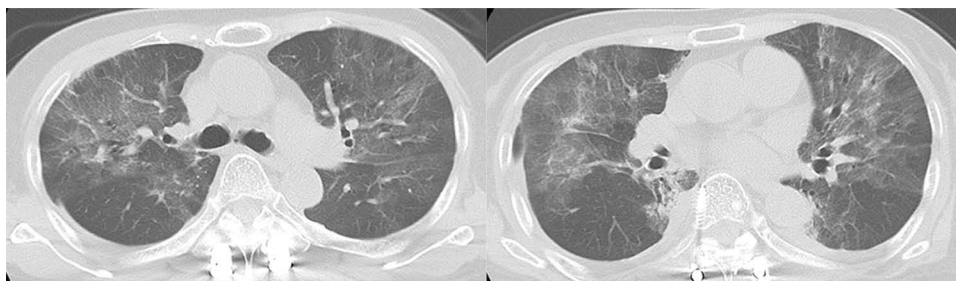
## Case 6

A 78-year-old Japanese woman with no history of smoking was diagnosed with stage IVB (cT1cN0M1c) lung adenocarcinoma harboring the EGFR exon 21 L858R mutation. Administration of osimertinib 80 mg daily was initiated as first-line treatment. However, osi-ILD occurred after 51 days, and treatment with osimertinib was discontinued. Following the administration of methylprednisolone 1000 for 3 days, post-therapy with prednisolone 45 mg daily was initiated. She had grade 3 osi-ILD, the maximal oxygen dose was 2 L with cannula, and CT imaging showed a HP pattern (Figure 8). The dose of prednisolone was tapered, and the administration was finished. Upon completion of prednisolone therapy, the lung cancer had not progressed; nevertheless, she strongly desired to continue treatment. Therefore, administration of gefitinib 250 mg daily was initiated as second-line therapy. At the time of this report, treatment with gefitinib is continued with no recurrence of ILD.

## Discussion

To the best of our knowledge, this is the first case series reporting the administration of gefitinib after osi-ILD. The characteristics of six cases are summarized in Table 1 and Figure 9. The median age was 74 years. All patients had grade 2 or higher osi-ILD (grade 2 in two patients; grade 3 in four patients). The CT imaging patterns of osi-ILD were based on a previous report;<sup>15</sup> moreover, they were determined by discussion among six respiratory physicians until a consensus was reached. The CT imaging patterns of osi-ILD<sup>15</sup> were OP, DAD, and HP in three, two, and one case, respectively. Only one patient developed gefi-ILD. The objective response rate, disease control rate, and median progression-free survival (PFS) following the administration of gefitinib were 33%, 83%, and 190 days (95% confidence interval: 33–328), respectively.

This case series demonstrates that treatment with gefitinib after the development of osi-ILD was tolerable. A retrospective study examined 33 cases of EGFR-mutated advanced non-small cell lung cancer in which osimertinib

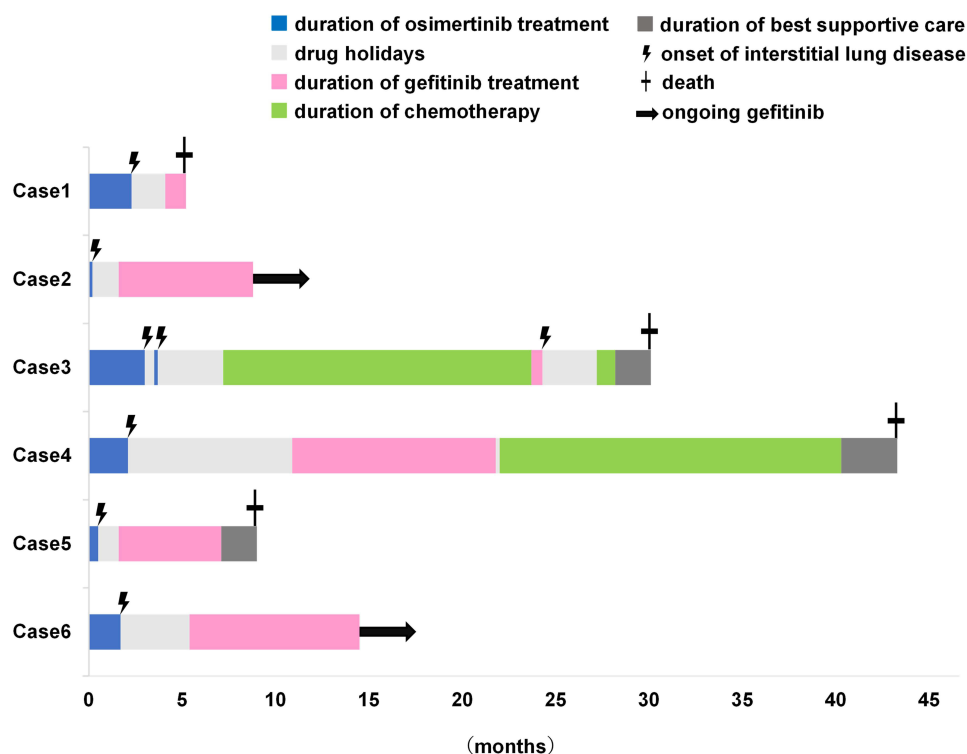


**Figure 8** Computed tomography imaging of osimertinib-induced interstitial lung disease in case 6 showing a hypersensitivity pneumonia pattern.

**Table 1** Characteristics of Six Targeted Cases in Which Gefitinib Was Administered After Osimertinib-Induced Interstitial Lung Disease

Case number	Age (years)	Sex	EGFR status	Osimertinib dose (mg)	Onset of osi-ILD (months)	Osi-ILD grade	CT pattern <sup>15</sup> of osi-ILD	From the end of osimertinib to the start of gefitinib (months)	Duration of gefitinib administration (months)	Occurrence of gefi-ILD	PFS after gefitinib administration (months)	Effect of osimertinib	Effect of gefitinib
1	62	Female	Exon 19 deletion	80	2.3	3	OP	1.8	1.1	No	1.1	SD	NE
2	82	Female	Exon 19 deletion	80	0.2	3	DAD	1.4	7.2*	No	7.2*	SD	SD
3	77	Male	Exon 21 L858R	80→40	3.3	2	OP	20	0.6	Yes	3.3	PR	SD
4	70	Female	Exon 21 L858R	80	2	3	DAD	8.8	10.9	No	10.9	SD	PR
5	57	Female	Exon 21 L858R	80	0.5	2	OP	1.1	5.5	No	5.5	SD	SD
6	78	Female	Exon 21 L858R	80	1.7	3	HP	3.7	9*	No	9*	PR	PR

**Notes:** \* Treatment with gefitinib is continued with no recurrence of ILD, as of March 31, 2024, which was the cutoff date for this study.  
**Abbreviations:** CT, computed tomography; DAD, diffuse alveolar damage; EGFR, epidermal growth factor receptor; gefi-ILD, gefitinib-induced interstitial lung disease; HP, hypersensitivity pneumonia; ILD, interstitial lung disease; NE, not evaluable; OP, organizing pneumonia; osi-ILD, osimertinib-induced interstitial lung disease; PFS, progression-free survival; PR, partial response; SD, stable disease.



**Figure 9** Treatment progress for each case.

was administered as first-line treatment, and therapy with this agent was continued or re-administered after developing osi-ILD. The results showed that ILD relapsed in five of 33 patients (15.1%).<sup>14</sup> In our study, ILD relapse after treatment with gefitinib occurred in one of six patients (16.7%). The ILD relapse rate after administration of gefitinib was similar to that observed after rechallenge with osimertinib. However, in the retrospective study, 26 of 33 cases had grade 1 osi-ILD, whereas all six cases in the present study had grade 2 or higher disease (Table 2). We suggest that, in cases with grade 2 or higher osi-ILD, administration of gefitinib might be safer than rechallenge with osimertinib.

To examine the efficacy of gefitinib after osi-ILD, we referred to previous case reports<sup>6–13</sup> in which patients received osimertinib or afatinib after osi-ILD. We selected only cases limited to grade 2 or higher osi-ILD to match the severity of ILD in this case series. Table 3 summarizes the data of a total of 15 cases: seven cases treated with osimertinib; two cases treated with afatinib; and six cases analyzed in this series. Case 1 had a short PFS of 33 days because it became difficult to receive gefitinib early due to deterioration of the general condition of the patient. In addition, case 3 developed gefi-ILD and had to discontinue treatment with gefitinib after 18 days; the PFS of this case was 100 days. Cases 2 and 6 are currently receiving gefitinib, which is expected to further prolong the PFS. Cases 2 and 4–6 had similar PFS compared with cases 7–15, which were cases of successful treatment. Notably, the rates of objective response (33%) and disease

**Table 2** Comparison of the Number of Cases Based on the Severity of Osimertinib-Induced Interstitial Lung Disease Between a Previous Report and the Present Study

	Severity of osi-ILD		
	Grade 1	Grade 2	Grade 3
Osimertinib rechallenge after osi-ILD <sup>14</sup>	26	6	1
Gefitinib after osi-ILD (present study)	0	2	4

**Notes:** Data are presented as numbers.

**Abbreviation:** osi-ILD, osimertinib-induced interstitial lung disease.

**Table 3** Literature Review of Epidermal Growth Factor Receptor Tyrosine Kinase Inhibitors Administered After Osimertinib-Induced Interstitial Lung Disease

Case number	Age (years)	Sex	Osi-ILD grade	EGFR-TKI used after osi-ILD / dose	Effect of EGFR-TKI used after osi-ILD	PFS of EGFR-TKI used after osi-ILD (months)	Steroid use during rechallenge	Reference
1	62	Female	3	Gefitinib / 250 mg	NE	1.1	Yes	Present study
2	82	Female	3	Gefitinib / 250 mg	SD	7.2*	Yes	Present study
3	77	Male	2	Gefitinib / 250 mg	SD	3.3	No	Present study
4	70	Female	3	Gefitinib / 250 mg	PR	10.9	No	Present study
5	57	Female	2	Gefitinib / 250 mg	SD	5.5	Yes	Present study
6	78	Female	3	Gefitinib / 250 mg	PR	9.0*	No	Present study
7	62	Male	2	Osimertinib / 40 mg	PR	5**	Yes	Kiriu et al <sup>6</sup>
8	75	Female	2	Osimertinib / 40 mg	PR	6**	Yes	Miyauchi et al <sup>7</sup>
9	60	Male	3	Osimertinib / not shown	PR	6**	Yes	Nagasaka et al <sup>8</sup>
10	75	Female	2	Osimertinib / 80 mg	SD	7	Yes	Itano et al <sup>9</sup>
11	58	Female	3	Osimertinib / 40 mg	Not shown	10**	Yes	Bickert et al <sup>10</sup>
12	65	Female	3	Osimertinib / 40 mg	Not shown	5**	Yes	Bickert et al <sup>10</sup>
13	69	Female	2	Osimertinib / 40 mg	SD	6**	Yes	Satoh et al <sup>11</sup>
14	84	Female	3	Afatinib / 20 mg	PR	13	Yes	Sato et al <sup>12</sup>
15	78	Female	2	Afatinib / 30 mg	PR	8	No	Nishima et al <sup>13</sup>

**Notes:** \* Treatment with gefitinib is continued with no recurrence of ILD, as of March 31 2024, which was the cutoff date for the present study. \*\* Data were censored at the time of manuscript submission.  
**Abbreviations:** EGFR-TKI, epidermal growth factor receptor tyrosine kinase inhibitor; NE: not evaluable; osi-ILD: osimertinib-induced interstitial lung disease; PFS, progression-free survival; PR, partial response; SD, stable disease.

control (83%) were encouraging. Gefitinib after osi-ILD may be as effective as other EGFR-TKIs. According to the results of previous Phase 3 trials, platinum combination chemotherapy after progression on EGFR-TKIs was associated with an objective response rate of 31–42% and a median PFS of 4.4–5.6 months.<sup>16–18</sup> The efficacy of gefitinib in this study was non-inferior to that recorded in the earlier mentioned trials. A multicenter trial with larger cohorts of patients is warranted to elucidate the efficacy of gefitinib after osi-ILD.

In cases 7–14 (Table 3),<sup>6–12</sup> steroid therapy was used concomitantly during the administration of EGFR-TKI after osi-ILD; there was no recurrence of ILD in any of these cases. In this study, gefitinib was administered along with a steroid in three of six cases (cases 1, 2, and 5 in Table 3). These three patients did not experience recurrence of ILD. Steroid therapy was not used at the time of treatment with gefitinib in case 3 (Table 3), the only patient who developed gefi-ILD. Because ILD is caused by an allergic or immunological reaction, the anti-inflammatory effect of steroid therapy may prevent the recurrence of ILD.<sup>19</sup> According to these findings, it is suggested that the concomitant use of steroid agents during treatment with a EGFR-TKI after osi-ILD may enable safer long-term administration.

When selecting EGFR-TKIs for administration after osi-ILD, we assigned importance to adverse events other than ILD that are directly linked to quality of life, such as diarrhea and skin rash. The probability of diarrhea as a result of treatment with gefitinib, erlotinib, and afatinib was 41.8%,<sup>20</sup> 79.6%,<sup>21</sup> and 95.2%,<sup>22</sup> respectively (grade 3 or higher severity: 2.8%, 1.0%, and 14.4%, respectively). The probability of skin rash was 60.7%,<sup>20</sup> 82.5%,<sup>21</sup> and 89.1%,<sup>22</sup> respectively (grade 3 or higher severity: 3.0%, 13.6%, and 16.2%, respectively). The selection of gefitinib for administration after osi-ILD was partly based on the relatively low incidence of diarrhea and skin rash.

Conclusion

The treatment with gefitinib after the development of osi-ILD was safe and effective. Gefitinib may be a promising therapeutic option for patients with grade 2 or higher osi-ILD who are concerned regarding the re-administration of osimertinib.



## Ethics Approval

This study was approved by the Ethics Committee of Nippon Medical School Tamanagayama Hospital (approval number: F-2023-088).

## Consent for Publication

Institutional approval was not required to publish the case details.

Informed consent was obtained from the patients or their families (if the patients are deceased) regarding the publication of their case details and accompanying images.

## Disclosure

K. Hisakane reports receiving personal fees from AstraZeneca, MSD, Kyorin Pharmaceutical, Chugai Pharmaceutical, and Daiichi-Sankyo, outside the submitted work. M. Seike reports receiving grants from Taiho Pharmaceutical, Chugai Pharmaceutical, Eli Lilly, Nippon Kayaku, and Kyowa Hakko Kirin; and personal fees from AstraZeneca, MSD, Chugai Pharmaceutical, Taiho Pharmaceutical, Eli Lilly, Ono Pharmaceutical, Bristol-Myers Squibb, Nippon Boehringer Ingelheim, Pfizer, Novartis, Takeda Pharmaceutical, Kyowa Hakko Kirin, Nippon Kayaku, Daiichi-Sankyo, Merck Biopharma, and Amgen, outside the submitted work. T. Hirose reports receiving grants from Chugai Pharmaceutical, Nippon Boehringer Ingelheim, and Taiho Pharmaceutical; and personal fees from Chugai Pharmaceutical, AstraZeneca, MSD, Bristol-Myers Squibb, Nippon Boehringer Ingelheim, Eli Lilly, Taiho Pharmaceutical, Daiichi-Sankyo, Takeda Pharmaceutical, Pfizer, and Novartis, outside the submitted work. The remaining authors have no conflicts of interest to declare for this work.

## References

1. Soria J-C, Ohe Y, Vansteenkiste J, et al. Osimertinib in Untreated EGFR -Mutated Advanced Non-Small-Cell Lung Cancer. *N Engl J Med*. 2018;378(2):113–125. doi:10.1056/NEJMoa1713137
2. Ohe Y, Imamura F, Nogami N, et al. Osimertinib versus standard-of-care EGFR-TKI as first-line treatment for EGFR-mutated advanced NSCLC: FLAURA Japanese subset. *Jpn J Clin Oncol*. 2019;49(1):29–36. doi:10.1093/jjco/hyy179
3. Kenmotsu H, Wakuda K, Mori K, et al. Randomized Phase 2 study of Osimertinib plus bevacizumab versus Osimertinib for untreated patients with non-squamous non-small cell lung cancer harboring EGFR mutations: WJOG9717L study. *J Thorac Oncol*. 2022;17(9):1098–1108. doi:10.1016/j.jtho.2022.05.006
4. Gemma A, Kusumoto M, Sakai F, et al. Real-world evaluation of factors for interstitial lung disease incidence and radiologic characteristics in patients with EGFR T790M positive NSCLC treated with osimertinib in Japan. *J Thorac Oncol*. 2020;15(12):1893–1906. doi:10.1016/j.jtho.2020.08.025
5. Sato Y, Sumikawa H, Shibaki R, et al. Drug-related pneumonitis induced by Osimertinib as first-line treatment for epidermal growth factor receptor mutation-positive non-small cell lung cancer. *Chest*. 2022;162(5):1188–1198. doi:10.1016/j.chest.2022.05.035
6. Kiri T, Tamura D, Tachihara M, et al. Successful osimertinib rechallenge with steroid therapy after osimertinib-induced interstitial lung disease. *Intern Med*. 2018;57:91–95. doi:10.2169/internalmedicine.8947-17
7. Miyauchi E, Ichinose M, Inoue A, et al. Successful osimertinib rechallenge in a patient with T790M-mutant non-small cell lung cancer after osimertinib-induced interstitial lung disease. *J Thorac Oncol*. 2017;12(5):e59–61. doi:10.1016/j.jtho.2017.01.027
8. Nagasaka M, Gadgeel SM. Retreatment with osimertinib following pneumonitis. *Clin Lung Cancer*. 2018;19:e53–55. doi:10.1016/j.clcc.2017.06.017
9. Itano J, Higo H, Ohashi K, et al. Successful re-administration of osimertinib in osimertinib-induced interstitial lung disease with an organizing pneumonia pattern: a case report and literature review. *Intern Med*. 2019;59(6):823–828. doi:10.2169/internalmedicine.3689-19
10. Bickert C, Kathrin K, Kauffmann-Guerrero D, et al. Osimertinib rechallenge under steroid protection following osimertinib-induced pneumonitis: three case studies. *Therapeut Adv Med Oncol*. 2021;13.
11. Satoh S, Shiroyama T, Tamiya M, et al. Successful osimertinib rechallenge after osimertinib-induced pneumonitis in a patient with lung adenocarcinoma. *Respir Med Case Rep*. 2018;23:68–70. doi:10.1016/j.rmcr.2017.12.005
12. Sato Y, Sekine A, Hagiwara E, et al. Successful treatment with Afatinib following the failure of osimertinib rechallenge with osimertinib-induced interstitial lung disease: a case report. *Respir Med Case Rep*. 2021;33:101450. doi:10.1016/j.rmcr.2021.101450
13. Nishima S, Miyanaga A, Saito S, et al. Successful treatment with Afatinib after osimertinib-induced interstitial lung disease in a patient with EGFR-mutant non-small-cell lung cancer. *Intern Med*. 2021;60(4):591–594. doi:10.2169/internalmedicine.5435-20
14. Imaji M, Fujimoto D, Sato Y, et al. Safety and efficacy of Osimertinib rechallenge or continuation after pneumonitis: a multicentre retrospective cohort study. *Eur J Cancer*. 2023;179:15–24. doi:10.1016/j.ejca.2022.10.029
15. Johkoh T, S LK, Nishino M, et al. Chest CT diagnosis and clinical management of drug related pneumonitis in patients receiving molecular targeting agents and immune checkpoint inhibitors: a position paper from the Fleischner Society. *Radiology*. 2021;298(3):550–566. doi:10.1148/radiol.202103427
16. Mok TS, Wu YL, Ahn MJ, et al. Osimertinib or Platinum–Pemetrexed in EGFR T790M-Positive Lung Cancer. *N Engl J Med*. 2017;376(7):629–640. doi:10.1056/NEJMoa1612674

17. Soria JC, Wu YL, Nakagawa K, et al. Gefitinib plus chemotherapy versus placebo plus chemotherapy in EGFR-mutation-positive non-small-cell lung cancer after progression on first-line gefitinib (IMPRESS): a phase 3 randomised trial. *Lancet Oncol.* **2015**;16(8):990–998. doi:10.1016/S1470-2045(15)00121-7
18. Park S, Kim TM, Han JY, et al. Phase III, Randomized Study of Atezolizumab Plus Bevacizumab and Chemotherapy in Patients With EGFR – or ALK –Rearranged or Translocated Non–Small-Cell Lung Cancer (ATLAS, KCSG-LU19-04). *J Clin Oncol.* **2024**;1042(11):1241–1251. doi:10.1200/JCO.23.01891
19. Camus P, Kudoh S, Ebina M, et al. Interstitial lung disease associated with drug therapy. *Br J Cancer.* **2004**;91(S2):s18–23. doi:10.1038/sj.bjc.6602063
20. T.s MOK, Y.I W, Thongprasert S, et al. Gefitinib or carboplatin-paclitaxel in pulmonary adenocarcinoma. *N Engl J Med.* **2009**;361(10):947–957. doi:10.1056/NEJMoa0810699
21. Yamamoto N, Goto K, Nishio M, et al. Final overall survival in JO22903, a Phase II, open-label study of first-line erlotinib for Japanese patients with EGFR mutation-positive non-small-cell lung cancer. *Int J Clin Oncol.* **2017**;22(1):70–78. doi:10.1007/s10147-016-1039-0
22. L.v S, J.C Y, Yamamoto N, et al. Phase III Study of Afatinib or Cisplatin Plus Pemetrexed in Patients With Metastatic Lung Adenocarcinoma With EGFR Mutations. *J Clin Oncol.* **2013**;31(27):3327–3334. doi:10.1200/JCO.2012.44.2806

## OncoTargets and Therapy

Dovepress

### Publish your work in this journal

OncoTargets and Therapy is an international, peer-reviewed, open access journal focusing on the pathological basis of all cancers, potential targets for therapy and treatment protocols employed to improve the management of cancer patients. The journal also focuses on the impact of management programs and new therapeutic agents and protocols on patient perspectives such as quality of life, adherence and satisfaction. The manuscript management system is completely online and includes a very quick and fair peer-review system, which is all easy to use. Visit <http://www.dovepress.com/testimonials.php> to read real quotes from published authors.

Submit your manuscript here: <https://www.dovepress.com/oncotargets-and-therapy-journal>